



Venous Sinus Thrombosis in the Hypoglossal Canal Mimics a Neurogenic Tumor in a Patient with Presumed Idiopathic Intracranial Hypertension: A Case Report

특발 두개내압상승 소견을 보인 환자에서 설하신경관의 신경 원성 종양으로 오인되었던 정맥동 혈전의 케이스: 증례 보고

Kiok Jin, MD , Ji Eun Park, MD* , Jeong Hyun Lee, MD

Department of Radiology and Research Institute of Radiology, University of Ulsan College of Medicine, Asan Medical Center, Seoul, Korea

ORCID iDs

Kiok Jin <https://orcid.org/0000-0003-1267-0899>

Ji Eun Park <https://orcid.org/0000-0002-4419-4682>

Jeong Hyun Lee <https://orcid.org/0000-0002-0021-4477>

Presumed idiopathic intracranial hypertension (IIH) is a disorder of elevated intracranial pressure with unknown etiology, and 10% of cases occur secondarily to cerebral venous sinus thrombosis (CVST). CVST may be underestimated when findings of IIH are missed in a normal-weight patient without risk factors of coagulopathy. Here, we present a case of CVST that mimics a neurogenic tumor in the hypoglossal canal in a normal-weight patient without risk factors of coagulopathy.

Index terms Sinus Thrombosis, Intracranial; Idiopathic Intracranial Hypertension; Diffusion Weighted MRI

INTRODUCTION

Idiopathic intracranial hypertension (IIH) is a disease in which intracranial pressure (ICP) increase without mass like lesion or abnormal cerebrospinal fluid (CSF) composition. Preva-

Received October 20, 2021

Revised March 8, 2022

Accepted May 27, 2022

*Corresponding author

Ji Eun Park, MD

Department of Radiology and
Research Institute of Radiology,
University of Ulsan
College of Medicine,
Asan Medical Center,
88 Olympic-ro 43-gil, Songpa-gu,
Seoul 05505, Korea.

Tel 82-2-3010-1505

Fax 82-2-3010-5682

E-mail jieunp@gmail.com

This is an Open Access article distributed under the terms of the Creative Commons Attribution Non-Commercial License (<https://creativecommons.org/licenses/by-nc/4.0>) which permits unrestricted non-commercial use, distribution, and reproduction in any medium, provided the original work is properly cited.

lence of IIH is increasing and usually occurs in obese female. The use of neuroimaging is important to differentiate causes of IIH including mass lesions, meningitis, and hydrocephalus. Cerebral venous sinus thrombosis (CVST) is another important cause that a previous cohort study reported occurrence of CVST in 9.4% (10/106) of presumed IIH (1).

Hypoglossal canal contains the hypoglossal nerve, emissary veins that joins the sigmoid sinus and occasionally a branch of the ascending pharyngeal artery. Since the canal is a narrow space, a space occupying lesion in this canal may cause hypoglossal nerve palsy. Clinical feature of space-occupying lesion in the hypoglossal canal including schwannomas manifest ipsilateral hemiatrophy and deviation of the tongue. Here, we present a case of a 41-year-old female with left sided tongue deviation of 1-month duration and exhibiting a space-occupying mass like lesion in the hypoglossal canal on MR imaging.

CASE REPORT

A 41-year-old female presented to clinic with left side tongue deviation, headache and strange feeling in the mouth for 1 month. She was a normal range of body weight of 64 kg

Fig. 1. Venous sinus thrombosis mimicking a neurogenic tumor in a 41-year-old female.

A. Axial T2-weighted image shows a 1.5-cm well-defined lobulated mass-like lesion (long arrow) in the left hypoglossal canal. The mass shows homogenous low T2 signal intensity. In the right hypoglossal canal, a 6-mm sized perineural cyst is noted (short arrow). A CE-T1w image reveals the mass-like lesion with thin peripheral CE (arrow). The DWI and ADC map show diffusion restriction of the mass with a low ADC value of $0.049 \times 10^{-3} \text{ mm}^2/\text{s}$ (arrows).

ADC = apparent diffusion coefficient, CE-T1w = contrast-enhanced T1-weighted image, DWI = diffusion-weighted imaging

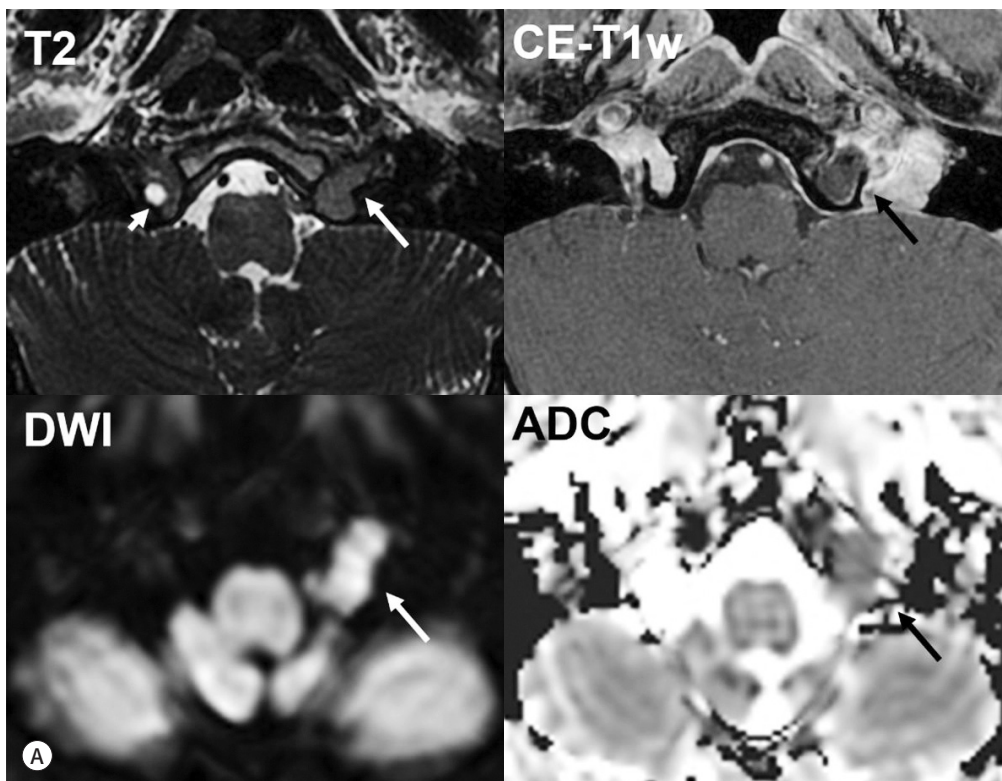
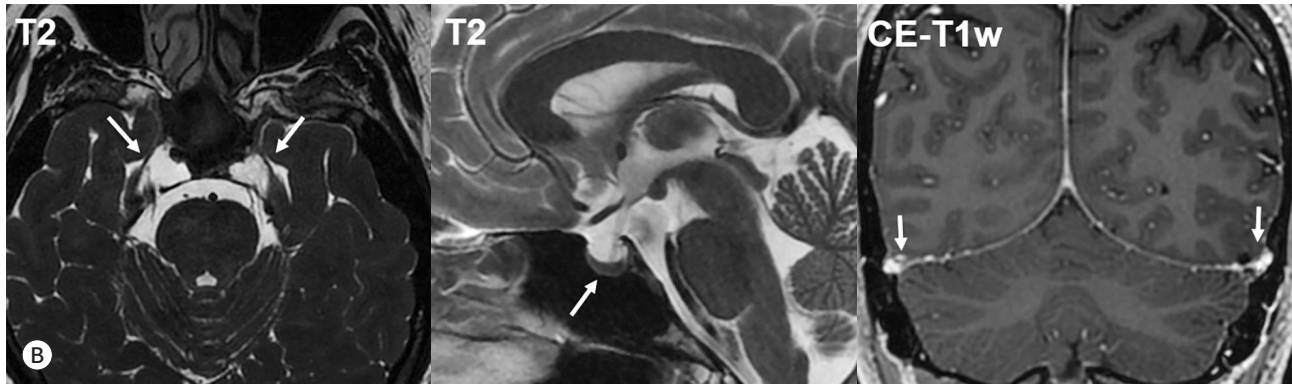


Fig. 1. Venous sinus thrombosis mimicking a neurogenic tumor in a 41-year-old female.

B. Findings of intracranial hypertension on initial exam. Axial T2-weighted image shows a dilated bilateral Meckel's cave (arrows), suggesting meningocele. The loss of pituitary height (arrow) on the mid-sagittal T2-weighted image is also noted. The decreased height shows about two-thirds concavity of the sella. Coronal CE-T1w reveals relatively luminal narrowing (arrows) of the bilateral transverse dural sinuses.

CE-T1w = contrast-enhanced T1-weighted image



with body mass index of 23.6 (according to the stage of overweight as defined by National Institute of Health) and had no other special medical history, including blood clotting disorders. Brain MRI showed a 1.5 cm-sized, well-defined lobulating mass-like lesion in the left hypoglossal canal (Fig. 1A). The lesion showed homogeneous iso-signal intensity on T2WI and thin peripheral contrast enhancement on contrast-enhanced T1-weighted image (CE-T1w). On the diffusion-weighted imaging (DWI) and apparent diffusion coefficient (ADC) map, the mass showed diffusion restriction with low ADC value, $0.49 \times 10^{-3} \text{ mm}^2/\text{s}$. Our differential diagnosis was a neurogenic tumor with cystic change. On the other hand, the patient has ancillary findings of presumed IIH (Fig. 1B). Axial T2-weighted image showed dilated bilateral Meckel's cave, suggesting meningocele. The loss of pituitary height was also noted on the mid-sagittal T2WI. The decreased height showed about 2/3 concavity of the sella. Coronal CE-T1w depicted relatively luminal narrowing of bilateral transverse dural sinuses.

Thus, radiologic suspicion of CVST was raised for the space-occupying lesion at the hypoglossal canal by an expert neuroradiologist (J.H.L., 25 year of experience in skull base imaging). The clinicians were informed of possibility of CVST and the follow up MRI exam was scheduled.

On MR taken at 3 weeks interval (Fig. 1C), the lesion showed decreased volume with more thickened rim enhancement, showing connecting to adjacent vessel. And diffusion restriction seen before was no longer visible. These dynamic changes suggested CVST in the hypoglossal canal. There were no changes in the IIH associated findings.

Because clinical symptoms including tongue deviation were improving, conservative management was planned for this patient. Also after 6 months follow up, the palsy was improved.

This study was approved by the Institutional Review Board of Asan Medical Center and the requirement for informed consent was waived (IRB No. 2021-1429).

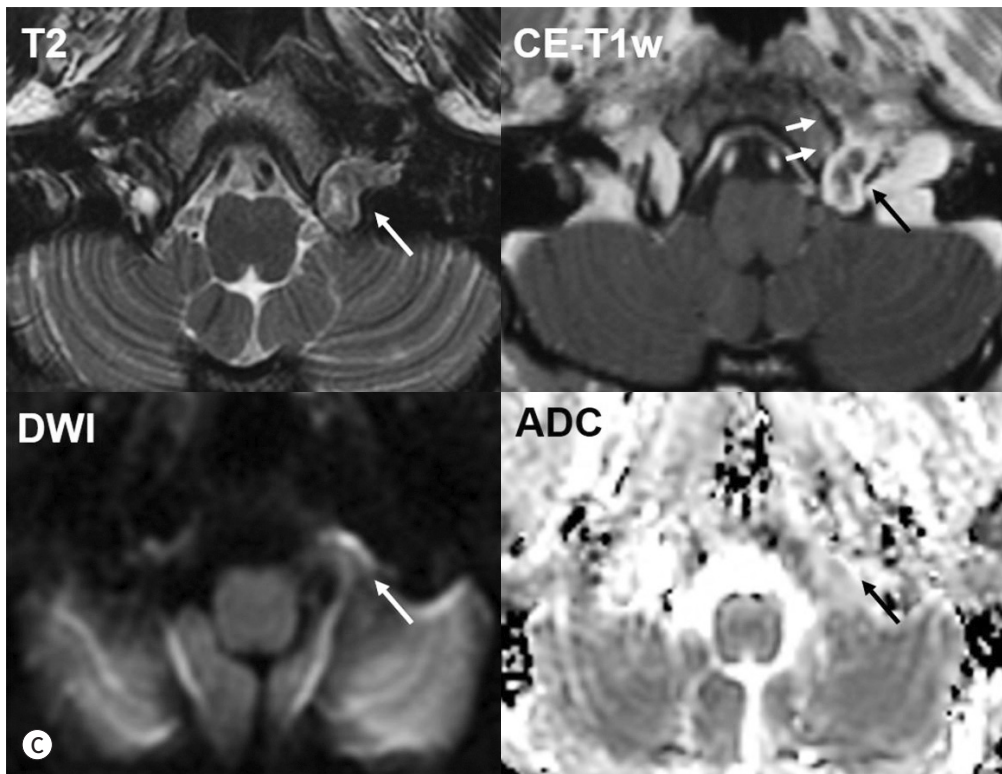
DISCUSSION

We presented a case with CVST in hypoglossal canal initially misdiagnosed as a neurogenic

Fig. 1. Venous sinus thrombosis mimicking a neurogenic tumor in a 41-year-old female.

C. Images obtained after a 3-week interval from the previous MR images (**A**) are shown. An axial T2-weighted image shows the decreased volume of the previously noted mass-like lesion in the left hypoglossal canal (arrow). On the axial CE-T1w image, a mass-like lesion shows decreased volume with more thickened rim enhancement (long arrow), demonstrating a connection with the adjacent vessel (short arrows). The diffusion restriction observed before is no longer visible (arrows). These dynamic changes suggest cerebral venous thrombosis in the hypoglossal canal.

ADC = apparent diffusion coefficient, CE-T1w = contrast-enhanced T1-weighted image, DWI = diffusion-weighted imaging



tumor. Careful observation of CSF space and veins raised clinical suspicion of presumed IIIH and associated CVST. On three weeks follow-up MRI, the mass like lesion revealed to be a CVST because of decreased volume and disappeared diffusion restriction. Our case emphasizes the neuroradiologic importance of careful observation to raise suspicion of CVST and follow-up imaging in a patient without risk factor of coagulopathy.

The diagnosis of CVST was made with evolution of high signal intensity on DWI as well as associated findings of IIIH. Atlas et al. (2) explained that potential cause of the diffusion restriction of the early stages of intracranial hematoma as follows: 1) a shrinkage of extracellular space with clot retraction, 2) a change in osmotic environment, 3) conformational changes of the hemoglobin macromolecule within the red blood cell, and 4) contraction of intact red blood cells. Temporal evolution of hematoma was observed in previous studies. In one study, it was noted that hematoma showed increased diffusion restriction up to 100 hours and normalized at 500 hours (3). In another study, high signal intensity on DWI was absent on MRI performed 2–3 months later, after the first examination (4). In our case, when referring to the follow up MR after 3 weeks, the DWI high signal intensity was partially normalized, which could be ex-

plained by hematoma evolution.

Diagnostic criteria for adult IIH is as follows: papilledema, normal neurologic examination except for cranial nerve abnormalities, normal CSF composition, and elevated CSF opening pressure (≥ 25 cm H₂O), and neuroimaging findings. Neuroimaging findings include normal brain parenchyma without hydrocephalus, no abnormal mass or structural lesion, but presence of venous sinus thrombosis. Neuroimaging of signs of elevated ICP such as perioptic subarachnoid space distension and an empty sella are frequently found, but these radiologic findings, however, need to be confirmed with further studies prior to incorporation into diagnostic guidelines (5). In our study, the findings include dilated bilateral Meckel's cave, loss of pituitary height and luminal narrowing of bilateral transverse dural sinuses. Nonetheless, the spinal tapping was not conducted for this patient and this could be a limitation.

Imaging features of IIH enabled to raise clinical suspicion of CVST. Previous review article reported typical neuroimaging findings in presumed IIH, including empty sella, distension of the optic nerve sheath, a posterior scleral flattening of optic globe, transverse sinus stenosis, CSF leak and meningocele such as Meckel's cave and foramen ovale widening (5). Sensitivity of empty sella, meningocele and transverse sinus venous stenosis was reported 80%, 11% and 97% in one review article (5),

Previous retrospective studies reported presence of CVST of 9.4% (10/106) (1) or 11.4% (35/308) (6) in patients who were presumed to have IIH. These studies (1, 6) emphasized that MRI combined with MR venography should be undertaken to rule out CVST, especially when risk factors of CVST may not be apparent. When MR venography is not feasible, follow-up MRI with DWI may become an alternative option. It is unclear whether venous sinus thrombosis are the consequence or cause of IIH (7, 8). In a proposal earlier, IIH was divided into 2 types as primary and secondary, and venogenic IIH was used for the type of secondary IIH originating from the pathology in venous sinuses (8). According to standard criteria, it is necessary to exclude venous thrombosis for the diagnosis of IIH, but in the latter classification, sinus vein thrombosis is reported as an etiological factor in secondary IIH. In this perspective, our case is thought to be a secondary IIH with venogenic cause of IIH."

The top differential diagnosis of the present case was neurogenic tumor in the hypoglossal canal. Two case reports reviewed dilated venous plexus of the hypoglossal canal mimicking disease, such as nerve sheath tumor. One case presented a similar case of CVST in the hypoglossal canal, exhibiting hemiglossal atrophy (9); nonetheless, the case was different from ours that IIH was not accompanied. One case could identified due to the continuity adjacent venous structure on the CE-T1w (9), another was confirmed by operation (10). Our case enabled to avoid a wrong imaging diagnosis from evolving diffusion restriction signal intensity, review of ancillary imaging findings of IIH and raise suspicion of CSVT.

In conclusion, this report demonstrates a rare case of CVST in hypoglossal canal that was initially diagnosed as a neurogenic tumor. Careful observation by neuroradiologists may find imaging features relevant to IIH and follow-up MRI or subsequent MR venography need to be recommended to reach final diagnosis.

Author Contributions

Conceptualization, P.J.E., L.J.H.; data curation, J.K.; investigation, J.K.; writing—original draft, J.K., P.J.E.; and writing—review & editing, P.J.E., L.J.H.

Conflicts of Interest

The authors have no potential conflicts of interest to disclose.

Funding

None

REFERENCES

1. Lin A, Foroozan R, Danesh-Meyer HV, De Salvo G, Savino PJ, Sergott RC. Occurrence of cerebral venous sinus thrombosis in patients with presumed idiopathic intracranial hypertension. *Ophthalmology* 2006;113:2281-2284
2. Atlas SW, DuBois P, Singer MB, Lu D. Diffusion measurements in intracranial hematomas: implications for MR imaging of acute stroke. *AJNR Am J Neuroradiol* 2000;21:1190-1194
3. Kamal AK, Dyke JP, Katz JM, Liberato B, Filippi CG, Zimmerman RD, et al. Temporal evolution of diffusion after spontaneous supratentorial intracranial hemorrhage. *AJNR Am J Neuroradiol* 2003;24:895-901
4. Favrole P, Guichard JP, Crassard I, Bousser MG, Chabriat H. Diffusion-weighted imaging of intravascular clots in cerebral venous thrombosis. *Stroke* 2004;35:99-103
5. Bidot S, Saindane AM, Peragallo JH, Bruce BB, Newman NJ, Biouesse V. Brain imaging in idiopathic intracranial hypertension. *J Neuroophthalmol* 2015;35:400-411
6. Agarwal P, Kumar M, Arora V. Clinical profile of cerebral venous sinus thrombosis and the role of imaging in its diagnosis in patients with presumed idiopathic intracranial hypertension. *Indian J Ophthalmol* 2010;58:153-155
7. Friedman DI, Jacobson DM. Idiopathic intracranial hypertension. *J Neuroophthalmol* 2004;24:138-145
8. Türoy S, Kabakuş N, Hanci F, Tunçlar A, Hizal M. Cause or consequence: the relationship between cerebral venous thrombosis and idiopathic intracranial hypertension. *Neurologist* 2019;24:155-160
9. Stuckey SL. Dilated venous plexus of the hypoglossal canal mimicking disease. *AJNR Am J Neuroradiol* 1999;20:157-158
10. Shiozawa Z, Koike G, Seguchi K, Shindo K, Sugita K. Unilateral tongue atrophy due to an enlarged emissary vein in the hypoglossal canal. *Surg Neurol* 1996;45:477-479

특발 두개내압상승 소견을 보인 환자에게서 설하신경관의 신경 원성 종양으로 오인되었던 정맥동 혈전의 케이스: 증례 보고

진기욱 · 박지은* · 이정현

특발 두개내압상승은 특별한 기질적 원인 없이 두개 내압의 증가가 생기는 증후군으로 이 질환의 약 10%에서 두개내 정맥동의 혈전 형성이 생길 수 있다고 알려져 있다. 체중이 정상 범위이며 응고 장애가 없는 특발 두개내압상승 환자에게서 정맥동의 혈전 형성은 간과될 수 있다. 본 증례 보고에서는 특별한 위험인자가 없던 환자에게서 설하신경관의 신경 원성 종양으로 오인되었던 정맥동 혈전의 케이스를 소개하고, 두개 내압상승의 다양한 영상 소견에 대해 고찰하고자 한다.

울산대학교 의과대학 서울아산병원 영상의학과