



Subungual Mixed Tumor Mimicking Glomus Tumor: A Case Report and Literature Review


사구체 종양으로 오인된 손톱 밑 종양: 증례 보고와
문헌 고찰

Jaemin Kim, MD¹ , Hyeongju Kwon, MD² ,
Jinrok Oh, MD³ , Hyunjung Kim, MD^{1*} 

Departments of ¹Radiology, ²Pathology, and ³Orthopedic Surgery, Yonsei University
Wonju College of Medicine, Wonju, Korea.

ORCID iDs

Jaemin Kim  <https://orcid.org/0000-0001-9959-8978>

Hyeongju Kwon  <https://orcid.org/0000-0003-1615-7152>

Jinrok Oh  <https://orcid.org/0000-0002-6868-2496>

Hyunjung Kim  <https://orcid.org/0000-0001-6522-9883>

Mixed tumors are well-circumscribed lesions exhibiting epithelial and/or myoepithelial cells and they usually occur in the skin and salivary glands. Soft tissue mixed tumors are extremely rare. Therefore, radiographic findings of soft tissue mixed tumors have very rarely been described in the radiologic literature. Here, we report a rare case of subungual mixed tumor in a 65-year-old female who presented with left 2nd finger pain, describe the radiographic findings, and discuss the differential diagnosis of the tumor.

Index terms Tumor; Subungual Tumor; Magnetic Resonance Imaging

INTRODUCTION

The normal subungual space is small and various pathologic types of tumors can occur in the subungual space (1).

The mixed tumor, first described Minssen in 1874 has both epithelial and mesenchymal features and usually develops in the skin and major or minor salivary glands (2-4). The tumor exhibits histological complexity because myoepithelial cells can be differentiated into various cell types (e.g., squamous, chondroid, or spindled) (5). Mixed tumor of soft tissue is ex-

Received April 21, 2021
Revised July 22, 2021
Accepted November 9, 2021

*Corresponding author

Hyunjung Kim, MD
Department of Radiology,
Yonsei University
Wonju College of Medicine,
20 Ilsan-ro, Wonju 26426, Korea.

Tel 82-33-741-1474

Fax 82-33-732-8281

E-mail radkhj@yonsei.ac.kr

This is an Open Access article distributed under the terms of the Creative Commons Attribution Non-Commercial License (<https://creativecommons.org/licenses/by-nc/4.0>) which permits unrestricted non-commercial use, distribution, and reproduction in any medium, provided the original work is properly cited.

tremely rare, and only a hundred cases have been reported (2-4, 6-8). The authors encountered a first case of subungual mixed tumor in the left 2nd finger, which was diagnosed preoperatively as a glomus tumor. To our knowledge, there has not been a report of a mixed tumor of subungual space.

CASE REPORT

A 65-year-old female presented at our hospital with a 3-year history of severe pain and sensitivity to cold in the tip of her left 2nd finger. Physical examination showed tenderness and deformity of her fingernail in left 2nd finger. She had numerous visits to our hospital in the past, with multiple different diagnoses including papillary thyroid carcinoma, hyperparathyroidism, and chronic kidney disease.

Plain radiography showed scalloping on dorsal side and no periosteal reaction, cortical destruction, or tumor matrix in the left index finger (Fig. 1A). MRI revealed a circumscribed oval shape mass in the subungual space of the left index finger. With a homogeneous contrast enhancement after contrast material injected, the tumor showed hyperintensity on T2-weighted image and fat-suppressed T2-weighted image and isointensity on T1-weighted image (Fig. 1B). The authors analyzed the tumor on dynamic contrast enhancement MRI image using a post-processing program (Syngo Via, version VB30A, Siemens Healthcare, Erlangen, Germany). The region of interest was manually placed in the tumor in the left index finger. A time-intensity curve was then created and showed rapid initial enhancement followed by sustained late enhancement (Fig. 1C) (9). Combining clinical and radiological clues, we suspected the tumor as glomus tumor.

Under local anesthesia, the nail of the left index finger was extracted. A $3 \times 3 \text{ mm}^2$ sized whitish mass was exposed and removed (Fig. 1D). Pathologically, the tumor was well circumscribed and consisted of variable myoepithelial cells and myxoid stromal components in a mixture of patterns (Fig. 1E). The final diagnosis was a mixed tumor. Fifteen days later, the total stitch out was done without any complication of on the left index finger.

This study was approved by the Institutional Review Board of our hospital, and the requirement for informed consent was waived.

DISCUSSION

According to several previous studies, soft tissue mixed tumor was diagnosed at various ages, ranging from the ages of 2-83, and peak incidence was 3rd-4th decades. Gender distribution was almost identical, and the duration of symptoms ranged from 2 weeks to 20 years (average of 4 years). Symptoms included painless mass, painful mass, only pain, swelling, paresthesia, and so on (4, 6). This tumor is so rare that there is no prediction established for prognosis, but the presence of high grade cytologic atypia and infiltrative margin increases the likelihood of malignant tumors. Most of them are benign, such as those tumors in the salivary glands, but complete resection is required due to metastasis or relapse, and chemotherapy or radiotherapy is combined depending on the patient's situation (2, 4, 6-8).

The four reports were analyzed, including radiologic findings, with mixed tumors of soft

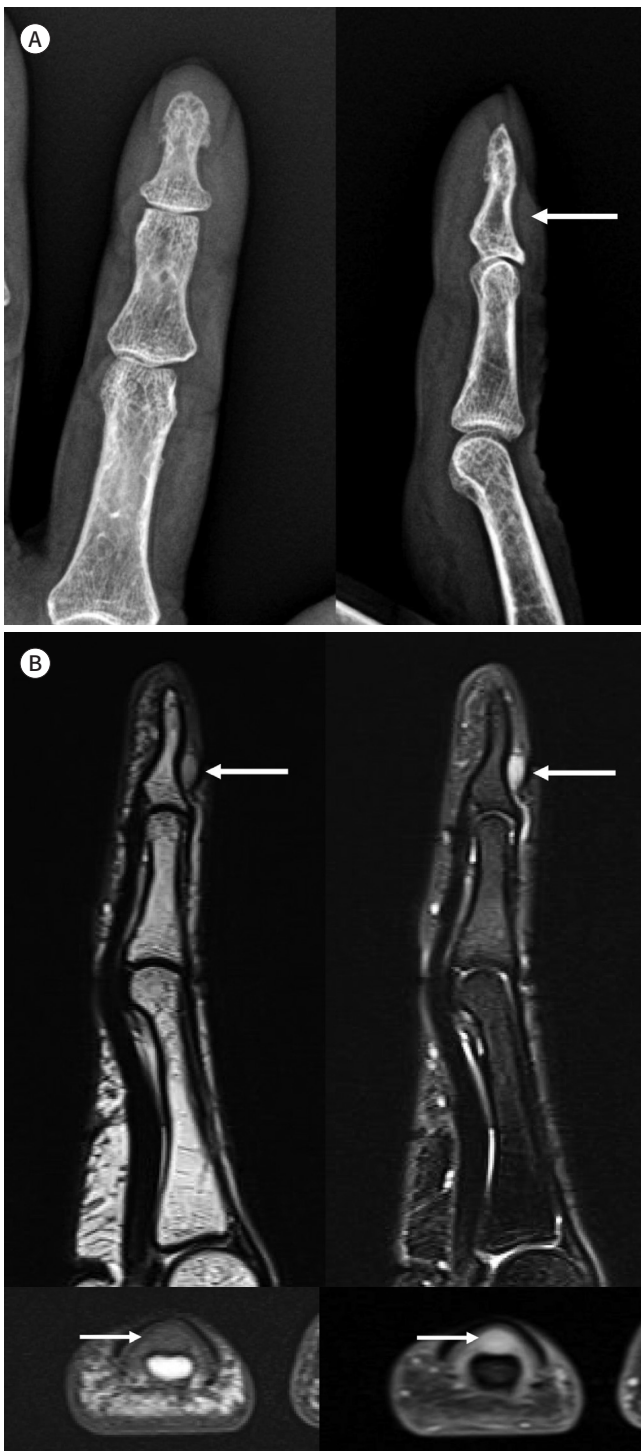

Fig. 1. A subungual mixed tumor in a 65-year-old female.

A. On anteroposterior and lateral radiographs of the left index finger, scalloping (arrow) is observed on the dorsal side of the left index finger. No periosteal reaction, cortical destruction, and tumor matrix ossification are observed.

B. The tumor (arrows) shows hyperintensity on sagittal T2-weighted image (left) and fat-suppressed T2-weighted image (right) (upper image). The tumor (arrows) shows isointensity on axial T1-weighted image (left lower image) and homogeneous enhancement on axial contrast-enhanced T1-weighted image (right lower image).

tissue respectively (Table 1) (2, 3, 7, 8). Three of those tumors showed heterogeneous signal intensity on MRI and were located in the upper and lower extremities and these findings are presumably due to difference in the heterogeneity of tumor (e.g., by hemorrhage, chondromyxoid and fibrous stroma) (2, 3, 8). Unlike these three cases, the tumor in our case showed homogeneous signal intensity. The authors thought this was due to homogeneously inter-

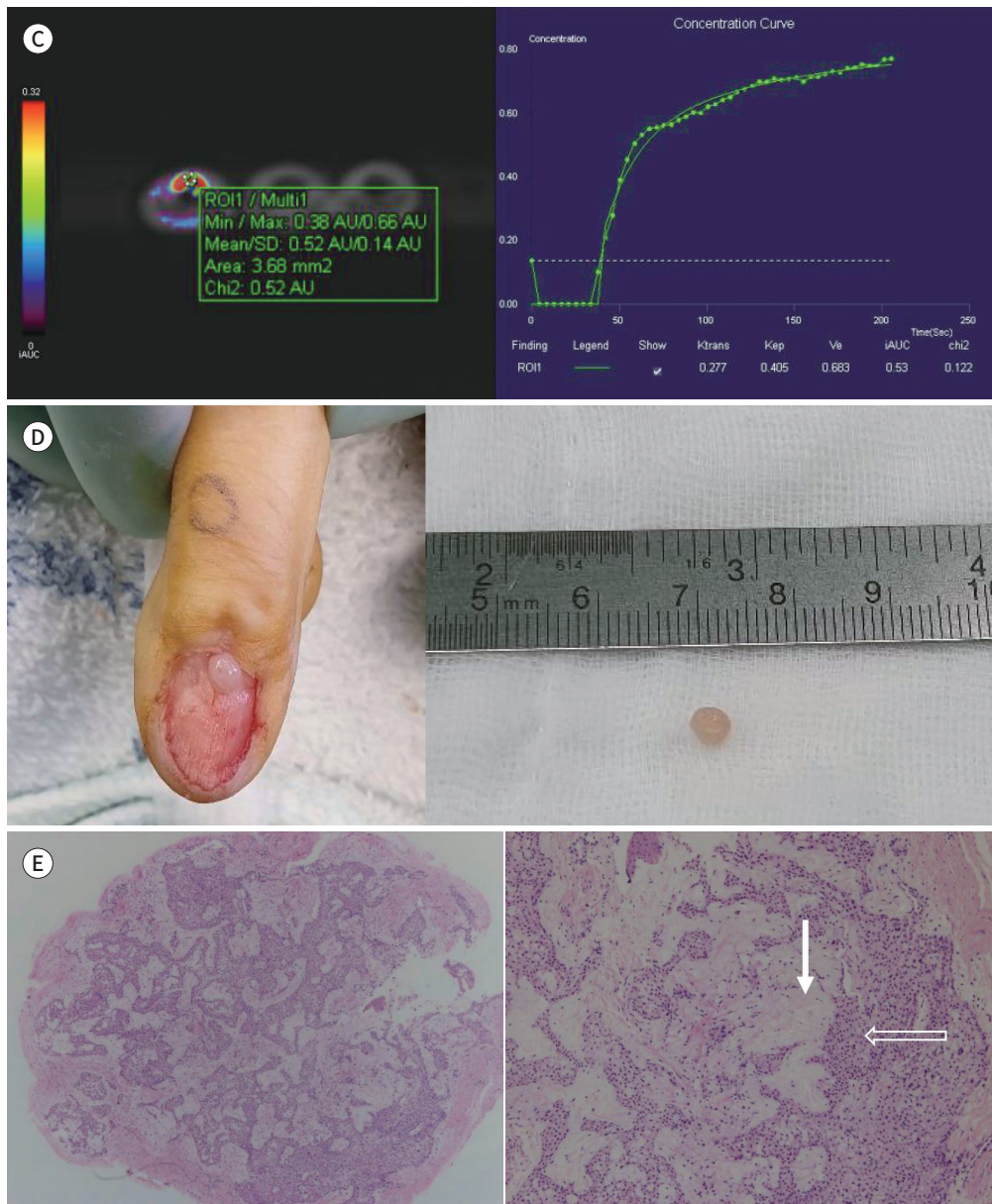
Fig. 1. A subungual mixed tumor in a 65-year-old female.

C. An axial dynamic contrast enhancement MR image (left) is displayed, and the circular ROI is drawn on the tumor; the corresponding time-intensity curve (right) shows a rapid initial enhancement followed by sustained late enhancement, suggesting a benign lesion.

D. Intraoperatively, a 3 × 3 mm²-sized whitish mass is noted in the subungual space of the left index finger.

E. On microscopy, the lesion is well circumscribed (hematoxylin & eosin stain; × 40) (left); the tumor is composed of variable myoepithelial cells (open arrow) and myxoid stromal components (arrow) in a mixture of patterns (hematoxylin & eosin stain; × 100) (right).

ROI = regions of interest, SD = standard deviation



mingled various cells and relatively small size. Actually, when pathologically analyzed, various cells were homogeneously intermingled. In the other case report, the tumor was evaluated only with a simple radiograph due to the previous history of total knee arthroplasty (7).

The subungual space is a small space about 1–2 mm thick, where various histological types

Table 1. A Review of the Literature on Mixed Tumors in the Soft Tissue

Study	Age	Sex	Site	MRI Finding
Shimosawa et al. (2), 2009	79	Female	Hypothenar region of hand	Heterogeneous subtle hyperintense (T2WI, T1WI)
Terada (3), 2014	56	Male	Arm	Heterogeneous hyperintense (T2WI)
Tomoeda et al. (7), 2011	70	Female	Knee	None
Adachi et al. (8), 2003	12	Female	Ankle	Hyperintense (T2WI) Heterogeneous enhancement (enhanced T1WI)

T1WI = T1-weighted image, T2WI = T2-weighted image

of tumors can appear. When a subungual tumor is identified, the differential diagnosis should include glomus tumor, soft tissue chondroma, hemangioma, lobular capillary hemangioma, epidermal cyst, and squamous cell carcinoma (1). Glomus tumor is a hamartoma originating from neuromyoarterial glomus body. MR imaging features are iso- or hypointensity on T1-weighted images, marked hyperintensity on T2-weighted images, and intense enhancement after injection of contrast material (1). There have been no study using dynamic contrast enhancement imaging for glomus tumor in soft tissue, but there is a study that the glomus tumor in stomach showed persistent, intense enhancement in arterial phase and portal venous phase (10). Soft tissue chondroma is rare benign tumor that consists of a small cartilaginous nodule without connection to the adjacent bone. MR imaging is isointensity on T1-weighted images and hyperintensity on T2-weighted images and strong enhancement after injection of contrast material. When calcification is present, the corresponding hypointense foci are noted on all MRI sequences (1). Hemangioma is benign nonreactive process accompanying an increase in the number of normal or abnormal vessels. MR imaging features are well-defined or rarely infiltrative margins, isointensity on T1-weighted images, extremely hyperintensity on T2-weighted images and can show heterogeneous hyperintensity due to reactive fatty tissue around the neoplastic vessels, or by vessels filled with blood in both sequences. Vascular components show serpentine heterogeneous signal intensity on T2-weighted images, along with flow void artifacts. Phleboliths, calcifications, or fibrosis can be accompanied. After injection of contrast material, MRI reveals serpentine or lattice-like enhancement of the tumor. Although MR signal is similar to the glomus tumor, hemangioma has a more superficial location in the papillary dermis and epidermis (1). Lobular capillary hemangioma is relatively common vascular tumor of the skin and mucous membranes. In the past, it was called pyogenic granuloma. MR imaging demonstrates isointensity on T1-weighted images and hyperintensity on T2-weighted images, and salient enhancement after injection of contrast material (1). Epidermal cyst is caused by the proliferation of epidermal cells in the dermis. MR imaging features are hyperintensity with variable hypointense components on T2-weighted images and bright foci on T1-weighted images. This tumor maybe shows isointensity on both T1- and T2-weighted images because of its histologic components, such as keratin debris and intraluminal calcifications. After injection of contrast material, MRI reveals thin peripheral enhancement. If it is ruptured, it can show irregular, thick peripheral enhancement, perilesional infiltration, and internal septations (1). Squamous cell carcinoma develops from squamous epithelium of the epidermis and is regarded as low-grade malignancy. MR imaging is homogeneous hypointensity on T1-weighted images, isointensity on T2-weighted im-

ages, and heterogeneous contrast enhancement after injection of contrast medium. Intramedullary hyperintense lesion often is associated due to bone marrow edema, which occurred by reactive change, tumor infiltration, or combined infection (1).

In our case, the clinical and radiological clues of the subungual tumor were quite consistent with the glomus tumor, so our preoperative diagnosis was a glomus tumor. However, pathologically, the tumor turned out to be a mixed tumor.

In conclusion, the mechanism for developing mixed tumor of soft tissue remains unknown. Further investigation is needed to clarify the mechanism. Subungual tumors are frequently diagnosed as glomus tumor, and mixed tumor may occur; however, there is no significant difference on radiological findings. Therefore, the physicians and radiologists should carefully consider the possibility of this unexpected identity of the tumor.

Author Contributions

Conceptualization, K.H.; data curation, all authors; formal analysis, K.H.; investigation, K.J.; methodology, K.H., K.J.; project administration, K.H.; resources, K.H., K.J., K.H.; software, K.H., K.J.; supervision, K.H.; validation, O.J., K.H.; visualization, K.H., K.J.; writing—original draft, K.J.; and writing—review & editing, K.H., K.J.

Conflicts of Interest

The authors have no potential conflicts of interest to disclose.

Funding

None

REFERENCES

1. Baek HJ, Lee SJ, Cho KH, Choo HJ, Lee SM, Lee YH, et al. Subungual tumors: clinicopathologic correlation with US and MR imaging findings. *Radiographics* 2010;30:1621-1636
2. Shimosawa H, Susa M, Honma T, Hiraishi E, Sakihara H. Soft tissue mixed tumor of the hand. *Rare Tumors* 2009;1:e30
3. Terada T. Mixed tumor of the soft tissue (arm). *Hum Pathol: Case Rep* 2014;1:52-57
4. Kilpatrick SE, Hitchcock MG, Kraus MD, Calonje E, Fletcher CD. Mixed tumors and myoepitheliomas of soft tissue: a clinicopathologic study of 19 cases with a unifying concept. *Am J Surg Pathol* 1997;21:13-22
5. Erlandson RA, Cardon-Cardo C, Higgins PJ. Histogenesis of benign pleomorphic adenoma (mixed tumor) of the major salivary glands. An ultrastructural and immunohistochemical study. *Am J Surg Pathol* 1984;8:803-820
6. Hornick JL, Fletcher CD. Myoepithelial tumors of soft tissue: a clinicopathologic and immunohistochemical study of 101 cases with evaluation of prognostic parameters. *Am J Surg Pathol* 2003;27:1183-1196
7. Tomoeda M, Yuki M, Kubo C, Yoshizawa H, Kitamura M, Nagata S, et al. Malignant mixed tumor of the soft tissue occurring after total knee arthroplasty. *Orthopedics* 2011;34:e768-e771
8. Adachi T, Oda Y, Sakamoto A, Saito T, Tamiya S, Hachitanda Y, et al. Mixed tumor of deep soft tissue. *Pathol Int* 2003;53:35-39
9. van Rijswijk CS, Geirnaerd MJ, Hogendoorn PC, Taminiu AH, van Coevorden F, Zwinderman AH, et al. Soft-tissue tumors: value of static and dynamic gadopentetate dimeglumine-enhanced MR imaging in prediction of malignancy. *Radiology* 2004;233:493-502
10. Liu KL, Wang HP, Tseng WY, Shun CT, Chen SJ, Tsang YM. Glomus tumor of the stomach: MRI findings. *AJR Am J Roentgenol* 2005;185:1190-1192

사구체 종양으로 오인된 손톱 밑 종양: 증례 보고와 문헌 고찰

김재민¹ · 권형주² · 오진록³ · 김현중^{1*}

혼합 종양은 상피세포와 근상피세포로 나타나는 경계가 좋은 종양이며 대개 피부와 침샘에서 발생한다. 연조직에서 발생하는 혼합 종양은 극히 드물다. 이에 따라, 연조직에서 발생한 혼합 종양에 대한 영상의학적 소견들은 영상의학 문헌에서 극히 드물게 언급되었다. 그러므로, 저자는 좌측 2번째 손가락의 통증을 주소로 내원한 65세 여자 환자의 손톱 밑 혼합 종양의 증례를 보고하고자 하며, 영상의학적 소견을 기술하고, 감별 진단들에 대해 논의하고자 한다.

연세대학교 원주의과대학 ¹영상의학교실, ²병리학교실, ³정형외과학교실