



# Diffuse Large B-Cell Lymphoma Associated with a Chronic Inflammatory Condition Induced by Metallic Implants: A Case Report

금속성 임플란트로 인한 만성 염증 상태와 연관된 미만성 거대 B세포 림프종: 증례 보고

Jin Hee Park, MD , Sun Joo Lee, MD\* , Hye Jung Choo, MD

Department of Radiology, College of Medicine, Inje University, Busan Paik Hospital, Busan, Korea

Chronic inflammatory condition associated with metallic implant insertion is a risk factor for diffuse large B-cell lymphoma (DLBCL). Metal ions play a role in the pathogenesis of lymphoma. We report a rare case of DLBCL in a patient who had a metallic implant in the proximal tibia for 15 months. Radiologic studies, including US and MRI, showed disproportionately large extraosseous soft-tissue mass and bone marrow involvement without prominent bone destruction. Multiple complications are associated with metallic implants, and misdiagnosis may lead to inappropriate treatment. Therefore, distinguishing lymphomas caused by a metallic implant-induced chronic inflammatory condition from other periprosthetic benign lesions and malignant soft tissue masses is challenging, but it is critical.

**Index terms** Prostheses and Implants; Diffuse Large B-Cell Lymphoma; Magnetic Resonance Imaging; Ultrasonography

## INTRODUCTION

In 2008, the World Health Organization classification of tumors of hematopoietic and lymphoid tissues categorized diffuse large B-cell lymphoma (DLBCL) associated with chronic inflammation (DLBCL-CI) as a distinct entity (1). Many cases have been reported, mainly in Japanese patients, under the term pyothorax-associated lymphoma (1). However, lymphoma arising in the context of other chronic inflammatory conditions, such as the conditions induced by metallic implants in bone, is very rare (1).

Received August 13, 2021  
Revised November 1, 2021  
Accepted December 14, 2021

\*Corresponding author

Sun Joo Lee, MD  
Department of Radiology,  
College of Medicine,  
Inje University,  
Busan Paik Hospital,  
75 Bokji-ro, Busanjin-gu,  
Busan 47392, Korea.

Tel 82-51-890-6579

Fax 82-51-896-1085

E-mail [sunjulee98@gmail.com](mailto:sunjulee98@gmail.com)

This is an Open Access article distributed under the terms of the Creative Commons Attribution Non-Commercial License (<https://creativecommons.org/licenses/by-nc/4.0>) which permits unrestricted non-commercial use, distribution, and reproduction in any medium, provided the original work is properly cited.

**ORCID iDs**

Jin Hee Park

<https://orcid.org/0000-0001-8549-7834>

Sun Joo Lee

<https://orcid.org/0000-0001-6210-9720>

Hye Jung Choo

<https://orcid.org/0000-0003-3941-6989>

It has been proposed that chronic antigen stimulation and immune suppression are associated with the development of DLBCL (2). Metallic debris is antigenic and induces chronic inflammation even in the absence of infection (3). In addition, there are concerns regarding the possible carcinogenic effect of metal ions; however, the data are not conclusive (4-6). The radiologic manifestations of metallic implant-associated DLBCL are consistent with those of primary bone lymphoma (7). Here, we report a patient with DLBCL that was associated with chronic inflammation in the context of a metallic implant.

## CASE REPORT

In September 2016, a 58-year-old male underwent a high tibial osteotomy (HTO) of the right lower extremity due to a right medial meniscus tear. After 14.5 months, he underwent a scheduled hardware removal operation (HWR) at a local clinic. Five days before the HWR, he complained of right lower extremity pain. Two weeks after the HWR, he complained of aggravated right lower extremity pain, swelling, and redness. He was transferred to our hospital, and radiologic examinations, including US and MRI, were performed.

On anteroposterior view serial radiographs of the right knee, a newly developed focal low-density lesion in the proximal tibia meta-epiphysis was observed 12 months after HTO. This lesion was more prominent 15 months after HTO as a focal permeative-type osteolytic lesion with a periosteal reaction in the distal portion (Fig. 1A). There was no evidence of focal osteolytic lesions or mass-forming lesions in radiographs and MRI before HTO.

Preoperative MRI scans obtained 14.5 months after HTO and immediately before HWR showed abnormal bone marrow signal intensity of the right tibia, despite limited evaluation due to metal artifacts. Additionally, an approximately 6.5 cm × 3.7 cm × 7.7 cm lesion in the right popliteal area showed homogeneous high signal intensity on T2-weighted imaging (T2WI) and an intermediate to high signal intensity on proton density (PD) imaging (Fig. 1B). Postoperative MRI scans, which were obtained 15 months after HTO and 2 weeks after HWR, showed diffuse marrow involvement and an approximately 7.8 cm × 3.7 cm × 9.2 cm extensive extraosseous soft tissue mass-like lesion with a relatively preserved trabecular pattern and bony cortex in the right tibia. The lesion showed intermediate signal intensity on PD imaging and iso- to slightly low signal intensity on T1-weighted imaging (T1WI) with heterogeneous patchy enhancement. This extraosseous soft tissue mass with diffuse bone marrow involvement enlarged rapidly based on a comparison with the previous MRI scan obtained 2 weeks prior (Fig. 1C).

US showed heterogeneous hypoechoic lesions in the pretibial and popliteal regions of the right lower extremity, which contained increased vascularity with an irregular but relatively preserved right tibia cortex (Fig. 1D).

US-guided biopsy of the hypoechoic lesion in the popliteal area of the right knee was performed. Histological analysis revealed extensive infiltration by lymphoid cells. At low-power magnification, lymphoid cells infiltrated into smooth muscle fibers. At high-power magnification, the infiltrated area showed large neoplastic lymphoid cells with large and vesicular nuclei with large nucleoli and scant cytoplasm. In addition, irregular cellular membranes with no specific architecture were observed. Lymphoma cells expressed CD20 and BCL6 but

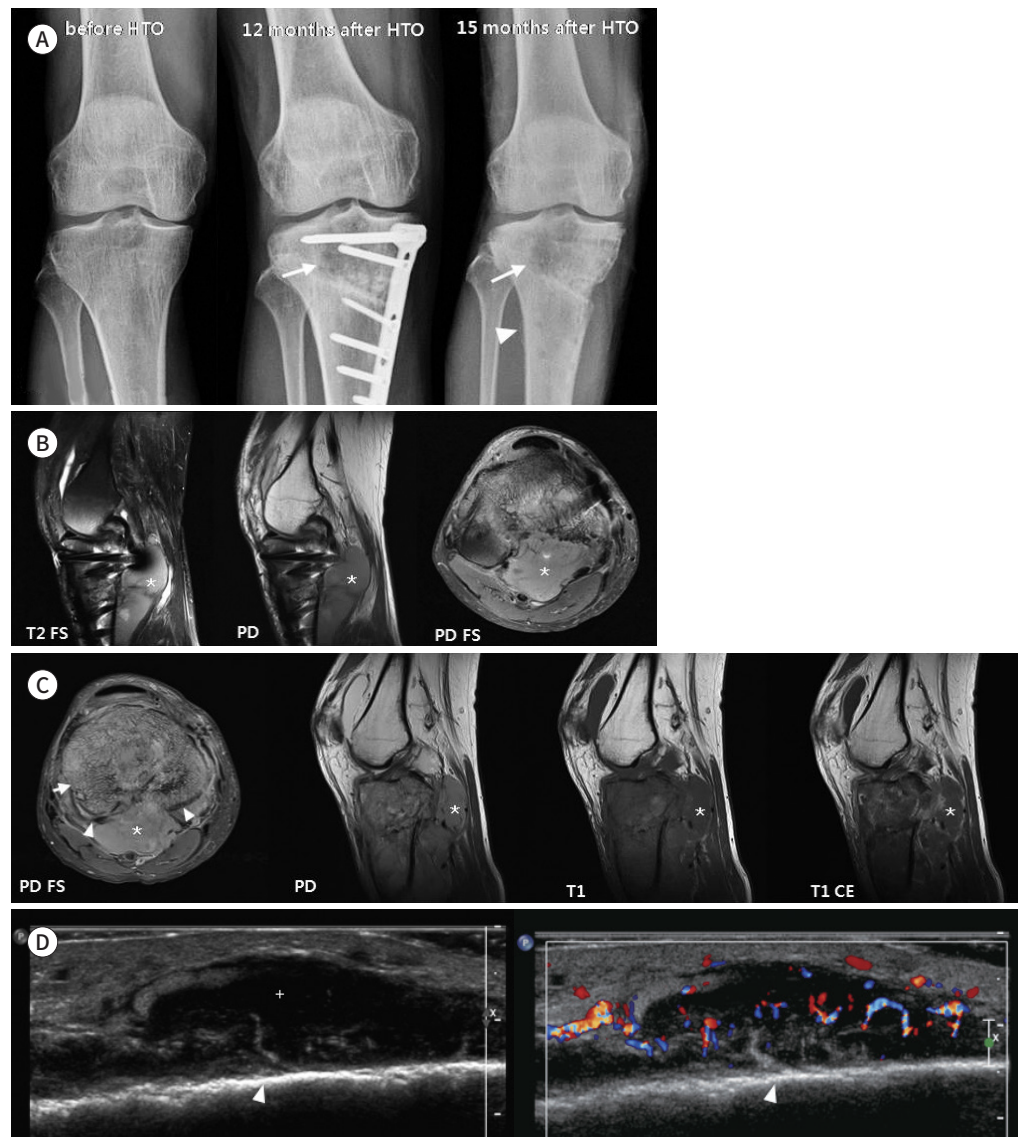
**Fig. 1.** Diffuse large B-cell lymphoma associated with a chronic inflammatory condition induced by metallic implants.

**A.** Serial right standing knee anteroposterior radiographs before HTO, 12 months, and 15 months after HTO (after HWR). Twelve months after HTO, a newly developed focal, low-density lesion (arrows) is observed in the proximal portion of the right tibia. Fifteen months after HTO, a focal, permeative-type osteolytic lesion with periosteal reaction in the distal portion is more apparent (arrowhead).

**B.** Right knee MRI scans at 14.5 months after HTO and just before HWR. An approximately 6.5 cm × 3.7 cm × 7.7 cm lesion in the right popliteal area shows homogenous high signal intensity on sagittal FS T2WI and intermediate to high signal intensity on sagittal PD and axial FS PD (\*). Evaluation of the right tibial bone marrow is limited due to metal artifacts; however, the MRI scan shows abnormal bone marrow signal intensity.

**C.** Right knee MRI scans at 15 months after HTO and 2 weeks after HWR. Diffuse marrow involvement and an approximately 7.8 cm × 3.7 cm × 9.2 cm extensive extraosseous soft-tissue mass-like lesion (\*) with a relatively preserved trabecular pattern (arrow) and bony cortex (arrowheads) is identified in the right tibia. The lesion shows intermediate signal intensity on axial FS PD and sagittal PD and iso- to slightly low signal intensity on T1WI with heterogeneous patchy enhancement on axial contrast-enhanced T1WI.

**D.** US findings after HWR at pretibial area. US shows a heterogeneous hypoechoic lesion (+) containing increased vascularity with an irregular but relatively preserved cortex of the right tibia (arrowheads) in the right pretibial area. FS = fat-suppressed, HTO = high tibial osteotomy, HWR = hardware removal operation, PD = proton density, WI = weighted imaging

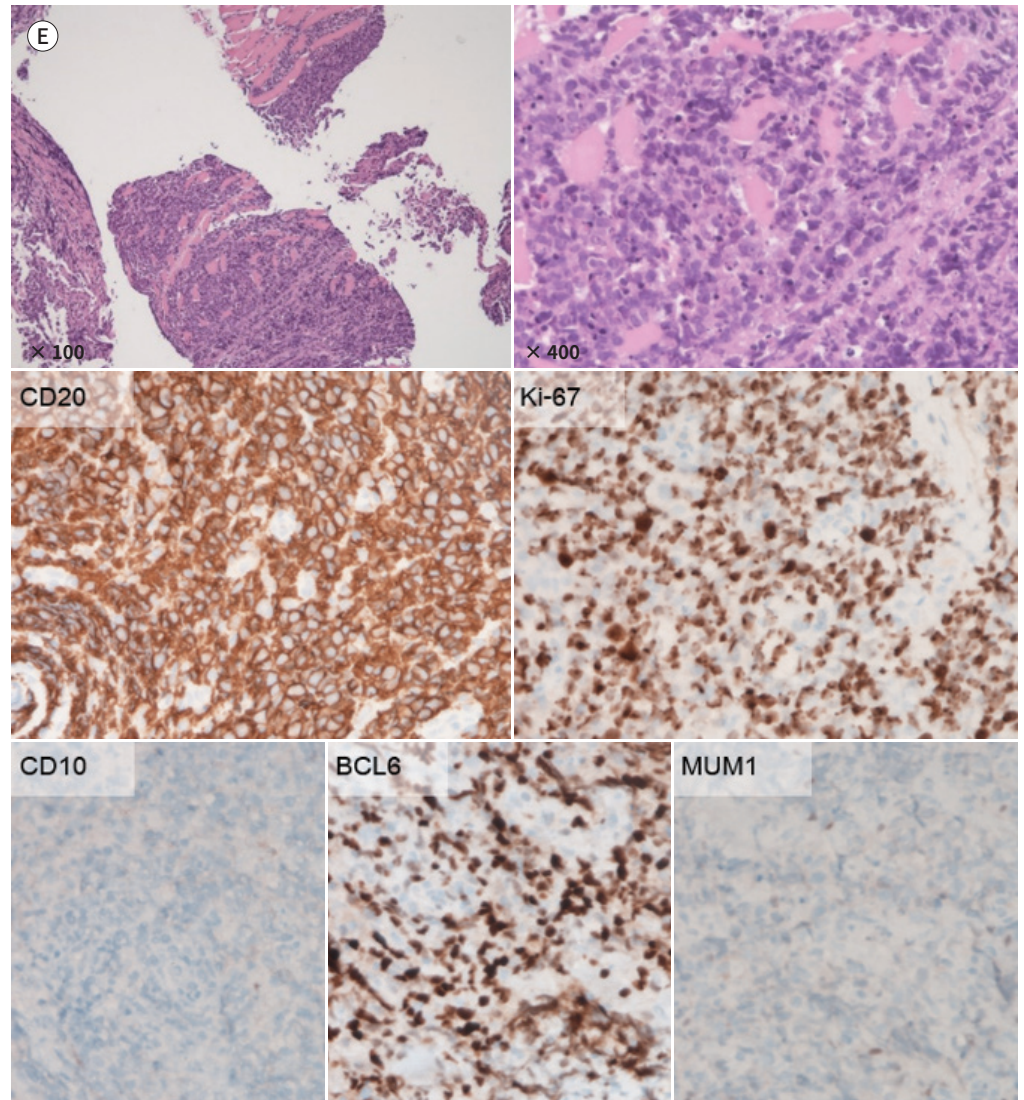




**Fig. 1.** Diffuse large B-cell lymphoma associated with a chronic inflammatory condition induced by metallic implants.

**E.** Histological and immunohistochemical analyses. The low-power magnification microphotograph of a histologic section of the neoplasm (H&E stain,  $\times 100$ ) shows infiltration of lymphoid cells into smooth muscle fibers. The high-power magnification microphotograph (H&E stain,  $\times 400$ ) shows neoplastic lymphoid cells with large vesicular nuclei containing large nucleoli and scant cytoplasm. In addition, irregular cellular membranes with no specific architecture are observed. Immunohistochemistry staining shows diffuse positivity for CD20 and 70% positivity for BCL6 but negativity for CD10 and MUM1. Ki-67 staining demonstrates a high proliferation index of 70%. These features are indicative of germinal center B cell-like diffuse large B-cell lymphoma.

H&E = hematoxylin & eosin



not CD10 or MUM1. Ki-67 staining demonstrated a high proliferation index of 70% (Fig. 1E). Subsequent CT and PET scans did not demonstrate other disease sites. In the context of metallic implants, the features were indicative of DLBCL-CI. Combined radiotherapy and immunochemotherapy with rituximab, cyclophosphamide, vincristine, doxorubicin, and prednisolone were administered.

This study was approved by the Institutional Review Board of Inje University Busan Paik

Hospital (IRB No. BPH 2020-12-035).

## DISCUSSION

Primary non-Hodgkin lymphoma of bone is uncommon, accounting for less than 5% of all extranodal non-Hodgkin lymphomas (8). Metallic implant-associated lymphoma is extremely rare (8). To our knowledge, only 14 cases of DLBCL associated with metallic implants, including our patient's case, have been reported up to 2020 (1, 3, 9). In these cases, the age at lymphoma diagnosis ranged from 25 to 85 years, and no sex bias was noted (1, 3, 9). The latency period from metallic implant placement to the diagnosis of lymphoma ranged from 14 months to 32 years (1, 3, 9). The median value of the latency period was approximately 9 years (1, 3, 9). Although no standard latency period has been identified, our patient's case was characterized by a shorter latency period (15 months). Further studies are needed to determine the specific standard interval between implant placement and the diagnosis of lymphoma.

DLBCL-CI is an Epstein-Barr virus (EBV)-associated lymphoproliferative disease arising under chronic inflammatory conditions (2). Typically, DLBCL-CI develops in a closed space and is associated with local immune dysregulation and a decreased T cell cytolytic response, which may allow EBV-transformed B cells to evade host immunological surveillance and may promote B cell proliferation, eventually leading to the development of lymphoma (2). Clinical factors related to DLBCL-CI include pyothorax, chronic osteomyelitis, metallic implants, and chronic skin ulcers (2). Many studies have explored the role of metal implants in the pathogenesis of lymphoma. Metallic debris is antigenic and associated with chronic inflammation even in the absence of infection (3, 8). Local accumulation of metallic debris can damage the cell membranes of local macrophages, causing the release of proinflammatory mediators (3, 8). Dissemination of metallic debris from implants to lymph nodes, spleen, and liver may also promote the formation of immunogenic complexes that increase the proliferation of activated T cells and B cells, cell-mediated cytotoxic reactions, and plasma cell activation (3, 8). In addition, immunosuppressive cytokines from inflammatory cells and EBV-transformed B cells contribute to lymphomagenesis (1). There are concerns regarding the possible long-term carcinogenic effect of exposure to high concentrations of metal ions. Coen et al. (4) reported that debris from a worn titanium metal produces chromosomal instability and reproductive failure in cell culture. Ladon et al. (5) reported a significant increase in both chromosome translocations and aneuploidy in peripheral blood lymphocytes from patients who received metal-on-metal hip arthroplasties. In contrast, another study reported that DNA abnormalities, such as chromosomal aberrations, may possibly be the result of a nonspecific inflammatory or foreign body response (6).

The radiologic features of metallic implant-associated DLBCL are similar to those of primary bone lymphoma (7). The radiographic features of primary bone lymphoma are variable, ranging from near-normal-appearing bone, a focal lytic lesion with geographic margins, a mixed sclerotic-lytic lesion, or a diffusely permeative process with cortical destruction and associated soft-tissue mass (7). Our case showed a focal permeative-type osteolytic lesion with periosteal reaction.

MRI plays an important role in the diagnosis of bone lymphoma, showing high sensitivity

in delineating associated soft-tissue masses and marrow replacement (7). Disproportionately extensive extraosseous soft-tissue masses and marrow involvement with only minimal cortical destruction are suggestive of round cell tumors, such as lymphoma (7). One explanation for this finding is the spread of tumor cells from the marrow through small vascular channels that run through the cortex into the surrounding soft tissue (7). Marrow involvement demonstrates low signal intensity on T1WI, and the soft tissue mass demonstrates variable signal intensity on T2WI, reflecting the degree of cellularity of the lesion (7). Contrast-enhanced images show homogeneous or heterogeneous enhancement within the bone marrow lesion and a soft-tissue mass (7). In contrast to the bone marrow component, the soft-tissue component is far more homogeneous on contrast-enhanced images (7).

Ultrasound has limited specificity to diagnose primary bone lymphoma. Its main function is to guide percutaneous biopsy of bone tumors with an associated extraosseous soft-tissue mass. Extraosseous soft-tissue masses of primary bone lymphoma show hypoechogenicity and hypervascularity with an irregular but relatively preserved bony cortex (7).

The standard treatment for DLBCL is chemotherapy combined with radiation therapy in contrast the treatment for other periprosthetic benign lesions and malignant soft tissue tumors (7). Therefore it is important to differentiate lymphomas from other periprosthetic benign lesions such as infection and hematoma and malignant soft tissue tumors such as sarcomas (10). Postoperative hematoma is an early complication and shows progressive decrease in size (10). This lesion shows variable signal intensity on T1- and T2WI according to the time and no internal contrast enhancement (10). Implant-associated infection typically exhibits bone marrow edema, cortical destruction, or inflammatory changes in adjacent soft tissues, which may mimic the radiologic features of bone tumors (10). Fluid collection with or without peripheral enhancement in soft tissues is suggestive of infection (10). Periprosthetic sarcoma demonstrates more destructive bone lesions with soft tissue masses, which show variable signal intensity on T1- and T2WI depending on the presence of hemorrhage, necrosis, or myxoid change and heterogeneous and fast contrast enhancement (7).

An increase in the number of metallic implants is expected with the current aging of our population. Therefore, it is important for surgeons and radiologists alike to be aware of the association between DLBCL and metallic implant insertions. Surgeons should have a strategy in place to screen for signs of DLBCL. Any slight change in regular imaging tests or clinical presentation, such as pain, should elicit further workup, such as MRI. If there is any suspicion of a lesion, it is better to conduct a biopsy. Therefore, with correct screening and diagnostic strategies, the diagnosis of metallic implant-associated DLBCL can be achieved earlier with higher efficacy, ultimately resulting in improved patient care and outcomes.

#### Author Contributions

Conceptualization, L.S.J.; data curation, P.J.H.; investigation, P.J.H.; project administration, all authors; resources, all authors; supervision, L.S.J.; visualization, P.J.H.; writing—original draft, P.J.H.; and writing—review & editing, L.S.J.

#### Conflicts of Interest

The authors have no potential conflicts of interest to disclose.

## Funding

None

## REFERENCES

1. Sanchez-Gonzalez B, Garcia M, Montserrat F, Sanchez M, Angona A, Solano A, et al. Diffuse large B-cell lymphoma associated with chronic inflammation in metallic implant. *J Clin Oncol* 2013;31:e148-e151
2. King RL, Goodlad JR, Calaminici M, Dotlic S, Montes-Moreno S, Oschlies I, et al. Lymphomas arising in immune-privileged sites: insights into biology, diagnosis, and pathogenesis. *Virchows Arch* 2020;476:647-665
3. Wang SJ, Cao DL, Xu HW, Zhao WD, Hu T, Wu DS. Development of primary diffuse large B-cell lymphoma around an internal fixation implant after lumbar fusion surgery: a case report and review of the literature. *World Neurosurg* 2020;137:140-145
4. Coen N, Kadhim MA, Wright EG, Case CP, Mothersill CE. Particulate debris from a titanium metal prosthesis induces genomic instability in primary human fibroblast cells. *Br J Cancer* 2003;88:548-552
5. Ladon D, Doherty A, Newson R, Turner J, Bhamra M, Case CP. Changes in metal levels and chromosome aberrations in the peripheral blood of patients after metal-on-metal hip arthroplasty. *J Arthroplasty* 2004; 19:78-83
6. Sarhadi VK, Parkkinen J, Reito A, Nieminen J, Porkka N, Wirtanen T, et al. Genetic alterations in periprosthetic soft-tissue masses from patients with metal-on-metal hip replacement. *Mutat Res* 2015;781:1-6
7. Krishnan A, Shirkhoda A, Tehranzadeh J, Armin AR, Irwin R, Les K. Primary bone lymphoma: radiographic-MR imaging correlation. *Radiographics* 2003;23:1371-1383; discussion 1384-1387
8. Cheuk W, Chan AC, Chan JK, Lau GT, Chan VN, Yiu HH. Metallic implant-associated lymphoma: a distinct subgroup of large B-cell lymphoma related to pyothorax-associated lymphoma? *Am J Surg Pathol* 2005; 29:832-836
9. Rajeev A, Ralte A, Choudhry N, Jabbar F, Banaszkiwicz P. Diffuse B cell non-Hodgkin's lymphoma presenting atypically as periprosthetic joint infection in a total hip replacement. *Case Rep Orthop* 2017;2017:7195016
10. Awan O, Chen L, Resnik CS. Imaging evaluation of complications of hip arthroplasty: review of current concepts and imaging findings. *Can Assoc Radiol J* 2013;64:306-313

## 금속성 임플란트로 인한 만성 염증 상태와 연관된 미만성 거대 B세포 림프종: 증례 보고

박진희 · 이선주\* · 추혜정

금속성 임플란트 삽입과 관련된 만성 염증 상태는 미만성 거대 B세포 림프종 발생의 위험 요소이다. 금속 이온은 림프종의 발병에 중요한 역할을 하는 것으로 알려져 있다. 저자들은 15개월 동안 근위 경골에 금속성 임플란트가 삽입된 환자에서 발생한 드문 미만성 거대 B세포 림프종 증례를 보고하고자 한다. 초음파 및 자기공명영상을 촬영하였으며 현저한 골 파괴 없이 불균형적으로 큰 골외 연조직 종괴와 골수 침범이 관찰되었다. 금속성 임플란트 삽입과 관련된 여러 합병증들이 있으며 오진하면 잘못된 치료로 이어질 수 있다. 따라서 금속성 임플란트로 인한 만성 염증 상태와 연관된 림프종과 임플란트 주위에 발생할 수 있는 다른 양성 병변 및 악성 연조직 종괴를 감별하는 것은 어렵지만 매우 중요하다.

인제대학교 의과대학 부산백병원 영상의학과