



Bladder Cancer Metastasis to the Breast in a Male Patient: Imaging Findings on Mammography and Ultrasonography

남자 환자에서 방광암의 유방 전이암:
유방촬영술 및 초음파 영상 소견

In Na Yoon, MD , Eun Suk Cha, MD* , Jeoung Hyun Kim, MD ,
Jee Eun Lee, MD , Jin Chung, MD

Department of Radiology, Ewha Womans University Mokdong Hospital, Seoul, Korea

Male breast cancer is rare, accounting for approximately 1% of breast cancers. Metastasis from extra-mammary malignancy to the breast in men is extremely rare. The most common primary tumors that metastasize to the breast in male are prostate, lung, stomach, colorectal cancer, melanoma, and sarcoma. To our knowledge, only a few cases of bladder cancer presenting with metastasis to the male breast have been reported, and metastasis with infiltration rather than mass is extremely rare. We report imaging findings on mammography and ultrasonography in a 59-year-old male with bladder cancer metastatic to the breast.

Index terms Breast Neoplasms; Urinary Bladder Neoplasms; Gynecomastia;
Neoplasm Metastasis; Ultrasonography

INTRODUCTION

Breast metastases from extra-mammary primary tumors are rare, with 1.7% to 6.6% in all breast cancers (1). The most common primary tumors that metastasize to the breast are melanoma, lymphoma, ovarian cancer, lung and neuroendocrine tumor, and sarcomas (2). Male breast cancer is rare, accounting for approximately 1% of breast cancers and metastases to male breast are extremely rare (3, 4). Primary cancers such as prostate, lung, stomach, colorectal cancer, melanoma, and sarcoma are known to metastasize to the breast in males (4).

Received April 23, 2021
Revised June 4, 2021
Accepted July 5, 2021

*Corresponding author
Eun Suk Cha, MD
Department of Radiology,
Ewha Womans University
Mokdong Hospital,
1071 Anyangcheon-ro,
Yangcheon-gu, Seoul 07985,
Korea.

Tel 82-2-2650-5977
Fax 82-2-2655-0984
E-mail escha@ewha.ac.kr

This is an Open Access article distributed under the terms of the Creative Commons Attribution Non-Commercial License (<https://creativecommons.org/licenses/by-nc/4.0>) which permits unrestricted non-commercial use, distribution, and reproduction in any medium, provided the original work is properly cited.

ORCID iDs

In Na Yoon
<https://orcid.org/0000-0002-5130-9484>
Eun Suk Cha
<https://orcid.org/0000-0001-9588-2074>
Jeoung Hyun Kim
<https://orcid.org/0000-0003-3504-9595>
Jee Eun Lee
<https://orcid.org/0000-0002-4013-2652>
Jin Chung
<https://orcid.org/0000-0001-9990-3768>

Bladder cancer is the second most common malignancy in older male, and its incidence is steadily increasing (5). However, the male breast is an uncommon site of metastasis, and cases of bladder cancer that metastasize to the male breast have rarely been reported before (5). Breast metastasis must be distinguished from primary breast cancer or common benign breast conditions such as gynecomastia. We present a case of bladder cancer metastasized to the male breast with mammographic and ultrasonographic findings.

CASE REPORT

A 59-year-old male was diagnosed with high-grade urothelial carcinoma of the urinary bladder and chest and abdominopelvic CT showed peritoneum and bone metastasis, and enlarged lymph nodes measuring 10 mm in maximum short-axis diameter in right inguinal area and left supraclavicular area, regarding as distant nodal metastasis from bladder cancer. He received six cycles of chemotherapy with gemcitabine and carboplatin. Eight months after the treatment, he visited the hospital with complaints of palpable and painful breast lumps on both sides for 2 weeks and redness of the skin on the left breast. At the time of physical examination, the redness had improved, hard masses measuring 2 cm on the right and 4 cm on the left were found, and there was no nipple discharge in both breasts. Laboratory results showed a mildly elevated C-reactive protein level of 2.03 mg/dL, which was previously normal. Hormonal status revealed slightly elevated levels of prolactin, human chorionic gonadotropin, luteinizing hormone, and thyroid-stimulating hormone, while testosterone and estradiol levels were within the normal range.

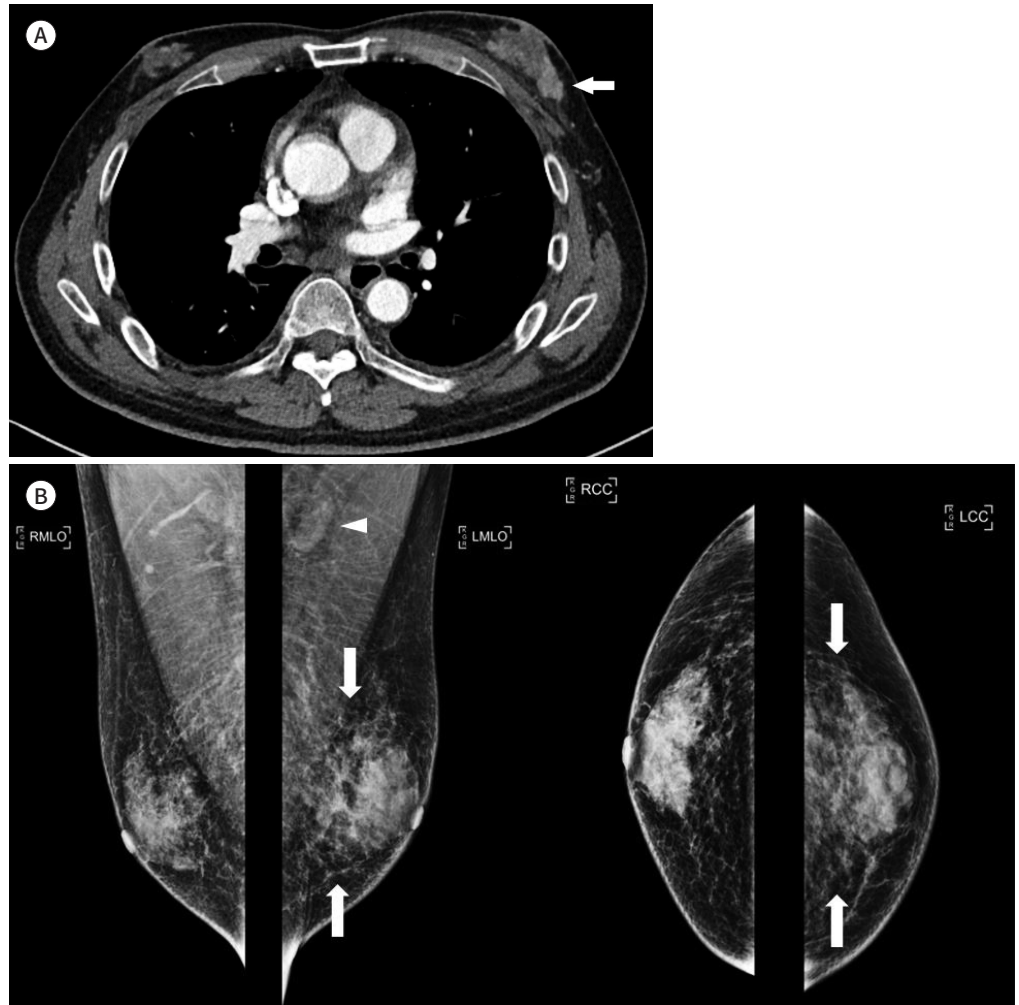
Although not shown in the figure, on follow-up chest and abdominopelvic CT for evaluating metastasis, right periureteral metastasis was newly developed and aggravation of peritoneal metastasis with increased size of metastatic lymph nodes in right inguinal area were noted. However the size of the left supraclavicular lymph node was reduced with short-axis diameter from 10 mm to 6 mm compared to initial CT. Bilateral gynecomastia, multiple enhancing lesions within the parenchyma and infiltration of subcutaneous fat in the left breast were newly detected and a few tiny enhancing lesions were also noted in the right breast on contrast enhanced chest CT (Fig. 1A). Mediolateral oblique and craniocaudal mammograms of both breasts showed bilateral diffuse gynecomastia (Fig. 1B). Focal asymmetry in the mid posterior breast, minimal skin thickening, trabecular thickening, and cortical thickening of the axillary lymph nodes in the left breast were also noted on mammography (Fig. 1B). Ultrasonography (US) revealed diffuse heterogeneous breast tissue with near 20 mm length irregular hypoechoic non-mass lesion in the left breast (at 3:30), diffuse increased echogenicity along the subcutaneous fat layer, and minimal surface skin thickening of the left breast (Fig. 1C). Focal cortical thickening of the left axillary lymph node was noted (Fig. 1C). However, no lesions were detected in the right breast except for gynecomastia (Fig. 1C). US-guided core needle biopsy was performed for the lesion in the left lower outer breast, and histologic finding was metastatic carcinoma with plasmacytoid feature from urinary bladder. Immunohistochemical studies revealed that the tumor cells were positive for GATA-3, p63, and some CK20, which are usually found in urinary bladder cancer, but negative for uroplakin III.

This study was approved by the Institutional Review Board of our institution and the re-

Fig. 1. A 59-year old male with bladder cancer metastasis to the breast.

A. Contrast-enhanced chest CT shows multiple enhancing lesions within the parenchyma with infiltration of subcutaneous fat tissue in the left breast (arrow) and a few tiny enhancing lesions in the right breast with newly developed gynecomastia in both breasts.

B. Mediolateral oblique and craniocaudal mammograms of both breasts shows bilateral diffuse gynecomastia and focal asymmetry (arrows) in the left mid-posterior breast with minimal skin thickening, trabecular thickening, and cortical thickening of the axillary lymph node (arrowhead) in the left breast.



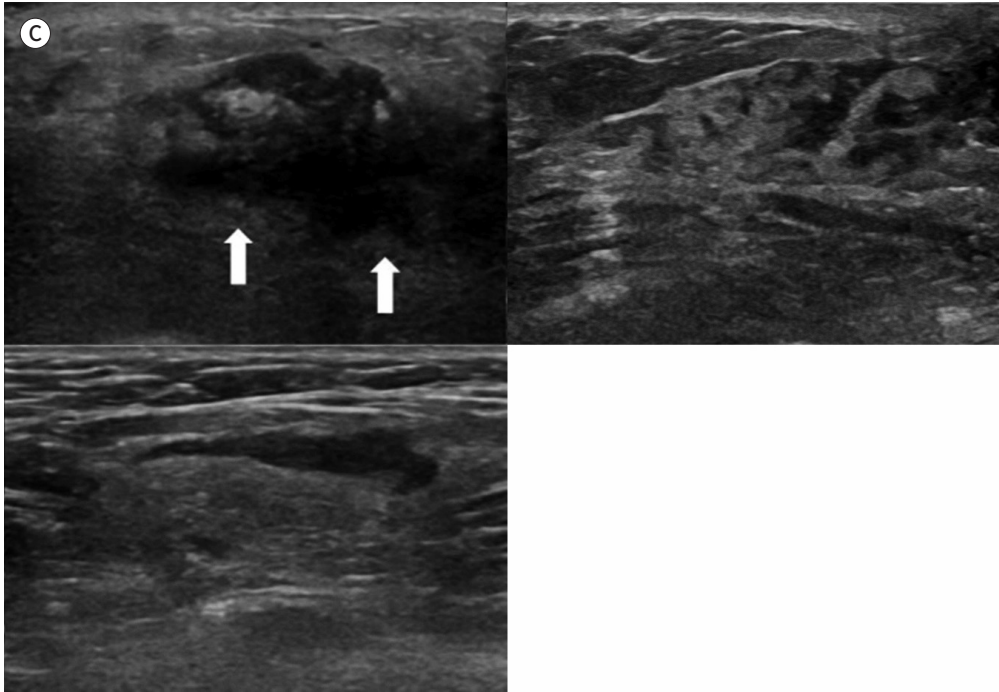
quirement for informed consent was waived (IRB No. EUMC 2021-01-001).

DISCUSSION

Breast metastases from extra-mammary malignancy are unusual, and if present, indicate widely disseminated cancer and poor prognosis (4). Immunohistochemical findings can predict aggressive characteristics, and as in our case, absent uroplakin III expression is significantly associated with advanced bladder cancer such as lymphovascular invasion, pathologic stage, and grade (5). Urinary bladder cancer metastasizes commonly to lymph nodes, liver, lung, bone, adrenal glands, intestine, and peritoneum (6). Another less common site of metastasis is the brain (6). However, metastasis to the male breast in bladder cancer is rare and

Fig. 1. A 59-year old male with bladder cancer metastasis to the breast.

C. Ultrasonography of the left breast reveals diffuse heterogeneous breast tissue with about 20 mm in length irregular hypoechoic non-mass lesion (arrows) and diffuse increased echogenicity along with the subcutaneous fat layer with minimal surface skin thickening in the lower outer breast (left upper image). Ultrasound of the right breast showed heterogeneous echogenicity of the breast parenchyma; however, no other lesions were found (right upper image). Ultrasound of the left axilla shows focal cortical thickening of the lymph node (left lower image).



it is important to detect metastatic lesions to prevent disease progression.

Mammography is the first-line imaging modality for suspicious disease in the male breast (4). On mammography, the typical imaging findings of breast metastasis are circumscribed single or multiple and round or lobulated masses, but spiculated margins and skin retraction are extremely rare, because breast metastasis causes less desmoplastic reaction (1, 4, 7). US is recommended when mammography findings are inconclusive (4). The ultrasonographic features of breast metastasis include masses with hypoechogenicity, circumscribed margins, increased internal vascularity, and posterior acoustic enhancement (1, 4, 8). Specifically, in cases of hematogenous breast metastases, the circumscribed masses are usually located in the upper outer quadrant and relatively blood-rich superficial subcutaneous tissue or breast parenchyma, while primary breast cancer tends to be unilateral lesion and glandular breast tissue involvement (1, 4, 8). In contrast, the imaging features of lymphangitic breast metastasis show diffuse heterogeneous increases in the density of subcutaneous fat and glandular tissue, with trabecular thickening, secondary skin thickening, lymphedema, and lymph node enlargement, similar to inflammatory breast cancer (1, 8). One of the US features of high-grade lymphoma in breast is bilateral diffuse parenchymal breast involvement and infiltrative pattern (8).

In our case, although it was not confirmed by pathology, distant lymph node metastasis

was estimated on the CT image and the imaging findings were similar to metastasis through lymphatic system and other infiltrative diseases such as high-grade lymphoma and mastitis, when clinical symptoms were considered. Mastitis, a benign breast inflammation, can mimic breast carcinoma both clinically and radiologically, with only a few cases reported and is extremely rare in male (4).

No clear predisposing factors associated with the development of breast metastasis have been identified (2). The role of hormones on breast metastasis is also controversial (2). However, breast metastasis is reported in puberty, pregnancy or the lactating state in female, and prostate cancer with hormone replacement therapy (2). Prostate cancer is the most common primary malignancy of breast metastasis in male (2, 6, 9). Estrogen therapy for men in prostate cancer may increase the risk of breast cancer because estrogen may increase the vascularity and stromal tissues in the breast, causing metastasis (2, 9).

In our patient, newly developed bilateral gynecomastia was observed with breast metastases, which occurred 9 months after chemotherapy for metastatic bladder cancer. Most of the breast lumps in male patients are benign, and the most common cause is gynecomastia (4). Gynecomastia is an enlargement of the male breast glandular tissue due to an imbalance between testosterone and estrogen (10). The most common cause of gynecomastia is idiopathic, but medications and medical conditions can also cause it (10). Gynecomastia is also known to occur after chemotherapy or radiation therapy, which damages the Leydig cells that produce testosterone (10). Gynecomastia can coexist with malignant tumors in 50% of cases, although the association between breast cancer and gynecomastia is unclear (3). Since cancer can be obscured by coexisting gynecomastia, a biopsy should be performed if physical examination and radiologic findings are suspicious for malignancy (3).

In summary, breast metastasis of bladder cancer in men is extremely rare, and breast metastases with infiltrative features that mimic breast high-grade lymphoma or inflammation such as mastitis are very rare. However, in the case of lymphatic spread of metastasis, image findings can be similar to that of inflammatory breast cancer. Therefore, if the imaging features of the male breast are suspicious or uncertain, tissue diagnosis through a core needle biopsy is necessary.

Author Contributions

Conceptualization, Y.I.N., C.E.S.; data curation, all authors; investigation, Y.I.N., C.E.S.; formal analysis, all authors; project administration, Y.I.N., C.E.S.; resources, Y.I.N., C.E.S.; supervision, Y.I.N., C.E.S.; visualization, all authors; writing—original draft, Y.I.N., C.E.S.; and writing—review & editing, all authors.

Conflicts of Interest

Eun Suk Cha has been a Editor Board Member of the Journal of the Korean Society of Radiology since 2008; however, she was not involved in the peer reviewer selection, evaluation, or decision process of this article. Otherwise, no other potential conflicts of interest relevant to this article were reported.

Funding

None

REFERENCES

1. Alvarado Cabrero I, Carrera Alvarez M, Pérez Montiel D, Tavassoli FA. Metastases to the breast. *Eur J Surg Oncol* 2003;29:854-855
2. Toombs BD, Kalisher L. Metastatic disease to the breast: clinical, pathologic, and radiographic features. *AJR Am J Roentgenol* 1977;129:673-676
3. Evans GF, Anthony T, Turnage RH, Schumpert TD, Levy KR, Amirkhan RH, et al. The diagnostic accuracy of mammography in the evaluation of male breast disease. *Am J Surg* 2001;181:96-100
4. Önder Ö, Azizova A, Durhan G, Elibol FD, Akpınar MG, Demirkazık F. Imaging findings and classification of the common and uncommon male breast diseases. *Insights Imaging* 2020;11:27
5. Matsumoto K, Satoh T, Irie A, Ishii J, Kuwao S, Iwamura M, et al. Loss expression of uroplakin III is associated with clinicopathologic features of aggressive bladder cancer. *Urology* 2008;72:444-449
6. Shinagare AB, Ramaiya NH, Jagannathan JP, Fennessy FM, Taplin ME, Van den Abbeele AD. Metastatic pattern of bladder cancer: correlation with the characteristics of the primary tumor. *AJR Am J Roentgenol* 2011;196:117-122
7. Bitencourt AGV, Gama RRM, Graziano L, Negrão EMS, Sabino SMPS, Watanabe AHU, et al. Breast metastases from extramammary malignancies: multimodality imaging aspects. *Br J Radiol* 2017;90:20170197
8. Mun SH, Ko EY, Han BK, Shin JH, Kim SJ, Cho EY. Breast metastases from extramammary malignancies: typical and atypical ultrasound features. *Korean J Radiol* 2014;15:20-28
9. Mandaliya H, Sung J, Hill J, Samali R, George M. Prostate cancer: cases of rare presentation and rare metastasis. *Case Rep Oncol* 2015;8:526-529
10. Niewoehner CB, Schorer AE. Gynaecomastia and breast cancer in men. *BMJ* 2008;336:709-713

남자 환자에서 방광암의 유방 전이암: 유방촬영술 및 초음파 영상 소견

윤인나 · 차은숙* · 김정현 · 이지은 · 정 진

남성 유방암은 드물며 유방암의 약 1%를 차지한다. 유방 외 악성 종양이 남성 유방으로의 전이는 매우 드물다. 남자에서 유방으로 전이되는 가장 흔한 원발성 종양은 전립선암, 폐암, 위암, 대장암, 흑색종 및 육종이다. 남자에서 방광암의 유방으로의 전이 유방암은 드물게 보고되었고, 종괴가 아닌 침윤성 소견의 전이 소견을 보이는 경우는 매우 드물다. 방광암이 유방으로 전이된 59세 남자 환자의 유방촬영술 및 초음파에서의 영상 소견을 보고하고자 한다.

이화여자대학교 목동병원 영상의학과