



Atypical Ductal Hyperplasia: Risk Factors for Predicting Pathologic Upgrade on Excisional Biopsy

침생검 조직검사에서 진단된 비정형 관상피증식증: 수술적 절제 생검에서 악성으로 진단될 가능성을 예측할 수 있는 위험인자들

Ko Woon Park, MD¹ , Boo-Kyung Han, MD^{1*} , Sun Jung Rhee, MD¹ ,
Soo Youn Cho, MD² , Eun Young Ko, MD¹ ,
Eun Sook Ko, MD¹ , Ji Soo Choi, MD¹

Departments of ¹Radiology and ²Pathology and Translational Genomics, Samsung Medical Center, Sungkyunkwan University School of Medicine, Seoul, Korea

Purpose To determine the incidence of atypical ductal hyperplasia (ADH) in needle biopsy and the upgrade rate to carcinoma, and to evaluate difference in findings between the upgrade and non-upgrade groups.

Materials and Methods Among 9660 needle biopsies performed over 48 months, we reviewed the radiologic and histopathologic findings of ADH and compared the differences in imaging findings (mammography and breast US) and biopsy methods between the upgrade and non-upgrade groups.

Results The incidence of ADH was 1.7% (169/9660). Of 112 resected cases and 30 cases followed-up for over 2 years, 35 were upgraded to carcinoma (24.6%, 35/142). The upgrade rates were significantly different according to biopsy methods: US-guided core needle biopsy (US-CNB) (40.7%, 22/54) vs. stereotactic-vacuum-assisted biopsy (S-VAB) (16.0%, 12/75) vs. US-guided VAB (US-VAB) (7.7%, 1/13) ($p = 0.002$). Multivariable analysis showed that only US-CNB (odds ratio = 5.19, 95% confidence interval: 2.16–13.95, $p < 0.001$) was an independent predictor for pathologic upgrade. There was no upgrade when a sonographic mass was biopsied by US-VAB ($n = 7$).

Conclusion The incidence of ADH was relatively low (1.7%) and the upgrade rate was 24.6%. Surgical excision should be considered because of the considerable upgrade rate, except in the case of US-VAB.

Index terms Atypical Ductal Hyperplasia; Needle Biopsy; Risk Factor

Received June 12, 2021
Revised July 28, 2021
Accepted August 16, 2021

*Corresponding author
Boo-Kyung Han, MD
Department of Radiology,
Samsung Medical Center,
Sungkyunkwan University
School of Medicine,
81 Irwon-ro, Gangnam-gu,
Seoul 06351, Korea.

Tel 82-2-3410-2518
Fax 82-2-3410-0049
E-mail bkhan@skku.edu

This is an Open Access article distributed under the terms of the Creative Commons Attribution Non-Commercial License (<https://creativecommons.org/licenses/by-nc/4.0>) which permits unrestricted non-commercial use, distribution, and reproduction in any medium, provided the original work is properly cited.

ORCID iDs

Ko Woon Park
<https://orcid.org/0000-0001-9386-5772>
Boo-Kyung Han
<https://orcid.org/0000-0003-1896-0571>
Sun Jung Rhee
<https://orcid.org/0000-0001-7788-9168>
Soo Youn Cho
<https://orcid.org/0000-0001-9714-7575>
Eun Young Ko
<https://orcid.org/0000-0001-6679-9650>
Eun Sook Ko
<https://orcid.org/0000-0002-0399-7956>
Ji Soo Choi
<https://orcid.org/0000-0003-1361-5269>

INTRODUCTION

Atypical ductal hyperplasia (ADH) is a representative breast lesion associated with increased breast cancer risk and is classified as lesion of uncertain malignant potential (B3 lesions) by the B-coding system employed by the National Health Service Breast Cancer Screening program (1). It is defined by involvement of no more than one terminal ductal lobular unit or low-grade intraductal proliferation with a maximum size of 2 mm and failure to meet all the criteria for low-grade ductal carcinoma in situ (DCIS) (2). With increased use of mammographic screening and percutaneous needle biopsy of screening-detected lesions, the incidence of ADH is reported to be approximately 1%–9% of all needle biopsies (3-5). In clinical practice, use of core needle biopsy (CNB) and vacuum-assisted biopsy (VAB) before surgery has replaced surgical breast biopsy, and debate on B3 lesion management is centered on the concept of upgrade rate, that is the rate of percutaneously diagnosed lesions that, after surgical excision or during active imaging surveillance, result in a diagnosis of DCIS or invasive cancer (6-8). The pathologic upgrade rate of ADH to cancer at surgical excision ranges from 7% to 45.8% of all cases (2, 9-15). The reported upgrade rate is 9% (95% confidence interval [CI]: 7%, 11%) for IDC and 20% (95% CI: 18%, 23%) for DCIS on surgical excision (16).

There has been increasing debate over whether all ADH lesions should be treated surgically or should undergo only follow-up after a lesion has been removed by VAB (16-18). Thus, recent research efforts have attempted to identify the factors associated with a low risk of cancer upgrade to select female who could avoid surgical excision with a minimal risk of harboring malignant foci (19, 20). Several pathologic predictors of ADH upgrade have been suggested, including a larger extent of ADH (9, 15) and presence of necrosis (20, 21) and microcalcifications (22). Other studies have shown similar high-risk radiologic upgrade criteria, including larger lesion size and a smaller percentage of lesion removed at biopsy (12, 23). Many results to date have primarily reported lesions found in mammographic screening, but there have been few reports of ADH incidence or following the pathologic outcome of needle biopsies of lesions found in mammography and US combined screening. Many countries in Asia use combined mammography and US screening due to the high proportion of dense breasts. In general, when US screening is added, needle biopsy procedures increase, so the incidence and outcome of certain lesions including ADH may be affected.

Considering the purpose of needle biopsy is to identify malignant lesions without a delay, encountering an ADH case is a matter of concern to clinicians and radiologists. For timely diagnosis, it is crucial to select the most appropriate needle and biopsy method for imaging-detected lesion. In addition, if we can determine a group that can avoid diagnostic surgery following ADH biopsy result, we may reduce the number of unnecessary diagnostic surgeries, which often cause patients' anxiety and result in a large incision scar.

Therefore, the goal of this study was 1) to quantify the incidence of ADH in needle biopsy and the rate of ADH upgrade to carcinoma in a single institution, 2) to investigate the differences between a pathologic upgrade group and a non-upgrade group according to clinicopathologic and radiologic features, and 3) to identify characteristics that help identify which patients with ADH on CNB could safely avoid surgical excision.

MATERIALS AND METHODS

STUDY POPULATION

Approval was obtained by the Institutional Review Board for this retrospective study, and the requirement of informed consent was waived (IRB No. 2020-04-062-001).

We reviewed US-guided and stereotactic-guided breast needle biopsy cases between February 2013 and December 2016. Of the 9660 needle biopsies, there were 8208 cases of automated Tru-cut CNBs and 1452 VABs. We searched ADH diagnoses resulting from needle biopsy histology. Patient age, biopsy method (US-CNB, US-VAB, or stereotactic-VAB [S-VAB]), needle biopsy histology, and subsequent surgical pathologic results were recorded. Decisions were made regarding excision vs. follow up based on patient's clinical presentation (screening, symptomatic work up or known breast cancer), comorbidity, adequacy of sampling, lesion size, and level of radiological suspicion (24). The representative imaging findings and Breast Imaging Reporting and Data System (BI-RADS) categories were reviewed through an analysis of imaging findings and radiologic reports.

MAMMOGRAPHY AND BREAST US EXAMINATION

All ADH cases had both mammography and breast US before the needle biopsy. All mammograms were obtained with dedicated equipment (Senographe 2000D or 2000DS, GE Medical Systems, Milwaukee, WI, USA; Selenia Dimensions, Hologic Inc., Bedford, MA, USA). Standard cranio-caudal and mediolateral oblique views were routinely obtained, and additional magnification views were obtained as needed. Breast US examinations were performed using an IU22 machine with a 12–5 MHz linear array transducer (Philips Advanced Technology Laboratories, Bothell, WA, USA) or an Aixplorer machine with a 15–4 MHz linear array transducer (SuperSonic Imagine, Aix en Provence, France). Most of the ADH lesions were detected during combined mammographic and US screening for breast cancer or during breast imaging studies in symptomatic patients, and some lesions were secondarily discovered during staging work up in breast cancer patients.

Two radiologists who had 8–26 years of experience in breast imaging, retrospectively evaluated the mammography and US findings and categorized the lesion types as mammographic calcification (without a distinct sonographic mass), mass(es) on US, or non-mass lesion on US according to the representative findings on mammography and US. When mammographic calcifications were associated with nonspecific parenchymal change including cysts on US, lesion type was categorized as calcification. Even when non-mass lesions on US had mammographic calcifications, if the calcifications were a few and nonspecific, the lesions were categorized as non-mass lesions on US. We recorded the BI-RADS category assigned at the time of biopsy from category 3 to 5 in keeping with BI-RADS atlas's definition. The estimated malignancy rate was 1%–2% in BI-RADS category 3 (probably benign), 3%–10% in category 4A (low suspicion for malignancy), 11%–50% in category 4B (moderate suspicion for malignancy), 51%–95% in category 4C (high suspicion for malignancy), and > 95% in category 5 (highly suggestive of malignancy) (25). We measured the largest lesion size on the one of two imaging modalities in which the dominant findings were clearly visible.

BIOPSY PROCEDURE

All needle biopsies were performed by imaging guidance by 1 of 8 radiologists with 1–26 years of breast imaging experience. US-guided CNB was performed using a 14G Tru-cut needle with a 22 mm throw (ACECUT, TSK Laboratory, Tokyo, Japan), and a minimum of four cores was obtained from each lesion. VAB was performed when a large number of specimens was needed for accurate diagnosis. US-guided VAB was performed using an 8–11G vacuum-assisted probe (Mammotome, Devicor Endo-Surgery, Cincinnati, OH, USA; Suros, Hologic Inc. Bedford, MA, USA). S-VAB was performed for microcalcifications that were invisible on US with an 11G vacuum-assisted probe (Mammotome, Devicor Endo-Surgery, Cincinnati, OH, USA) using the stereotactic unit of a prone table (Lorad, Hologic Inc., Danbury, CT, USA).

STATISTICAL ANALYSIS

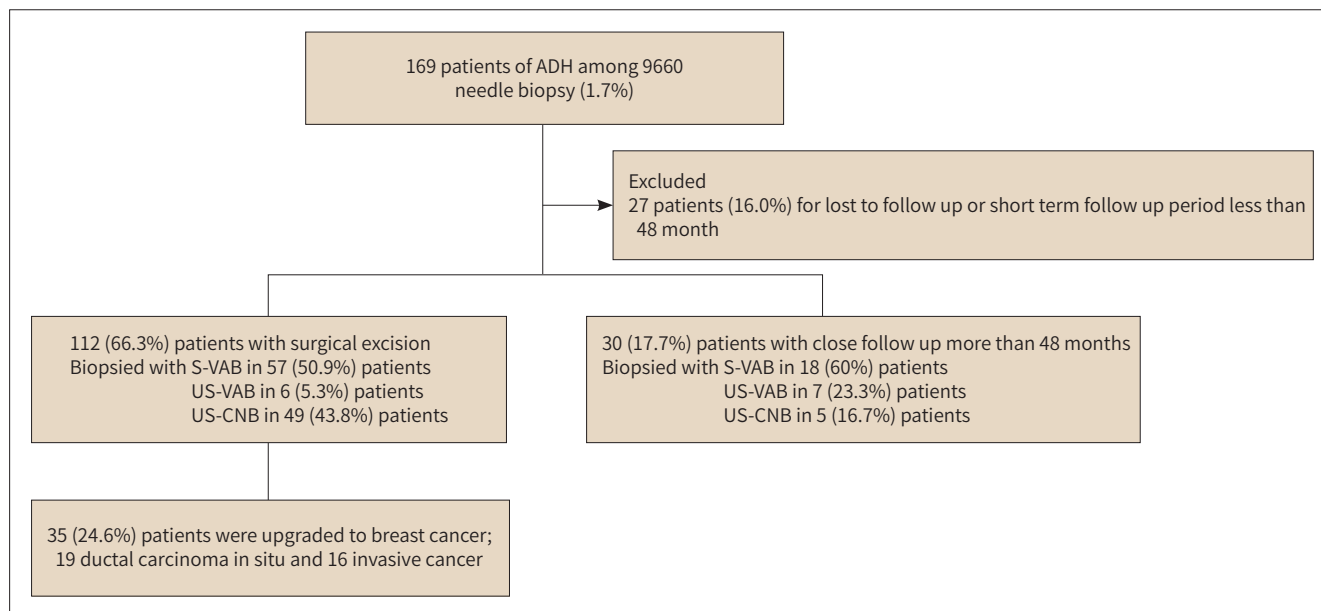
The continuous predictor variables, such as patient age and lesion size, were assessed using the Wilcoxon rank sum test for comparisons between the upgrade and non-upgrade groups. We used Fisher's exact test and the chi-square test to examine the significance of the association between upgrade and lesion type, biopsy method, biopsy guidance, and BI-RADS category. Exact logistic regression was performed with the malignant outcomes of each lesion as the dependent variables. Adjusted odds ratios (ORs), 95% CIs, and exact *p* values were reported for the multivariable results. A univariable analysis was performed to compare the variables for predictors of pathologic upgrade, and variables with *p* values less than 0.2 (categorical variables based on type 3 *p* values) according to a univariable analysis were included in the multivariable analysis (26). Linear logistic regression test was performed for evaluating differences of all variables between invasive cancer and DCIS. A *p* value less than 0.05 was regarded as statistically significant. The data analyses were conducted using the SAS software, version 9.4 (SAS Institute Inc., Cary, NC, USA).

RESULTS

Among 9660 needle biopsies, pathologic analysis revealed 169 patients of ADH (1.7%). Subsequent surgical excision was performed in 112 patients, and 30 patients were followed up closely (stable for 56–70 months). The remaining 27 patients were excluded due to follow up loss or short term follow up period (less than 48 months). Finally, 142 patients were included. Of the 112 surgically resected cases and 30 followed up cases, 35 (24.6%) were upgraded to breast carcinoma (15 invasive ductal carcinomas, one mucinous carcinoma, and 19 DCIS). Ten were symptomatic patients and 132 were asymptomatic. Asymptomatic image-detected lesions were detected mammographically in 79 patients, sonographically in 47 patients, and via MRI in six patients. These six patients were diagnosed by staging work-up for breast cancer and biopsies were performed by US-guidance after second look US. Among the 30 followed up patients, 18 were biopsied with S-VAB with complete removal of visible calcifications, seven with US-VAB with complete removal of mass on US, and only five with US-CNB with BI-RAD 4A categorical assessment (Fig. 1).

The factors associated with ADH upgrade rate are demonstrated in Table 1. There was no significant difference in patient age between the upgrade and non-upgrade groups (47.8 ± 9.03

Fig. 1. Flow chart of results of patients who underwent needle biopsy in the 9660 cases.



ADH = atypical ductal hyperplasia, CNB = core needle biopsy, S-VAB = stereotactic-VAB, VAB = vacuum-assisted biopsy

years; 47.0 ± 7.34 years, mean \pm standard deviation [SD], $p = 0.936$). The mean lesion size of the upgrade group was significantly larger than that of the non-upgrade group (2.3 ± 1.81 ; $1.7 \text{ cm} \pm 1.73$, mean \pm SD, $p = 0.035$). The upgrade rates were significantly different according to biopsy method and biopsy guidance: US-CNB using a 14G needle (40.7%, 22/54) vs. S-VAB (16.0%, 12/75) vs. US-VAB (7.7%, 1/13) using 8–11G needle ($p = 0.002$) and US-guidance (34.3%, 23/67) vs. stereotactic guidance (16.0%, 12/75) ($p = 0.020$). Although the upgrade rate was lowest in mammographic calcifications (19.8%, 18/91), there was no significant difference in upgrade rate according to lesion type ($p = 0.107$). ADH was discovered most frequently when mammographic calcifications that were nonvisible or inconspicuous on US were subject to S-VAB in our study. There was no significant difference in upgrade rate according to biopsy method customized to lesion type. The upgrade rate was highest in US-CNB for calcifications (50.0%, 5/10), but there was no significant difference according to lesion type ($p = 0.236$). There was no upgrade when a US mass was biopsied by US-VAB (0%, 0/7). In most cases (84.5%, 120/142), the BI-RADS category of the target lesion was 4A (57.7%, 82/142) or 4B (26.8%, 38/142). There was no significant difference in upgrade rate according to BI-RADS category ($p = 0.060$), although the BI-RADS 4B category showed the highest (39.5%, 15/38) upgrade rate.

In univariable analysis (Table 2), biopsy method (US-CNB, $p = 0.002$) and lesion type (non-mass lesion on US, $p = 0.045$) showed statistical significance. BI-RADS category ($p = 0.045$) and lesion size ($p = 0.086$) showed p values less than 0.2 (categorical variables based on type 3 p values). Therefore, these four variables were included in the multivariable analysis. For VAB, there was no significant difference in upgrade rate between US-VAB and S-VAB, OR 0.44, 95% CI: 0.05–3.69 ($p = 0.447$). Only biopsy method was a significant risk factor in the multivariable analysis when these three variables were used (Table 3): US-CNB vs. S-VAB, OR 5.49, CI 2.16–13.95 ($p < 0.001$) (Figs. 2, 3).

Table 1. Factors associated with Pathologic Upgrade Rate of Atypical Ductal Hyperplasia

Variable	n = 142 (%)	Upgrade Group (n = 35, 24.6%)	Non-Upgrade Group (n = 107, 75.4%)	Upgrade Rate (%)	p-Value
Patient age, mean ± SD		47.8 ± 9.03	47.0 ± 7.34	24.6	0.936
Target lesion size, cm, mean ± SD	2.1 ± 1.86	2.3 ± 1.81	1.7 ± 1.73	24.6	0.035
Biopsy method					0.002
S-VAB	75 (52.8)	12	63	16.0	
US-CNB	54 (38.0)	22	32	40.7	
US-VAB	13 (9.2)	1	12	7.7	
Biopsy guidance					0.020
Stereotactic guidance	75 (52.8)	12	63	16.0	
US guidance	67 (47.2)	23	44	34.3	
BI-RADS category					
3	14 (9.9)	1	13	7.1	0.060
4A	82 (57.7)	18	64	22.0	
4B	38 (26.8)	15	23	39.5	
4C	8 (5.6)	1	7	12.5	
Target lesion type					0.107
Mammographic calcification	91 (64.1)	18	73	19.8	
Mass on US	38 (26.8)	11	27	28.9	
Non-mass lesion on US	13 (9.1)	6	7	46.2	
Biopsy method/target lesion type					0.236
S-VAB for calcification	75 (52.8)	12	63	16.0	
US-CNB for mass	31 (21.8)	11	20	35.5	
US-CNB for non-mass lesion	13 (9.2)	6	7	46.2	
US-CNB for calcification	10 (7.1)	5	5	50.0	
US-VAB for calcification	6 (4.2)	1	5	16.7	
US-VAB for mass	7 (4.9)	0	7	0	
US-VAB for non-mass lesion	0 (0)	NA	NA	NA	

BI-RADS = Breast Imaging Reporting and Data System, CNB = core needle biopsy, NA = not available, SD = standard deviation, S-VAB = stereotactic-VAB, VAB = vacuum-assisted biopsy

Table 4 shows the pathologic findings of breast cancer in the upgrade group ($n = 35$). All 35 upgrade cases were T0 or T1 stage (< 2 cm) and consisted of 19 DCIS cases, 15 invasive ductal carcinoma cases, and one mucinous carcinoma. Axillary surgery was performed in 19 (54.3%) cases, and there was no regional lymph node metastasis. Only one of 16 invasive cancer cases (6.3%) had high nuclear grade. The majority of upgrade cases (87.5%, 14/16) was hormone receptor positive. Linear logistic regression test showed no significant differences between invasive cancer ($n = 16$) and DCIS ($n = 19$) according to all variables ($p > 0.05$).

DISCUSSION

In our study, the incidence of ADH in breast needle biopsy (1.7%) was relatively low, and asymptomatic presentation was much more common than symptomatic cases. The upgrade rate (24.6%) was similar to that reported in earlier studies (16, 27, 28) but considerable when

Table 2. Univariable Analysis of Risk Factors for Pathologic Upgrade of Atypical Ductal Hyperplasia to Malignancy Outcome ($n = 142$)

Variable	Odds Ratio (95% CI)	Pearson Chi Square	Type 3 p -Value*
Biopsy method			
S-VAB	1		0.002
US-CNB	3.61 (1.59–8.21)	0.002	
US-VAB	0.44 (0.05–3.69)	0.447	
Biopsy guidance			
US guidance	1	0.013	
Stereotactic guidance	0.36 (0.16–0.81)		
BI-RADS category			
4A	1		0.045
3	0.27 (0.03–2.23)	0.226	
4B	2.32 (1.01–5.34)	0.048	
4C	0.51 (0.06–4.40)	0.539	
Lesion size			
Mean lesion size	1.19 (0.98–1.46)	0.086	
Mammographic calcification	1		
Lesion type			
Mass on US	1.63 (0.68–3.89)	0.272	0.118
Non-mass lesion on US	3.43 (1.03–11.46)	0.045	

*Type 3 p values are used to identify the effects of categorical variables.

BI-RADS = Breast Imaging Reporting and Data System, CI = confidence interval, CNB = core needle biopsy, S-VAB = stereotactic-VAB, VAB = vacuum-assisted biopsy

Table 3. Multivariable Analysis of Risk Factors for Pathologic Upgrade of Atypical Ductal Hyperplasia to Malignancy Outcome ($n = 112$)

Variable	Odds Ratio (95% CI)	Pearson Chi Square	Type 3 p -Value
Biopsy method			
S-VAB	1		
US-CNB	5.49 (2.16–13.95)	< 0.001	< 0.001
US-VAB	0.65 (0.07–5.90)	0.698	
BI-RADS category			
4A	1		0.063
3	0.24 (0.03–2.14)	0.203	
4B	2.42 (0.91–6.47)	0.078	
4C	0.52 (0.05–5.01)	0.569	
Lesion size			
Mean lesion size	1.24 (0.97–1.59)	0.084	
Mammographic calcification	1		
Lesion type			
Mass on US	0.83 (0.19–3.61)	0.809	
Non-mass lesion on US	0.68 (0.12–3.80)	0.655	

Odds ratios (95% CIs) were determined with multivariable analysis (variables with p values < 0.2) of variables according to univariable analysis.

BI-RADS = Breast Imaging Reporting and Data System, CI = confidence interval, CNB = core needle biopsy, S-VAB = stereotactic-VAB, VAB = vacuum-assisted biopsy

compared to other studies (7.0%–45.8%) (2-5, 9-16). The strongest risk factor for ADH upgrade was the biopsy method (US-CNB vs. S-VAB, $p < 0.001$), possibly due to the different amounts of target lesion removed between CNB and VAB. This result was similar to that of Rageth et al. (29). Although there was no difference according to lesion type, calcification was the most com-

Fig. 2. A 68-year-old female diagnosed with ADH by US-CNB using a 14G needle.

A. Longitudinal B-mode US image shows a 0.6 cm ill-defined oval hypoechoic mass (arrows) in the right breast at the 9 o'clock position. The Breast Imaging Reporting and Data System category was assessed as 4A by radiologists.

B. US-CNB using a 14G needle reveals focal ADH. This small mass lesion on US was upgraded to ductal carcinoma in situ with an intermediate nuclear grade after surgical excision.

ADH = atypical ductal hyperplasia, CNB = core needle biopsy

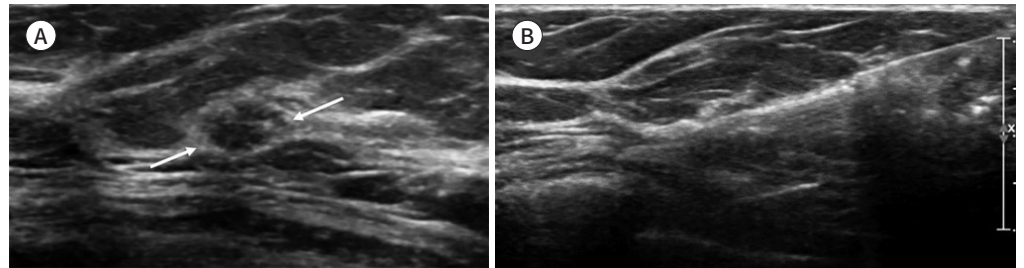


Fig. 3. A 48-year-old female diagnosed with ADH by S-VAB using an 11G needle.

A. Mediolateral oblique mammography image shows 8 cm segmental fine pleomorphic microcalcifications (arrows).

B. S-VAB was performed targeting suspicious calcifications. Subsequent surgical excision was performed with mammography-guided needle localization. The pathologic result is multifocal ADH. This calcification-dominant lesion on mammography was assessed as Breast Imaging Reporting and Data System category 4C by radiologists, but it was not upgraded after surgical excision.

ADH = atypical ductal hyperplasia, S-VAB = stereotactic-vacuum-assisted biopsy

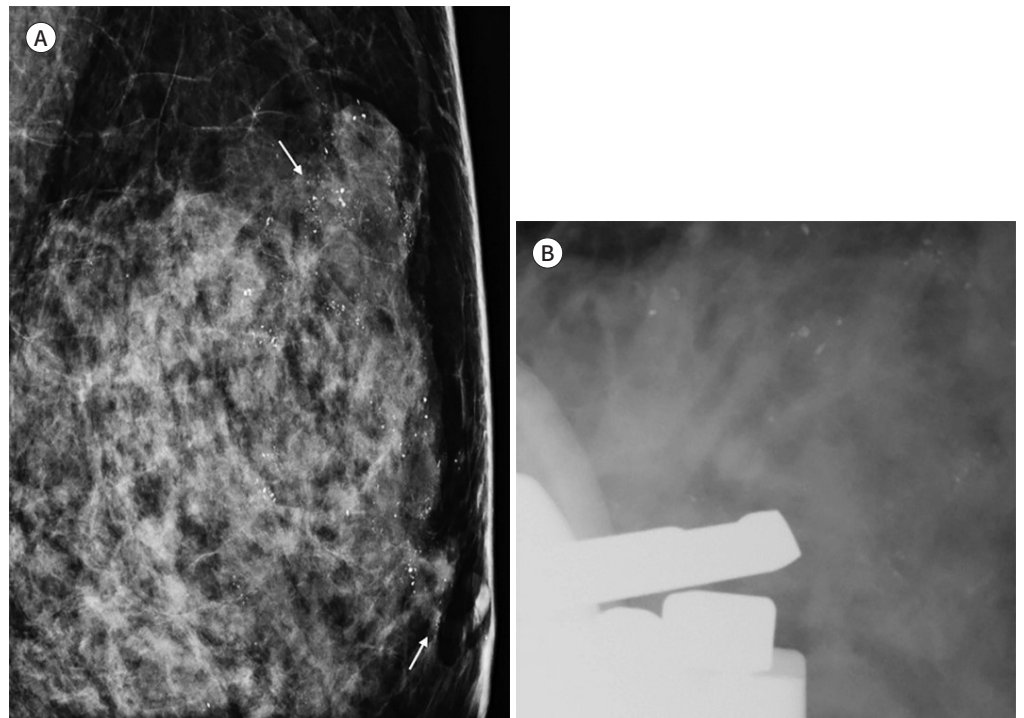


Table 4. Histopathologic Results of Breast Cancer in the Upgrade Group ($n = 35$)

Variable	No. of Patients (%)
N stage	
N0*	19 (100)
T stage	
DCIS	19 (54.3)
Invasive carcinoma [†]	16 (45.7)
Tumor stage	
T1mic	2 (5.7)
T1a	4 (11.4)
T1b	2 (5.7)
T1c	8 (22.9)
Nuclear grade	
Low	6 (37.5)
Intermediate	9 (56.2)
High	1 (6.3)
Tumor subtype	
HR-positive	14 (87.4)
HER 2-enriched	1 (6.3)
TNBC	1 (6.3)

T1mic: microinvasion ≤ 0.1 cm, T1a: tumor > 0.1 to ≤ 0.5 cm, T1b: tumor > 0.5 to ≤ 1 cm, T1c: tumor > 1 to ≤ 2 cm.

*Axillary surgery was only performed in 19 cases.

[†] One was mucinous carcinoma.

DCIS = ductal carcinoma in situ, HER 2 = human epidermal growth factor receptor 2, HR = hormone receptor (estrogen or progesterone receptor), TNBC = triple negative breast cancer

mon presentation of ADH (64.1%, 91/142) in our study, and it could only be seen on mammography. Hence, S-VAB seems to have the lowest upgrade rate and may provide further evidence that ADH without associated calcifications requires further diagnostic steps, especially in patients diagnosed using CNB. Considering the guidance method, VAB with US-guidance is often aimed at achieving total removal of all imaging evidence on US. We believe this is because even though the numbers are small ($n = 7$), our study showed no pathologic upgrade when the mass on US was biopsied by US-VAB. Similarly, despite a lack of statistical significance, the upgrade rate of non-mass lesions was relatively high as 46.2% (6/13), which may be caused by the fact that all non-mass lesions were biopsied by US-CNB in our study.

As in previous reports, neither the mammographic and sonographic findings nor the final BI-RADS category were able to predict malignancy. Chae et al. (30) showed that a combined mass with microcalcifications on US was a predictive factor for breast cancer only in univariable analysis. Moreover, Mesurolle et al. (31) reported that upgrades could not be predicted using mammographic and sonographic BI-RADS features or a final BI-RADS category. Therefore, we believe that the decision of whether or not to perform surgical excision should primarily consider the biopsy method.

Although a recent study (17) justified conservative management in a selective group of patients without residual microcalcifications after S-VAB, showing a malignancy rate lower

than 2%, our results showed a considerable upgrade rate (16.0% by S-VAB). Moreover, the upgrade rate of US-VAB was 7.7% in our case. We also found no upgrade when mass lesions on US were removed by US-VAB, although the number of lesions was small ($n = 7$). Therefore, we suggest that surgical excision should be considered because of the significant upgrade rate, except for the case of US-VAB for mass lesions. In line with our suggestion, the Second International Consensus Conference recommended that a lesion containing ADH diagnosed by CNB or VAB should undergo open surgical excision. Surveillance can be justified only in special situations after discussion at the multidisciplinary meeting (32). These recommendations were somewhat different from those of the First International Consensus Conference, in which 42% of all voting participants (27 radiologists, 2 pathologists, 2 surgeons, and 16 gynecologists) thought that surveillance was adequate for ADHs diagnosed by VAB (18).

As we have seen so far, current approaches toward better management of ADH are diverse given the potential distance between B3 lesions and associated DCIS or invasive cancer (8). Further research integrating various radiologic and clinicopathologic findings with artificial intelligence models, including machine learning, could lead to precision decision-making, reducing overtreatment.

This study has a few limitations. First, it is a single-center retrospective study that may have selection bias, and our institution is a referral center that may consequently have a lower proportion of B3 lesions including ADH than at other medical centers. Second, the upgrade rate may have been different because we included a smaller proportion of follow-up patients than surgically resected patients considering the slow natural course of DCIS. It seems difficult to conclude that there was no upgrade even if the lesions were stable for a follow-up period. Future studies with similar proportions of patients with sufficient follow-up for more than two years and surgical excision may show a more reliable upgrade rate. Another limitation was the relatively small numbers of samples and variables, especially pathological variables. Further research should consider a large number of variables, including clinicopathological and radiological variables.

In conclusion, the incidence of ADH in breast needle biopsies was low (1.7%) in our institution. Surgical excision should be considered because of the significant upgrade rate, except for the case of US-VAB for mass.

Author Contributions

Conceptualization, H.B.; data curation, P.K.W., R.S.J., H.B., K.E.S., K.E.Y., C.J.S.; formal analysis, P.K.W., R.S.J., H.B.; investigation, P.K.W., R.S.J.; methodology, H.B., K.E.Y.; project administration, H.B.; resources, H.B.; software, P.K.W., supervision, H.B., C.S.Y.; validation, H.B.; visualization, P.K.W., R.S.J.; writing—original draft, P.K.W., H.B.; and writing—review & editing, P.K.W., H.B.

Conflicts of Interest

The authors have no potential conflicts of interest to disclose.

Funding

None

REFERENCES

1. Ellis IO, Humphreys S, Michell M, Pinder SE, Wells CA, Zakhour HD. Best practice no 179. Guidelines for

- breast needle core biopsy handling and reporting in breast screening assessment. *J Clin Pathol* 2004;57:897-902
2. Allison KH, Eby PR, Kohr J, DeMartini WB, Lehman CD. Atypical ductal hyperplasia on vacuum-assisted breast biopsy: suspicion for ductal carcinoma in situ can stratify patients at high risk for upgrade. *Hum Pathol* 2011;42:41-50
 3. Acheson MB, Patton RG, Howisey RL, Lane RF, Morgan A. Histologic correlation of image-guided core biopsy with excisional biopsy of nonpalpable breast lesions. *Arch Surg* 1997;132:815-818; discussion 819-821
 4. Liberman L, Cohen MA, Dershaw DD, Abramson AF, Hann LE, Rosen PP. Atypical ductal hyperplasia diagnosed at stereotaxic core biopsy of breast lesions: an indication for surgical biopsy. *AJR Am J Roentgenol* 1995;164:1111-1113
 5. Lin PH, Clyde JC, Bates DM, Garcia JM, Matsumoto GH, Girvin GW. Accuracy of stereotactic core-needle breast biopsy in atypical ductal hyperplasia. *Am J Surg* 1998;175:380-382
 6. Brem RF. Management of breast atypical ductal hyperplasia: now and the future. *Radiology* 2020;294:87-88
 7. Forester ND, Lowes S, Mitchell E, Twiddy M. High risk (B3) breast lesions: what is the incidence of malignancy for individual lesion subtypes? A systematic review and meta-analysis. *Eur J Surg Oncol* 2019;45:519-527
 8. Sharma N, Wilkinson LS, Pinder SE. The B3 conundrum-the radiologists' perspective. *Br J Radiol* 2017;90:20160595
 9. Wagoner MJ, Laronga C, Acs G. Extent and histologic pattern of atypical ductal hyperplasia present on core needle biopsy specimens of the breast can predict ductal carcinoma in situ in subsequent excision. *Am J Clin Pathol* 2009;131:112-121
 10. Degnim AC, King TA. Surgical management of high-risk breast lesions. *Surg Clin North Am* 2013;93:329-340
 11. Ely KA, Carter BA, Jensen RA, Simpson JF, Page DL. Core biopsy of the breast with atypical ductal hyperplasia: a probabilistic approach to reporting. *Am J Surg Pathol* 2001;25:1017-1021
 12. Forgeard C, Benchaib M, Guerin N, Thiesse P, Mignotte H, Faure C, et al. Is surgical biopsy mandatory in case of atypical ductal hyperplasia on 11-gauge core needle biopsy? A retrospective study of 300 patients. *Am J Surg* 2008;196:339-345
 13. Kim J, Han W, Go EY, Moon HG, Ahn SK, Shin HC, et al. Validation of a scoring system for predicting malignancy in patients diagnosed with atypical ductal hyperplasia using an ultrasound-guided core needle biopsy. *J Breast Cancer* 2012;15:407-411
 14. Ko E, Han W, Lee JW, Cho J, Kim EK, Jung SY, et al. Scoring system for predicting malignancy in patients diagnosed with atypical ductal hyperplasia at ultrasound-guided core needle biopsy. *Breast Cancer Res Treat* 2008;112:189-195
 15. Sneige N, Lim SC, Whitman GJ, Krishnamurthy S, Sahin AA, Smith TL, et al. Atypical ductal hyperplasia diagnosis by directional vacuum-assisted stereotactic biopsy of breast microcalcifications. Considerations for surgical excision. *Am J Clin Pathol* 2003;119:248-253
 16. Schiaffino S, Calabrese M, Melani EF, Trimboli RM, Cozzi A, Carbonaro LA, et al. Upgrade rate of percutaneously diagnosed pure atypical ductal hyperplasia: systematic review and meta-analysis of 6458 lesions. *Radiology* 2020;294:76-86
 17. Schiaffino S, Massone E, Gristina L, Fregatti P, Rescinito G, Villa A, et al. Vacuum assisted breast biopsy (VAB) excision of subcentimeter microcalcifications as an alternative to open biopsy for atypical ductal hyperplasia. *Br J Radiol* 2018;91:20180003
 18. Rageth CJ, O'Flynn EA, Comstock C, Kurtz C, Kubik R, Madjar H, et al. First International Consensus Conference on lesions of uncertain malignant potential in the breast (B3 lesions). *Breast Cancer Res Treat* 2016;159:203-213
 19. Nguyen CV, Albarracin CT, Whitman GJ, Lopez A, Sneige N. Atypical ductal hyperplasia in directional vacuum-assisted biopsy of breast microcalcifications: considerations for surgical excision. *Ann Surg Oncol* 2011;18:752-761
 20. Peña A, Shah SS, Fazzio RT, Hoskin TL, Brahmabhatt RD, Hieken TJ, et al. Multivariate model to identify women at low risk of cancer upgrade after a core needle biopsy diagnosis of atypical ductal hyperplasia. *Breast Cancer Res Treat* 2017;164:295-304
 21. Yeh IT, Dimitrov D, Otto P, Miller AR, Kahlenberg MS, Cruz A. Pathologic review of atypical hyperplasia identified by image-guided breast needle core biopsy. Correlation with excision specimen. *Arch Pathol Lab*

Med 2003;127:49-54

22. Degnim AC, Visscher DW, Berman HK, Frost MH, Sellers TA, Vierkant RA, et al. Stratification of breast cancer risk in women with atypia: a Mayo cohort study. *J Clin Oncol* 2007;25:2671-2677
23. Renshaw AA, Cartagena N, Schenkman RH, Derhagopian RP, Gould EW. Atypical ductal hyperplasia in breast core needle biopsies. Correlation of size of the lesion, complete removal of the lesion, and the incidence of carcinoma in follow-up biopsies. *Am J Clin Pathol* 2001;116:92-96
24. Krishnamurthy S, Bevers T, Kuerer H, Yang WT. Multidisciplinary considerations in the management of high-risk breast lesions. *AJR Am J Roentgenol* 2012;198:W132-W140
25. Sickles EA, D'Orsi CJ, Bassett LW, Appleton CM, Berg WA, Burnside ES. *ACR BI-RADS® atlas: mammography*. In American College of Radiology, ed. *ACR BI-RADS® atlas: breast imaging reporting and data system*, 5th ed. Reston, VA: American College of Radiology 2013:5-175
26. Cao C, Louie BE, Melfi F, Veronesi G, Razzak R, Romano G, et al. Impact of pulmonary function on pulmonary complications after robotic-assisted thoracoscopic lobectomy. *Eur J Cardiothorac Surg* 2019;57:338-342
27. Deshaies I, Provencher L, Jacob S, Côté G, Robert J, Desbiens C, et al. Factors associated with upgrading to malignancy at surgery of atypical ductal hyperplasia diagnosed on core biopsy. *Breast* 2011;20:50-55
28. Jung I, Kim MJ, Moon HJ, Yoon JH, Kim EK. Ultrasonography-guided 14-gauge core biopsy of the breast: results of 7 years of experience. *Ultrasonography* 2018;37:55-62
29. Rageth CJ, Rubenov R, Bronz C, Dietrich D, Tausch C, Rodewald AK, et al. Atypical ductal hyperplasia and the risk of underestimation: tissue sampling method, multifocality, and associated calcification significantly influence the diagnostic upgrade rate based on subsequent surgical specimens. *Breast Cancer* 2019;26:452-458
30. Chae BJ, Lee A, Song BJ, Jung SS. Predictive factors for breast cancer in patients diagnosed atypical ductal hyperplasia at core needle biopsy. *World J Surg Oncol* 2009;7:77
31. Mesurolle B, Perez JC, Azzumea F, Lemercier E, Xie X, Aldis A, et al. Atypical ductal hyperplasia diagnosed at sonographically guided core needle biopsy: frequency, final surgical outcome, and factors associated with underestimation. *AJR Am J Roentgenol* 2014;202:1389-1394
32. Rageth CJ, O'Flynn EAM, Pinker K, Kubik-Huch RA, Mundinger A, Decker T, et al. Second International Consensus Conference on lesions of uncertain malignant potential in the breast (B3 lesions). *Breast Cancer Res Treat* 2019;174:279-296

침생검 조직검사에서 진단된 비정형 관상피증식증: 수술적 절제 생검에서 악성으로 진단될 가능성을 예측할 수 있는 위험인자들

박고운¹ · 한부경^{1*} · 이선정¹ · 조수연² · 고은영¹ · 고은숙¹ · 최지수¹

목적 조직생검으로 진단된 비정형 관상피증식증이 수술 후 악성으로 진단되는 과소평가율과 이를 예측할 수 있는 영상 소견이나 진단 방법에 따른 위험인자를 조사하고자 한다.

대상과 방법 2년 이상의 기간 동안 시행된 9660예의 침생검을 후향적으로 분석하여 영상 소견과 조직검사 방법에 따라 과소평가 군과 비 과소평가 군의 차이점을 비교하였다.

결과 9660예의 침생검 중 169 (1.7%)예가 비정형 관상피증식증으로 진단되었다. 절제 생검을 한 112예와 2년 이상 추적검사를 한 30예를 합친 142예 중 35예에서 과소평가되었다 (24.6%, 35/142). 과소평가율의 차이는 조직생검 방법에 따라 의미 있었다; 초음파 유도 핵생검(40.7%, 22/54), 입체정위 진공 보조흡입생검(16.0%, 12/75), 초음파 유도 진공 보조흡입생검(7.7%, 1/13) ($p=0.002$). 다변량 분석에서는 초음파 유도 핵생검(교차비 5.19, 95% 신뢰구간 2.16–13.95, $p < 0.001$)이 독립적인 위험 인자였다. 종괴로 보이는 병변이 초음파 유도 진공 보조흡입생검으로 진단된 경우는 과소평가가 보고되지 않았다($n=7$).

결론 비정형 관상피증식증이 1.7%로 진단되었고 과소평가율은 24.6%였다. 종괴로 보이는 병변이 초음파 유도 진공 보조흡입생검으로 제거된 경우를 제외하고는 상당한 과소평가율을 보이고 있으므로 수술적 절제를 고려해야 한다.

성균관대학교 의과대학 삼성서울병원 ¹영상의학과, ²병리과