



# MRI Findings Suggestive of Metastatic Axillary Lymph Nodes in Patients with Invasive Breast Cancer

유방암 환자에서 액와부 림프절 전이를 시사하는 자기공명영상 소견

Ka Eun Kim, MD<sup>1</sup> , Shin Young Kim, MD<sup>2</sup> , Eun Young Ko, MD<sup>1\*</sup>

<sup>1</sup>Department of Radiology and Center for Imaging Science, Samsung Medical Center, Sungkyunkwan University School of Medicine, Seoul, Korea

<sup>2</sup>Department of Radiology, Soonchunhyang University Cheonan Hospital, Soonchunhyang University College of Medicine, Cheonan, Korea

**Purpose** This study aimed to investigate the diagnostic performance of features suggestive of nodal metastasis on preoperative MRI in patients with invasive breast cancer.

**Materials and Methods** We retrospectively reviewed the preoperative breast MRI of 192 consecutive patients with surgically proven invasive breast cancer. We analyzed MRI findings of axillary lymph nodes with regard to the size, long/short ratio, cortical thickness, shape and margin of the cortex, loss of hilum, asymmetry, signal intensity (SI) on T2-weighted images (T2WI), degree of enhancement in the early phase, and enhancement kinetics. Receiver operating characteristic (ROC) analysis, chi-square test, *t* test, and McNemar's test were used for statistical analysis.

**Results** Increased shorter diameter, uneven cortical shape, increased cortical thickness, loss of hilum, asymmetry, irregular cortical margin, and low SI on T2WI were significantly suggestive of metastasis. ROC analysis revealed the cutoff value for the shorter diameter and cortical thickness as 8.05 mm and 2.75 mm, respectively. Increased cortical thickness (> 2.75 mm) and uneven cortical shape showed significantly higher sensitivity than other findings in McNemar's test. Irregular cortical margins showed the highest specificity (100%).

**Conclusion** Cortical thickness > 2.75 mm and uneven cortical shape are more sensitive parameters than other findings, and an irregular cortical margin is the most specific parameter for predicting axillary metastasis in patients with invasive breast cancer.

**Index terms** Magnetic Resonance Imaging; Breast Neoplasms; Lymph Nodes

Received May 22, 2021  
Revised July 28, 2021  
Accepted August 10, 2021

\*Corresponding author  
Eun Young Ko, MD  
Department of Radiology and  
Center for Imaging Science,  
Samsung Medical Center,  
Sungkyunkwan University  
School of Medicine,  
81 Irwon-ro, Gangnam-gu,  
Seoul 06351, Korea.

Tel 82-2-3410-6418  
Fax 82-2-3410-2559  
E-mail claudel@skku.edu

This is an Open Access article distributed under the terms of the Creative Commons Attribution Non-Commercial License (<https://creativecommons.org/licenses/by-nc/4.0>) which permits unrestricted non-commercial use, distribution, and reproduction in any medium, provided the original work is properly cited.

## ORCID iDs

Ka Eun Kim   
<https://orcid.org/0000-0002-8916-1761>  
Shin Young Kim   
<https://orcid.org/0000-0002-1582-6871>  
Eun Young Ko   
<https://orcid.org/0000-0001-6679-9650>

## INTRODUCTION

Preoperative evaluation of axillary nodal status is important in breast cancer patients because lymph nodes metastasis is the most important prognostic factor in breast cancer staging and has particular value in choosing adjuvant therapy (1, 2).

There are two traditional surgical methods managing axillary lymph nodes in breast cancer patients (2, 3). One is sentinel lymph node biopsy, which samples the first node the tumor drain to. The other is axillary lymph node dissection, which removes nodes in level I and II. However, axillary lymph nodes dissection may lead complications including lymphedema, seroma formation, and limitation of shoulder movement (4, 5). The treatment of axilla in breast cancer patients has been moderated from radical axillary lymph nodes dissection toward a more limited dissection (6).

Noninvasive method for accessing the axillary nodal status has been advanced mainly by ultrasonography (US) (7, 8), and there has been relatively fewer reports on MR findings. MRI with its high soft tissue contrast and multiplanar capabilities provides excellent anatomical information on the axilla with an information about anatomical level of possible metastatic lymph nodes (9, 10).

Several studies have reported the use of MRI for preoperative axillary staging on measurement of lymph node diameter and morphologic features like shape, cortical contour, cortical thickening or dynamic enhancement patterns (2, 10-12). Some studies suggests functional MR imaging techniques like diffusion-weighted MRI, but it is still not clear whether apparent diffusion coefficient value is useful for detecting metastatic axillary lymph nodes (13, 14). The morphologic features on the conventional MRI are still an intuitive and practical methods to use in daily clinical practice. However, some criteria still remain controversial, and performance of the accepted MRI criteria for determination of nodal metastasis is not clear (2, 3).

Therefore, the purpose of this study is to investigate the diagnostic performance of various nodal features suggesting metastasis on preoperative MRI in patients with invasive breast cancer.

## MATERIALS AND METHODS

### PATIENTS SELECTION

Our Institutional Review Board approved this study and waived the need for informed consent because of the retrospective study design (IRB No. 2021-05-101).

This study reviewed a series of 241 consecutive patients who underwent preoperative breast MRI for evaluating invasive breast cancer and axillary lymph nodes status. Among them, patients with neoadjuvant chemotherapy ( $n = 17$ ) before surgery and patients with severe biopsy-related changes in axillary images for lymph node evaluation due to MRI examination on the day of axillary biopsy ( $n = 32$ ) were excluded. Finally, 192 patients with histopathological confirmed axillary lymph nodes status were included in this study. All these patients were female and in age range from 31 to 73 years (mean age: 47 years). There were 76 patients (mean age: 44 years, range: 31-70) with axillary lymph nodes metastasis, and 116 patients (mean age: 51 years, range: 31-73 years) without axillary lymph nodes metastasis. All

patients underwent surgical confirmations of axillary lymph nodes; Sentinel lymph node biopsy alone ( $n = 116$ ), sentinel lymph node biopsy with axillary dissection ( $n = 23$ ), or direct axillary lymph nodes dissection without sentinel lymph node biopsy ( $n = 53$ ).

## HISTOPATHOLOGIC AND CLINICAL DATA

Preoperative breast MRI was done at least 2 months before surgery, and all patients underwent surgical confirmation of axillary lymph nodes. Lymph node metastasis was defined as final pathologic results. Pathologic staging same or more than N1 stage was defined as lymph node metastasis, and micro-metastasis of lymph node was also included at N1 category.

## BREAST MR IMAGING

Breast MRI were performed using 1.5T Achieva scanner (Philips Medical Systems, Best, the Netherlands) and 3T Achieva scanner (Philips Medical Systems) with 7 channel and a dedicated bilateral phased-array breast coil, with the patient in the prone position. The MRI protocol consisted of axial turbo spine-echo and fat-suppressed T2 weighted sequences, and a three-dimensional (3D) dynamic contrast-enhanced sequence. Axial dynamic contrast-enhanced images were obtained with one pre-contrast and six post-contrast dynamic series. A 0.1 mmol/kg bolus injection of gadobutrol (Gadovist; Bayer Healthcare, Berlin, Germany) was carried out via an antecubital vein, followed by a 20 mL saline flush. After contrast administration, images were acquired from 30 seconds, six times per every 60 seconds, with gradient echo sequence and the acquisition time for one scanning was about 60 seconds. The parameters on 1.5T scanner were as follows: repetition time/echo time, 6.5/2.5 ms; 1.5 mm sections without gap; flip angle, 12°; matrix size, 376 × 374; and field of view, 32 × 32 cm. Images with the 3T scanner were obtained under the following parameters: repetition time/echo time, 4.6/2.3 ms; 1.5 mm sections with no gap; flip angle, 24°; matrix size, 512 × 512; and field of view, 32 × 32 cm. The time for scanning ranged from 25 to 27 minutes.

After scanning, two subtraction images were made automatically on a pixel-by-pixel basis: the nonenhanced images were subtracted from the early postcontrast images (standard subtraction), and the delayed postcontrast images were subtracted from the early postcontrast images (reverse subtraction). The reformatted sagittal images and axial and sagittal maximum intensity projections were created from the each standard images.

## INTERPRETATION OF THE MR IMAGES

MR images were retrospectively reviewed by two radiologists (K.E.Y. with K.E.K.) in consensus on our picture archiving and communication system (Centricity, GE Healthcare) without any information about the final pathological findings. The axillary lymph nodes were evaluated at ipsilateral level I area.

We analyzed the MRI findings of the axillary lymph nodes, according to the size (long and short diameters), long/short (L/S) ratio, cortical thickness, cortical shape (even or uneven), cortical margin (smooth or irregular), loss of hilum, asymmetry, signal intensity (SI) on T2-weighted image (T2WI), degree of enhancement (DE) on early phase and enhancement kinetics. The maximum cortical thickness and cortical shape were also evaluated. SI on T2WI was compared to ipsilateral breast parenchyma.

The size of lymph node (long and short diameters), L/S ratio, cortical thickness, cortical shape (even or uneven), cortical margin (smooth or irregular), loss of hilum, asymmetry was evaluated at postcontrast fat-saturated T1-weighted dynamic series on axial and sagittal reconstructed images. SI on T2WI was evaluated on axial T2WI compared to ipsilateral breast parenchyma.

After drawing a region of interest in the cortex with maximum dimension, early and delayed contrast enhancement were measured for evaluating DE, and enhancement kinetics. Enhancement index for DE on early phase was calculated using following equation;  $DE = ([SI \text{ on early post-contrast}] - [SI \text{ on pre-contrast}]) / ([SI \text{ on pre-contrast}])$ . Enhancement kinetics was evaluated according to the type of kinetic curve; Type 1 is continually increasing enhancement over time, type 2 is rapid wash in and then plateau type of enhancement, and type 3 is rapid wash in and wash out of enhancement (10).

## STATISTICAL ANALYSIS

We compared the MRI findings of lymph nodes between the group with axillary lymph node metastasis and the group without metastasis, and analyzed the parameters which showed statistically significant difference between lymph node with and without metastasis.

Receiver operating characteristic (ROC) analysis was performed to determine the optimal cutoff value, balancing sensitivity and specificity, for the evaluation of short diameter and cortical thickness. *t* test was performed to analyze diameter, L/S ratio, cortical thickness and DE on early phase. Chi-square test performed to evaluate shape, margin, loss of hilum, SI on T2WI, asymmetry and enhancement kinetics.

Sensitivity, specificity, positive predictive value (PPV) and negative predictive value (NPV) were evaluated for the MR findings with significant difference between lymph node with metastasis and lymph node without metastasis.

McNemar's test was used to determine whether sensitivity and specificity of some MR findings are significantly higher than other finding. Bonferroni's correction was done to correct false positive error inflation by multiple testing.

Data were analyzed by using statistical software (SPSS 26.0, IBM Corp., Armonk, NY, USA) and  $p < 0.05$  was considered statistically significant.

## RESULTS

Among 192 patients (mean age: 47 years, range: 31–73 years) with histopathological confirmed invasive breast cancer patients, 76 patients (mean age: 44 years, range: 31–70 years) had axillary lymph nodes metastasis.

In metastatic lymph nodes, mean and standard deviation of short diameter and cortical thickness were  $8.7 \pm 4.0$  mm and  $5.2 \pm 3.4$  mm, which were significantly greater than non-metastatic lymph nodes ( $p < 0.001$ ). Other significant morphologic findings of metastatic lymph nodes were uneven cortical shape ( $p < 0.001$ ), irregular cortical margin ( $p = 0.001$ ), loss of hilum ( $p < 0.001$ ) and asymmetry ( $p < 0.001$ ). Also, low SI on T2WI ( $p = 0.017$ ) showed significant difference between metastatic and non-metastatic lymph nodes. However, long diameter, L/S ratio, enhancement kinetics and DE on early phase were not significantly related to

metastatic lymph nodes (all  $p > 0.05$ ) (Table 1, Figs. 1-3).

Table 2 showed performance of significant MR findings suggesting axillary lymph node metastasis. We analyzed the cutoff value of short diameter and cortical thickness using ROC analysis as 8.05 mm and 2.75 mm.

Sensitivities of MR findings suggesting metastatic lymph nodes were 82.9% in cortical thickness  $> 2.75$  mm, 71.1% in uneven cortical shape, 56.8% in low SI on T2WI, 43.3% in short diameter  $> 8.05$  mm, 40.8% in asymmetry, 26.3% in loss of hilum, followed by 9.2% in irregular cortical margin..

McNemar's test was performed to determine if there was a significant difference between the sensitivity of each finding. Cortical thickness  $> 2.75$ mm (82.9%) and uneven cortical shape (71.1%), showed significantly higher sensitivity than other findings. However, there was no significant difference between the sensitivities of cortical thickness  $> 2.75$  mm (82.9%) and uneven cortical shape ( $p = 0.132$ ). Bonferroni's correction was conducted to correct false positive error inflation by multiple testing (Table 3).

Irregular cortical margin (100%) showed the highest specificity for metastatic lymph nodes. Other specificities were 94% in loss of hilum, 86.2% in asymmetry, 76.7% in short diameter  $> 8.05$  mm, 65.5% in uneven cortical shape, 61.1% in low SI on T2WI, followed by 47.4% in cortical thickness  $> 2.75$ mm. McNemar's test was not available for irregular cortical margin ( $p = NA$ ), because there was no false positive case in irregular cortical margin.

**Table 1.** MRI Characteristics of Axillary Lymph Nodes

	With Metastasis (n = 76)	Without Metastasis (n = 116)	p-Value
Size			
Long diameter, mm	15.2 ± 8.0	13.4 ± 6.5	0.225
Short diameter, mm	8.7 ± 4.0	6.8 ± 2.3	<0.001
L/S ratio	1.8 ± 0.6	2.1 ± 1.7	0.063
Cortical thickness, mm	5.2 ± 3.4	3.2 ± 1.6	<0.001
Cortical shape, %			<0.001
Even	22 (28.9)	76 (65.5)	
Uneven	54 (71.1)	40 (34.5)	
Cortical margin, %			0.001
Smooth	69 (90.8)	116 (100.0)	
Irregular	7 (9.2)	0 (0.0)	
Loss of hilum, %	20 (26.3)	7 (6.0)	<0.001
Low SI on T2WI, %	42 (56.8)	44 (38.6)	0.017
Asymmetry, %	31 (40.8)	16 (13.8)	<0.001
Degree of enhancement	1.3 ± 1.8	1.3 ± 1.4	0.855
Enhancement type*, %			0.523
1	25 (37.3)	46 (44.2)	
2	31 (46.3)	39 (37.5)	
3	11 (16.4)	19 (18.3)	

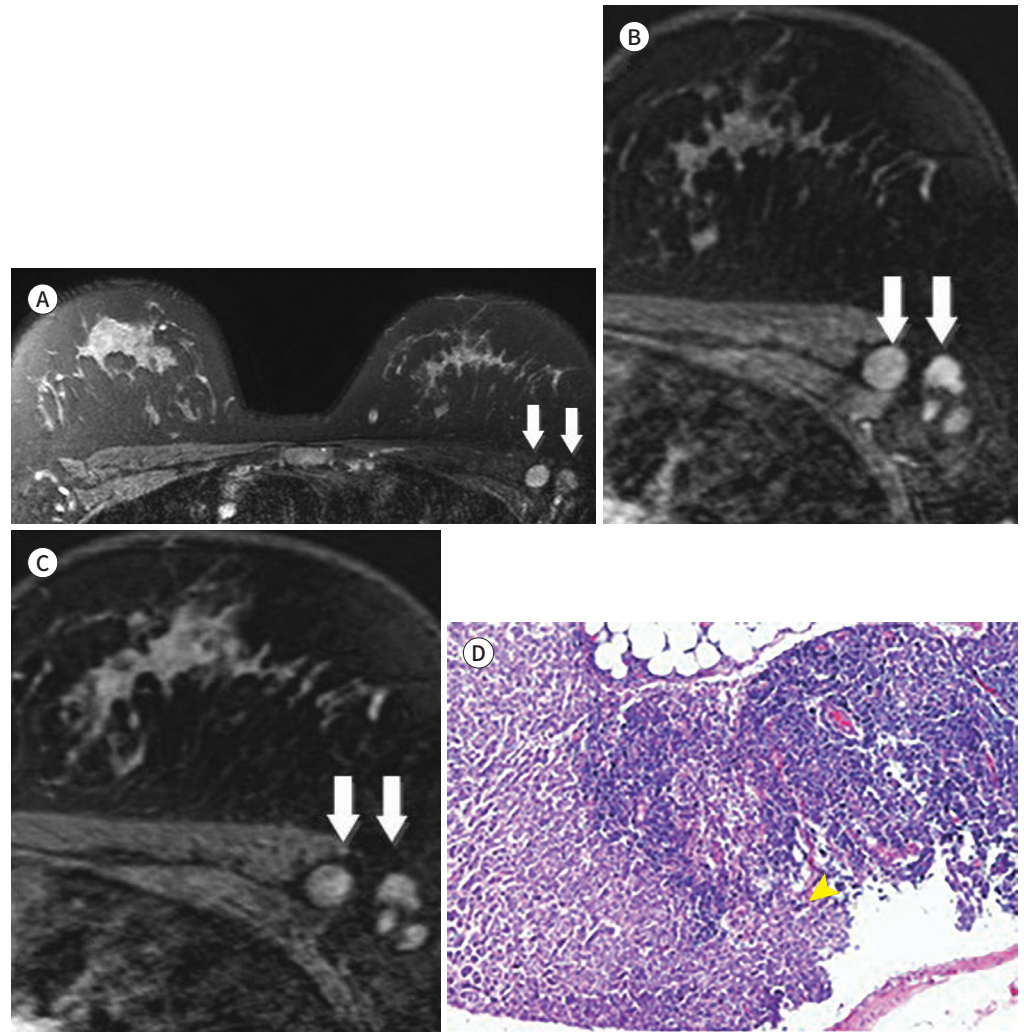
Data are presented as mean ± standard deviation or n (%).

\*1 = progressive or persistent enhancement pattern, 2 = plateau pattern, 3 = washout pattern.

L/S = long/short, SI = signal intensity, T2WI = T2-weighted image



**Fig. 1.** Invasive ductal carcinoma in the left breast with lymph nodes metastasis in a 33-year-old female. **A-C.** On T2WI (**A**) and dynamic enhanced MRI (**B** and **C**), lymph nodes show loss of hilum, low signal intensity on T2WI, asymmetry, increased shorter diameter and cortical thickness, uneven cortical shape and irregular margins (arrows). The enhancement pattern is type 3. The patient underwent axillary lymph node dissection, and metastasis was observed in 28 of the 45 lymph nodes examined. **D.** Histopathological examination shows metastatic invasive ductal carcinoma (arrowhead) (hematoxylin and eosin stain,  $\times 100$ ). Metastasis was confirmed in the lymph nodes. T2WI = T2 weighted image



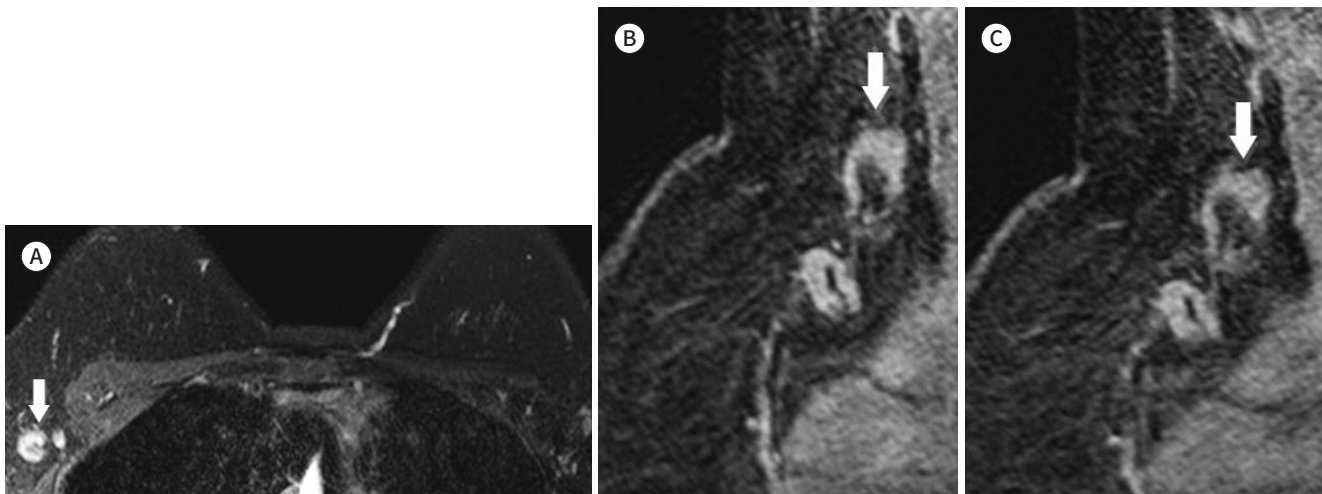
PPV was high in lymph nodes with irregular cortical margin (100%) and loss of hilum (74.1%). NPV was high in lymph nodes with cortical thickness more than 2.75 mm (80.9%), and uneven cortical shape (77.6%)

## DISCUSSION

The presence of metastasis in ipsilateral axillary lymph nodes is the most important single predictor of long-term survival in patients with a primary breast cancer (5, 15). About 60% of patients with breast cancer (usually those with small primary tumors) have negative results

**Fig. 2.** Invasive ductal carcinoma in the right breast with lymph nodes metastasis in a 37-year-old female.

**A-C.** On T2 weighted image (A) and dynamic enhanced MRI (B and C), lymph nodes show asymmetry, increased shorter diameter and cortical thickness, uneven cortical shape, and irregular margins (arrows). The enhancement pattern is type 2. The patient underwent axillary lymph node dissection, and metastasis was observed in 25 out of 37 lymph nodes.



in the lymph nodes, the ability to non-operatively define pathologically positive or negative axillary lymph nodes would offer significant advantages.

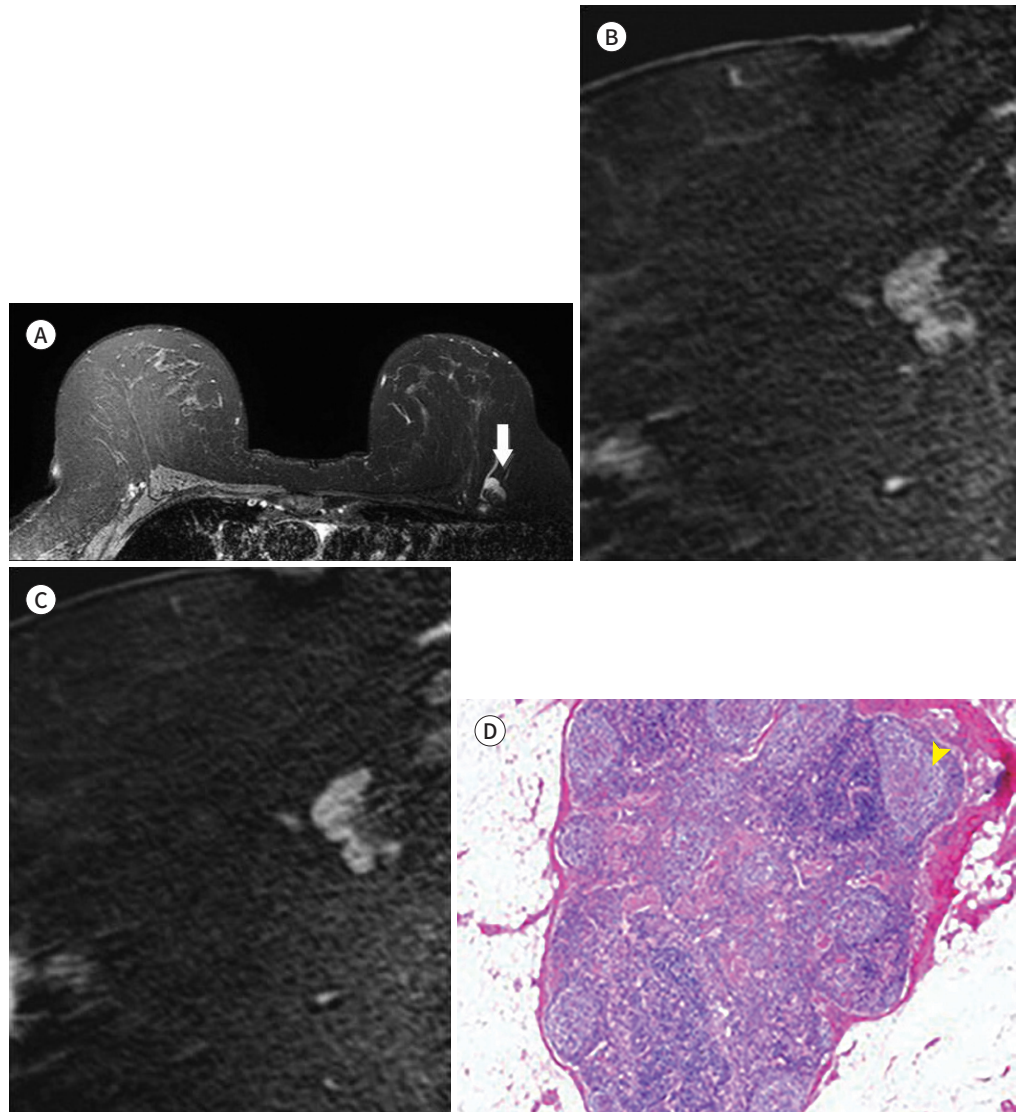
Several studies have been tried to prove accuracy in identifying axillary nodal metastasis with conventional imaging modalities including CT, PET, scintimammography, US and mammography, but there were no satisfactory results (3, 16-19). PET studies with radiolabeled glucose analogs have shown promising results for axillary lymph nodes assessment, but the limited availability of PET instruments makes widespread application of the method difficult (18, 19). Axillary US alone showed 72.3% sensitivity and 93.4% specificity, while combination with fine needle aspiration cytology showed 88.1% sensitivity and 100% specificity, but it is highly operator dependent and invasive (20).

MRI is a noninvasive diagnostic technique that allows 3D morphological analysis of lymph nodes. Dynamic contrast-enhanced MRI has evolved as a sensitive method for breast cancer diagnosis (21, 22). In our study, we investigated the diagnostic performance of conventional MRI with dynamic contrast enhancement for detecting metastatic axillary lymph nodes in invasive breast cancer patients. Among several parameters of previously known radiologic findings of metastatic axillary lymph nodes, short diameter, cortical thickness, uneven cortical shape, irregular cortical margin, loss of fatty hilum, low SI on T2WI, asymmetry were also significant findings suggesting metastatic axillary lymph nodes, concordant with several previous studies (3, 10, 23-25).

The ratio between long and short diameter of lymph nodes (L/S ratio) of approximately 1, defined as “roundness index” (26), and this has been reliable index of nodal metastasis (27, 28). However, in our study, L/S ratio was not a significant finding. This can be explained that very small benign lymph nodes with a longitudinal diameter < 10 mm are also nearly always round in shape. On the other hand, metastatic lymph nodes with > 20 mm may maintain an oval shape (29, 30).

Our results for the enhancement kinetics were not significant for predicting metastatic

**Fig. 3.** Invasive ductal carcinoma in the left breast without lymph nodes metastasis in a 61-year-old female. **A-C.** On T2WI (**A**) and dynamic enhanced MRI (**B** and **C**), lymph nodes show asymmetry, increased shorter diameter and cortical thickness, and uneven cortical shape (arrow). However, lymph nodes show low signal intensity on T2WI and have smooth margins. The enhancement pattern is type 3. The patient underwent sentinel lymph node biopsy, and metastasis was not observed in any of the 5 lymph nodes examined. **D.** Histopathologically, the lymph node shows well-preserved follicles (arrowhead) in cortex, with no evidence of metastasis (hematoxylin and eosin stain,  $\times 40$ ). T2WI = T2 weighted image



lymph nodes, similar to other previous studies (3, 10). One possible explanation for the normal lymph node with washout kinetics is that the capillaries in lymph node are highly permeable to gadolinium contrast agent (15). Therefore, analyzing enhancement kinetics is not recommended for predicting lymph nodes metastasis, and rather morphologic criteria (e.g., shape, cortical thickness, loss of hilum) has been accepted more important imaging factors (2, 31).

Murray et al. (5) reported that patients with axillary lymph node metastasis had enhancement index of  $> 21\%$  with 100% sensitivity and 56% specificity, which suggested quantitative



**Table 2.** Performance of MRI Findings with Regard to Predicting Axillary Lymph Node Metastasis

	Sensitivity (%)	Specificity (%)	PPV (%)	NPV (%)
Short diameter > 8.05 mm*	43.4	76.7	55.0	67.4
Uneven cortical shape	71.1	65.5	57.4	77.6
Irregular cortical margin	9.2	100.0	100.0	62.7
Loss of hilum	26.3	94.0	74.1	66.1
Cortical thickness > 2.75 mm*	82.9	47.4	50.8	80.9
Low SI on T2WI	56.8	61.4	48.8	68.6
Asymmetry	40.8	86.2	66.0	69.0

\*Cutoff value was calculated using receiver operating characteristic analysis.

NPV = negative predictive value, PPV = positive predictive value, SI = signal intensity, T2WI = T2-weighted image

**Table 3.** Comparison of the Sensitivity between the MRI Findings Suggestive of Axillary Lymph Node Metastasis

	Cortical Thickness		Uneven Cortical Shape	
	p-Value	p-Value <sup>†</sup>	p-Value	p-Value <sup>†</sup>
Short diameter > 8.05 mm*	< 0.001	< 0.001	0.001	0.006
Uneven cortical shape	0.022	0.132		
Irregular cortical margin	< 0.001	< 0.001	< 0.001	< 0.001
Loss of hilum	< 0.001	< 0.001	< 0.001	< 0.001
Cortical thickness > 2.75 mm*			0.022	0.132
Low SI on T2WI	< 0.001	< 0.001	< 0.001	< 0.001
Asymmetry	< 0.001	< 0.001	0.043	0.258

\*Cutoff value was calculated using receiver operating characteristic analysis.

<sup>†</sup> Bonferroni's correction was done for multiple testing.

SI = signal intensity, T2WI = T2-weighted image

assessment with dynamic gadolinium enhanced MRI may be a reliable method of predicting metastasis. But in our study, DE on early phase or enhancement kinetics were not significant, although breast cancer usually shows early enhancement and washout.

There are some limitations in this study. First, the MRI-pathological correlation on a node-to-node basis (co-localization) has not been carried in our study. We analyzed the image of most suspicious lymph node, however, tried to analyze the lowest and the most medially located lymph node when there were multiple suspicious lymph nodes, to reduce this limitation. Second, we analyzed the MRI findings of axillary lymph node alone and did not considered other imaging findings such as US or mammography. Third, lymph node analysis was done by two radiologists in consensus. Respective analysis by two or more radiologists and evaluating interobserver variability would much increase the reliability of the study results. Fourth, there may be the difference in-plane resolution between 1.5T and 3T MRI protocols. Images achieved by both types of MRI were analyzed by same criteria in our study, which may affect the interpretation of lymph node characteristics. The last, lymph node metastasis was defined as same or more than pathologic N1 staging. Micrometastasis was also included in N1 staging, which might not reflect the several known characteristic features of metastatic lymph nodes in MRI.

In conclusion, cortical thickness > 2.75 mm and uneven cortical shape are more sensitive parameters than other findings, and irregular cortical margin is the most specific parameter for predicting the axillary metastasis in patients with invasive breast cancer.

### Author Contributions

Conceptualization, K.E.Y., K.S.Y.; data curation, K.K.E., K.S.Y.; formal analysis, K.K.E., K.S.Y.; investigation, K.K.E., K.S.Y.; methodology, K.E.Y.; project administration, K.E.Y.; resources, K.K.E., K.S.Y.; supervision, K.E.Y.; validation, K.K.E.; visualization, K.K.E.; writing—original draft, K.K.E., K.S.Y.; and writing—review & editing, K.K.E., K.E.Y.

### Conflicts of Interest

The authors have no potential conflicts of interest to disclose.

### Funding

None

## REFERENCES

- Luciani A, Pigneur F, Ghazali F, Dao TH, Cunin P, Meyblum E, et al. Ex vivo MRI of axillary lymph nodes in breast cancer. *Eur J Radiol* 2009;69:59-66
- Michel SC, Keller TM, Fröhlich JM, Fink D, Caduff R, Seifert B, et al. Preoperative breast cancer staging: MR imaging of the axilla with ultrasmall superparamagnetic iron oxide enhancement. *Radiology* 2002;225:527-536
- Mortellaro VE, Marshall J, Singer L, Hochwald SN, Chang M, Copeland EM, et al. Magnetic resonance imaging for axillary staging in patients with breast cancer. *J Magn Reson Imaging* 2009;30:309-312
- Meyer JS. Sentinel lymph node biopsy: strategies for pathologic examination of the specimen. *J Surg Oncol* 1998;69:212-218
- Murray AD, Staff RT, Redpath TW, Gilbert FJ, Ah-See AK, Brookes JA, et al. Dynamic contrast enhanced MRI of the axilla in women with breast cancer: comparison with pathology of excised nodes. *Br J Radiol* 2002;75:220-228
- Kinkel K, Helbich TH, Esserman LJ, Barclay J, Schwerin EH, Sickles EA, et al. Dynamic high-spatial-resolution MR imaging of suspicious breast lesions: diagnostic criteria and interobserver variability. *AJR Am J Roentgenol* 2000;175:35-43
- Sidibé S, Coulibaly A, Traoré S, Touré M, Traoré I. Role of ultrasonography in the diagnosis of axillary lymph node metastases in breast cancer: a systematic review. *Mali Med* 2007;22:9-13
- Cho N, Moon WK, Han W, Park IA, Cho J, Noh DY. Preoperative sonographic classification of axillary lymph nodes in patients with breast cancer: node-to-node correlation with surgical histology and sentinel node biopsy results. *AJR Am J Roentgenol* 2009;193:1731-1737
- Hergan K, Morrigl B, Kathrein A, Buchberger W, Judmaier W, Peer S, et al. MR and CT anatomy of the axilla. *Acta Radiol* 1997;38:198-205
- Kvistad KA, Rydland J, Smethurst HB, Lundgren S, Fjøsne HE, Haraldseth O. Axillary lymph node metastases in breast cancer: preoperative detection with dynamic contrast-enhanced MRI. *Eur Radiol* 2000;10:1464-1471
- He N, Xie C, Wei W, Pan C, Wang W, Lv N, et al. A new, preoperative, MRI-based scoring system for diagnosing malignant axillary lymph nodes in women evaluated for breast cancer. *Eur J Radiol* 2012;81:2602-2612
- Rahbar H, Partridge SC, Javid SH, Lehman CD. Imaging axillary lymph nodes in patients with newly diagnosed breast cancer. *Curr Probl Diagn Radiol* 2012;41:149-158
- Guvenc I, Whitman GJ, Liu P, Yalniz C, Ma J, Dogan BE. Diffusion-weighted MR imaging increases diagnostic accuracy of breast MR imaging for predicting axillary metastases in breast cancer patients. *Breast J* 2019;25:47-55
- Kim EJ, Kim SH, Kang BJ, Choi BG, Song BJ, Choi JJ. Diagnostic value of breast MRI for predicting metastatic axillary lymph nodes in breast cancer patients: diffusion-weighted MRI and conventional MRI. *Magn Reson Imaging* 2014;32:1230-1236

15. Pressman PI. Surgical treatment and lymphedema. *Cancer* 1998;83:2782-2787
16. Walsh R, Kornguth PJ, Soo MS, Bentley R, DeLong DM. Axillary lymph nodes: mammographic, pathologic, and clinical correlation. *AJR Am J Roentgenol* 1997;168:33-38
17. Fuster D, Duch J, Paredes P, Velasco M, Muñoz M, Santamaría G, et al. Preoperative staging of large primary breast cancer with [<sup>18</sup>F]fluorodeoxyglucose positron emission tomography/computed tomography compared with conventional imaging procedures. *J Clin Oncol* 2008;26:4746-4751
18. Ueda S, Tsuda H, Asakawa H, Omata J, Fukatsu K, Kondo N, et al. Utility of 18F-fluoro-deoxyglucose emission tomography/computed tomography fusion imaging (18F-FDG PET/CT) in combination with ultrasonography for axillary staging in primary breast cancer. *BMC Cancer* 2008;8:165
19. Kuznetsova M, Graybill JC, Zusag TW, Hartsell WF, Griem KL. Omission of axillary lymph node dissection in early-stage breast cancer: effect on treatment outcome. *Radiology* 1995;197:507-510
20. Luparia A, Campanino P, Cotti R, Lucarelli D, Durando M, Mariscotti G, et al. Role of axillary ultrasound in the preoperative diagnosis of lymph node metastases in patients affected by breast carcinoma. *Radiol Med* 2010;115:225-237
21. Heywang-Köbrunner SH. Contrast-enhanced magnetic resonance imaging of the breast. *Invest Radiol* 1994;29:94-104
22. Klerkx WM, Geldof AA, Heintz AP, van Diest PJ, Visser F, Mali WP, et al. Longitudinal 3.0T MRI analysis of changes in lymph node volume and apparent diffusion coefficient in an experimental animal model of metastatic and hyperplastic lymph nodes. *J Magn Reson Imaging* 2011;33:1151-1159
23. Dershaw DD, Selland DG, Tan LK, Morris EA, Abramson AF, Liberman L. Spiculated axillary adenopathy. *Radiology* 1996;201:439-442
24. Lam WW, Yang WT, Chan YL, Stewart IE, Metreweli C, King W. Detection of axillary lymph node metastases in breast carcinoma by technetium-99m sestamibi breast scintigraphy, ultrasound and conventional mammography. *Eur J Nucl Med* 1996;23:498-503
25. Mumtaz H, Hall-Craggs MA, Davidson T, Walmsley K, Thurell W, Kissin MW, et al. Staging of symptomatic primary breast cancer with MR imaging. *AJR Am J Roentgenol* 1997;169:417-424
26. Sakai F, Kiyono K, Sone S, Kondo Y, Oguchi M, Watanabe T, et al. Ultrasonic evaluation of cervical metastatic lymphadenopathy. *J Ultrasound Med* 1988;7:305-310
27. Nori J, Vanzi E, Bazzocchi M, Bufalini FN, Distanti V, Branconi F, et al. Role of axillary ultrasound examination in the selection of breast cancer patients for sentinel node biopsy. *Am J Surg* 2007;193:16-20
28. Vassallo P, Wernecke K, Roos N, Peters PE. Differentiation of benign from malignant superficial lymphadenopathy: the role of high-resolution US. *Radiology* 1992;183:215-220
29. Balu-Maestro C, Chapellier C, Carrier P, Darcourt J, Ettore F, Raoust I. Role of imaging in the evaluation of axillary nodes and metastatic disease from breast carcinoma. *J Radiol* 2005;86:1649-1657
30. Feu J, Tresserra F, Fábregas R, Navarro B, Grases PJ, Suris JC, et al. Metastatic breast carcinoma in axillary lymph nodes: in vitro US detection. *Radiology* 1997;205:831-835
31. Weissleder R, Elizondo G, Wittenberg J, Lee AS, Josephson L, Brady TJ. Ultrasmall superparamagnetic iron oxide: an intravenous contrast agent for assessing lymph nodes with MR imaging. *Radiology* 1990;175:494-498

## 유방암 환자에서 액와부 림프절 전이를 시사하는 자기공명영상 소견

김가은<sup>1</sup> · 김신영<sup>2</sup> · 고은영<sup>1\*</sup>

**목적** 유방암 환자의 수술 전 자기공명영상에서 림프절 전이를 시사하는 소견들에 따른 진단 성적을 알아보려고 한다.

**대상과 방법** 수술 전 유방 자기공명영상을 촬영하고 유방암 수술을 시행한 192명의 환자를 후향적으로 분석하였다. 영상 소견에서 림프절의 크기와 장경/단경의 비율, 피질의 두께와 모양, 변연, 수질의 소실, 비대칭성, T2 강조영상에서의 신호강도, 이른 조영증강의 정도, 조영증강의 역학을 조사하였다. 수신자판단특성곡선 분석, 카이 분석과 t-검정, 맥니마 검정을 이용하여 통계분석을 시행하였다.

**결과** 단경의 증가, 피질의 불규칙한 모양과 피질 두께의 증가, 수질의 소실, 비대칭성, 피질의 불규칙한 변연 그리고 T2 강조영상에서의 낮은 신호강도는 전이를 시사하는 의미 있는 소견이었다. 이중 단경과 피질의 두께에 대해 수신자판단특성곡선 분석으로 각각 8.05 mm와 2.75 mm로 절단값을 얻었다. 2.75 mm 이상의 피질 두께, 피질의 불규칙한 모양은 맥니마 검정으로 다른 소견들과 비교할 때 민감도의 유의한 차이를 보였다. 피질의 불규칙한 변연 (100%)은 가장 높은 특이도를 보였다.

**결론** 유방 자기공명영상의 전이 림프절 분석에서 2.75 mm 이상의 피질 두께와 피질의 불규칙한 모양은 다른 소견들보다 높은 민감도를 보이고 피질의 불규칙한 변연은 가장 높은 특이도를 보이는 소견이다.

<sup>1</sup>성균관대학교 의과대학 삼성서울병원 영상의학과,

<sup>2</sup>순천향대학교 의과대학 부속 천안병원 영상의학과