



Extracorporeal Pedicles for Free Flap Reconstruction in Diabetic Lower Extremity Wounds

Alejandro R. Gimenez, MD¹ Daniel Lazo, MD, MSc² Salomao Chade, MD, PhD² Alex Fioravanti, MD²
 Olimpio Colicchio, MD² Daniel Alvarez, MD² Ernani Junior, BA² Sarth Raj, BS¹
 Amjed Abu-Ghname, MD¹ Marco Maricevich, MD¹

¹Division of Plastic Surgery, Michael E. DeBakey Department of Surgery, Baylor College of Medicine, Houston, Texas
²Hospital Especializado, Sao Paulo, Brazil

Address for correspondence Marco Maricevich, MD, Division of Plastic Surgery, Michael E. DeBakey Department of Surgery, Baylor College of Medicine, 1977 Butler Blvd. Suite E6.100, Houston, TX 77030 (e-mail: Marco.Maricevich@bcm.edu).

Arch Plast Surg 2022;49:782–784.

Abstract

Diabetic foot ulcers are a severe complication of diabetes, and their management requires a multidisciplinary approach for optimal management. When treating these ulcers, limb salvage remains the ultimate goal. In this article, we present the “hanging” free flap for the reconstruction of chronic lower extremity diabetic ulcers. This two-staged approach involves standard free flap harvest and inset; however, following inset the “hanging” pedicle is covered within a skin graft instead of making extraneous incisions within the undisturbed soft tissues or tunnels that can compress the vessels. After incorporation, a second-stage surgery is performed in 4 to 6 weeks which entails pedicle division, flap inset revision, and end-to-end reconstruction of the recipient vessel. Besides decreasing the number of incisions on diabetic patients, our novel technique utilizing the “hanging” pedicle simplifies flap monitoring and inset and allows reconstruction of recipient vessels to reestablish distal blood flow.

Keywords

- ▶ diabetic foot ulcers
- ▶ hanging pedicle
- ▶ microvascular reconstruction
- ▶ free tissue transfer

Diabetic foot ulcers (DFUs) are a severe complication of diabetes with significant morbidity, mortality, and health care costs.¹ Despite advances in wound care and limb revascularization, many patients still undergo amputation, increasing 5-year mortality rates by up to 80%.^{2,3} While numerous treatment modalities exist for this challenging pathology, limb salvage remains the ultimate goal.

Given their complex nature, DFU treatment requires a multidisciplinary approach to optimize nutritional status, comorbidities, and local wound care while providing appropriate footwear and patient education.² Revascularization procedures and antibiotics should be implemented when appropriate. If these measures fail, microsurgical free-tissue

transfer can be considered in suitable candidates, with consistently high rates of flap survival and long-term salvage.^{1,3,4}

Microvascular reconstruction in the diabetic patient warrants thorough preoperative evaluation and perioperative management to mitigate risk factors that increase flap failure.^{1–3} Concomitant atherosclerotic disease, which further complicates reconstruction, can be overcome by using end-to-side anastomoses to preserve distal blood flow and minimize vascular spasm, harvest of a long pedicle to escape the zone of inflammation, and utilization of supermicrosurgery in the absence of adequate major recipient vessels.^{4,5} Though successful, these methods are limited by technical difficulty, surgeon expertise, and available technology.

received
 January 17, 2022
 accepted after revision
 July 8, 2022

DOI <https://doi.org/10.1055/s-0042-1758635>.
 eISSN 2234-6171.

© 2022. The Korean Society of Plastic and Reconstructive Surgeons. All rights reserved.

This is an open access article published by Thieme under the terms of the Creative Commons Attribution-NonDerivative-NonCommercial-License, permitting copying and reproduction so long as the original work is given appropriate credit. Contents may not be used for commercial purposes, or adapted, remixed, transformed or built upon. (<https://creativecommons.org/licenses/by-nc-nd/4.0/>)

Thieme Medical Publishers, Inc., 333 Seventh Avenue, 18th Floor, New York, NY 10001, USA

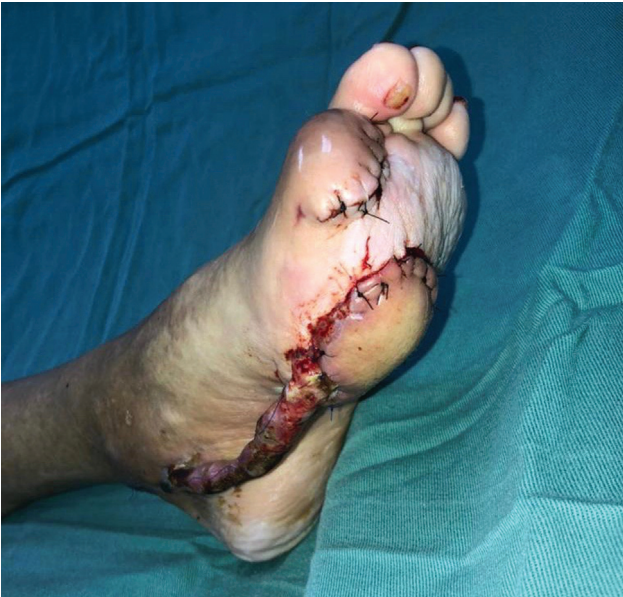

Fig. 1 "Hanging" pedicle immediately postoperatively, covered with skin graft.

Additionally, these procedures are time-consuming and can result in added incisions in an already ischemic limb with healing difficulties.

To decrease operative time and minimize the number of incisions and risk of wound healing complications, we suggest the use of the "hanging" free flap for the reconstruction of chronic lower extremity diabetic ulcers. Following patient optimization and adequate wound debridement, our reconstruction involves standard free flap harvest, end-to-end microsurgical anastomosis, and inset. Following flap inset, we cover the "hanging" pedicle with a skin graft instead of making extraneous incisions within the undisturbed soft tissues or tunnels that can compress the vessels (→ **Fig. 1** and → **Video 1**). While the flap incorporates, the exposed pedicle is protected with a soft dressing. After incorpo-

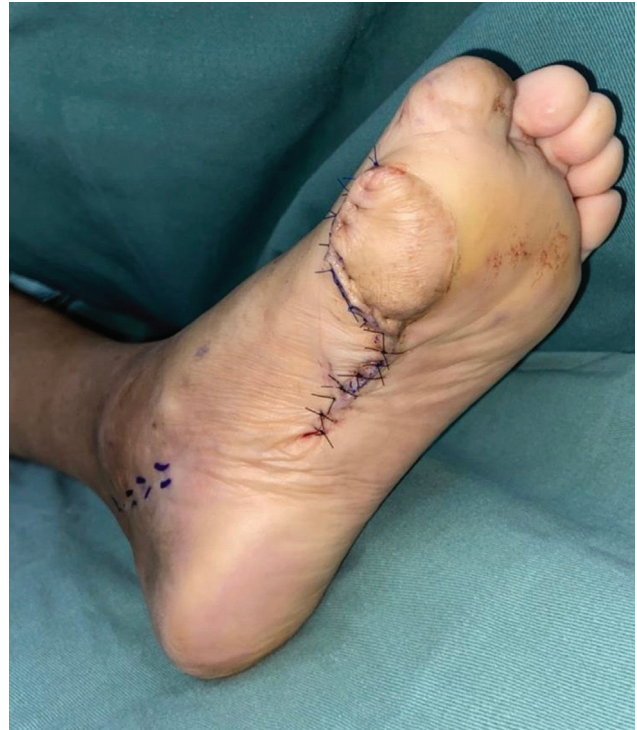

Fig. 2 Wound following incorporation, pedicle division, and flap revision.

ration, the patient undergoes a second-stage surgery in 4 to 6 weeks which entails pedicle division, flap inset revision, and end-to-end reconstruction of the recipient vessel. We have utilized this technique to reconstruct 10 patients so far. Patients (ages 41 to 57) had prolonged history of diabetes complicated by chronic stage 3 lower extremity ulcers. Defects ranged between 18 and 23 cm² and were located over the distal third of the leg or the foot. Defects were reconstructed using the first dorsal metatarsal artery perforator, radial forearm, and anterolateral thigh

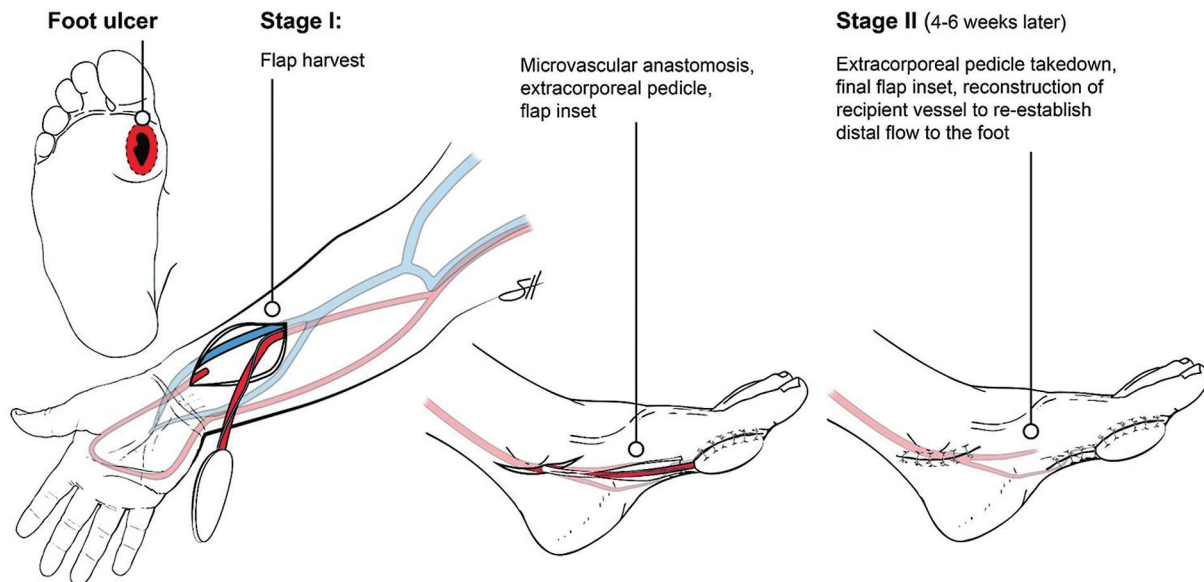


Fig. 3 Pictorial representation of the extracorporeal pedicle reconstruction.

free flaps. All patients underwent successful flap division (► **Figs. 2 and 3**) with 100% flap survival rate. One patient developed partial necrosis of the distal tip of the flap that was managed conservatively.

Video 1

Video detailing original wound following debridement, radial forearm harvest, “hanging pedicle” overlying flap coverage, subsequent coverage of pedicle with skin graft, and immediate postoperative result. Online content including video sequences viewable at: <https://www.thieme-connect.com/products/ejournals/html/10.1055/s-0042-1758635>.

Free tissue transfer to reconstruct poorly vascularized lower extremity DFU remains the cornerstone for limb salvage in diabetic patients. Besides decreasing the number of incisions on diabetic patients, our novel technique utilizing the “hanging” pedicle simplifies flap monitoring and inset. Furthermore, it allows reconstruction of recipient vessels to reestablish distal blood flow. There is no substantial increase in operative skill required to incorporate our technique into surgical practice.

Financial Disclosures/Commercial Associations
None.

Author Contribution

Conceptualization: M Maricevich. Data curation: AR Gimenez, S Raj, A Abu-Ghname. Methodology: M Maricevich. Project administration: M Maricevich, D Lazo, A

Fioravanti, O Colicchio, D Alvarez, E Junior. Visualization: M Maricevich. Writing - original draft: AR Gimenez, S Raj, A Abu-Ghname. Writing - review & editing: AR Gimenez, A Abu-Ghname, M Maricevich, D Lazo, A Fioravanti, O Colicchio, D Alvarez, E Junior.

Products/Devices/Drugs

None.

Patient Consent

The patients provided written informed consent for the publication and the use of their images.

Sources of Support

None.

Conflict of Interest

None declared.

References

- 1 Kotha VS, Fan KL, Schwitzer JA, et al. Amputation versus free flap: long-term outcomes of microsurgical limb salvage and risk factors for amputation in the diabetic population. *Plast Reconstr Surg* 2021;147(03):742–750
- 2 Evans KK, Attinger CE, Al-Attar A, et al. The importance of limb preservation in the diabetic population. *J Diabetes Complications* 2011;25(04):227–231
- 3 Oh TS, Lee HS, Hong JP. Diabetic foot reconstruction using free flaps increases 5-year-survival rate. *J Plast Reconstr Aesthet Surg* 2013;66(02):243–250
- 4 Suh HS, Oh TS, Hong JP. Innovations in diabetic foot reconstruction using supermicrosurgery. *Diabetes Metab Res Rev* 2016;32(Suppl 1):275–280
- 5 Suh HP, Park CJ, Hong JP. Special considerations for diabetic foot reconstruction. *J Reconstr Microsurg* 2021;37(01):12–16