









# A Nationwide Analysis Evaluating the Safety of Using Acellular Dermal Matrix with Tissue Expander-Based Breast Reconstruction

Jessica Luo, MD<sup>1</sup>  Whitney D. Moss, MD<sup>1</sup>  Giovanna R. Pires, BA<sup>1</sup>  Irfan A. Rhemtulla, MD, MS<sup>1</sup>  
Megan Rosales, MS, MStat<sup>2</sup> Gregory J. Stoddard, MS<sup>2</sup>  Jayant P. Agarwal, MD<sup>1</sup>   
Alvin C. Kwok, MD, MPH<sup>1</sup> 

<sup>1</sup>Division of Plastic and Reconstructive Surgery, Department of Surgery, University of Utah School of Medicine, Salt Lake City, Utah

<sup>2</sup>Division of Epidemiology, Department of Internal Medicine, University of Utah School of Medicine, Salt Lake City, Utah

Address for correspondence Alvin Kwok, MD, MPH, University of Utah, 30N 1900 E 3b400, Salt Lake City, UT 84132 (e-mail: alvin.kwok@hsc.utah.edu).

Arch Plast Surg 2022;49:716–723.

## Abstract

**Background** In March 2021, the United States Food and Drug Administration (FDA) safety communication cautioned against the use of acellular dermal matrix (ADM) products in breast reconstruction and reiterated that the FDA does not approve ADM use in breast surgery. This study aims to assess the safety of ADM use in breast reconstruction.

**Methods** Women who underwent ADM and non-ADM assisted tissue expander (TE)-based breast reconstruction were identified using the National Surgical Quality Improvement Program database (2012–2019). Trends of ADM use over time, and 30-day outcomes of surgical site infection (SSI), dehiscence, and unplanned reoperation were assessed.

**Results** Of the 49,049 TE-based breast reconstructive cases, 42.4% were ADM assisted and 57.6% non-ADM assisted. From 2012 to 2019, the use of ADM increased from 26.1 to 55.6% (relative risk [RR] = 1.10;  $p < 0.01$ ). Higher rates of SSI (3.9 vs. 3.4%;  $p = 0.003$ ) and reoperation (7.4 vs. 6.0%;  $p < 0.001$ ) were seen in the ADM cohort. There was no significant difference seen in dehiscence rates (0.7 vs. 0.7%;  $p = 0.73$ ). The most common reoperation within 30 days for the ADM group (17.6%) was removal of TE without insertion of implant (current procedural terminology: 11,971). ADM-assisted breast reconstruction was associated with increased relative risk of SSI by 10% (RR = 1.10, confidence interval [CI]: 1.01–1.21;  $p = 0.03$ ) and reoperation by 15% (RR = 1.15, CI: 1.08–1.23;  $p < 0.001$ ).

**Conclusions** ADM-assisted breast reconstruction more than doubled from 2012 to 2019. There are statistically higher complication rates of SSI (0.5%) and reoperation (1.4%) with ADM use in TE-based breast reconstruction, suggesting that reconstruction without ADM is safe when comparing immediate postoperative outcomes.

## Keywords

- ▶ tissue expander
- ▶ breast reconstruction
- ▶ outcomes
- ▶ acellular dermal matrix

received  
November 4, 2021  
accepted  
July 8, 2022

DOI <https://doi.org/10.1055/s-0042-1758638>.  
eISSN 2234-6171.

© 2022. The Korean Society of Plastic and Reconstructive Surgeons. All rights reserved.

This is an open access article published by Thieme under the terms of the Creative Commons Attribution-NonDerivative-NonCommercial-License, permitting copying and reproduction so long as the original work is given appropriate credit. Contents may not be used for commercial purposes, or adapted, remixed, transformed or built upon. (<https://creativecommons.org/licenses/by-nc-nd/4.0/>)

Thieme Medical Publishers, Inc., 333 Seventh Avenue, 18th Floor, New York, NY 10001, USA

## Introduction

In March 2021, the United States Food and Drug Administration (FDA) released a safety communication regarding acellular dermal matrix (ADM) products used in implant-based breast reconstruction.<sup>1</sup> This communication includes an important set of recommendations for reconstructive surgeons and reiterates that ADM has still not received approval for use in breast surgery. Despite its off-label use, ADM is becoming increasingly popular.<sup>2,3</sup>

ADM was introduced as an aid to subpectoral breast reconstruction to cover the inferior portion of the implant and improve cosmesis. Previously, implants placed in the subpectoral space required no additional mesh or support. Implant-based reconstruction was first described in the prepectoral plane just under the mastectomy skin flaps in the late 1960s into the 1980s<sup>4</sup> shortly after the introduction of silicone implants.<sup>4</sup> During the 1980s, implants were transitioned into the subpectoral space due to high complication rates and better aesthetics when compared with implants placed above the muscle.<sup>5</sup>

Over the past few years, the pendulum has swung back toward prostheses placement in the pre-pectoral plane due to decreased post-operative pain, decreased operative time, and reduced animation deformity.<sup>6</sup> Proponents have also suggested that the addition of ADM in the prepectoral plane helps with improving positioning, preventing device extrusion, decreasing capsular contracture, allowing for greater initial fill volume, having fewer visits for expansion, and achieving a shorter time to implant exchange.<sup>6</sup> Additionally, a study by Craig et al showed that the incidence of explantation of tissue expanders after radiation was significantly reduced when using ADM.<sup>7</sup>

Despite these perceived advantages of using ADM, it is imperative to keep in mind that the matrix has not received clearance from the FDA to be used in any capacity for any type of breast reconstruction. In fact, some of the same studies cited above have shown that patients receiving ADM during their reconstruction have higher complication rates, such as mastectomy skin necrosis, infection, and seroma.<sup>6,7</sup> While others have shown no difference in outcomes, including a study by Safran et al that showed patient satisfaction remained similar whether ADM was or was not used during breast reconstruction.<sup>8</sup> Ganesh Kumar et al have even argued that since there is no significant benefit in outcomes, the cost of using ADM outweighs any benefits it may confer.<sup>9</sup>

Considering the new FDA safety communication and these discrepancies in outcomes, we sought to look at a nationally representative large group of patients through the American College of Surgeons National Surgical Quality Improvement Program to understand the trends in the use of ADM in tissue expander placement for breast reconstruction from 2012 to 2019. Our aims were to (1) demonstrate how the use of ADM has changed over time and to (2) identify the differences in complications when ADM was and was not used.

## Methods

The study was exempted by our institution's Institutional Review Board (IRB#00068446). The American College of Surgeons National Surgical Quality Improvement Program database was queried for female patients with current procedural terminology (CPT) code 19357 to identify tissue expander-based breast reconstruction between 2012 and 2019. This database is a nationally validated, risk-adjusted, outcomes-based database aimed at improving the quality of surgical care. There are over 700 participating hospitals, and the data provided by the registry represents a sampling of both the participating hospitals and the total number of procedures performed by the individual hospitals, with up to 273 individual variables collected for each procedure. In-depth explanations of the American College of Surgeons National Surgical Quality Improvement Program methods have been previously reported.<sup>10</sup>

Patients were categorized into ADM and non-ADM-assisted tissue expander-based breast reconstruction cohorts. Outcomes included surgical site infection (SSI; superficial incisional, deep incisional, and organ/space), dehiscence (wound disruption), and reoperation (unplanned). The effect of ADM use was assessed after controlling for patient demographics (age, race), patient characteristics (obesity, American Society of Anesthesiologist Classification score [ASA class], history of diabetes, history of smoking), operative time in hours and in whether they had immediate versus delayed reconstruction. Obesity was defined as body mass index more than or equal to 30.0 kg/m<sup>2</sup>. Age was categorized by quartile. Exclusion criteria were body mass index outside of 1.5 interquartile (IQR) range (18.2–35.0), operating time outside of 1.5 IQR range (1.26–5.10 hours), and missing data from ASA classification, height, weight, or operating time. Any patient with CPT codes for mastectomy (19303, 19304, 19305, 19306, 19307) and tissue expander-based reconstruction (19357) was considered immediate; all others were classified as delayed.

► **Table 1** presents the descriptive statistics of the two breast reconstruction cohorts. Unadjusted comparison of surgical outcomes by cohort is shown in ► **Table 2**. For SSI, dehiscence, and reoperation, multivariable modified Poisson regression was used to assess the relationship between each outcome and ADM adjusting for covariates of interest. Predictor variables were selected based on clinical significance. The most common reoperation codes were identified for surgeries with and without ADM by calculating the percentage frequency of each CPT code in the primary and additional CPT fields (number of times code appeared/total number of non-missing codes CPT codes across primary and additional CPT fields). Percentage ADM use over time and results for test of trend are displayed in ► **Fig. 1**.

Two-sided significance for all tests was assessed at the *p* less than 0.05 level. All analyses were performed with R 4.0.3.

## Results

A total of 49,049 tissue expander-based breast reconstructive cases were included in the study with 42.4% (*n* = 20,776)

**Table 1** Demographic information of analyzed patients including age, white race, obesity status, ASA class, diabetes history, smoking history, operation time, timing of reconstruction

	Total, n (%)	ADM, n (%)	No ADM, n (%)	p-Value
<b>Total</b>	49,049 (100.0)	20,776 (42.4)	28,273 (57.6)	
<b>Age</b>				< 0.001
18–42	11,332 (23.1)	4,989 (24.0)	6,343 (22.4)	
43–49	11,433 (23.3)	4,918 (23.7)	6,515 (23)	
50–58	13,365 (27.2)	5,534 (26.6)	7,831 (27.7)	
59+	12,919 (26.3)	5,335 (25.7)	7,584 (26.8)	
<b>White race</b>				< 0.001
Yes	36,725 (74.9)	16,436 (79.1)	20,289 (71.8)	
No	12,324 (25.1)	4,340 (20.9)	7,984 (28.2)	
<b>Obese</b>				0.48
Yes	14,610 (29.8)	6,153 (29.6)	8,457 (29.9)	
No	34,439 (70.2)	14,623 (70.4)	19,816 (70.1)	
<b>ASA class of 3+</b>				0.01
Yes	11,687 (23.8)	5,065 (24.4)	6,622 (23.4)	
No	37,362 (76.2)	15,711 (75.6)	21,651 (76.6)	
<b>Diabetes</b>				< 0.001
Yes	2,870 (5.9)	1,126 (5.4)	1,744 (6.2)	
No	46,179 (94.1)	19,650 (94.6)	26,529 (93.8)	
<b>Smoker</b>				< 0.001
Yes	5,147 (10.5)	2,065 (9.9)	3,082 (10.9)	
No	43,902 (89.5)	18711 (90.1)	25,191 (89.1)	
<b>Operating time (h)</b>				< 0.001
Mean (SD)	3.2 (1.4)	3.5 (1.3)	3.1 (1.4)	
Range	0.0–7.1	0.0–7.1	0.0–7.1	
<b>Year</b>				< 0.001
2012	4,569 (9.3)	1,191 (5.7)	3,378 (11.9)	
2013	5,586 (11.4)	1,847 (8.9)	3,739 (13.2)	
2014	5,975 (12.2)	2,149 (10.3)	3,826 (13.5)	
2015	6,347 (12.9)	2,485 (12.0)	3,862 (13.7)	
2016	6,871 (14.0)	2,870 (13.8)	4,001 (14.2)	
2017	6,843 (14.0)	3,302 (15.9)	3,541 (12.5)	
2018	6,491 (13.2)	3,394 (16.3)	3,097 (11.0)	
2019	6,367 (13.0)	3,538 (17.0)	2,829 (10.0)	
<b>Timing of reconstruction</b>				<0.001
Immediate		16,658 (80.2)	18,141 (64.2)	
Delayed		4,118 (19.8)	10,132 (35.8)	

Abbreviations: ADM, acellular dermal matrix; ASA, American Society of Anesthesiologist; SD, standard deviation.

cases involving ADM and 57.6% ( $n = 28,273$ ) without ADM. A significant difference was seen between ADM and non-ADM groups in the distribution of age ( $p < 0.001$ ), race ( $p < 0.001$ ), ASA classification of 3+ ( $p = 0.01$ ), history of diabetes ( $p < 0.001$ ), history of smoking ( $p < 0.001$ ), operative time ( $p < 0.001$ ), the use of ADM in each year studied ( $p < 0.001$ ),

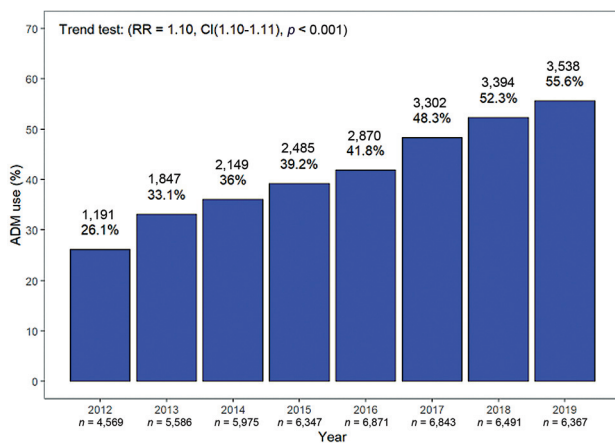
and if the patient underwent immediate reconstruction versus delayed reconstruction ( $p < 0.001$ ). No significant difference was seen in obesity ( $p = 0.48$ ) between the two cohorts (► **Table 1**).

Unadjusted outcome rates of the ADM and non-ADM cohorts showed significant relative risk differences for SSI

**Table 2** Outcomes of SSI, dehiscence, and reoperation with and without ADM

	ADM % (n) (N = 20,776)	No ADM % (n) (N = 28273)	p-Value
<b>SSI</b>			0.003
Yes	3.9 (817)	3.4 (969)	
No	96.1 (19,959)	96.6 (27,304)	
<b>Dehiscence</b>			0.73
Yes	0.7 (142)	0.7 (186)	
No	99.3 (20,634)	99.3 (28,087)	
<b>Reoperation</b>			< 0.001
Yes	7.4 (1,535)	6.0 (1,698)	
No	92.6 (19,241)	94.0 (26,575)	

Abbreviations: ADM, acellular dermal matrix; SSI, surgical site infection.



**Fig. 1** Rate of acellular dermal matrix (ADM) utilization for breast reconstruction over time. CI, confidence interval; RR, relative risk.

(3.9 vs. 3.4%;  $p=0.003$ ) and reoperation (7.4 vs. 6.0%;  $p<0.001$ ). However, there was no difference in dehiscence rates between cohorts (0.7 vs. 0.7%;  $p=0.73$ ; **Table 2**).

In the multivariate analysis, ADM use was associated with a significantly higher risk of SSI (relative risk [RR]=1.10, confidence interval [CI]: 1.01–1.21;  $p=0.03$ ). Other significant risk factors for SSI included obesity (RR = 1.79, CI: 1.63–1.97;  $p<0.001$ ), history of smoking (RR = 1.54, CI: 1.36–1.75;  $p<0.001$ ), ASA class 3+ (RR = 1.31, CI: 1.19–1.45;  $p<0.001$ ), history of diabetes (RR = 1.21, CI: 1.03–1.43;  $p=0.02$ ), White race (RR = 1.15, CI: 1.03–1.28;  $p=0.02$ ) compared with all other races, and longer operative time (RR = 1.10, CI: 1.06–1.13;  $p<0.001$ ) Patients who underwent immediate reconstruction showed significantly decreased risk of SSI (RR = 0.84, CI: 0.76–0.93;  $p=0.01$ ). Age was not significantly associated with SSI (**Table 3**).

ADM use (RR = 1.02, CI: 0.82–1.27;  $p=0.86$ ) was not significantly related to dehiscence after controlling for other variables of interest. However, history of smoking (RR = 2.21, CI: 1.69–2.89;  $p<0.001$ ), obesity (RR = 1.84, CI: 1.47–2.31;  $p<0.001$ ), history of diabetes (RR = 1.64, CI: 1.16–2.32;  $p=0.005$ ), and longer operative time (RR = 1.14, CI: 1.05–1.24;  $p=0.003$ ) were significant risk factors. Protective

factors against dehiscence were found to be younger age (ages 43–49 [RR = 0.61, CI: 0.44–0.84;  $p=0.002$ ]; ages 18–42 (RR = 0.73, CI: 0.54–0.99;  $p=0.04$ )), White race (RR = 0.79, CI: 0.62–1.00;  $p=0.048$ ), and if the patient underwent immediate reconstruction (RR = 0.71, CI: 0.56–0.89;  $p=0.004$ ) (**Table 3**).

For reoperation, ADM use (RR = 1.15, CI: 1.08–1.23;  $p<0.001$ ) was a significant risk factor. All variables of interest, except for younger age and immediate reconstruction, were associated with increased risk of reoperation, including history of smoking (RR = 1.53, CI: 1.39–1.67;  $p<0.001$ ), obesity (RR = 1.29, CI: 1.20–1.39;  $p<0.001$ ), history of diabetes (RR = 1.26, CI: 1.11–1.42;  $p<0.001$ ), White race (RR = 1.25, CI: 1.15–1.36;  $p<0.001$ ), ASA class 3+ (RR = 1.17, CI: 1.09–1.27;  $p<0.001$ ), operative time (RR = 1.17, CI: 1.14–1.20;  $p<0.001$ ), and ages 59 and older (RR = 1.09, CI: 1.00–1.19;  $p=0.051$ ). Compared with the referent group of 50 to 58 years old, age groups 18 to 42 years old (RR = 0.83, CI: 0.75–0.92;  $p<0.001$ ) and 43 to 49 years old (RR = 0.90, CI: 0.82–0.99;  $p=0.02$ ) demonstrated significantly lower risk of dehiscence (**Table 3**).

The most common reoperation codes for the ADM cohort were CPT codes 11971 (17.6%) for removal of tissue expander without insertion of implant; 10140 (15.8%) for incision and drainage of hematoma, seroma, or fluid collection; 11042 (10.3%) for debridement, subcutaneous tissue (includes epidermis and dermis, if performed; first 20 cm<sup>2</sup> or less, 19380 (9.4%) for revision of reconstructed breast, and 21501 (4.4%) for incision and drainage, deep abscess or hematoma, soft tissues of neck or thorax. The most common reoperation codes for the non-ADM cohort were CPT codes 10140 (21.6%), 11971 (14.9%), 11042 (9.5%), 19380 (8.5%), and 19020 (5.8%) for mastectomy with exploration or drainage of abscess (**Table 4**).

ADM use in breast reconstruction showed significant growth from 26.1% ( $n=1,191$ ) in 2012 to 55.5% ( $n=3,538$ ) in 2019 (RR = 1.10, CI: 1.10–1.11;  $p<0.001$ ; **Fig. 1**).

## Discussion

With the growing popularity of ADM-assisted breast reconstruction and the recent FDA safety communication stating

**Table 3** Multivariate analysis evaluating SSI, dehiscence, and reoperation outcomes with and without ADM

	SSI (RR)	p-Value	Dehiscence (RR)	p-Value	Reoperation (RR)	p-Value
Age 18–42	0.98 (0.86–1.12)	0.76	0.73 (0.54–0.99)	0.04	0.83 (0.75–0.92)	<0.001
Age 43–49	0.90 (0.79–1.03)	0.11	0.61 (0.44–0.84)	0.002	0.90 (0.82–0.99)	0.02
Age 50–58 (ref)	1		1		1	
Age 59+	1.08 (0.95–1.22)	0.23	0.84 (0.63–1.10)	0.20	1.09 (1.00–1.19)	0.051
White race	1.15 (1.03–1.28)	0.02	0.79 (0.62–1.00)	0.048	1.25 (1.15–1.36)	<0.001
Obese	1.79 (1.63–1.97)	<0.001	1.84 (1.47–2.31)	<0.001	1.29 (1.20–1.39)	<0.001
ASA class of 3+	1.31 (1.19–1.45)	<0.001	1.25 (0.98–1.59)	0.07	1.17 (1.09–1.27)	<0.001
Diabetes	1.21 (1.03–1.43)	0.02	1.64 (1.16–2.32)	0.005	1.26 (1.11–1.42)	<0.001
Smoker	1.54 (1.36–1.75)	<0.001	2.21 (1.69–2.89)	<0.001	1.53 (1.39–1.67)	<0.001
Operating time (h)	1.10 (1.06–1.13)	<0.001	1.14 (1.05–1.24)	0.003	1.17 (1.14–1.20)	<0.001
Immediate reconstruction	0.84 (0.76–0.93)	0.001	0.71 (0.56–0.89)	0.004	0.99 (0.92–1.07)	0.81
ADM	1.10 (1.01–1.21)	0.03	1.02 (0.82–1.27)	0.86	1.15 (1.08–1.23)	<0.001

Abbreviations: ADM, acellular dermal matrix; ASA, American Society of Anesthesiologist; RR, relative risk; SSI, surgical site infection.

**Table 4** Most common reoperation codes utilized between the with and without ADM cohorts

	CPT codes	Definition	% of cases (n)
ADM reoperation codes	11971	Removal of tissue expander without insertion of implant	17.6 (254)
	10140	Incision and drainage of hematoma, seroma, or fluid collection	15.8 (228)
	11042	Debridement, subcutaneous tissue (includes epidermis and dermis, if performed; first 20 cm <sup>2</sup> or less	10.3 (148)
	19380	Revision of reconstructed breast (e.g., significant removal of tissue, readvancement and/or reinsert of flaps in autologous reconstruction or significant capsular revision combined with soft tissue excision in implant-based reconstruction)	9.4 (135)
	21501	Incision and drainage, deep abscess or hematoma, soft tissues of neck, or thorax	4.4 (64)
No ADM reoperation codes	10140	Incision and drainage of hematoma, seroma, or fluid collection	21.6 (341)
	11971	Removal of tissue expander without insertion of implant	14.9 (236)
	11042	Debridement, subcutaneous tissue (includes epidermis and dermis, if performed; first 20 cm <sup>2</sup> or less	9.5 (151)
	19380	Revision of reconstructed breast (e.g., significant removal of tissue, re-advancement and/or re-inset of flaps in autologous reconstruction or significant capsular revision combined with soft tissue excision in implant-based reconstruction)	8.5 (135)
	19020	Mastotomy with exploration or drainage of abscess, deep	5.8 (91)

Abbreviations: ADM, acellular dermal matrix; CPT, current procedural terminology.

the use of the product may result in higher chances of complications, this begs the question of whether the benefits of using ADM outweigh the risks. Importantly, the FDAs conclusion is based on patient cases who underwent immediate, implant-based reconstruction in the submuscular plane, whereas the current study analyzes ADM use in tissue expander-based breast reconstruction.<sup>1</sup> We aim to utilize a national database to assess the safety profile and complication risks of ADM-assisted breast reconstruction.

### Difficulty in Comparing Studies

ADM is derived from porcine, bovine, or human cadaver skin. A decellularization process removes cells and antigenic components and leaves behind the extracellular matrix that provides structural support for vascular and tissue ingrowth when used in the human body.<sup>11,12</sup> The different ADM processing methods across companies and evolving technologies have resulted in multiple products on the market with various levels of sterility, biomechanical

properties, and preparation instructions prior to clinical application.<sup>1</sup> ADM was first introduced in breast reconstruction as a sling and inferior pole support for submuscular implant placement.<sup>13</sup> In recent years, pre-pectoral placement of implants has grown in popularity where ADM is employed for the anterior coverage or the entire wrapping of the prosthesis.<sup>13</sup> Furthermore, the entire sheet of ADM can be utilized, or fenestrations or meshing modifications can be applied.<sup>1</sup> The heterogeneity in patient selection, ADM types, processing methods and modifications, surgical technique, and surgeon's learning curves pose a challenge in comparing studies and deciphering complications risks. Hallberg et al's systematic review on ADM use in breast reconstruction found low certainty of evidence on overall complication rates and concluded that there is a lack of high-quality studies in this area.<sup>14</sup>

### ADM Trends

With the additional data from Winocour et al's<sup>2</sup> National Surgical Quality Improvement Program study on ADM-assisted breast reconstruction, the adjunct of ADM in breast reconstruction grew from 0% in 2005 to 55.6% in 2019. Furthermore, a survey study of the American Society of Plastic Surgeon members demonstrated the popularity of the product, with 84.2% of respondents using ADM in their breast reconstructive procedures.<sup>3</sup> Our study had a total of 49,049 tissue-expander breast reconstructive cases, with 42.2% involving ADMs.

### Complications: ADM versus None

In our study, the use of ADM in breast reconstruction saw statistically significant higher rates and increased risk of experiencing SSI by 0.5% and reoperations by 1.4%. Though these are statistically significant differences, these small clinical differences may not be large enough to suggest that ADM use in breast reconstruction is unsafe. Rather, our data suggests that breast reconstruction outcomes without ADM use are the same if not just slightly better than cases where ADM is used. A different study utilizing the National Surgical Quality Improvement Program dataset found that from 2005 to 2011 found similar results, that patients who underwent immediate tissue expander breast reconstruction with ADM had significantly more SSIs than those who were reconstructed without ADM (4.5 vs. 3.2%,  $p = 0.005$ ).<sup>2</sup> Contrarily, a few other National Surgical Quality Improvement Program reports on ADM use in breast reconstruction in study periods prior to ours found no increased risks in SSI or overall complications.<sup>2,15</sup> Both had a smaller sample size of ADM-assisted breast reconstruction cases that may have been underpowered to detect any differences in complications ( $n = 1,717-3,301$ ).<sup>2,3,15</sup> Most meta-analyses looking at complications have consistently found higher risks of flap necrosis,<sup>16-18</sup> infection,<sup>16-18</sup> seroma,<sup>16-19</sup> reconstructive failure,<sup>16-18</sup> and total complications.<sup>16,17</sup> Furthermore, a randomized controlled trial of implant-based breast reconstruction with and without ADM found higher risks of wound healing problems.<sup>20</sup> However, complications of hematoma,<sup>18</sup> implant explanation,<sup>17</sup> reoperation,<sup>17</sup> and cellulitis<sup>18</sup> were

inconclusive or did not see an increase. In our study, dehiscence was not associated with ADM use. This may be attributed to the practices of surgeons, where necrosis of the skin flap or concerns of the incision line would be brought in for reoperation before dehiscence occurs. Hematoma complication was explored in our study; however, the incidences were too small for an accurate analysis. Additionally, in our study, CPT code frequencies were explored which match prior studies of ADM use and non-ADM use resulting in similar proportions of implant removal.

### Benefits of ADM

Capsular contracture is one of the most common reasons for reoperations after breast surgery and ADM in breast reconstruction has shown reduced incidence of capsular contracture. A meta-analysis found a 0.6% reduced rate or a 3- to 40-fold lower incidence of capsular contracture.<sup>21</sup> It is speculated that the protective layer provided by the ADM between the implant and native tissue helps to slow the inflammatory process and limits the pathogenesis. However, with the growing popularity of meshing the matrix for better expansion and lower costs,<sup>22</sup> this ADM-assisted advantage in breast reconstruction may no longer exist. Currently, only one study by Maisel Lotan et al assessed fenestrated versus meshed ADM and found no differences in capsular contracture rates (2.7 vs. 5.2%;  $p = 0.342$ ).<sup>23</sup>

The etiology of capsular contracture is most likely multifactorial, and the cause is still being elucidated, but there is a hypothesis of biofilm-producing bacteria accelerating the process of capsular contracture formation.<sup>24</sup> Studies investigating the role of prophylactic or postoperative antibiotics, local antibiotics and/or irrigation, and funnel insertion of the implant in breast reconstruction in reducing capsular contracture incidences suggest some truth to this theory.<sup>24,25</sup> This can be concerning since higher infection rates are seen in ADM-assisted breast reconstruction in both our study and meta-analyses.<sup>16-18</sup> Contrarily, Hidalgo and Weinstein demonstrated superior success in treating capsular contracture in breast augmentation patients with ADM over the conventional treatment of capsulectomies.<sup>26</sup> Perhaps clearer indications and better patient selection should be considered in terms of the application of ADM in breast reconstructions.

### Cost of ADM

The cost of ADM is a major drawback for its use. Depending on the brand, the price can range from approximately \$22 to \$34 per cm<sup>2</sup>.<sup>21</sup> Proponents argue that the initial cost can be offset by the substantial improvement in patient outcomes. The advantages of improved positioning, greater initial fill volume, prevention of device extrusion, fewer visits for expansion, and shorter time to implant exchange are thought to be substantial benefits for the patient. However, a recent randomized controlled trial found no acceleration of postoperative expansion rate.<sup>27</sup> Another study found a lower number of fills in the ADM-assisted group compared with the non-ADM group (3.6 vs. 6.5;  $p < 0.0001$ ); however, the study still concluded that the direct cost of the ADM does not offset the cost-saving from the reduced number of visits.<sup>28</sup> The use of ADM in certain scenarios can be

more cost-effective. A comparative cost analysis by de Blacam et al found that one-stage breast reconstruction with ADM cost the least compared with both two-staged breast reconstruction with and without ADM.<sup>29</sup> Overall, cost analysis methodologies varied across studies making it difficult to elucidate scenarios where ADM is a cost-effective addition to breast reconstruction.<sup>30</sup>

### Limitations

There are several limitations to this study. This is a retrospective study; therefore, further high-quality prospective or randomized controlled trial studies are needed to answer the proposed questions. Furthermore, limitations in utilizing the National Surgical Quality Improvement Program database for research have been well-reported.<sup>31</sup> The database is not designed to measure specialty-specific outcomes; therefore, outcomes important to breast reconstruction such as rates of seroma, flap necrosis, reconstructive failure, red breast syndrome, cellulitis, and capsular contracture could not be determined. The database also does not record the ADM type used, the plane in which the ADM is set (complete submuscular vs. subpectoral vs. dual plane), modifications done, or surgical technique performed, which can impact patient outcomes. The FDA has suggested that certain brands of ADM may have a higher risk profile than others.<sup>1</sup> Lastly, complications were only tracked postoperatively for 30 days; therefore, complications that occurred after 30 days were not included in the study.

In the United States, from 2012 to 2019, the use of ADM in breast reconstruction more than doubled. There are statistically higher complication rates of SSI (0.5%) and reoperation (1.4%) with ADM use in tissue expander-based breast reconstruction. This data suggests that breast reconstruction without ADM can be performed safely when comparing immediate postoperative outcomes.

### Patient Consent

The patients provided written informed consent for the publication and the use of their images.

### Ethical Approval

This study was provided an exemption from the University of Utah IRB.

### Authors' Contributions

The conceptualization of the goals/aims of the article were driven by Alvin Kwok, Jayant Agarwal, Jessica Luo, Megan Rosales, Gregory Stoddard, and Irfan Rhemtulla. Whitney Moss and Giovanna Pires were involved in drafting, revising, and approving the final version for submission.

### Financial Disclosure Statement

Dr. Jayant Agarwal is a consultant for DonJoy Orthopedics, which is unrelated to this article. The remainder of the authors have nothing to disclose.

### Conflict of Interest

None declared.

### References

- 1 Acellular Dermal Matrix (ADM) Products Used in Implant-Based Breast Reconstruction Differ in Complication Rates. FDA Safety Communication. Accessed April 24, 2021, at: <https://www.fda.gov/medical-devices/safety-communications/acellular-dermal-matrix-adm-products-used-implant-based-breast-reconstruction-differ-complication>
- 2 Winocour S, Martinez-Jorge J, Habermann E, Thomsen K, Lemaine V. Early surgical site infection following tissue expander breast reconstruction with or without acellular dermal matrix: national benchmarking using national surgical quality improvement program. *Arch Plast Surg* 2015;42(02):194–200
- 3 Ibrahim AM, Koolen PG, Ashraf AA, et al. Acellular dermal matrix in reconstructive breast surgery: survey of current practice among plastic surgeons. *Plast Reconstr Surg Glob Open* 2015;3(04):e381
- 4 Uroskie TW, Colen LB. History of breast reconstruction. *Semin Plast Surg* 2004;18(02):65–69
- 5 Gruber RP, Kahn RA, Lash H, Maser MR, Apfelberg DB, Laub DR. Breast reconstruction following mastectomy: a comparison of submuscular and subcutaneous techniques. *Plast Reconstr Surg* 1981;67(03):312–317
- 6 DeLong MR, Tandon VJ, Bertrand AA, et al. Review of outcomes in prepectoral prosthetic breast reconstruction with and without surgical mesh assistance. *Plast Reconstr Surg* 2021;147(02):305–315
- 7 Craig ES, Clemens MW, Koshy JC, et al. Outcomes of acellular dermal matrix for immediate tissue expander reconstruction with radiotherapy: a retrospective cohort study. *Aesthet Surg J* 2019;39(03):279–288
- 8 Safran T, Al-Halabi B, Viezel-Mathieu A, Boileau JF, Dionisopoulos T. Skin-reducing mastectomy with immediate prepectoral reconstruction: surgical, aesthetic, and patient-reported outcomes with and without dermal matrices. *Plast Reconstr Surg* 2021;147(05):1046–1057
- 9 Ganesh Kumar N, Berlin NL, Kim HM, Hamill JB, Kozlow JH, Wilkins EG. Development of an evidence-based approach to the use of acellular dermal matrix in immediate expander-implant-based breast reconstruction. *J Plast Reconstr Aesthet Surg* 2021;74(01):30–40
- 10 Surgeons AC. User Guide for the 2016 ACS NSQIP Participant Use File. 2018
- 11 Wong AK, Schonmeyer BH, Singh P, Carlson DL, Li S, Mehrara BJ. Histologic analysis of angiogenesis and lymphangiogenesis in acellular human dermis. *Plast Reconstr Surg* 2008;121(04):1144–1152
- 12 Daar DA, Gandy JR, Clark EG, Mowlds DS, Paydar KZ, Wirth GA. Plastic surgery and acellular dermal matrix: highlighting trends from 1999 to 2013. *World J Plast Surg* 2016;5(02):97–108
- 13 Margulies IG, Salzberg CA. The use of acellular dermal matrix in breast reconstruction: evolution of techniques over 2 decades. *Gland Surg* 2019;8(01):3–10
- 14 Hallberg H, Rafnsdottir S, Selvaggi G, et al. Benefits and risks with acellular dermal matrix (ADM) and mesh support in immediate breast reconstruction: a systematic review and meta-analysis. *J Plast Surg Hand Surg* 2018;52(03):130–147
- 15 Ibrahim AMS, Shuster M, Koolen PGL, et al. Analysis of the National Surgical Quality Improvement Program database in 19,100 patients undergoing implant-based breast reconstruction: complication rates with acellular dermal matrix. *Plast Reconstr Surg* 2013;132(05):1057–1066
- 16 Bi S, Liu R, Wu B, et al. Breast implants for mammoplasty: an umbrella review of meta-analyses of multiple complications. *Aesthetic Plast Surg* 2020;44(06):1988–1996
- 17 Lee KT, Mun GH. Updated evidence of acellular dermal matrix use for implant-based breast reconstruction: a meta-analysis. *Ann Surg Oncol* 2016;23(02):600–610

- 18 Ho G, Nguyen TJ, Shahabi A, Hwang BH, Chan LS, Wong AK. A systematic review and meta-analysis of complications associated with acellular dermal matrix-assisted breast reconstruction. *Ann Plast Surg* 2012;68(04):346–356
- 19 Jordan SW, Khavanin N, Kim JYS. Seroma in prosthetic breast reconstruction. *Plast Reconstr Surg* 2016;137(04):1104–1116
- 20 Lohmander F, Lagergren J, Roy PG, et al. Implant based breast reconstruction with acellular dermal matrix: safety data from an open-label, multicenter, randomized, controlled trial in the setting of breast cancer treatment. *Ann Surg* 2019;269(05):836–841
- 21 Gravina PR, Pettit RW, Davis MJ, Winocour SJ, Selber JC. Evidence for the use of acellular dermal matrix in implant-based breast reconstruction. *Semin Plast Surg* 2019;33(04):229–235
- 22 Scheffan M, Allweis TM, Ben Yehuda D, Maisel Lotan A. Meshed acellular dermal matrix in immediate prepectoral implant-based breast reconstruction. *Plast Reconstr Surg Glob Open* 2020;8(11):e3265
- 23 Maisel Lotan A, Ben Yehuda D, Allweis TM, Scheffan M. Comparative study of meshed and nonmeshed acellular dermal matrix in immediate breast reconstruction. *Plast Reconstr Surg* 2019;144(05):1045–1053
- 24 Bachour Y, Bargon CA, de Blok CJM, Ket JCF, Ritt MJPF, Niessen FB. Risk factors for developing capsular contracture in women after breast implant surgery: a systematic review of the literature. *J Plast Reconstr Aesthet Surg* 2018;71(09):e29–e48
- 25 Headon H, Kasem A, Mokbel K. Capsular contracture after breast augmentation: an update for clinical practice. *Arch Plast Surg* 2015;42(05):532–543
- 26 Hidalgo DA, Weinstein AL. Surgical treatment for capsular contracture: a new paradigm and algorithm. *Plast Reconstr Surg* 2020;146(03):516–525
- 27 Dikmans RE, Negenborn VL, Bouman MB, et al. Two-stage implant-based breast reconstruction compared with immediate one-stage implant-based breast reconstruction augmented with an acellular dermal matrix: an open-label, phase 4, multicentre, randomised, controlled trial. *Lancet Oncol* 2017;18(02):251–258
- 28 Bank J, Phillips NA, Park JE, Song DH. Economic analysis and review of the literature on implant-based breast reconstruction with and without the use of the acellular dermal matrix. *Aesthetic Plast Surg* 2013;37(06):1194–1201
- 29 de Blacam C, Momoh AO, Colakoglu S, Slavin SA, Tobias AM, Lee BT. Cost analysis of implant-based breast reconstruction with acellular dermal matrix. *Ann Plast Surg* 2012;69(05):516–520
- 30 Aliotta RE, Duraes EFR, Scomacao I, et al. A controlled cost and outcomes analysis of acellular dermal matrix and implant-based reconstruction. *J Plast Reconstr Aesthet Surg* 2020;74(06):1229–1238
- 31 Alluri RK, Leland H, Heckmann N. Surgical research using national databases. *Ann Transl Med* 2016;4(20):393