



Comparison of Patients Satisfaction with Direct to Implant versus Latissimus Dorsi Flap with Implant Breast Reconstruction Using Breast-Q

Ji Min Kim, MD¹ Woo Jin Song, MD¹ Sang Gue Kang, PhD¹

¹Department of Plastic and Reconstructive Surgery, Soonchunhyang University Hospital, Seoul, Korea

Arch Plast Surg 2022;49:710–715.

Address for correspondence Sang Gue Kang, MD, PhD, Department of Plastic and Reconstructive Surgery, Soonchunhyang University Hospital, 59, Daesagwan-ro, Yongsan-gu, Seoul 04401, Korea (e-mail: sgkang@schmc.ac.kr).

Abstract

Background The latissimus musculocutaneous flap (LD flap) is a useful option for breast reconstruction following mastectomy. It has the advantage of obtaining sufficient tissue padding and natural shape by using autologous tissue. However, with the emergence of the skin-sparing mastectomy technique and artificial dermis matrix, direct-to-implant (DTI) breast reconstruction has become the first choice of surgery. The purpose of this study was to compare the satisfaction levels of patients who underwent DTI and LD flap with implant using patient-reported Breast-Q results. **Methods** A retrospective study was performed reviewing the records of 49 women who underwent immediate breast reconstruction with DTI or LD flap with implant and responded to the BREAST-Q questionnaire after the operation. The patient-reported breast-Q results were analyzed and correlated to the demographic information and intraoperative information.

Results A total of 26 patients who underwent reconstruction with LD flap with implant and 23 patients with DTI were identified and responded to the questionnaire after an average of 32.3 and 10.4 months postoperation, respectively. According to the patient response to the breast-q values, satisfaction with breast was 60.0 and 57.0 points, psychosocial well-being 61.0 and 60.0 points, and sexual well-being 41.0 and 43.0 points in the two groups. Overall, there was no significant difference in the breast-Q score between the two groups.

Conclusion Patients who underwent DTI breast reconstruction seemed equally satisfied with the appearance and outcome of their breast reconstruction compared with LD flap with implant. Therefore, it appears that DTI is adequately replacing LD with implant.

Keywords

- ▶ direct to implant
- ▶ latissimus dorsi musculocutaneous flap
- ▶ breast-Q

Introduction

The latissimus dorsi musculocutaneous flap (LD flap) is a reliable and versatile reconstruction choice for breast recon-

struction. The LD flap can be used with implant together to compensate for insufficient volumes after various types of mastectomy.¹ There was an advantage of obtaining sufficient tissue padding and natural shape by using autologous tissue.

received
June 28, 2021
accepted after revision
November 7, 2022

DOI <https://doi.org/10.1055/s-0042-1744420>.
eISSN 2234-6171.

© 2022. The Korean Society of Plastic and Reconstructive Surgeons. All rights reserved.

This is an open access article published by Thieme under the terms of the Creative Commons Attribution-NonDerivative-NonCommercial-License, permitting copying and reproduction so long as the original work is given appropriate credit. Contents may not be used for commercial purposes, or adapted, remixed, transformed or built upon. (<https://creativecommons.org/licenses/by-nc-nd/4.0/>)

Thieme Medical Publishers, Inc., 333 Seventh Avenue, 18th Floor, New York, NY 10001, USA

With the development of mastectomy techniques such as skin-sparing mastectomy or nipple-sparing mastectomy, the quality of the mastectomy skin flap has improved, and, at the same time, commercialization of the acellular dermis matrix (ADM) and the expansion of insurance coverage for total mastectomy have led to an increase in the rate of direct to implant (DTI).² LD flap with implant was mainly used for breast reconstruction until 2018, but subpectoral DTI became the mainstream after 2018 in our institution. This is a change only in the surgical trend for the same indication. Currently, we consider LD flap with implant as the first option only when performing mastectomy including skin excision that is too large for primary closure and mostly have been replaced with reconstruction using tissue expander or implant with ADM. In most cases, DTI showed good postoperative results with no donor site morbidity and short operation time, but LD flap with implant was thought to have more natural contour results for breast with thinner skin or ptosis. The purpose of this study is to compare the difference in satisfaction levels between the patient groups who underwent DTI and LD flap with implant by patient-reported Breast-Q results.

Methods

Study Design

A retrospective, single-center study was conducted on 49 patients with breast-Q after breast reconstruction using DTI or LD flap with implant from June 2018 to December 2020. The study was approved by the Institutional Review Board of Soonchunhyang University Hospital (IRB No. 2017-09-020) and was performed in accordance with the principles of the Declaration of Helsinki.

Patients

Inclusion and exclusion criteria

The inclusion criteria were the following:

- Patients at least 6 months after immediate breast reconstruction with dual-plane DTI or LD flap with implant surgery at the ***University Hospital.

- Patients who completed the Breast-Q postoperative module between June 2018 and December 2020.

The exclusion criteria were the following:

- Patients who underwent contralateral breast surgery.
- Patient who underwent a two-stage breast reconstruction using tissue expanders.

For all LD implant surgeries, the skin island of the LD flap was designed and harvested to cover the implant without manipulation for the pectoralis major muscle (→ Fig 1). For all DTI operations, dual-plane techniques were used, with some of them placed underneath dissected pectoralis major muscle and the rest under mastectomy skin, and the lower poles were supported with ADM (typically 8 × 16 cm size) being partially overlapped over the muscle (→ Fig 2).

Through chart review, demographic and clinical information was collected on the patient's age, hospitalization period, postoperative follow-up period, and postoperative radiotherapy. Operative information, such as mastectomy specimen weight, implant size, operation time, postoperative complications, and cost of surgery, was also collected. Only major complications requiring reoperation such as grade 3 or 4 capsular contracture, implant rupture, and skin necrosis were included. A case in which reoperation was performed due to patient dissatisfaction with the size and shape, except for the above-mentioned complications, was considered a secondary aesthetic procedure. Among the BREAST-Q 2.0 postoperative module, the converted scores were compared between the group with DTI and the group with LD flap for satisfaction with breast, psychosocial well-being, and sexual well-being items. In addition, five postoperative photos were taken at the time the breast-Q was given, and the medical staff consisting of three plastic surgeons, one surgeon, and one nurse scored from worst (1 point) to best (10 points) for each item using the aesthetic item scale (volume, shape, symmetry, scar, and nipple-areolar complex), and the total score was calculated and compared (→ Fig 3).

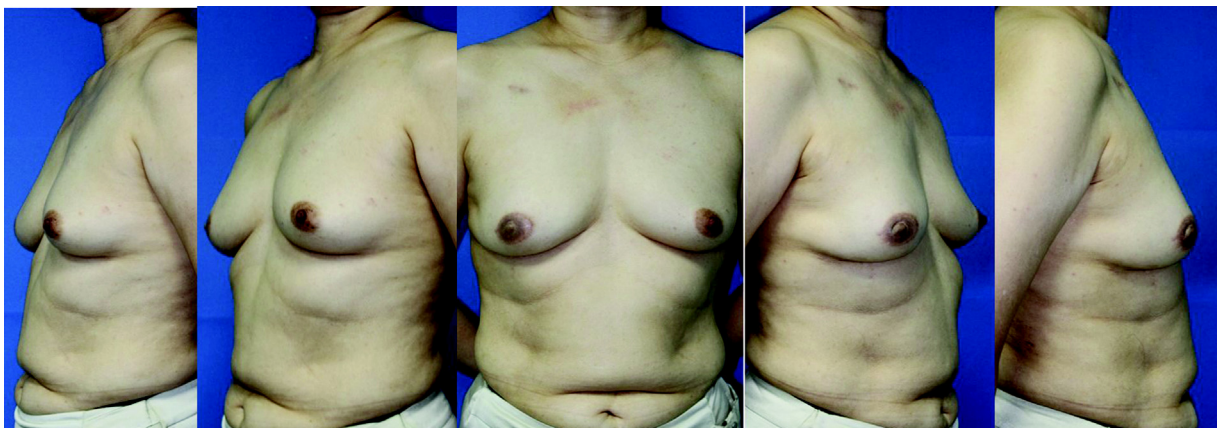

Fig. 1 Postoperative follow-up photograph taken 2 years after breast reconstruction: the LD musculocutaneous flap with implant (Bellagel round smooth type; low projection; 200 mL) after skin-sparing mastectomy with nipple-areolar complex (NAC) excision on right breast.

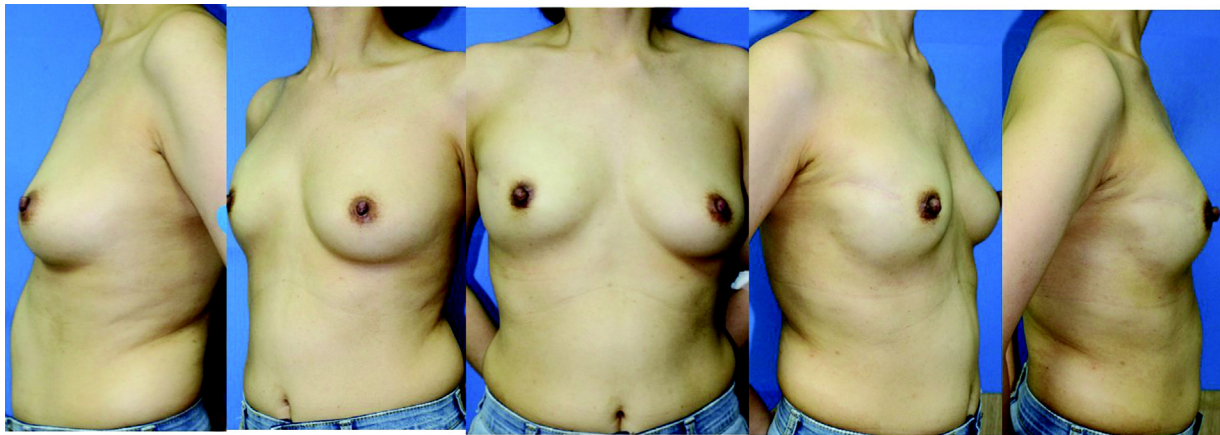


Fig. 2 Postoperative follow-up photograph taken 1 year after breast reconstruction: the dual-plane direct to implant (Bellagel round smooth type; medium projection; 325 mL) after nipple-sparing mastectomy with 4 × 1 cm skin excision on right breast.

Volume	10	9	8	7	6	5	4	3	2	1
Shape	10	9	8	7	6	5	4	3	2	1
Symmetry	10	9	8	7	6	5	4	3	2	1
Scar	10	9	8	7	6	5	4	3	2	1
Nipple-areolar complex	10	9	8	7	6	5	4	3	2	1
Total AIS score										

Fig. 3 Aesthetic item scales (AIS score).

Statistical Analysis

Statistical analysis was conducted using SPSS version 24.0 (IBM Corp., Armonk, New York, United States). The analysis was conducted through Fisher's exact test, independent two-sample test, and Mann-Whitney *U* test. A *p*-value less than 0.05 was considered statistically significant.

Results

Of the 49 patients who underwent breast reconstruction and responded to Breast-Q questionnaire, there were 26 (53.1%) LD flap with implant patients and 23 (46.9%) DTI patients. A total of 26 patients with LD flap and 23 patients with DTI were identified and responded to the questionnaire after an average of 32.3 and 10.4 months after surgery, respectively. The mean age of the patients who received LD flap with the implant was 46.6 years, the mean body mass index (BMI) was 22.9 kg/m², and the hospital stay was 10.4 days. The average age of the group that underwent DTI was 48.0 years, the mean BMI was 21.6 kg/m², and the length of hospital stay was 9.7 days. The proportion of patients receiving radiotherapy was 15.4% for LD flap with implant, which was higher than 4.3% for the DTI group, but it was not statistically significant (►Table 1). Also, the average weight of the mastectomy specimen was 255.9g in the LD flap with

implant group and 217.4g in the DTI group, and there was no significant difference. In all, 34.6% of the LD flap with implant group reconstructed the defect along with the skin paddle. Since there was no difference in the weight of the mastectomy specimen, the size of the implant used in the LD flap with implant group was smaller than that of the DTI group due to the characteristics of the operation. The average operation time for the group with LD flap with implant was 177.5 minutes, which was significantly longer than that for the DTI group (78.8 minutes). The operation costs for the DTI group was ~3.7 million won, which was higher than the LD flap with implant group (~2.4 million won), which was mainly due to the ADM price (►Table 2). The difference in follow-up period between the two groups was significant due to changes in surgical trends. Although the difference in follow-up period was not considered, the surgical complication rates of the two groups were 15.3 and 13.0%, indicating no statistically significant difference. In patients who underwent the secondary aesthetic procedure, 3.8 and 4.3%, were replaced with implants of different sizes, and fat grafting was performed if necessary (►Table 1). Therefore, there were no differences between characteristics of the patient groups except for differences due to the surgical method and trends.

Comparing the values of breast-Q in the group with LD flap with implant and the DTI group, satisfaction with the

Table 1 Demographic data and clinical information

Demographic data and clinical information		LD flap with implant	DTI	p-Value
N (%)		26	23	
Follow-up period (mo)		32.3 ± 23.0	10.4 ± 8.2	< 0.001
Age (y)		46.6 ± 6.4	48.0 ± 8.7	0.527
BMI (kg/m ²)		22.9 ± 2.7	21.6 ± 2.3	0.094
Hospitalization period (d)		10.4 ± 2.7	9.7 ± 1.5	0.261
Postoperative radiation therapy (%)		15.4%	4.3%	0.353
Postoperative complication	Capsular contracture grade 3 or 4 (%)	11.5%	0	
	Implant rupture (%)	3.8%	8.7%	
	Skin necrosis (%)	0	4.3%	
	Total (%)	15.3%	13.0%	0.308
Secondary aesthetic procedure	Asymmetry (%)	3.8%	4.3%	

Abbreviations: DTI, direct to implant; LD, latissimus dorsi musculocutaneous flap.
Note: Values are presented as mean ± SD.

Table 2 Operative data

Operative date		LD flap with implant	DTI	p-Value
Mastectomy type	NSM	69.3%	78.3%	0.475
	SSM	30.7%	21.7%	
Mastectomy specimen (g)		255.9 ± 80.5	217.4 ± 88.5	0.121
Implants size (mL)		149.6 ± 52.3	222.2 ± 80.3	< 0.001
Operation time (min)		177.5 ± 35.9	78.8 ± 24.2	< 0.001
Operation cost (₩) Patient copayment		2,434,328 (operation fee + implant cost)	3,691,917 (operation fee/ADM (8 × 16 cm)/implant cost)	

Abbreviations: DTI, direct to implant; LD, latissimus dorsi musculocutaneous flap; NSM, nipple-sparing mastectomy; SSM, skin-sparing mastectomy.
Note: Values are presented as mean ± SD.

breast was 60.0 and 57.0 points, psychosocial well-being was 61.0 and 60.0 points, and sexual well-being was 41.0 and 43.0 points, respectively. There was no significant difference between the two groups. Also, the combined values were 165.0 and 175.5 points for the two groups, showing no significant difference. Interestingly, the results of the aesthetic item scale, in which the medical staff evaluated the appearance on postoperative photographs, also showed no significant difference with 47.7 and 47.2 points (→ **Table 3**).

Discussion

The LD flap has been widely used as a breast reconstruction method suitable for Korean women because it can show better cosmetic results in women with low to normal BMI and small to moderate breast size.³ Compared with DTI, LD flap with implant has the following advantages. It shows better aesthetic results when there is ptosis or thin skin flap, provides additional skin, and shows low capsular contracture rate and infection rate.^{1,3} The skin-sparing mastectomy technique, which leaves skin as much as possible, and ADM, which can reinforce lower pole, could solve the problem with skin flap.⁴ ADM is also known to reduce capsular

contracture.⁵ Therefore, only the reconstructive surgery method was naturally changed to DTI with relatively short surgery and recovery time without significant changes in the patient group.

The only difference in indication is that, if there is a possibility of radiotherapy after surgery, a two-stage reconstruction using an expander is performed in our institution. There is still controversy about this. Therefore, in this study, the postoperative radiotherapy rate was high in the group with LD flap with implant, but there was no statistically significant difference. In one study, when comparing the complication rates according to the difference in surgical method between patients who underwent radiotherapy after mastectomy, the single-stage DTI had a lower complication rate than the two-stage DTI, and showed results similar to autologous reconstruction.⁶

Compared with the DTI, the LD flap was known to have a longer recovery period, but there was no difference in the length of hospital stay. This may be thought to have an effect on the absence of manipulation for pectoralis major muscle for the LD flap with implant group.

Due to the change in surgical trend, the period when LD flap with implant and DTI were mainly performed is

Table 3 Breast-Q postoperative module score and total visual score (aesthetic item scale score)

		LD flap with implant	DTI	p-Value
Breast-Q score	Satisfaction with breast	60.0 (51.0–68.5)	57.0 (49.5–66.0)	0.85
	Psychosocial well-being	61.0 (52.0–78.5)	60.0 (46.0–75.5)	0.71
	Sexual well-being	41.0 (31.75–60.5)	43.0 (24.0–49.0)	0.55
	Total	165.0 (146.0–219.5)	175.5 (138.8–187.8)	0.77
Aesthetic item scale score	Overall aesthetic outcome	7.6(7.2–8.2)	7.8(7.0–8.2)	0.92
	Volume	8.4 (8.0–8.55)	8.4 (8.1–8.6)	0.67
	Shape	7.8 (7.4–8.15)	8.0 (7.3–8.2)	0.94
	Symmetry	8.1 (7.3–8.75)	8.4 (7.2–8.7)	0.90
	Scarring	8.0 (7.0–8.75)	7.0 (6.4–8.0)	0.042
	Nipple–areolar complex	8.2 (6.65–8.75)	8.4 (8.40–8.70)	0.039
	Total	47.70 (45.65–49.60)	47.20 (43.30–49.60)	0.58

Abbreviations: DTI, direct to implant; LD, latissimus dorsi musculocutaneous flap.
Note: Values are presented as median (lower quartile–upper quartile).

different, and ever since the introduction of BREAST-Q in 2018 at the hospital, there is inevitably a difference in the follow-up period. The complication rate was found to be 15.3% for an average follow-up period of 32.3 months in the LD flap with implant group and 13.0% for an average follow-up period of 10.4 months in the DTI group. Because the general surgery department in the institution mainly manages patients, complications or dissatisfaction occurs during long-term follow-up, which is considered the cause of the rather high rates of complications. Due to the relatively long follow-up period and the higher postoperative radiotherapy rate of the LD flap with implant group, it is difficult to simply compare the complication rates between the two groups. Controversy remains in terms of the complication and failure rates of autologous reconstruction and DTI.⁷

The mean duration of surgery in the two groups was 177.5 and 78.8 minutes, which was more than twice as significant. On the other hand, the DTI was 1.5 times higher than the patient burden due to the high cost of the ADM. This was considering only the surgical materials such as ADM and implants and the cost of reconstructive surgery. If the anesthesia cost due to the long operation time in LD flap is additionally considered, this difference can be reduced. Additional consideration also will be given to the rate of complications and the consequent costs of additional treatment, such as reoperation or readmission.

The breast-Q is widely used as a useful tool to study the effects of surgery in patient perspectives.^{8,9} The Breast-Q reconstruction module is divided into four major categories: quality of life, satisfaction, expectation, and breast sensation. Among the details of these categories, the results of psychosocial well-being, sexual well-being, and satisfaction with breast were compared with evaluate mainly the breast. In this study, there was no difference in the results between DTI and LD flap with implant in the three domains. Although there was a difference in the follow-up period between the two groups, we thought that if ~6 months have passed after the operation, satisfaction can be compared, considering that it is maintained

for a certain period of time without significant change in shape. A previous study showed that patients who underwent autologous reconstruction showed better satisfaction than patients who underwent implant-based reconstruction at 2 years.^{10,11} In addition, in the previous study, it was reported that, in the case of autologous surgery, satisfaction with breasts and sexual well-being tended to be maintained at baseline and continuously up to 4 years, but a tendency to decrease over time after implant-based reconstruction was reported.¹¹ It was thought that it was because ptosis occurred due to aging as time passed, and matching with the opposite side was not possible. This was a study comparing pure autologous reconstruction and DTI, but since LD flap with implant is also naturally ptotic to some extent and covers the implant with sufficient soft tissue thickness, it is thought that it may show similar results to pure autologous reconstruction. Considering this point, it is considered as a significant result to compare satisfaction in spite of the difference in follow-up period between the two groups in my study. This is because experienced surgeons usually preserves a certain level of mastectomy skin flap with a certain level of quality. Also, it shows that short-term results may be similar, but the long-term results may be different.

There were also some difficulties in applying the translated breast-Q questionnaire. Some patients complained of difficulties in interpreting the translated sentences, or in the case of sexual well-being. Considering the cultural differences, there were some factors that were somewhat uncomfortable to answer. Therefore, it is thought that it is necessary to study normative data in Korea as well.^{12,13}

Postoperative external evaluations also showed no difference between the two groups. As previously observed, we thought there would be cosmetic advantages in patients with ptosis or thin skin, but these differences were not reflected.³ This was probably because only pictures in the static state were evaluated and not the touch or movement. However, even if there is such a difference that was not reflected in this study, it is thought that the DTI can be further improved by using the contralateral surgery or the prepectoral plane.¹⁴

There was no difference in patient-reported satisfaction and appearance evaluation of the chest except for problems with the donor sites. Therefore, taking into consideration the donor site and surgical time, DTI may have some advantages over LD flap with implant. Further consideration is needed for postoperative complications or cost-effectiveness.

This study has some limitations. First, it is a single-center, retrospective study, and thus has a small sample size. Second, there is a difference in the follow-up period between the two groups due to changes in surgical trends and, in addition, the baseline or preoperative evaluation was not performed. Therefore, further studies with a longer follow-up period is necessary to evaluate the satisfaction level.

The trend of breast reconstruction surgery is changing from autologous breast reconstruction to DTI, and patient satisfaction is maintained similarly, which is believed to be properly replaced. Furthermore, in the case of DTI, there is still room for improvement through the prepectoral plane and the contralateral breast surgery in terms of appearance. Further long-term follow-up observations and comparisons of results including cost-effectiveness taking into consideration the complications and reoperation cost will be needed.

Patient Consent

The patients provided written informed consent for publication.

Ethical Approval

The study was approved by the Institutional Review Board of Soonchunhyang University Hospital (IRB No. 2017 -09 -020) and was performed in accordance with the principles of the Declaration of Helsinki.

Author Contribution

Conceptualization: SG Kang.

Data curation: JM Kim.

Formal analysis: JM Kim.

Writing - original draft: JM Kim.

Writing - review & editing: WJ Song.

Conflict of Interest

None declared.

References

- Sood R, Easow JM, Konopka G, Panthaki ZJ. Latissimus dorsi flap in breast reconstruction: recent innovations in the workhorse flap. *Cancer Contr* 2018;25(01):1073274817744638
- Song WJ, Kang SG, Kim EK, et al. Current status of and trends in post-mastectomy breast reconstruction in Korea. *Arch Plast Surg* 2020;47(02):118–125
- Pacella SJ, Vogel JE, Locke MB, Codner MA. Aesthetic and technical refinements in latissimus dorsi implant breast reconstruction: a 15-year experience. *Aesthet Surg J* 2011;31(02):190–199
- Margulies IG, Salzberg CA. The use of acellular dermal matrix in breast reconstruction: evolution of techniques over 2 decades. *Gland Surg* 2019;8(01):3–10
- Liu J, Hou J, Li Z, Wang B, Sun J. Efficacy of acellular dermal matrix in capsular contracture of implant-based breast reconstruction: a single-arm meta-analysis. *Aesthetic Plast Surg* 2020;44(03):735–742
- Naoum GE, Salama L, Niemierko A, et al. Single stage direct-to-implant breast reconstruction has lower complication rates than tissue expander and implant and comparable rates to autologous reconstruction in patients receiving postmastectomy radiation. *Int J Radiat Oncol Biol Phys* 2020;106(03):514–524
- Bennett KG, Qi J, Kim HM, Hamill JB, Pusic AL, Wilkins EG. Comparison of 2-year complication rates among common techniques for postmastectomy breast reconstruction. *JAMA Surg* 2018;153(10):901–908
- Cano SJ, Klassen AF, Scott AM, Cordeiro PG, Pusic AL. The BREAST-Q: further validation in independent clinical samples. *Plast Reconstr Surg* 2012;129(02):293–302
- Srinivasa DR, Clemens MW, Qi J, et al. Obesity and breast reconstruction: complications and patient-reported outcomes in a multicenter, prospective study. *Plast Reconstr Surg* 2020;145(03):481e–490e
- Pirro O, Mestak O, Vindigni V, et al. Comparison of patient-reported outcomes after implant versus autologous tissue breast reconstruction using the BREAST-Q. *Plast Reconstr Surg Glob Open* 2017;5(01):e1217
- Santosa KB, Qi J, Kim HM, Hamill JB, Wilkins EG, Pusic AL. Long-term patient-reported outcomes in postmastectomy breast reconstruction. *JAMA Surg* 2018;153(10):891–899
- Klifton KM, Aravind P, Major M, et al. Differences between breast cancer reconstruction and institutionally established normative data using the BREAST-Q reconstruction module: a comparative study. *Plast Reconstr Surg* 2020;145(06):1371–1379
- Mundy LR, Homa K, Klassen AF, Pusic AL, Kerrigan CL. Breast cancer and reconstruction: normative data for interpreting the BREAST-Q. *Plast Reconstr Surg* 2017;139(05):1046e–1055e
- Yang JY, Kim CW, Lee JW, Kim SK, Lee SA, Hwang E. Considerations for patient selection: prepectoral versus subpectoral implant-based breast reconstruction. *Arch Plast Surg* 2019;46(06):550–557