



Case Report

## Improved Symptoms of Peripheral Facial Nerve Palsy in ChAdOx1 nCoV-19 Vaccine Recipients Following Complex Korean Medicine Treatment

Woo Seok Jang, Jung Eun Jang, Chan Yung Jung, Kyung Ho Kim\*

Department of Acupuncture and Moxibustion Medicine, Dongguk University Ilsan Oriental Medicine Hospital, Goyang, Korea



### ABSTRACT

#### Article history:

Submitted: October 29, 2021

Revised: December 06, 2021

Accepted: December 13, 2021

#### Keywords:

Bell palsy, Coronavirus, cranial nerve diseases, facial paralysis, Korean traditional medicine, vaccines

Peripheral facial nerve palsy is a neurological condition/disease characterized by unilateral paralysis of the facial muscles. We report the effects of complex Korean medicine treatment in 2 patients diagnosed with Bell's palsy who developed symptoms 3-4 days following vaccination with ChAdOx1 nCoV-19 and who received oral steroids and antiviral medications. Complex Korean medicine treatments including acupuncture, electroacupuncture, bee venom acupuncture, cupping therapy, herbal medicine, and physical therapy were performed. Symptom improvement was evaluated daily using the Numerical Rating Scale, House-Brackmann Grade, and Yanagihara's Score. Patient 1 was hospitalized for 22 days and Patient 2 visited the outpatient clinic 20 times. In both cases, postauricular pain caused by Bell's palsy disappeared, and symptoms of facial paralysis improved following completion of treatment. These findings could suggest that combined Korean medicine treatment may improve symptoms of peripheral facial nerve palsy.

<https://doi.org/10.13045/jar.2021.00283>  
pISSN 2586-288X eISSN 2586-2898

©2022 Korean Acupuncture & Moxibustion Medicine Society. This is an open access article under the CC BY-NC-ND license (<http://creativecommons.org/licenses/by-nc-nd/4.0/>).

### Introduction

Facial nerve palsy is a neurological condition/disease characterized by unilateral paralysis of the facial muscles due to damage in the 7<sup>th</sup> cranial nerve (facial nerve) [1]. Facial nerve palsy is the most common cranial nerve condition/disease. Paralysis due to abnormalities of the facial nerve (except for central facial nerve palsy caused by cerebrovascular condition/diseases or brain tumor) is referred to as peripheral facial nerve palsy [2]. The cause is undetermined in 90% of peripheral facial nerve palsy cases. Idiopathic (cause undetermined) facial nerve palsy (Bell's palsy) affects 20 per 100,000 individuals [3] and there is no difference in the incidence of Bell's palsy according to sex or race [4].

Coronavirus disease 2019 (COVID-19) was first observed in Wuhan, Hubei Province, China in December 2019 and rapidly spread around the world. On March 11, 2020, the World Health Organization declared COVID-19 a global pandemic [5]. The Oxford-AstraZeneca chimpanzee adenovirus-vectored vaccine (ChAdOx1 nCoV-19) is an approved vaccine for immunization against COVID-19. The ChAdOx1 nCoV-19 vaccine reduces the risk of serious infection and health authorities worldwide have determined that this COVID-19 vaccine is safe and effective. There are however, rare cases of serious adverse events associated with this vaccine. The French national agency for the safety of medicines and health products reported 5 cases of facial palsy and 3 cases of acute polyradiculoneuropathy including Guillain-Barré syndrome

\*Corresponding author. Kyung Ho Kim

Department of Acupuncture and Moxibustion Medicine, Dongguk University Ilsan Oriental Medicine Hospital, 27, Dongguk-ro, Ilsandong-gu, Goyang, Gyeonggi, Korea  
E-mail: [omdkkh@hanmail.net](mailto:omdkkh@hanmail.net)

ORCID: Woo Seok Jang <https://orcid.org/0000-0003-3149-1618>, Jung Eun Jang <https://orcid.org/0000-0002-1175-070X>,

Chan Yung Jung <https://orcid.org/0000-0002-0751-5037>, Kyung Ho Kim <https://orcid.org/0000-0002-9714-4224>

©2022 Korean Acupuncture & Moxibustion Medicine Society. This is an open access article under the CC BY-NC-ND license (<http://creativecommons.org/licenses/by-nc-nd/4.0/>).

following the roll out of the ChAdOx1 nCoV-19 vaccination [6]. In the UK, to monitor suspected adverse reactions to medicines on the market, the Yellow Card scheme collates suspected adverse events (reported by individuals) so that regulators can investigate. With regards to vaccination with ChAdOx1 nCoV-19, the frequency of cases of “facial nerve palsy or facial paralysis and nerve disorder” following vaccination, was recorded in the yellow card scheme on April 3, 2021, as approximately 13 cases per million [7]. To date, there has been no reports of Korean medicine treatments for facial nerve palsy which may be associated with the ChAdOx1 nCoV-19 vaccination.

In this case report we present the cases of 2 patients who developed peripheral facial nerve palsy 3-4 days after receiving the ChAdOx1 nCoV-19 vaccine. These patients were diagnosed with facial palsy and received oral steroids and antiviral medication, and underwent complex Korean medicine treatment (acupuncture, electroacupuncture, bee venom acupuncture, cupping therapy, herbal medicine, and physical therapy). Significant improvements in outcomes were observed.

This study was a retrospective chart review and was exempt from the Institutional Review Board deliberations (IRB no.: DUIOH 2021-10-002).

## Case Report

### Case 1

#### Patient 1

OOO(F/64)

#### Presenting complaint

Left facial palsy

#### Onset date

June 18, 2021

#### Present illness and medical history

The patient received the ChAdOx1 nCoV-19 vaccine on June 14, 2021. Symptoms including sagging eyes and a crooked mouth developed on June 18, 2021. The patient was admitted to the Neurology Department of a local hospital on June 19, 2021. Brain computed tomography and magnetic resonance imaging results were normal. She was diagnosed with Bell's palsy and was administered oral steroids and antiviral medications for 6 days. Her symptoms did not improve after 6 days. The patient was admitted to the Department of Acupuncture of the Dongguk University Ilsan Oriental Hospital for treatment on June 25, 2021.

#### Duration of Korean medicine treatment

The patient received Korean medicine treatment between June 25, 2021 and July 16, 2021 (22 days of hospitalization).

### Case 2

#### Patient 2

OOO(F/60)

#### Presenting complaint

Right facial palsy

#### Onset date

June 18, 2021

#### Present illness and medical history

The patient received the ChAdOx1 nCoV-19 vaccine on June 12, 2021. Right-sided postauricular pain developed on June 15, 2021. On the morning of June 18, 2021, she had pain within her ear, saliva drooled from the right side of her mouth during tooth brushing, and water leaked from her mouth whilst drinking. The patient's right eye appeared to produce excessive tears and could not fully close. The patient visited a local Otolaryngology Department on June 18, 2021. However, no abnormalities were observed. On June 18, 2021, the patient visited the Department of Neurology, Dongguk University Ilsan Oriental Medicine hospital and was diagnosed with Bell's palsy. She received oral steroids and antiviral drugs for 7 days. Since her symptoms did not improve after a week, the patient visited the Department of Acupuncture, Dongguk University Ilsan Oriental hospital for treatment on June 25, 2021.

#### Duration of treatment

The patient received treatment between June 25, 2021 and September 7, 2021 (20 days of outpatient treatment).

### Treatments

#### Acupuncture

Acupuncture was performed for 15 minutes using 0.25 × 40 mm sterilized disposable stainless steel DongBang needles (DONGBANG Medical, Boryeong, Korea) under infrared light. Acupuncture treatment was administered to GB14, EX-HN5, TE17, ST02, ST03, ST04, ST06, LI4, and ST36 acupoints. The needle insertion depth was 10-20 mm. Acupuncture was performed twice a day (morning and afternoon) during hospitalization, and was performed once a day during outpatient treatment.

#### Electroacupuncture

Electroacupuncture was performed using a STN-330 device (Stratek, Anyang, Korea). Electrodes were placed at GB14-EX-HN5, ST02-ST03, and ST04-ST06 acupoints. Treatment was performed for 15 minutes using an intensity of stimulation of 3 mA and a frequency of 4.0 Hz.

#### Pharmacopuncture

Bee venom acupuncture was performed using sweet bee venom acupuncture solution (10,000:1), which was prepared at the Kirin Korean Medicine Industrial Institute. A 1.0-mL disposable syringe (WEGO, Weihai, China) and a 30-G 38-mm disposable needle (Jungrim-medical, Jincheon, Korea) were used. To test for allergy to bee venom, acupuncture solution remained on the skin for 10 minutes. After confirming the patient was not allergic to bee venom, 0.1 mL of sweet bee venom acupuncture solution was administered 10 mm deep into the TE17 acupoint. The side effects of bee venom acupuncture were explained to the patients, who gave

oral consent before initiating the procedure.

### Herbal medicine

In Patient 1, during hospitalization (June 25–July 16, 2021), 3 sachets (120 cc each) of Ligigeopoong-san per day were administered orally after meals. In Patient 2, who visited the hospital as an outpatient, 3 sachets (120 cc each) of Ligigeopoong-san per day were prescribed to be taken orally after meals (July 1 to July 11, 2021). Table 1 shows herbal medicine ingredients and daily doses of Ligigeopoong-san.

### Physiotherapy

Electrical stimulation treatment (EST) and laser therapy were administered once per day. EST was performed using an electrode patch (SEJIN M.T. CO., Ltd., Korea) for 10 minutes at 30.0 Hz. Laser treatment was performed using the Super Lizer HA-2200 (TOKYO IKEN CO., Ltd., Japan) to irradiate the stellate ganglion area between the 7<sup>th</sup> cervical vertebra and the 1<sup>st</sup> thoracic vertebra in the anterior part of the neck. The irradiator was fixed, and laser

Table 1. Daily Amounts of Ligigeopoong-Sangami.

Ligigeopoong-sangami	
Scientific name	8
Angelicae Koreanae Radix	4
Angelicae Pubescentis Radix	4
Aurantii Fructus Immaturus	4
Citrii Unshiu Immaturi Pericarpium	4
Aurantii Nobilis Pericarpium	4
Linderae Radix	4
Platycodi Radix	4
Arisaematis Rhizoma	4
Gastrodiae Rhizoma	4
Cnidii Rhizoma	4
Angelicae Dahuricae Radix	4
Schizonepeta Spica	4
Ledebouriellae Radix	4
Paeoniae Radix Alba	4
Glycyrrhizae Radix	4
Typhonii Rhizoma	4
Bombycis Corpus cum Batryticatus	4
Zingiberis Rhizoma Recens	4

therapy was performed with a volume of 60% (1,320 mW) and an ON:OFF ratio of 1:4 for 10 minutes.

### Cupping treatment

Wet cupping therapy was performed once a day at the TE17 acupoint.

### Evaluation

#### The numerical rating scale

The numerical rating scale (NRS) was used daily to evaluate postauricular pain after treatment: pain severity using an integer scale from 0 to 10, with 0 indicating no pain and 10 indicating severe pain [8].

#### The House-Brackmann

The House-Brackmann (H-B) scale is a system for evaluating facial paralysis and other secondary symptoms ranging from Grade 1 to 6, according to the level of paralysis. Grade 1 indicated a normal state and Grade 6 indicated complete paralysis, i.e., the higher the grade the greater the severity of paralysis [9]. The H-B scale was evaluated daily (Table 2).

#### The Yanagihara's unweighted grading system

The Yanagihara's unweighted grading system score (Y-score) is the sum of several scores to determine the severity of paralysis. The total score is calculated out of 40 points, and a lower score indicated greater severity of paralysis. The system included 10 items, each of which was evaluated on a 5-point scale (4, normal; 3, slight paresis; 2, moderate paresis; 1, severe paresis; 0, complete paresis) [10]. The Y-score was evaluated daily (Table 3).

### Evaluation results

Patient 1 had an NRS score of 3 points at the time of admission. This score decreased to 1 after 5 days, and postauricular pain was not observed after 16 days (Fig. 1). The H-B grade was 4 at the time of admission, decreased to 3 after 6 days, and was 2 after 18 days. The Y-score increased from 16 points at the time of admission to 19 points after 1 week. It further increased to 22 after 2 weeks, and 23 points at the time of discharge (Fig. 2).

Patient 2 had an NRS score of 4 points at admission and this score decreased to 3 points after 7 days. The NRS score further decreased to 2 after 15 days, and 1 point after 21 days. Moreover, no pain was experienced after 29 days of treatment (Fig. 3). The H-B grade was 5 at the time of admission and decreased to 4, 3, and 2 after 19, 26, and 54 days of treatment, respectively. The Y-score increased from 18 points at admission to 20 points after 1 week, and gradually increased to 22, 23, 26, 28, 31, and 33 points after 19, 26, 36, 54, 68, and 75 days, respectively (Fig. 4).

### Discussion

Bell's palsy is paralysis of the affected facial muscles caused by an injury to the facial nerve that leads to dysarthria, dysgeusia, decreased salivation, decreased tear secretion, and hypersensitivity

Table 2. The House-Brackmann Facial Grading Scale.

Grade	Description	Characteristics
I	Normal	Gross : Slight weakness noticeable on close inspection may have very slight synkinesis At rest : Normal symmetry and tone
II	Mild dysfunction	Motion : Forehead-Moderate to good function Eye-Complete closure with minimum effort Mouth-Slight asymmetry Gross : Obvious but not disfiguring difference between two sides, noticeable but severe synkinesis, contracture, and/or hemifacial spasm At rest : Normal symmetry and tone
III	Moderate dysfunction	Motion : Forehead-Slight to moderate movement Eye-Complete closure with effort Mouth-Slight weak with maximum effort Gross : Obvious weakness and/or disfiguring asymmetry At rest : Normal symmetry and tone
IV	Moderately severe dysfunction	Motion : Forehead-None Eye-Incomplete closure Mouth-asymmetry with maximum effort Gross : Only barely perceptible At rest : Asymmetry
V	Severe dysfunction	Motion : Forehead-None Eye-Incomplete closure Mouth-Slight movement
VI	Total paralysis	No movement

Table 3. Yanagihara’s Unweighted Grading System.

	Scale of rating				
At rest	0	1	2	3	4
Wrinkle forehead	0	1	2	3	4
Blink	0	1	2	3	4
Closure of eye lightly	0	1	2	3	4
Closure of eye tightly	0	1	2	3	4
Closure of eye involved side only	0	1	2	3	4
Wrinkle nose	0	1	2	3	4
Whistle	0	1	2	3	4
Grin	0	1	2	3	4
Depress lower lip	0	1	2	3	4

to sounds [2,11]. This peripheral nerve paralytic condition/disease is the most common type of facial nerve palsy without a clear cause. Thus, it is also known as idiopathic facial nerve palsy. It is accompanied by inflammation or swelling of the facial neural tube, causing pain around the auricle of the affected side. These clinical symptoms lead to a diagnosis of Bell’s palsy [12,13].

Bell’s palsy comprises the prodromal, paralytic, aggravating, parallel, and recovery stages. In general, nerve damage occurs

between 48 hours and 10 days after onset. Approximately, 80% of patients recover within a few weeks to 3 months. In certain cases, recovery requires over 2 years [14]. Most patients suffering from Bell’s palsy recover completely. However, up to 30% of untreated adult patients do not fully recover and have residual symptoms. Additionally, the condition/disease recurs in 7-12% of patients [15].

Although most patients with Bell’s palsy show asymmetric facial muscle movements, bilateral muscles are affected in less than 1%

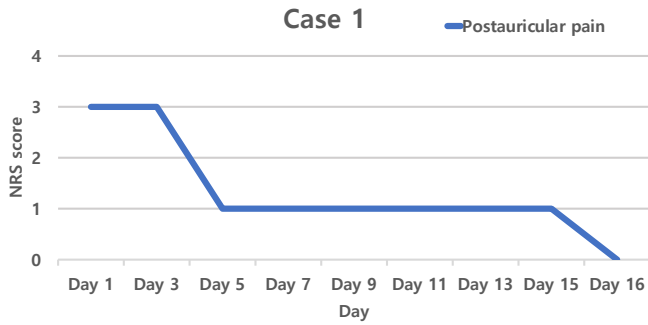


Fig. 1. Changes in the NRS score of postauricular pain over time in Case 1. NRS, numerical rating scale.

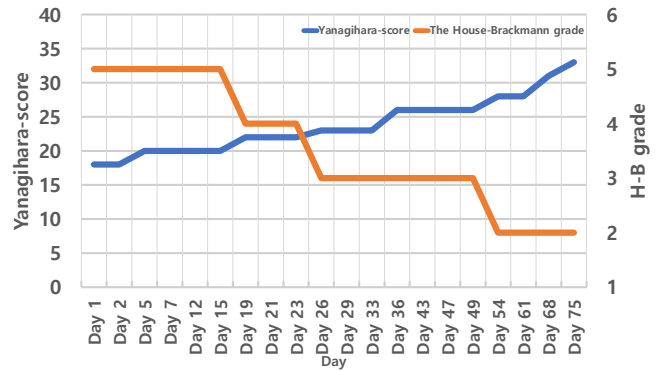


Fig. 4. Changes in the H-B grade and Y-score over time in Case 2. H-B grade, House Brackmann Grade; Y-score, Yanagihara's unweighted grading system.

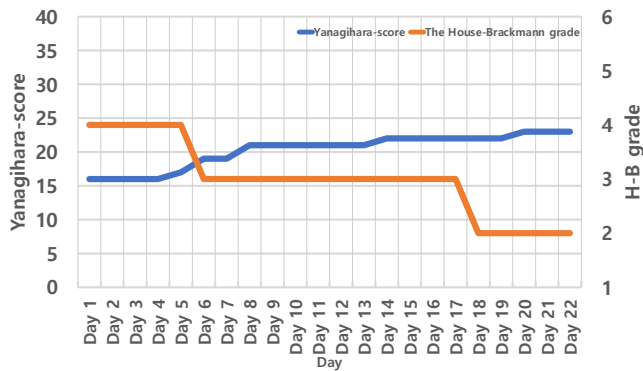


Fig. 2. Changes in the H-B grade and Y-score from admission of Case 1 to discharge. H-B grade, House Brackmann grade; Y-score, Yanagihara's unweighted grading system.

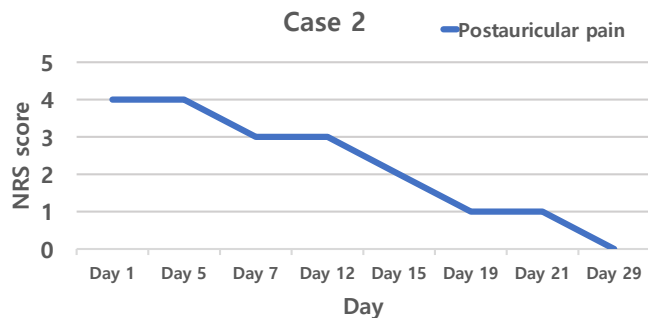


Fig. 3. Changes in the NRS score of postauricular pain over time in Case 2. NRS, numerical rating scale.

of those affected [16]. Factors associated with poor prognosis in patients with Bell's palsy include a history of hypertension and diabetes, old age, and complete paralysis [17].

Western medical treatment of Bell's palsy can be divided into conservative and surgical. Conservative treatment involves administration of steroids, and antiviral agents (given within 72 hours of symptoms). Other types of conservative treatment include stellate ganglion block, vasodilator administration, eye therapy,

psychotherapy, and physical therapy. Surgical treatment (in some countries) includes facial nerve decompression in patients who show no recovery after conservative treatment for 6 to 8 weeks or have sudden complete paralysis [18].

The purpose of physical therapy in this study was to promote blood supply to the face and prevent atrophy by maintaining facial muscle tension. During acupuncture, infrared radiation was applied to the affected side of the face, and EST and electroacupuncture were performed for stimulation of the affected side. In addition, the stellate ganglion area was irradiated by a laser beam, and vasodilating effects were expected.

COVID-19 is a respiratory disease caused by severe acute respiratory syndrome coronavirus-2 (SARS-CoV-2). Among the vaccines created, the ChAdOx1 nCoV-19 vaccine was developed by the Oxford University research team and AstraZeneca. It was created by inserting the entire nucleotide sequence of the SARS-CoV-2 spike protein into a replication-incompetent monkey adenovirus vector [5]. The ChAdOx1 nCoV-19 vaccine is actively offered in Korea. By October 8, 2021, the Korea Disease Control and Prevention Agency had reported administration of 11,094,405 1<sup>st</sup> doses and 8,908,016 2<sup>nd</sup> doses of the vaccine. Adverse reactions have been reported, of which the most common was headache, followed by muscle pain, dizziness, allergic reactions, and nausea. Serious adverse reactions include death, anaphylaxis, thrombocytopenic purpura, acute paralysis, encephalopathy or encephalitis, convulsions, and Guillain-Barré syndrome. However, these serious adverse reactions are very rare. Nasuelli et al reported a case of Guillain-Barré syndrome that was accompanied by bilateral facial paralysis after receiving the ChAdOx1 nCoV-19 vaccine [19]. The patients in this case report developed peripheral facial nerve palsy a few days after receiving the ChAdOx1 nCoV-19 vaccine. They were diagnosed with Bell's palsy, received oral steroid and antiretrovirals, and underwent complex Korean medicine treatment, which improved their symptoms and relieved their pain.

After treatment, postauricular pain was evaluated using the NRS, and symptoms of facial nerve palsy were evaluated using the H-B grade, and Y-score. The H-B grade evaluates all accompanied symptoms of facial paralysis in 5 grades. However, the H-B grade



tends to change very little over a short treatment period. Moreover, discontinuous characteristics and lack of objectivity limit how the H-B grade accurately reflects minor changes in facial function [20,9].

The Y-score evaluates palsy in facial subdivisions using 10 items in 5 different grades. The items are added to calculate a total score. Although, this system allows for evaluation of differential paralysis, it does not consider secondary defects. Compared with the H-B grade, the Y-grade is more objective and accurate [20,10].

In Patient 1, postauricular pain began as an NRS score of 3 points, and 0 after 16 days. The NRS score in Patient 2 was 4 points at the 1st outpatient visit, and postauricular pain disappeared after 29 days (11th visit). This may suggest that the complex Korean medicine treatment could have helped relieve postauricular pain. Additionally, the H-B grade in Patient 1 improved from 4 to 2 during hospitalization, and the Y-score improved from 16 points at the time of admission, to 23 points at the time of discharge. The H-B grade of Patient 2 improved from 5 at the 1st outpatient visit, to 2 at the last outpatient visit. Moreover, the Y-score improved from 18 points to 33 points during hospitalization, suggesting that facial paralysis was improved.

In this study, we describe 2 cases of patients who developed Bell's palsy. They had been vaccinated with the ChAdOx1 nCoV-19 vaccine. They underwent antiviral treatment and oral steroid treatment, and a combination of Korean medicine treatments, which led to improvements in symptoms. However, the indicators used to evaluate symptom improvement are subjective, and spontaneous recovery may have occurred within the timeframe of treatment. Larger, controlled studies are required. In addition, treatments for Bell's palsy, prior to the patients receiving complex Korean medicine treatment do not allow conclusions to be made regarding efficacy of particular treatments. Complex Korean medicine treatment for the 2 patients who developed Bell's palsy may have improved their symptoms.

Although various neurological adverse reactions have been reported after receiving the ChAdOx1 nCoV-19 vaccine, the association between the vaccine and facial nerve palsy has not been determined. Therefore, ongoing, large-scale, real-world data is needed.

### Conflicts of Interest

The authors have no conflicts of interest to declare.

### Funding

None.

### Ethical Statement

This research did not involve any human or animal experiment.

### Data Availability

All relevant data are included in this manuscript

### References

- [1] Kwon N, Shin Y, Kim C, Koh P, Yi W, Joh B et al. Comparative clinical study between oriental medical and oriental-western medical treatment on Bell's Palsy. *J Korean Acupunct Moxib Soc* 2008;25:19-28.
- [2] Korean Acupuncture & Moxibustion Medicine Society. *Acupuncture medicine*. Seoul (Korea): Hanmi Medical Science; 2016. p. 638-642.
- [3] Kang NR, Tark MR, Byun SM, Ko WS, Yoon HJ. A clinical analysis on 250 cases of inpatients with facial paralysis. *J Korean Med Ophthalmol Otolaryngol Dermatol* 2010;23:109-121.
- [4] Donika KP, Kerry HL. Bell palsy: Clinical examination and management. *Cleve Clin J Med* 2015;82:419-426.
- [5] Choe PG. Vaccines and treatment of coronavirus disease 2019. *Korean J Med* 2020;95:364-369.
- [6] Knoll MD, Wonodi C. Oxford-AstraZeneca COVID-19 vaccine efficacy. *Lancet* 2021;397:72-74.
- [7] Cirillo N, Doan R. Bell's palsy and SARS-CoV-2 vaccines-an unfolding story. *Lancet* 2021;21:1210-1211.
- [8] Hawker GA, Mian S, Kendzerska T, French M. Measures of adult pain: Visual Analog Scale for Pain (VAS Pain), Numeric Rating Scale for Pain (NRS Pain), McGill Pain Questionnaire (MPQ), Short-Form McGill Pain Questionnaire (SF-MPQ), Chronic Pain Grade Scale (CPGS), Short Form-36 Bodily Pain Scale (SF-36 BPS), and Measure of Intermittent and Constant Osteoarthritis Pain (ICOAP). *Arthritis Care Res (Hoboken)* 2011;63:S240-252.
- [9] House JW, Brackmann DE. Facial nerve grading system. *Otolaryngology Head and Neck Surgery* 1985;93:145-147.
- [10] Yanagihara N. Grading of Facial Palsy. *Proceedings of the third international symposium on facial nerve surgery*. Amstelveen (Netherlands): Kugler Medical Publications; 1977. p. 533-535.
- [11] Kim KJ, Lee DK, Seok JI. Clinical analysis of Bell's Palsy. *Korean J Clin Neurophysiol* 2007;9:5-10.
- [12] Lindsay KW, Bone I, Fuller G. *Neurology and Neurosurgery Illustrated*. Amsterdam (Netherlands): Elsevier; 2011. p. 227-228.
- [13] Gronseth GS, Paduga R. Evidence-based guideline update: Steroids and antivirals for Bell Palsy. Report of the Guideline Development Subcommittee of The American Academy of Neurology. *Neurology* 2012;79:2209-2213.
- [14] Hong KE. Prevalence and treatment pattern of Korean patients with facial palsy. *Acupuncture* 2010;27:137-146.
- [15] Peitersen E. Bell's palsy: The spontaneous course of 2,500 peripheral facial nerve palsies of different etiologies. *Acta Otolaryngol Suppl* 2002;(549):4-30.
- [16] Ahmed A. When is facial paralysis Bell palsy? Current diagnosis and treatment. *Cleveland Clin J Med* 2005;72:398-405.
- [17] Kim PK, Sung WS, Goo BH, Ryu HK, Suk KH, Lee JH et al. Retrospective study on factors influencing facial nerve damage of acute peripheral facial palsy patients: By electromyography. *Acupuncture* 2013;30:155-167.
- [18] Korean Society of Otorhinolaryngology-Head and Neck Surgery. *Otorhinolaryngology*. Seoul (Korea): Iljogak; 2005. p. 209-211.
- [19] Nasuelli NA, De Marchi F, Cecchin M, Paoli ID, Onorato S, Pettinaroli R et al. A case of acute demyelinating polyradiculoneuropathy with bilateral facial palsy after ChAdOx1 nCoV-19 vaccine. *Neurol Sci* 2021;42:4747-4749.
- [20] Kim MB, Kim JH, Shin SH, Yoon HJ, Ko WS. A study of facial nerve grading system. *J Korean Med Ophthalmol Otolaryngol Dermatol* 2007;20:147-160.