

# Protocatechuic acid impacts rotator cuff healing and reduces fatty degeneration in a chronic rotator cuff tear model in rats

Su-Jung Seo<sup>1</sup>, Jae-Young Park<sup>2</sup>, Hyoung-Jin Park<sup>3</sup>, Jung-Taek Hwang<sup>4</sup>

<sup>1</sup>Department of Orthopedic Surgery, Hallym University College of Medicine, Chuncheon, Korea

<sup>2</sup>Department of Pathology, Bucheon Sejong Hospital, Bucheon, Korea

<sup>3</sup>Department of Physiology, Hallym University College of Medicine, Chuncheon, Korea

<sup>4</sup>Department of Orthopedic Surgery, Hallym University Chuncheon Sacred Heart Hospital, Hallym University College of Medicine, Chuncheon, Korea

**Background:** The purpose of this study was to verify the effect of protocatechuic acid (PCA) on tendon healing and fatty degeneration in a chronic rotator cuff model.

**Methods:** Twenty-eight Sprague-Dawley male rats were randomly allocated into two groups: Saline+repair (SR) and PCA+repair (PR). The right shoulder was used for experimental interventions, and the left served as a control. PCA (30 mg/kg/day) was administered intraperitoneally at the site of infraspinatus tendon detachment in rats in the PR group, and the same volume of saline was administered to the same site in the SR group. The torn tendon was repaired 4 weeks after infraspinatus detachment. Four weeks after repair, hematoxylin and eosin (H&E), S100, and CD68 stains were performed to evaluate the degree of fatty degeneration and H&E and Masson trichrome stains were performed to assess tendon healing. Superoxide dismutase (SOD) was measured to test the efficacy of PCA as an antioxidant.

**Results:** Results from histological evaluation indicated that SOD and CD68 levels at the musculotendinous region and collagen fiber parallel to the orientation at the tendon-to-bone junction were not significantly different between the SR and PR groups. The mean load-to-failure of the PR group (20.32±9.37 N) was higher than that of the SR group (16.44±6.90 N), although this difference was not statistically significant (p=0.395). The SOD activity in the operative side infraspinatus muscle of the PR group was higher than that of the SR group, but the difference was not statistically significant (p=0.053).

**Conclusions:** The use of PCA could improve tendon healing and decrease fatty degeneration after rotator cuff repair.

**Keywords:** Protocatechuic acid; Antioxidant; Rotator cuff tear; Tendon healing; Fatty degeneration

## INTRODUCTION

Rotator cuff tears are the most common tendon injury in ortho-

pedic patients, and result in shoulder pain and dysfunction [1].

Traditionally, the factors that contribute to cuff tears can be divided into extrinsic (including shoulder overuse, presence of

Received: June 17, 2021    Revised: August 9, 2021    Accepted: August 10, 2021

Correspondence to: Jung-Taek Hwang

Department of Orthopedic Surgery, Hallym University Chuncheon Sacred Heart Hospital, Hallym University

College of Medicine, 77 Sakju-ro, Chuncheon 24253, Korea

Tel: +82-33-240-5197, Fax: +82-33-252-0177, E-mail: drakehjt@hanmail.net, ORCID: <https://orcid.org/0000-0003-4189-084X>

Su-Jung Seo and Jae-Young Park contributed equally to this work as first authors.

**Financial support:** This research was supported by the Basic Science Research Program through the National Research Foundation of Korea (NRF) funded by the Ministry of Science, ICT (NRF-2016R1C1B2007014).

**Conflict of interest:** None.

Copyright© 2022 Korean Shoulder and Elbow Society.

This is an Open Access article distributed under the terms of the Creative Commons Attribution Non-Commercial License (<http://creativecommons.org/licenses/by-nc/4.0/>) which permits unrestricted non-commercial use, distribution, and reproduction in any medium, provided the original work is properly cited.

spurs, and differences in the acromion shape) and intrinsic factors (including aging, inflammation, oxidative stress, and apoptosis) [2,3]. Rotator cuff degeneration is one of several factors that contribute to rotator cuff tears and associated pathologic changes have been reported that impact cuff insertion, such as thinning and disorientation of collagen fibers and loss of cellularity, vascularity, and fibrocartilage mass at the site of cuff insertion [2,3]. Oxidative stress is an intrinsic factor that is responsible for tendon degeneration. Oxidative stress leads to tenocyte apoptosis via the c-Jun N-terminal kinase (JNK)-matrix metalloproteinase pathway (MMP) pathway and likely contributes to further tendon degeneration [3,4].

Several studies have investigated whether antioxidant treatment of attenuated rotator cuff degeneration caused by oxidative stress can be used for patient benefits. One study demonstrated that an administration of vitamin C, a major antioxidant, attenuated the rotator cuff degeneration that was caused by oxidative stress in *Sod1<sup>-/-</sup>* mice [1]. Another study showed a trend for improved tendon healing after rotator cuff repair with vitamin C supplementation [5]. Park et al. [6] suggested the possibility of therapeutic use of anthocyanins in patients with tendon degeneration.

Protocatechuic acid (3,4-dihydroxybenzoic acid; PCA), a major metabolite of anthocyanin, is a phenolic compound that naturally occurs in various plants such as star anise (*Illicium verum*), lemon balm (*Melissa officinalis*), and medical rosemary (*Salvia rosmarinus*). It is a biologically active component of some medicinal plants, such as roselle (*Hibiscus sabdariffa*), maidenhair tree (*Ginkgo biloba*) and St. John's wort (*Hypericum perforatum*). It is known for its beneficial effects that include antioxidant, anti-inflammation, antibacterial, antiaging, anticancer, antifibrotic, antiviral, analgesic, antithrombotic, hepatoprotective, neurological, and nephron protective activity [7,8]. Several studies have verified the efficacy of PCA as an antioxidant. Harini and Pugalendi [9] suggested that PCA treatment exerts a therapeutic property by decreasing the oxidative stress in streptozotocin-diabetic rats. Another study suggested that Alpinia PCA was a potential neuroprotective agent and that its neuroprotective effects were at least partially achieved by promoting endogenous antioxidant enzymatic activities and inhibiting free radical generation [8].

The purpose of the present study was to investigate the effects of PCA on tendon healing and reversal of fatty degeneration in a chronic rotator cuff tear model using the rat infraspinatus. The results indicated that PCA influences rotator cuff healing in a rat rotator cuff repair model.

## METHODS

This animal study was conducted in accordance with the guidelines and approval of the Institutional Animal Care and Use Committees (IACUC) of Hallym University (No. Hallym 2015-30). The present study was performed in accordance with the ethical standards in the 1964 Declaration of Helsinki. The present study was performed in accordance with relevant regulations of the US Health Insurance Portability and Accountability Act (HIPAA). Details that might disclose the identity of the subjects under study were omitted.

### Animals

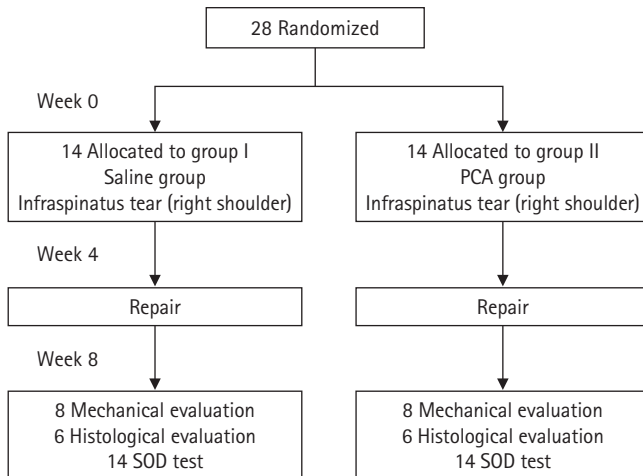
Twenty-eight 10-week-old male Sprague-Dawley male rats (Koatech, Pyeongtaek, Korea) were used in this study. The rats were maintained at a constant room temperature ( $22^{\circ}\text{C} \pm 2^{\circ}\text{C}$ ) and two were housed in each, and the room lights were automatically turned on and off at a 12-hour cycle (on at 6:00 a.m. and off at 6:00 p.m.) food and water were provided *ad libitum* to all animals.

### Allocation of Experimental Rats

For biomechanical testing, a priori power analysis revealed that a minimum of eight rats per group was necessary to detect a significant difference in peak load-to-failure (mean difference, 11.5 N; standard deviation, 6.3 N) with a power of 0.8 and an alpha of 0.05, considering a 25% drop-out rate [10]. For histological testing, we assigned six rats per group at 4 weeks after repair. The 28 male Sprague-Dawley rats ( $300 \pm 5$  g) were randomly allocated to two groups (14 rats per group: 6 for histological and eight for mechanical testing, 14 for superoxide dismutase [SOD] level of rotator cuff): saline+repair (SR) and PCA+repair (PR) groups. All experimental procedures were performed in the right shoulders; the left shoulders underwent sham operations (controls) (Fig. 1).

### Chronic Rotator Cuff Tear Model

Under intraperitoneal pentobarbital anesthesia (50 mg/kg) and sterile draping, a 2-cm skin incision was made along the spine of the scapula to the posterolateral angle of the acromion, and then the infraspinatus muscle and tendon were exposed after incising and retracting the deltoid muscle. In all rats, a chronic infraspinatus tear model was created in the right shoulder by completely detaching the infraspinatus tendon at its insertion site into the greater tuberosity. The torn tendon was wrapped with a 6-mm-long silicone Penrose hose (6-mm outer diameter, Sewoon Medical Co., Ltd., Cheonan, Korea) and the torn tendon that was wrapped with the Penrose hose was sutured to the other tendons



**Fig. 1.** Flow diagram. Superoxide dismutase (SOD) test: the levels of infraspinatus muscle and supraspinatus tendon were measured at 4 weeks after repair. PCA: protocatechuic acid.

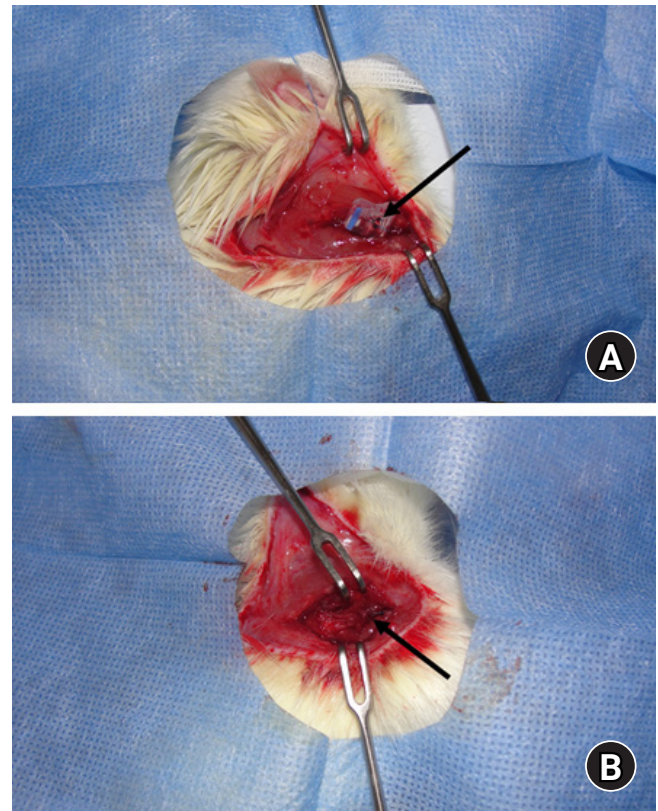
using No. 5-0 Prolene (Ethicon; Johnson & Johnson, New Brunswick, NJ, USA) to inhibit adhesion to the surrounding soft tissue. The repair was left alone and allowed to heal for 4 weeks. The deltoid muscle was sutured with a No. 5-0 Monocryl absorbable suture (Ethicon; Johnson & Johnson) and the skin was sutured with No. 5-0 Prolene (Ethicon; Johnson & Johnson). The left shoulder underwent a sham operation (skin incision and closure only).

### Infraspinatus Repair

Four weeks after the infraspinatus detachment, the torn tendon was repaired [11]. A modified Mason-Allen stitch with a No. 5-0 Prolene (Ethicon; Johnson & Johnson) was used to repair in a transosseous manner by passing the suture through a bone tunnel created in the greater tuberosity using a 22-gauge needle. The deltoid muscle was repaired immediately afterwards using a No. 5-0 Monocryl absorbable suture (Ethicon; Johnson & Johnson). The skin was sutured using a No. 5-0 Prolene (Ethicon; Johnson & Johnson) (Fig. 2).

### Administration of Protocatechuic Acid

First, 300 mg of PCA (Sigma-Aldrich, St. Louis, MO, USA) was dissolved in 100 mL of saline and stored at room temperature. After the initial operation, which detached the infraspinatus tendon, PCA was administered at 1 mL per 100 g of body weight to the PR group intraperitoneally and the same volume of saline was administered to the rats in the SR group until the last operation was completed; the total administration was over the course of 56 days.



**Fig. 2.** Surgical procedures in a rat model. (A) Detached infraspinatus tendon wrapped using a Penrose drain. (B) Repaired tendon attached to the greater tuberosity of the humeral head.

### Histological Testing


Evidence of vascularization was determined based on the presence of blood vessels, and cells were observed in the irregularly arranged fibrovascular interface tissue. Vascularity and cellularity were considered as the parameters for inflammation or foreign body reaction, respectively. Histological evaluation was performed at 4 weeks after the repair. The rats (six per group) were intraperitoneally anesthetized with pentobarbital and euthanized with carbon dioxide, and the proximal humerus including the greater tuberosity with the attached entire infraspinatus tendon of both shoulders of each rat was harvested. The specimens were fixed in neutral buffered 10% formalin (pH 7.4) and decalcified for 24 hours (Formical-2000; Decal Chemical Corporation, Tallman, NY, USA). Two paraffin blocks were created for each specimen. The specimen was horizontally cut at a point that was approximately 3 mm medial to the musculotendinous junction. The proximal portion was used to create a paraffin block and the distal portion was cut longitudinally at a midpoint of the repair site (the infraspinatus tendon and the greater tuberosity). Two distal portions were prepared in one paraffin block. Then, 5  $\mu\text{m}$ -thick sections were cut in the coronal plane from the tendon-to-

bone junction; these were stained with hematoxylin and eosin (H&E) and Masson trichrome. We assessed vascularity and cellularity on an average field of  $\times 200$  from the H&E stain sections, and we assessed the collagen fiber continuity and parallel orientation from the sections of Masson's trichrome stain on average field of  $\times 100$ . We graded each of these parameters semi-quantitatively using four stages (grade 0, present with  $< 25\%$  of proportion; grade 1,  $25\% - 50\%$  of proportion; grade 2,  $50\% - 75\%$  of proportion; grade 3,  $> 75\%$  of proportion) [12]. We also cut 5-um-thick sections in the sagittal plane to a point about 3 mm medial to the musculotendinous junction of the infraspinatus and stained the sections with H&E, and S100 or SOD stains. On average, in a field of  $\times 200$ , the histological findings from these sections were graded with a four-scale system (grades 0, 1, 2, 3), where a grade 0 was no fat deposits or SOD and a grade 3 was fat droplets or SOD found in most fibers [13].

In addition, S100, CD68, and SOD stainings were performed using immunohistochemistry in the sagittal sections. The S100 stain was adopted to detect adipose cells [14], and the CD68 stain was adopted to detect macrophages which suggested degeneration [15]. Fat globules between muscle fibers were visualized using the S100 protein stain, in which fat was stained in a distinct red color [14,16]. Macrophages were visualized using the CD68 stain as distinct brown body, and SOD was visualized using the SOD stain as a generalized brown colored muscle fiber. Sections of formalin-fixed, paraffin wax-embedded infraspinatus muscle tissue were stained in the Bond-Max automatic immunostaining device (Leica Biosystem, Wetzlar, Germany) using a bond polymer intensity detection kit (Leica Biosystem) for formalin-fixed, paraffin-embedded tissue sections. A CD68 (Leica Biosystem), S100 (Leica Biosystem), and SOD (Abcam, Cambridge, UK) were used to analyze antibody levels. These sections were counterstained with Harris hematoxylin. From CD68 immunohistochemical staining, the findings were assessed on an average field of  $\times 400$  as the number of stained macrophages using an antigen counter (UTHSCSA ImageTool 3.0; The University of Texas Health Science Center, San Antonio, TX, USA). The findings from S100 and SOD immunohistochemical staining were checked on an average field of  $\times 200$  as a four-scale system (grades 0, 1, 2, 3), where a grade 0 was no fat deposit or SOD and a grade 3 was fat droplets or SOD found in most fibers [13]. All of these analyses were performed by one pathologist who was blinded to the experimental conditions. In all the grading and measuring, the pathologist selected an average field and performed the work on the field. The average of the three measured values for the histologic grading and measurements was used for quantitative analysis.

## Mechanical Testing

Insertional tearing is suggestive of relatively poor tendon-to-bone healing whereas midsubstance tearing indicate good healing. The rats (eight per group) were intraperitoneally anesthetized and euthanized with carbon dioxide, and the proximal humerus, including the greater tuberosity with the attached entire infraspinatus tendon of both shoulders of each rat, was harvested at 4 weeks after the cuff repair. The harvested tendon with the bone was wrapped in saline soaked gauze and placed in an icebox. Each sample was placed at room temperature for 10 minutes just before testing. Biomechanical testing was performed with the aid of an Instron 3343 device (Instron, Norwood, MA, USA) (Fig. 3A). The proximal humerus of the specimen was hung on a metal (rat muscle fixation device), and a hole was drilled into the specimen to fix a pneumatic grip (ISG Inc., Sunnam, Korea) (Fig. 3B). The muscular end of each sample was wrapped in a thin layer of dry gauze and fixed between the two hard rubber layers of a second pneumatic grip. Each tendon was initially preloaded to 0.1 N, followed by 10 cycles of preconditioning (cycling between 0.1 and 0.5 N at a strain rate of 0.4%/sec). After a 300-second hold to allow equilibrium to be attained, each 600-second stress-relaxation experiment began with a ramp to 5% strain at 5%/sec, followed by a return to gauge length and a 60-second hold. Finally, each specimen was quasi-statically tested to failure at a rate of 0.3%/sec. The key data recorded included the mode of tearing and the peak load-to-failure [12].



**Fig. 3.** Material testing machine. (A) Instron 3343 (Instron, Norwood, MA, USA) equipped with a pneumatic grip and a metal device for the humeral head (rat muscle fixation device). (B) The tensile load was applied to the rat infraspinatus.

### Superoxide Dismutase Activity

After the sacrifice, the supraspinatus tendon and infraspinatus muscle were harvested to detect SOD activity and homogenized in ice-cold 50 mM phosphate buffer (containing 1 mM EDTA, pH 7.0). The infraspinatus tendon and muscle component used a mechanical test, and the most proximal portion of the infraspinatus muscle was used for the SOD assay. The SOD activity was determined using a SOD assay kit (Dojindo, Kumamoto, Japan). The assay used water-soluble tetrazolium salt, which produces a water-soluble formazan dye upon reduction with a superoxide anion. The rate of reduction by a superoxide anion is linearly related to the xanthine oxidase activity and is inhibited by SOD. Therefore, the inhibition activity of SOD as determined by a colorimetric method was used to determine the supraspinatus tendon and infraspinatus muscle SOD levels. One unit of SOD was defined as the amount of enzyme needed to exhibit 50% dismutation of superoxide radicals. The absorbance was read at 450 nm by a GloMax Discover multimode plate reader (Promega, Madison, WI, USA) and activity was expressed in U/mg protein. The protein concentration was measured using Bradford's method.

### Statistical Analysis

All statistical analyses were performed using IBM SPSS ver. 25 (IBM Corp., Armonk, NY, USA). A p-value <0.05 was considered statistically significant. The Mann-Whitney U-test or independent t-test was performed to compare values from the operative procedure side or the control side.

## RESULTS

Three specimens from the SR and PR groups died during the op-

eration. Therefore, these six rats were excluded from the following assessment, and 22 rats were included in the analysis (histological evaluation 4 weeks after repair, n=4; mechanical evaluation 4 weeks after repair, n=7; SOD level 4 weeks after repair, n=11; and 11 for SR and PR groups), as shown in Table 1.

### Histological Testing

Overall histological gradings are reported in Table 2. Immunohistochemical evaluations are shown in Table 3 and comparison of the histologic results outcomes between the groups are shown in Table 4. The SOD stain levels at the musculotendinous region were greater in the PR group than in the SR group (p=0.390). A lower vascularity was observed in the PR group than in the SR group (p=0.752), but there was no statistically significant difference between the groups, and the same level of cellularity was observed in the SR and PR groups (p=1.000). The PR group had more fiber continuity (p=0.190) and parallel collagen fiber than the SR group (p=0.096). Immunohistochemical testing analysis of the musculotendinous region indicated that the S100 stain showed a lower mean number of adipose cells in the PR group than in the SR group (p=0.390). The CD68 stain results showed a similar pattern to the S100 stain (p=0.447). The overall results for the histologic and immunohistochemical evaluations showed

**Table 1.** Complications and number of rats included in each analysis

Complication	SR Group	PR Group
No recovery from anesthesia	3	3
8-Week histological evaluation	4	4
8-Week mechanical evaluation	7	7
8-Week SOD level in cuffs	11	11

SR: saline+repair, PR: protocatechuic acid+repair, SOD: superoxide dismutase.

**Table 2.** Histologic gradings

Variable	Sham				SR				PR			
	g0	g1	g2	g3	g0	g1	g2	g3	g0	g1	g2	g3
H&E (S100) stain at M-T region*	0	4	0	0	0	1	1	2	0	1	3	0
SOD at M-T region*	0	4	0	0	0	3	1	0	0	1	3	0
H&E, M&T stain at T-B junction†												
Cellularity at T-B region	4	0	0	0	0	2	2	0	0	2	2	0
Vascularity at T-B region	3	1	0	0	0	2	1	1	0	2	2	0
Collagen fiber continuity at T-B region	0	0	0	4	2	1	1	0	0	2	1	1
Collagen fiber parallel orientation at T-B region	0	0	0	4	0	1	3	0	0	0	2	2

Values are presented as number.

Sham: light shoulder of PR, SR: saline+repair, PR: protocatechuic acid+repair, H&E: hematoxylin and eosin, M-T: musculotendinous, SOD: superoxide dismutase, M&T: Masson trichrome, T-B: tendon-to-bone.

\*Four-scale system of adipose cell: g0, no; g3, fat droplets found in most fibers; †g0, absent or minimal or >25% of proportion; g1, mild degree or 25%–50%; g2, moderate degree or 50%–75%; g3, severe (marked) degree or >75%.

that the PR group had better improvements than the SR group. (Fig. 4).

### Mechanical Testing

Data for the mechanical testing are shown in Table 5. The failure modes in the SR group were two insertional and five midsub-

stance parameters, and four insertional and three midsubstance parameters in the PR group ( $p=0.591$ ). All control failures were attributed to midsubstance tears. The mean load-to-failure values of the PR group ( $20.32 \pm 9.37$  N) was higher than that of the SR group ( $16.44 \pm 6.90$  N), although the differences were not statistically significant ( $p=0.395$ ). (Tables 5 and 6). The load-to-failure values of the control side (left side) specimens were greater than those of the test specimens, but the differences were not significant in the PR group ( $p=0.085$ ), suggesting that tendon healing was good.

**Table 3.** Immunohistochemistry (S100 and CD68) at musculotendinous region

Group	4 weeks after repair	
	S100	CD6
Sham (n = 4)	2.3 ± 4.5	1.3 ± 2.5
SR (n = 4)	174.8 ± 39.7	8.5 ± 4.2
PR (n = 4)	123.8 ± 63.8	6.3 ± 3.6

Values are presented as mean±standard error.  
SR: saline+repair, PR: protocatechuic acid+repair.

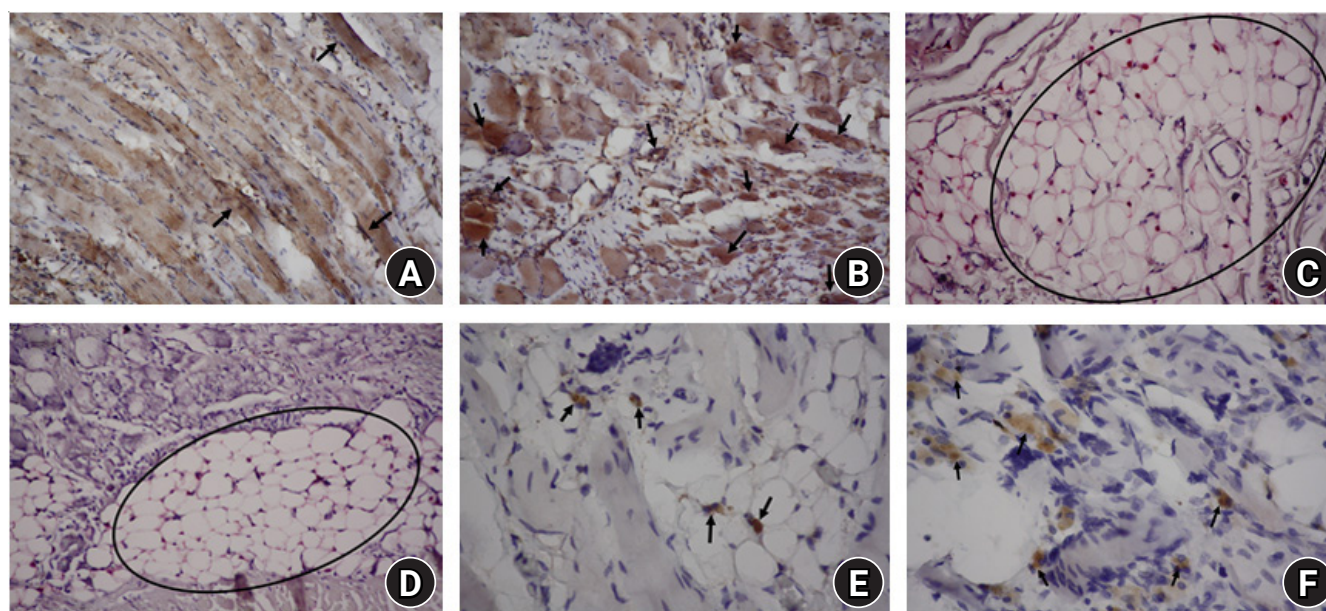
### Superoxide Dismutase Activity

The SOD activity in the infraspinatus muscle and supraspinatus are shown in Fig 5. The average level of SOD in the treated infraspinatus muscle of the PR group was higher than that of the SR group. But the result was not statistically significant ( $p=0.053$ ),

**Table 4.** Outcome of mechanical testing

Group	MT-H&E (S100)	MT-SOD	MT-CD68	TB-V	TB-C	TB-Co	TB-PA
Sham vs. SR	0.040	0.356	0.025	0.032	0.013	0.013	0.011
Sham vs. PR	0.046	0.024	0.062	0.017	0.013	0.046	0.127
SR vs. PR	0.390	0.207	0.447	0.752	1.000	0.190	0.096

MT: musculotendinous region, H&E: hematoxylin and eosin, SOD: superoxide dismutase, TB: tendon-to-bone junction, V: vascularity, C: cellularity, Co: continuity of collagen fiber, PA: parallel orientation of collagen fiber, Sham: left shoulder of SR group, SR: saline+repair, PR: protocatechuic acid+repair.  
 $P<0.05$ .



**Fig. 4.** Immunohistochemical findings. (A, B) Superoxide dismutase (SOD) staining ( $\times 200$ ) of the musculotendinous region at 4 weeks after repair. The protocatechuic acid+repair (PR) group (B) showed more SOD expression than the saline+repair (SR) group (A). Black arrows: superoxide dismutase. (C, D) S100 stain ( $\times 200$ ) of the tendon-to-bone junction at 4 weeks after repair. The PR group (D) exhibited fewer S100 stained cells than the SR group (C). Black ellipses: S100 stained cell mass. (E, F) CD68 stain ( $\times 400$ ) of the tendon-to-bone junction at 4 weeks after repair. The PR group (F) had fewer CD 68 stained cells than the SR group (E). Black arrows: CD68 stained macrophage.

**Table 5.** Outcome of mechanical testing

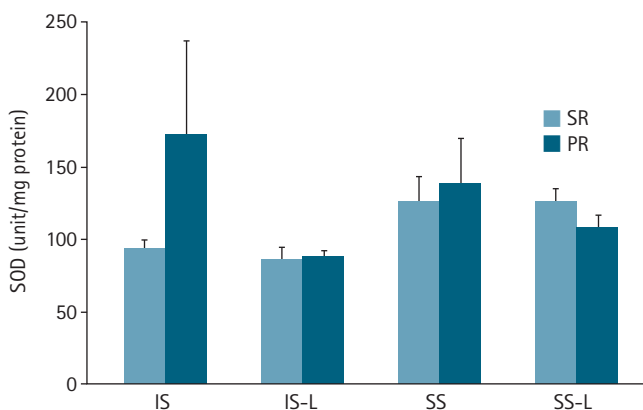
Variable	SR Group (n = 7)	PR Group (n = 7)
Load-to-failure		
Operated side (N)	16.44 ± 6.90	20.32 ± 9.37
Control side (N)	26.88 ± 4.57	29.47 ± 2.83
p-value	0.006	0.085
Tear pattern insertional:midsubstance		
Operated side	2:5	4:3
Control side	0:7	0:7
p-value	0.007	0.023

Values are presented as mean±standard error or number. SR: saline+repair, PR: protocatechuic acid+repair.

**Table 6.** Outcome of mechanical testing between the treated right sides

Group	p-value	
	Load-to-failure (N)	Tear pattern
SR vs. PR	0.395	0.591

SR: saline+repair, PR: protocatechuic acid+repair. p<0.05.



**Fig. 5.** Superoxide dismutase (SOD) levels of the infraspinatus muscle and supraspinatus tendon at 4 weeks after repair. Values are presented as mean±standard error. IS: right infraspinatus muscle, IS-L: left infraspinatus muscle, SS: right supraspinatus tendon, SS-L: left supraspinatus tendon, SR: saline+repair, PR: protocatechuic acid+repair.

**Table 7.** Comparison of superoxide dismutase levels between SR and PR

Variable	p-value
Rt infraspinatus muscle	0.053
Lt infraspinatus muscle	0.870
Rt supraspinatus tendon	0.818
Lt supraspinatus tendon	0.317

SR: saline+repair, PR: protocatechuic acid+repair, Rt: right side, Lt: left side. p<0.05.

as shown in Table 7. The average SOD activity levels in the control infraspinatus muscle and the treated supraspinatus tendon are shown in Fig. 5.

## DISCUSSION

In this study, PCA was associated with tendon healing and fatty degeneration of chronic rotator cuff tears in a rat model, and the recovery was associated with SOD levels. The mean values for the histological and mechanical parameters were higher in the PR group than in the SR group, but there was no statistically significant difference.

Several studies have investigated different approaches for treating antioxidant attenuated rotator cuff degeneration caused by oxidative stress. Morikawa et al. [11] suggested that intracellular oxidative stress contributes to the degeneration of rotator cuff entheses. Morikawa et al. [1] revealed that rotator cuff degeneration in SOD1-deficient mice could be suppressed by vitamin C. Martel et al. [5] showed that administration of vitamin C is associated with improvements in tendon healing after rotator cuff injury. DePhillipo et al. [17] demonstrated that vitamin C has the potential to accelerate bone healing after a fracture and increase type I collagen synthesis. Aiyegbusi et al. [18] suggested that antioxidants can promote healing by stimulating tenoblast proliferation. Hung et al. [19] suggest that local injections of vitamin C solution can reduce the extent of adhesion for healing tendons, which is likely facilitated by redox modulation in a chicken model. Koike et al. [20] reported that vitamin C effectively suppressed superoxide generation and cartilage degeneration. Therefore, antioxidants could be helpful for treating and preventing rotator cuff tears with oxidative stress.

PCA has been demonstrated as an effective antioxidant. Oxidative stress plays a key role in the pathogenesis of degenerative conditions such as cardiovascular disease, cancer, and aging [21]. In streptozotocin-induced diabetic rats, PCA has been shown to decrease reactive oxygen species (ROS) formation in the liver, heart, kidney, and brain by restoring endogenous antioxidant enzyme activities [9,22]. Tsai and Yin [23] demonstrated that PCA decreased advanced glycation end products (AGEs) and ROS production in D-galactose-induced ROS and AGEs formation in mice. Endogenous antioxidants, such as SOD, protect cells from ROS damage [24]. There is evidence to support the role of inflammatory mediators and suggest that the symptoms of rotator cuff tendinopathy are mediated by cyclooxygenase-2 and prostaglandin E<sub>2</sub>, and that the loss of tissue architecture is mediated by the MMP. Oxidative stress leads to tenocyte apoptosis via MMP within the extracellular matrix and JNK within the intracellular

environment [4,25,26] and likely contributes to further tendon degeneration [3,4].

In this study, histological evaluation indicated that there were more S100-stained cells at the musculotendinous region in the SR group than in the PR group ( $p=0.390$ ). The SOD staining at the musculotendinous region was greater in the PR group than in the SR group. The PR group had more fiber continuity and parallel collagen fiber than the SR group.

Immunohistochemical evaluation of the musculotendinous region indicated that there was reduced S100 and CD68 staining in the PR group ( $123.8 \pm 63.8$ ,  $6.3 \pm 3.6$ , respectively) than in the SR group ( $174.8 \pm 39.7$ ,  $8.5 \pm 4.2$ , respectively). Statistical analysis of histologic results compared the sham and the right shoulders of the SR group and PR group and indicated that there was a significant difference in the sham group compared with all the other groups with the exception of the musculotendinous CD68 staining of the PR group and tendon-to-bone parallelity on the Masson trichrome staining of the SR group. The mean value for histological parameters was higher in the PR group than in the SR group, but the difference was not statistically significant. Histological evaluation indicated that there was an increase of SOD in the PR group and an increase of CD68 in the SR group at the musculotendinous region compared to the sham group ( $p=0.024$  and  $p=0.025$ ), and the collagen fiber parallel orientations at the tendon-to-bone junction in PR group were not significantly different compared to the sham group ( $p=0.127$ ), which suggest improvement of fatty degeneration and tendon healing.

On a histological evaluation, degeneration is characterized by loss of cellularity, vascularity, tissue architecture, and a fibrocartilaginous mass within the cuff resulting in a mechanically inferior tendon property [3]. On the biomechanical evaluation, the mean load-to-failure values of the two groups were  $20.32 \pm 9.37$  N and  $16.44 \pm 6.90$  N, respectively. Although the mean load-to-failure values were slightly higher in the PR group than the SR group, there was no significant difference between the groups ( $p=0.395$ ). The load-to-failure values of the control side (left side) specimens were greater than those of the test specimens, but the differences were not significant in the PR group ( $p=0.085$ ), suggesting that tendon healing was good.

Several studies have suggested that administration of antioxidants is effective for tendon healing. In this study, the SOD activity in the treated infraspinatus muscle of the PR group was higher than that of the SR group although the difference was statistically significant ( $172 \pm 215$  and  $94 \pm 5$  units/mg protein;  $p=0.053$ ). Based on these results, applying PCA as a treatment likely increases the SOD activity. Therefore, the use of PCA may also im-

prove tendon healing and decrease fatty degeneration after cuff repair. In contrast to this study, Uehara et al. [27] showed that SOD activity was significantly decreased in rotator cuff injury but showed no significant difference in the rotator tear model. These findings suggested that SOD might not be associated with rotator cuff degeneration after tears but may be involved in rotator cuff degeneration without tears [27]. In this study, we hypothesized that PCA was recruited to the damage site due to the need for SOD for tear regeneration when PCA was administered. This suggests that healing of degenerative chronic rotator cuff tears requires more SOD than the non-injury state.

The infraspinatus of rats was adopted as the specimen model in this study because of its biomechanical similarity to humans. Rotator cuff tears occur more frequently in the supraspinatus than the infraspinatus in humans. But the infraspinatus in rats has a longer tendinous portion than the supraspinatus. Therefore, the infraspinatus is more suitable for a rotator cuff repair model in rats [28,29].

Our study had several limitations. First, the SOD activity was assessed by using the infraspinatus muscle instead of the tendon, this is because the tendinous portion with bone was used for biomechanical testing. However, this approach is acceptable because the infraspinatus muscle and tendon are one unit. Second, S100 staining is not highly specific to adipocytes and the neural crest origin cells are also stained. Third, we did not identify a statistically significant difference in the histologic and biomechanical findings between the SR and PR groups. Further, there was no statistically significant difference in SOD activity levels between the two groups. Therefore, this study did not conclusively identify an effect of PCA on rotator cuff healing. We did, however, determine that the PR group did significantly differ from the sham group, suggesting that tendon healing was good. In addition, the administration of PCA might increase SOD levels in repaired infraspinatus muscle. Finally, in this study, we did not assess the stiffness of the repaired tendon, we only measured the mode of tearing and the peak load-to-failure. However, because animal studies have intrinsic limitations these results should be interpreted with caution in terms of clinical applications. In conclusion, histological and biomechanical tests showed that use of PCA could improve tendon-to-bone healing and decrease fatty degeneration after cuff repair in a rat model.

## ORCID

Su-Jung Seo

<https://orcid.org/0000-0003-1667-9102>

Jae-Young Park

<https://orcid.org/0000-0003-3893-0521>

Hyoung-Jin Park

<https://orcid.org/0000-0002-0380-8836>



## REFERENCES

- Morikawa D, Nojiri H, Itoigawa Y, Ozawa Y, Kaneko K, Shimizu T. Antioxidant treatment with vitamin C attenuated rotator cuff degeneration caused by oxidative stress in Sod1-deficient mice. *JSES Open Access* 2018;2:91-6.
- Hashimoto T, Nobuhara K, Hamada T. Pathologic evidence of degeneration as a primary cause of rotator cuff tear. *Clin Orthop Relat Res* 2003;(415):111-20.
- Nho SJ, Yadav H, Shindle MK, Macgillivray JD. Rotator cuff degeneration: etiology and pathogenesis. *Am J Sports Med* 2008; 36:987-93.
- Wang F, Murrell GA, Wang MX. Oxidative stress-induced c-Jun N-terminal kinase (JNK) activation in tendon cells upregulates MMP1 mRNA and protein expression. *J Orthop Res* 2007;25: 378-89.
- Martel M, Laumonerie P, Girard M, Dauzere F, Mansat P, Bonneville N. Does vitamin C supplementation improve rotator cuff healing? A preliminary study. *Eur J Orthop Surg Traumatol* 2021 Mar 16 [Epub]. <https://doi.org/10.1007/s00590-021-02926-0>.
- Park HB, Hah YS, Yang JW, Nam JB, Cho SH, Jeong ST. Antia-poptotic effects of anthocyanins on rotator cuff tenofibroblasts. *J Orthop Res* 2010;28:1162-9.
- El-Sonbaty YA, Suddek GM, Megahed N, Gameil NM. Protocatechuic acid exhibits hepatoprotective, vasculoprotective, antioxidant and insulin-like effects in dexamethasone-induced insulin-resistant rats. *Biochimie* 2019;167:119-34.
- Shi GF, An LJ, Jiang B, Guan S, Bao YM. Alpinia protocatechuic acid protects against oxidative damage in vitro and reduces oxidative stress in vivo. *Neurosci Lett* 2006;403:206-10.
- Harini R, Pugalendi KV. Antioxidant and antihyperlipidaemic activity of protocatechuic acid on streptozotocin-diabetic rats. *Redox Rep* 2010;15:71-80.
- Plate JF, Brown PJ, Walters J, et al. Advanced age diminishes tendon-to-bone healing in a rat model of rotator cuff repair. *Am J Sports Med* 2014;42:859-68.
- Morikawa D, Itoigawa Y, Nojiri H, et al. Contribution of oxidative stress to the degeneration of rotator cuff entheses. *J Shoulder Elbow Surg* 2014;23:628-35.
- Beason DP, Tucker JJ, Lee CS, Edelstein L, Abboud JA, Soslowsky LJ. Rat rotator cuff tendon-to-bone healing properties are adversely affected by hypercholesterolemia. *J Shoulder Elbow Surg* 2014;23:867-72.
- Kim HM, Galatz LM, Lim C, Havlioglu N, Thomopoulos S. The effect of tear size and nerve injury on rotator cuff muscle fatty degeneration in a rodent animal model. *J Shoulder Elbow Surg* 2012;21:847-58.
- Miettinen M. Immunohistochemistry of soft tissue tumours: review with emphasis on 10 markers. *Histopathology* 2014;64: 101-18.
- Gumucio JP, Korn MA, Saripalli AL, et al. Aging-associated exacerbation in fatty degeneration and infiltration after rotator cuff tear. *J Shoulder Elbow Surg* 2014;23:99-108.
- Nakajima T, Watanabe S, Sato Y, Kameya T, Hirota T, Shimosato Y. An immunoperoxidase study of S-100 protein distribution in normal and neoplastic tissues. *Am J Surg Pathol* 1982;6:715-27.
- DePhillipo NN, Aman ZS, Kennedy MI, Begley JP, Moatshe G, LaPrade RF. Efficacy of vitamin C supplementation on collagen synthesis and oxidative stress after musculoskeletal injuries: a systematic review. *Orthop J Sports Med* 2018;6:232596711880 4544.
- Aiyegbusi AI, Duru FI, Awelimobor D, Noronha CC, Okanlawon AO. The role of aqueous extract of pineapple fruit parts on the healing of acute crush tendon injury. *Nig Q J Hosp Med* 2010;20:223-7.
- Hung LK, Fu SC, Lee YW, Mok TY, Chan KM. Local vitamin-C injection reduced tendon adhesion in a chicken model of flexor digitorum profundus tendon injury. *J Bone Joint Surg Am* 2013; 95:e41.
- Koike M, Nojiri H, Ozawa Y, et al. Mechanical overloading causes mitochondrial superoxide and SOD2 imbalance in chondrocytes resulting in cartilage degeneration. *Sci Rep* 2015; 5:11722.
- Semaming Y, Pannengpetch P, Chattipakorn SC, Chattipakorn N. Pharmacological properties of protocatechuic acid and its potential roles as complementary medicine. *Evid Based Complement Alternat Med* 2015;2015:593902.
- Semaming Y, Kumfu S, Pannangpetch P, Chattipakorn SC, Chattipakorn N. Protocatechuic acid exerts a cardioprotective effect in type 1 diabetic rats. *J Endocrinol* 2014;223:13-23.
- Tsai SJ, Yin MC. Anti-glycative and anti-inflammatory effects of protocatechuic acid in brain of mice treated by D-galactose. *Food Chem Toxicol* 2012;50:3198-205.
- Li L, Okusa MD. Macrophages, dendritic cells, and kidney ischemia-reperfusion injury. *Semin Nephrol* 2010;30:268-77.
- Han Z, Boyle DL, Chang L, et al. c-Jun N-terminal kinase is required for metalloproteinase expression and joint destruction in inflammatory arthritis. *J Clin Invest* 2001;108:73-81.
- Yuan J, Murrell GA, Wei AQ, Wang MX. Apoptosis in rotator cuff tendonopathy. *J Orthop Res* 2002;20:1372-9.
- Uehara H, Itoigawa Y, Wada T, et al. Relationship of superoxide

- dismutase to rotator cuff injury/tear in a rat model. *J Orthop Res* 2021 Jun 29 [Epub]. <https://doi.org/10.1002/jor.25141>.
28. Mathewson MA, Kwan A, Eng CM, Lieber RL, Ward SR. Comparison of rotator cuff muscle architecture between humans and other selected vertebrate species. *J Exp Biol* 2014;15;217(Pt 2):261-73.
29. Edelman L, Thomas SJ, Soslowsky LJ. Rotator cuff tears: what have we learned from animal models. *J Musculoskelet Neuronal Interact* 2011;11:150-62.