



Effectiveness of miniscrew assisted rapid palatal expansion using cone beam computed tomography: A systematic review and meta-analysis

Patchaya Siddhisaributr^a 
Kornkanok
Khlongwanitchakul^a
Niwat Anuwongnukroh^a
Somchai Manopatanakul^b
Nita Viwattanatipa^a 

^aDepartment of Orthodontics, Faculty of Dentistry, Mahidol University, Bangkok, Thailand

^bDepartment of Advanced General Dentistry, Faculty of Dentistry, Mahidol University, Bangkok, Thailand

Objective: This study aims to examine the effectiveness of miniscrew assisted rapid palatal expansion (MARPE) treatment in late adolescents and adult patients using cone-beam computed tomography (CBCT). **Methods:** Literature search was conducted in five electronic databases (PubMed, Embase, Scopus, Web of Science, and Cochrane Library) based on the PICOS keyword design focusing on MARPE. Out of the 18 CBCT screened outcomes, only nine parameters were sufficient for the quantitative meta-analysis. The parameters were classified into three main groups: 1) skeletal changes, 2) alveolar change, and 3) dental changes. Heterogeneity test, estimation of pooled means, publication bias, sensitivity analysis and risk of bias assessment were also performed. **Results:** Upon database searching, only 14 full-text articles were qualified from the 364 obtained results. Heterogeneity test indicated the use of the random-effects model. The pooled mean estimate were as follows: 1) Skeletal expansion: zygomatic width, 2.39 mm; nasal width, 2.68 mm; jugular width, 3.12 mm; and midpalatal suture at the posterior nasal spine and anterior nasal spine, 3.34 mm and 4.56 mm, respectively; 2) Alveolar molar width expansion, 4.80 mm; and 3) Dental expansion: inter-canine width, 3.96 mm; inter-premolar width, 4.99 mm and inter-molar width, 5.99 mm. The percentage of expansion demonstrated a skeletal expansion (PNS) of 55.76%, alveolar molar width expansion of 24.37% and dental expansion of 19.87%. **Conclusions:** In the coronal view, the skeletal and dental expansion created by MARPE was of the pyramidal pattern. MARPE could successfully expand the constricted maxilla in late adolescents and adult patients.

Key words: Evidence-based orthodontics, Microimplant assisted rapid maxillary expansion, Miniscrew assisted rapid palatal expansion, Maxillary skeletal expansion

Received October 19, 2021; Accepted December 18, 2021.

Corresponding author: Nita Viwattanatipa.
Associate Professor, Department of Orthodontics, Faculty of Dentistry, Mahidol University, 6 Yothi Rd. Phaya thai district, Bangkok 10400, Thailand.
Tel +66-86-4008716 e-mail Nitaviw@hotmail.com

How to cite this article: Siddhisaributr P, Khlongwanitchakul K, Anuwongnukroh N, Manopatanakul S, Viwattanatipa N. Effectiveness of miniscrew assisted rapid palatal expansion using cone beam computed tomography: A systematic review and meta-analysis. Korean J Orthod. <https://doi.org/10.4041/kjod21.256>

© 2022 The Korean Association of Orthodontists.

This is an Open Access article distributed under the terms of the Creative Commons Attribution Non-Commercial License (<http://creativecommons.org/licenses/by-nc/4.0>) which permits unrestricted non-commercial use, distribution, and reproduction in any medium, provided the original work is properly cited.

INTRODUCTION

A unilateral or bilateral posterior crossbite, or maxillary transverse deficiency (MTD), are frequently found malocclusions in orthodontic treatment. Other discrepancies associated with MTD may involve the skeletal, dentoalveolar, or soft tissue structure and function, such as, Class II or Class III skeletal malocclusion, excessive vertical alveolar height, functional shift of the mandible, crowding, bucco-lingual tipping of the posterior teeth, etc.¹

MTD does not show spontaneous correction and should be treated with maxillary expansion as early as possible.² Generally, the optimal timing for MTD correction using a conventional rapid palatal expansion (RPE) is preferably below the age of 15.³ Unfortunately, in late adolescents and adults, the midpalatal suture and surrounding maxillary sutures start to fuse and become more rigid resulting in a higher resistance to expansion force.⁴ Thus, the nonsurgical conventional RPE would be less successful in adult patients and may lead to undesired complications, such as buccal crown tipping of the posterior teeth, pain, tissue swelling, root resorption, marginal bone loss, gingival recession, limited skeletal expansion, failure, and post-expansion relapse.⁵

Therefore, in adults or from the age of 16 onwards, surgically-assisted RPE (SARPE), is commonly recommended. However, the invasiveness of this surgical procedure, the inherent risks of surgical operation, expensive cost, hospitalization, etc. may pose certain limitations for patients undergoing this procedure.^{1,6}

A non-surgical treatment of MTD in adults, using miniscrew assisted rapid palatal expansion (MARPE), was introduced as a possible alternative for SARPE. It is also known as microimplant assisted rapid maxillary expansion (MARME) or maxillary skeletal expansion (MSE).⁷ The device is classified mainly as: 1) bone-anchored maxillary expansion (BAME), which is a bone-borne type having no tooth attachment and 2) hybrid design or tooth-bone-anchored maxillary expansion, which combines both bone and tooth support.^{8,9} MARPE may consist of two to four miniscrews, and may also be mono-cortical or bi-cortical miniscrew anchorage.^{10,11} Among the appliances used for MARPE, MSE is the type that promotes the bi-cortical engagement of the four miniscrews into the cortical bone of the palate and nasal floor.¹²

Recent clinical studies using MARPE demonstrated a high success rate of the midpalatal suture separation in young adults, which ranged from 71–92%.^{1,7,8,13,14} However, failure of the midpalatal suture separation and incidents of asymmetric expansion were reported in some cases.⁸

In adults, several research papers demonstrated that

the transverse expansion of the midpalatal suture, zygomatic bone, temporal bone, lateral pterygoid plate, and nasal cavity occurred to a varied extent using MARPE.^{7,15} The expansion of the maxilla followed a pyramidal pattern. The least expansion was found at the level of the zygoma, which progressively increased across the palate and the greatest expansion was at dentoalveolar level.⁸

The pattern of the midpalatal suture separation by MARPE was different from that of conventional RPE. While RPE resulted in a greater degree of opening in the anterior than the posterior palate, majority of the MARPE studies reported the creation of the parallel split pattern of the midpalatal suture.^{8,12,13,16,17} Moreover, MARPE could create openings between the medial and lateral pterygoid plates without any surgery. The pterygopalatine suture splitting or the pterygomaxillary dysfunction was detectable in 53–84% of the sutures.^{16,17}

Although there were several studies evaluating the skeletal and dental responses of MARPE in adults, its treatment effects still remain controversial. Most of these publications were retrospective with a limited sample size.^{1,8,14,15,18,19}

Only two studies followed a prospective study design.^{20,21} Recently, Jesus et al.²² compared the effectiveness between MARPE and SARPE in late adolescents and adults, which reported similar effectiveness but less complications with MARPE. To the best of our knowledge, no randomized controlled trial (RCT) publication has been conducted on this issue and, both orthodontists and oral-maxillofacial surgeons may be seeking for more concrete evidence of the effectiveness of MARPE.

Thus, our systematic review and meta-analysis study aimed to evaluate the treatment effect of MARPE, with a specific purpose to summarize the treatment outcomes of MARPE in adult patients in the context of skeletal, alveolar, and dental changes using cone-beam computed tomography (CBCT) evaluation.

MATERIALS AND METHODS

This meta-analysis was conducted in accordance with the Preferred Reporting Items for Systematic Reviews and Meta-Analyses (PRISMA) statement guidelines. The Prospero registration number for the study protocol is CRD42021255630.

Eligibility criteria

The PICOS framework was used to construct the inclusion criteria as shown in Table 1.

Search strategy

Five electronic databases (PubMed, Embase, Scopus, Web of Science, and Cochrane Library) were systematically searched up to June 2021. No limits were applied

Table 1. Inclusion and exclusion criteria: PICOS framework

Inclusion criteria	Exclusion criteria
Participants (P) - Adult - Maxillary transverse deficiency	- Children, Growing - Systemic disease/craniofacial anomalies/syndrome
Intervention (I) - Non orthognatic surgery - 4 microimplant assisted rapid maxillary expansion - MARPE, MSE, MARME	- <i>In-vitro</i> /Laboratory/Molecular/Cellular/Animal – Surgery - Finite element study - RME, RPE, SARPE, SARME - Bone distraction - Tooth borne RME - 2 microimplant assisted rapid maxillary expansion
Comparison (C): compared vs. post treatment or MARPE vs. SARPE	
Outcome measures (O) - Cone-beam computed tomography (CBCT) - Skeletal and dental changes	- Non- CBCT
Study design (S) - Randomized controlled trial (RCT) - Cohort study - Case-control study - One-group pretest-posttest design	- Case report/Case series/Opinions/Letter to editor - Narrative review/Summary - Systematic review/Meta-analysis - Non-English

RME, rapid maxillary expansion; RPE, rapid palatal expansion; MARME, microimplant assisted rapid maxillary expansion; MARPE, miniscrew assisted rapid palatal expansion; MSE, maxillary skeletal expansion; SARME, surgically-assisted RME; SARPE, surgically-assisted RPE.

for the language or publication date. Dissertations and conference proceedings retrieved from the electronic database were also included. In addition, secondary search from reference lists of systematic review and meta-analyses articles were manually examined and any papers of interest by title or authors were retrieved for possible inclusion. Details of the advanced search keywords have been provided in Appendix.

Duplicated records were deleted using EndNote® 9 (Clarivate Analytics, Philadelphia, PA, USA). Title and abstract of all the identified articles were independently reviewed by two reviewers (P.S. and K.K.) according to the inclusion/exclusion criteria, in a blinded standardized manner. Disagreements between the reviewers were resolved upon discussion with a third researcher (N.V.).

Data collection

Full text papers were retrieved after title and abstract screening. Two reviewers independently extracted the data from relevant studies according to the full text eligibility criteria, and then recorded the data into a data extraction spreadsheet. The extracted data characteristics included the author, year of publication, sample size, study design, setting, race, comparison groups, appliance, diameter and length of the miniscrew, mean age in years, activation protocol and success rate.

Since the CBCT outcomes reported in literature varied

greatly among studies, preliminary screening was necessary to check the adequacy of the number of papers for each value. Overall, 18 skeletal, alveolar, and dental parameters were screened; however, only nine parameters were considered appropriate for the subsequent quantitative analysis. The eligible outcomes were as follows.

- Skeletal expansion: zygomatic width (ZMW), nasal width (NW), jugular width (J-J), and the midpalatal suture at the posterior nasal spine (PNS) and the anterior nasal spine (ANS)
- Alveolar expansion: alveolar molar width (AMW)
- Dental expansion: inter-canine width (ICW), inter-premolar width (IPMW), and inter-molar width (IMW).

Calculation of any raw data that warranted the combined means was carried out with the online application using the sample size, means, and standard deviations in order to obtain the new values.

Meta-analysis

Heterogeneity test (Forest plots, Cochran Q-test, and I² index)

Forest plots were shown as visual assessment of the heterogeneity across the studies. Statistical heterogeneity was assessed using Cochran Q-test at 95% confidence interval (CI) ($p < 0.05$). Moreover, the I² statistics were used to assess the degree of heterogeneity. The

I^2 index was defined as low (25%), moderate (50%), or high (75%). If I^2 was more than 50%, significant heterogeneity would be considered, and the random effect would be used to estimate the pooled means with 95% CI. Else, the fixed effect model would be used.

Publication bias (Funnel plot and Egger's test)

In addition, the publication bias was tested using the funnel plot and Egger's test. If the distribution was equal between each side of the funnel plot, no publication bias was indicated. However, if small studies clustered asymmetrically around the pooled mean estimate line, bias in the study was indicated.

The Egger's test was used to evaluate the symmetry of the funnel plot. If it was significant ($p < 0.05$), a publication bias was considered owing to missing studies or heterogeneity.

Sensitivity analysis

The sensitivity test would be performed if any study was considered to be of poor quality or the source of a publication bias. The method trim and fill procedure by Duval and Tweedie was used to correct the publication bias by imputing the hypothesized missing studies for the newly adjusted pooled-mean estimate. In order to err on the safe side, the sensitivity analysis would also be attempted if any case was considered insignificant but with a p -value closed to 0.05.

Subgroup analysis

If the possible causes of the variation of results were detected across studies, a subgroup analysis was performed.

Risk of bias assessment in individual studies

Risk of bias in individual studies was assessed both at

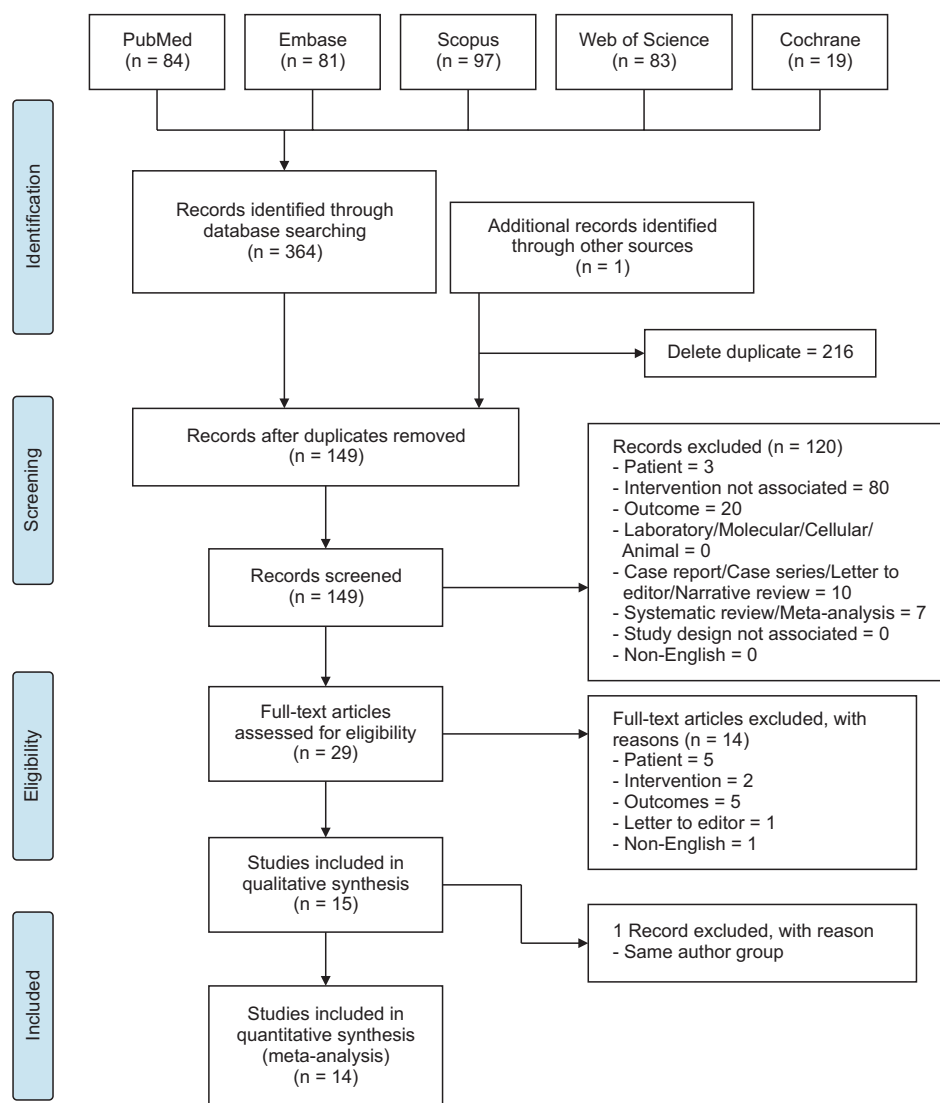


Figure 1. PRISMA (Preferred Reporting Items for Systematic Reviews and Meta-Analyses) flow diagram.

Table 2. Study characteristics

Author	N	Study design	Setting	Race	Compare	Appliance	Appliance design	Diameter length	Mean age (SD)	Activation	Activation period	Success rate
Calil et al. ¹³ (2021)	16	Retrospective cohort	University Dentistry Institute	Brazil	Self ligate vs. MARPE	PecLab appliance (Belo Horizonte, Brazil)	Molar without extension	4 titanium mini-implants of 1.8 mm diameter and 8 mm length	24.92 (7.6)	2/4-turn a day	Until the palatal cusps of maxillary first molars touch the buccal cusps of the mandibular first molars	ND
Cantarella et al. ¹⁶ (2017)	15	Retrospective	University	USA	No	BioMaterials Korea (Hanam, Korea)	Molar without extension	ND	17.2 (4.2)	2 turns per day, then 1 activation per day	Until interincisal diastema appear, then complete when maxillary width was equal to mandibular width	100%*
Clement et al. ²⁰ (2017)	10	Prospective	University	India	No	BioMaterials Korea	Molar without extension	4 titanium mini-implants of 1.8 mm diameter and 11 mm length	21.5 (ND)	2 turns per day	Until the required expansion was achieved	100%*
Elkenawy et al. ²⁵ (2020)	31	Retrospective	University	USA	No	BioMaterials Korea	Molar without extension	4 titanium mini-implants of 1.5 mm diameter and 11 mm length	20.4 (3.2)	2 turns per day, then 1 activation per day	Until interincisal diastema appear, then complete when maxillary width was equal to mandibular width	ND
Jesus et al. ²² (2021)	12	Retrospective cohort	ND	Brazil	SARPE with/without cinch	PecLab appliance	Molar without extension	4 titanium mini-implants, ND	Range 15-39	2 turns a day	For 14 to 18 days, until full correction	ND
Li et al. ²⁶ (2020)	22	Retrospective	University	China	No	BioMaterials Korea	Molar without extension	4 titanium mini-implants of 1.5 mm diameter and 11 mm length	22.6 (4.5)	2 turns every other day	Maxillary skeletal width was no longer less than mandible (mean 38 days)	100%*
Li et al. ¹¹ (2020)	48	Retrospective	University	China	No	BioMaterials Korea	Molar without extension	4 titanium mini-implants of 1.5 mm diameter and 11 mm length	19.4 (3.3)	One-sixth of turn (0.13 mm) each day	Maxillary skeletal width was no longer less than mandible	ND
Lim et al. ¹⁵ (2017)	24	Retrospective	Hospital	Korea	No	Hyrax II (Dentaureum, Ispringen, Germany)	Molar with anterior arm extension	4 titanium mini-implants diameter, 1.8 mm; length, 7 mm; Orilus	21.6 (3.1)	Once a day (0.2 mm)	Until the required expansion was achieved (5 week)	86.84%

Table 2. Continued

Author	N	Study design	Setting	Race	Compare	Appliance	Appliance design	Diameter length	Mean age (SD)	Activation	Activation period	Success rate
Moon et al. ²⁷ (2020)	24	Retrospective	University	Korea	C- expander	BioMaterials Korea	Molar without extension	4 titanium mini-implants of 1.5 mm diameter and 11 mm length	19.2 (5.9)	Once a day (0.2 mm)	Until the required expansion was achieved (5 week)	ND
Ngan et al. ¹⁸ (2018)	8	Retrospective	University	USA	No	BioMaterials Korea	Molar without extension	4 titanium mini-implants of 1.8 mm diameter and 11 mm length	21.9 (1.5)	Varied with the severity of transverse discrepancy	Until the occlusal aspect of lingual cusp of the maxillary first molars contacted occlusal aspect of the buccal cusp of the mandibular first molars. The 2-3 mm of overexpansion	100%*
Nguyen et al. ²⁸ (2021)	20	Retrospective	University	Korea	No	BioMaterials Korea MSE type II	Molar without extension	4 titanium mini-implants of 1.8 mm diameter and 11 mm length	22.4 (17.6-27.1)	2 turns per day (0.13 mm/turn)	Until diastema appeared, after which the rate was reduced to one turn per day, stop when required amount was achieved 20% overexpansion	100%*
de Oliveira et al. ²⁴ (2021)	17/15	Retrospective cohort	University	Brazil	MARPE vs. SARPE	PecLab appliance 9 mm expander	Molar without extension	4 miniscrew unknown diameter and length	MARPE 26 (11) SARPE 28.5 (10.5)	2/4 immediately after mini implant placement and 2/4 turns daily (14-18 days)	Until full correction	86.96%
Park et al. ²⁹ (2017)	14	Retrospective	University	Korea	No	Hyrax II (Dentaurum, Ispringen, Germany)	Molar with anterior arm extension	Diameter, 1.8 mm; length, 7 mm; Orlius	20.1 (2.4)	Once a day (0.2 mm)	Until the required expansion was achieved	84.21%
Tang et al. ⁷ (2021)	31	Retrospective	University	China	No	BioMaterials Korea	Molar without extension	4 titanium mini-implants of 1.5 mm diameter and 11 mm length	22.14 (4.76)	Once a day (0.13 mm)	Ranging from 40 to 60 turns	92%

Success rate, the percentage of patients who exhibited success of maxillary expansion to required amount; 100%*, author mentioned successful midpalatal suture split, however there was no numerical percentage reported; SD, standard deviation; MARPE, miniscrew assisted rapid palatal expansion; SARPE, surgically-assisted rapid palatal expansion; ND, no data.

the methodology and outcome level by two reviewers (P.S., K.K.). The criteria was modified from the method reported by Feldmann and Bondemark.²³ The assessment included study design, sample size, selection description, measurement method, method error analysis, blinding in measurement, statistical method, and confounding factors.

RESULTS

Search strategy

The PRISMA flow diagram demonstrating the search and selection of studies is shown in Figure 1. The initial 364 results from the 5 databases were as follows: PubMed, 84; Embase, 81; Scopus, 97; Web of Science, 83; and Cochrane Library, 19. Through manual searching, 1 article was found from Google Scholar. The remaining 149 articles were screened based on the titles and abstracts. Inter-reviewer agreement on the study

Table 3. Outcomes classified by skeletal, alveolar molar width, and dental expansion

Variable	Author	N	Mean	SD	Combined measurements
ZMW	Elkenawy et al. ²⁵ (2020)	31	3.99	1.60	
	Li et al. ²⁶ (2020)	22	0.50	1.00	
	Li et al. ¹¹ (2020)	48	1.77	0.90	3 groups*
	Tang et al. ⁷ (2021)	31	1.45	1.04	
NW	Calil et al. ¹³ (2021)	16	2.82	1.54	
	Jesus et al. ²² (2021)	12	3.46	1.95	ant./post.*
	Li et al. ²⁶ (2020)	22	2.30	1.20	
	Li et al. ¹¹ (2020)	48	3.58	1.39	3 groups*
	Lim et al. ¹⁵ (2017)	24	2.20	1.01	
	Moon et al. ²⁷ (2020)	24	2.45	1.37	
	Ngan et al. ¹⁸ (2018)	8	2.53	0.53	
	de Oliveira et al. ²⁴ (2021)	17	2.91	1.62	ant./post.*
	Tang et al. ⁷ (2021)	31	2.33	1.22	
	J-J	Calil et al. ¹³ (2021)	16	3.06	1.81
Jesus et al. ²² (2021)		12	3.20	1.92	
Li et al. ²⁶ (2020)		22	2.00	1.00	
Li et al. ¹¹ (2020)		48	4.69	1.31	3 groups*
Tang et al. ⁷ (2021)		31	2.65	0.98	
PNS	Cantarella et al. ¹⁶ (2017)	15	4.33	1.74	
	Elkenawy et al. ²⁵ (2020)	31	4.77	2.65	
	Ngan et al. ¹⁸ (2018)	8	3.27	0.46	
	Nguyen et al. ²⁸ (2021)	20	3.95	0.50	
	de Oliveira et al. ²⁴ (2021)	17	2.75	0.85	
ANS	Cantarella et al. ¹⁶ (2017)	15	4.75	2.59	
	Elkenawy et al. ²⁵ (2020)	31	4.98	1.94	
	Ngan et al. ¹⁸ (2018)	8	3.53	0.80	
	Nguyen et al. ²⁸ (2021)	20	4.83	0.53	
	de Oliveira et al. ²⁴ (2021)	17	3.69	1.42	

N, sample size; SD, standard deviation; ZMW, zygomatic width; NW, nasal width; J-J, jugular width; PNS, midpalatal suture at the posterior nasal spine; ANS, midpalatal suture at the anterior nasal spine.

*Combined mean and SD from multiple groups using an online calculator <https://www.statstodo.com/CombineMeansSDs.php>

eligibility was 96% (6/149). After abstract screening, 29 articles met the inclusion criteria. Thereafter, the full texts were examined. The remaining 15 studies were used in the quantitative analysis. However, since there were two studies by de Oliveira et al.,²⁴ which may have used the same group of subjects, only one study with the most recent information was selected to prevent double-counting of the data. Finally, 14 studies were eligible for the meta-analysis.

Study characteristics

The characteristics of each study are shown in Table 2. Ten studies were of the retrospective one-group pretest-posttest design.^{7,11,15,16,18,25-29} Three were retrospective cohort studies,^{13,22,24} and one was a prospective study.²⁰

The sample size ranged from eight to 48 patients. Considering the appliance design, two studies used modified Hyrax II (Dentaurum, Ispringen, Germany) with extension to the first premolars,^{15,29} three studies used Peclab appliance (Belo Horizonte, Brazil), and nine

studies used BioMaterials Korea (Hanam, Korea). The device of all studies incorporated four titanium miniscrews with diameter of either 1.5 or 1.8 mm. It should be noted that majority of the studies used miniscrews with the length of 11 mm except two studies, which used miniscrews of 7 mm long.^{15,29} The mean age of most studies was late adolescents to adult patients (> 15 years). The success rate of the midpalatal split ranged from 84% to 100%; however, half of the studies did not report this data.

Meta-analysis

Outcomes of the CBCT measurement from the final recruited papers for skeletal expansion are shown in Table 3. Alveolar molar width and dental expansion are shown in Table 4.

Heterogeneity test (Forest plots, Cochrane Q-test, and I² index)

The forest plots of the skeletal, alveolar molar width,

Table 4. Outcomes of the AMW and dental expansion

Variable	Author	N	Mean	SD	Combined measurements
AMW	Clement et al. ²⁰ (2017)	10	6.50	1.51	
	Lim et al. ¹⁵ (2017)	24	2.60	0.85	
	Nguyen et al. ²⁸ (2021)	20	4.19	0.67	
	de Oliveira et al. ²⁴ (2021)	17	3.86	1.20	
ICW	Calil et al. ¹³ (2021)	16	3.04	2.03	
	Clement et al. ²⁰ (2017)	10	5.83	1.32	
	Lim et al. ¹⁵ (2017)	24	3.02	1.25	
IPMW	Calil et al. ¹³ (2021)	32	3.63	2.14	1st/2nd PM*
	Clement et al. ²⁰ (2017)	20	5.50	1.52	1st/2nd PM*
	Lim et al. ¹⁵ (2017)	48	5.87	1.26	1st/2nd PM*
	de Oliveira et al. ²⁹ (2021)	17	5.21	2.25	
	Park et al. ²⁹ (2017)	14	5.50	1.40	
IMW	Calil et al. ¹³ (2021)	16	6.37	1.72	
	Clement et al. ²⁰ (2017)	10	7.33	1.96	
	Jesus et al. ²² (2021)	12	5.82	2.03	
	Li et al. ¹¹ (2020)	48	6.95	1.25	3 groups*
	Lim et al. ¹⁵ (2017)	24	5.63	1.90	
	Moon et al. ²⁷ (2020)	24	4.91	1.50	
	Ngan et al. ¹⁸ (2018)	8	6.26	1.31	
	de Oliveira et al. ²⁴ (2021)	17	5.25	2.34	
	Park et al. ²⁹ (2017)	14	5.40	1.70	

N, sample size; SD, standard deviation; AMW, alveolar molar width; ICW, inter-canine width; IPMW, inter-premolar width; IMW, inter-molar width; PM, premolar.

*Combined mean and SD from multiple groups using an online calculator <https://www.statstodo.com/CombineMeansSDs.php>

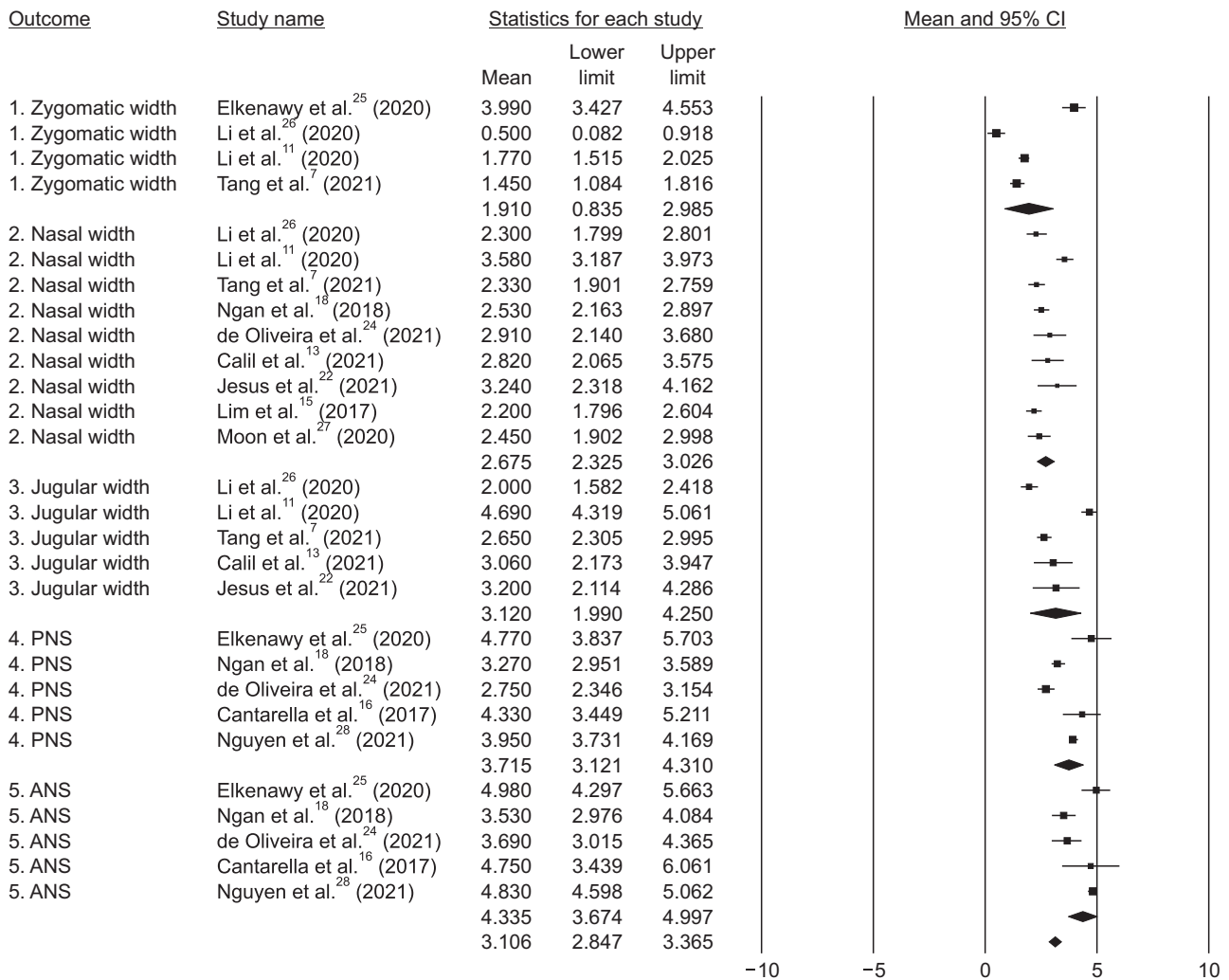


Figure 2. Forest plots of skeletal expansion.

PNS, midpalatal suture at the posterior nasal spine; ANS, midpalatal suture at the anterior nasal spine; CI, confidence interval.

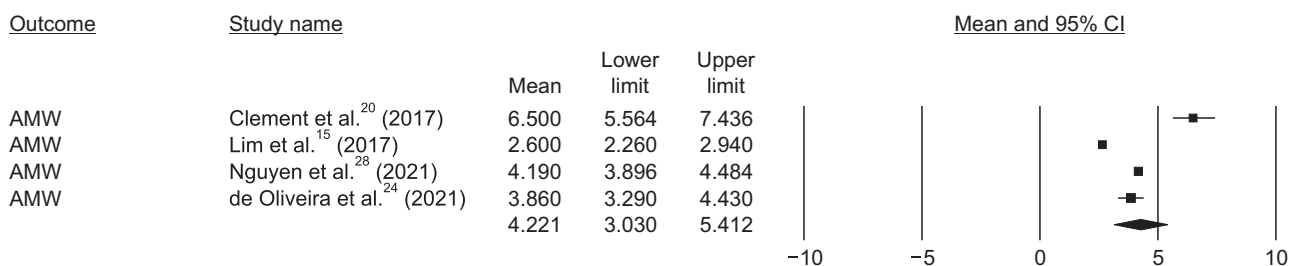


Figure 3. Forest plots of alveolar molar width (AMW) expansion.

CI, confidence interval.

and dental expansion are shown in Figure 2, 3, and 4 respectively. The vertical line of the diagram indicates the point estimate of the means and the horizontal line shows the 95% CI.

According to Table 5, the heterogeneity test indicated that the Q-values of all the variables were statistically significant ($p < 0.05$). Similarly, the I^2 index of all the variables were high ($> 50\%$). Therefore, the random ef-

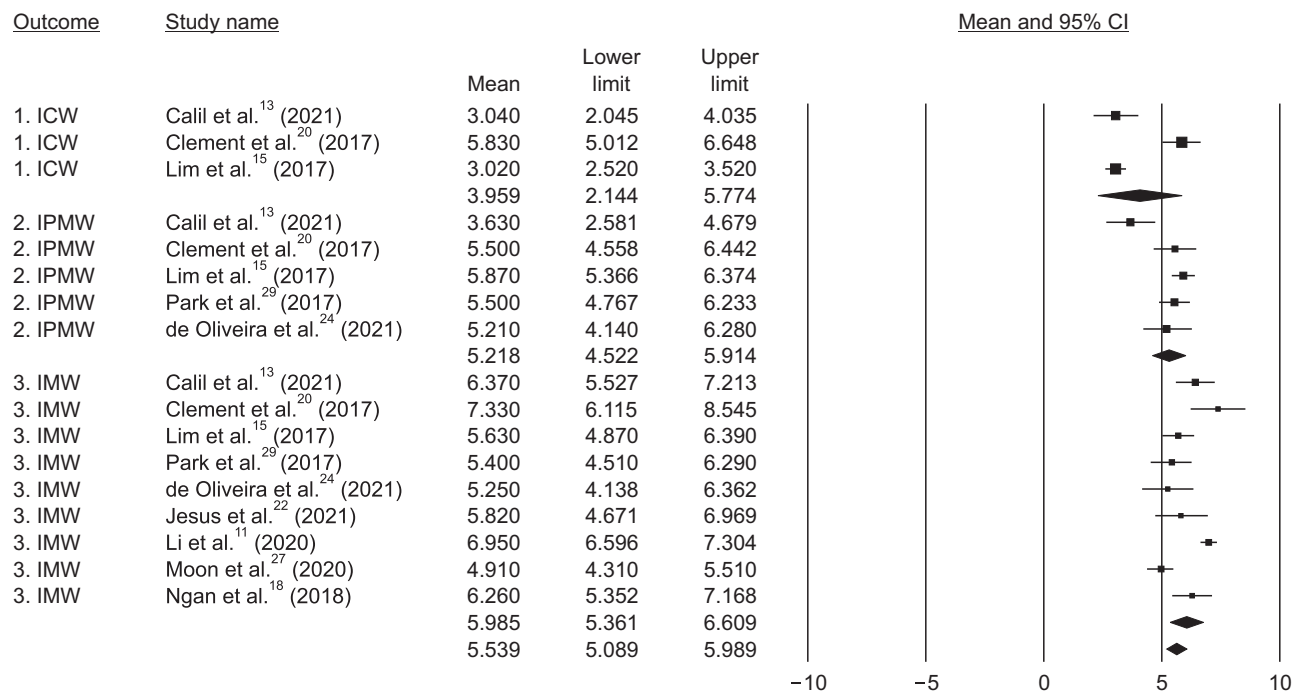


Figure 4. Forest plots of dental expansion.

ICW, inter-canine width; IPMW, inter-premolar width; IMW, inter-molar width; CI, confidence interval.

Table 5. Assessment of the heterogeneity and publication bias (Egger’s test) for skeletal, alveolar molar width (AMW), and dental expansion

Group	Parameter	n/N	Heterogeneity test			Egger’s regression intercept		
			Q-value	p-value	I ²	Intercept	SE	p-value (2-tailed)
Skeletal expansion	ZMW	4/132	97.241	0.000	96.915	5.929	11.815	0.666
	NW	9/202	33.382	0.000	76.035	0.872	2.569	0.744
	J-J	5/129	103.526	0.000	96.136	-0.689	6.924	0.927
	PNS	5/91	39.477	0.000	89.868	0.337	3.467	0.929
	ANS	5/91	26.285	0.000	84.782	-2.116	2.192	0.406
Alveolar expansion	AMW	4/71	85.575	0.000	96.494	6.114	7.562	0.504
Dental expansion	ICW	3/50	34.807	0.000	94.254	5.539	10.361	0.344
	IPMW	5/131	14.460	0.000	72.337	-4.236	2.207	0.151
	IMW	9/173	46.970	0.000	82.968	-2.526	1.880	0.221

SE, standard error; ZMW, zygomatic width; NW, nasal width; J-J, jugular width; PNS, midpalatal suture at the posterior nasal spine; ANS, midpalatal suture at the anterior nasal spine; ICW, inter-canine width; IPMW, inter-premolar width; IMW, inter-molar width.

fect model was used.

Estimation of the pooled means with 95% CI

The pooled mean estimate with 95% CI of skeletal change is shown in Table 6 and Figure 2. Alveolar change is shown in Table 6 and Figure 3. Dental change is shown in Table 6 and Figure 4.

Publication bias

Visual inspection of the data distribution around funnel plots of all the parameters is shown in Figure 5. Moreover, Egger’s regression (Table 5) was also used to supplement the assessment of the publication bias. The results revealed the non-significant p-value of all the parameters.

Table 6. The results of the pooled mean estimate for skeletal, alveolar molar width (AMW), and dental expansion from the meta-analysis including the adjusted values after the method of trim and fill

Group	Parameter	n	N	Mean	SE	95% CI
Skeletal expansion	ZMW	4	132	1.910 (2.385)**	0.548	0.835, 2.985 (1.120, 3.649)**
	NW	9	202	2.675	0.179	2.325, 3.026
	J-J	5	129	3.120	0.576	1.990, 4.250
	PNS	5	91	3.715 (3.337)**	0.303	3.121, 4.310 (2.754, 3.919)**
	ANS	5	91	4.335 (4.562)**	0.338	3.674, 4.997 (3.938, 5.187)**
Alveolar expansion	AMW	4	71	4.221 (4.799)**	0.608	3.030, 5.412 (3.112, 6.486)**
Dental expansion	ICW	3	50	3.959	0.926	2.144, 5.774
	IPMW	5	131	5.218 (4.992)**	0.355	4.522, 5.914 (4.229, 5.755)**
	IMW	9	173	5.985	0.318	5.361, 6.609

n, number of articles; N, number of subjects; SE, standard error; CI, confidence interval; ZMW, zygomatic width; NW, nasal width; J-J, jugular width; PNS, midpalatal suture at the posterior nasal spine; ANS, midpalatal suture at the anterior nasal spine; ICW, inter-canine width; IPMW, inter-premolar width; IMW, inter-molar width. Values in parenthesis ** = adjusted values after the method of trim and fill.

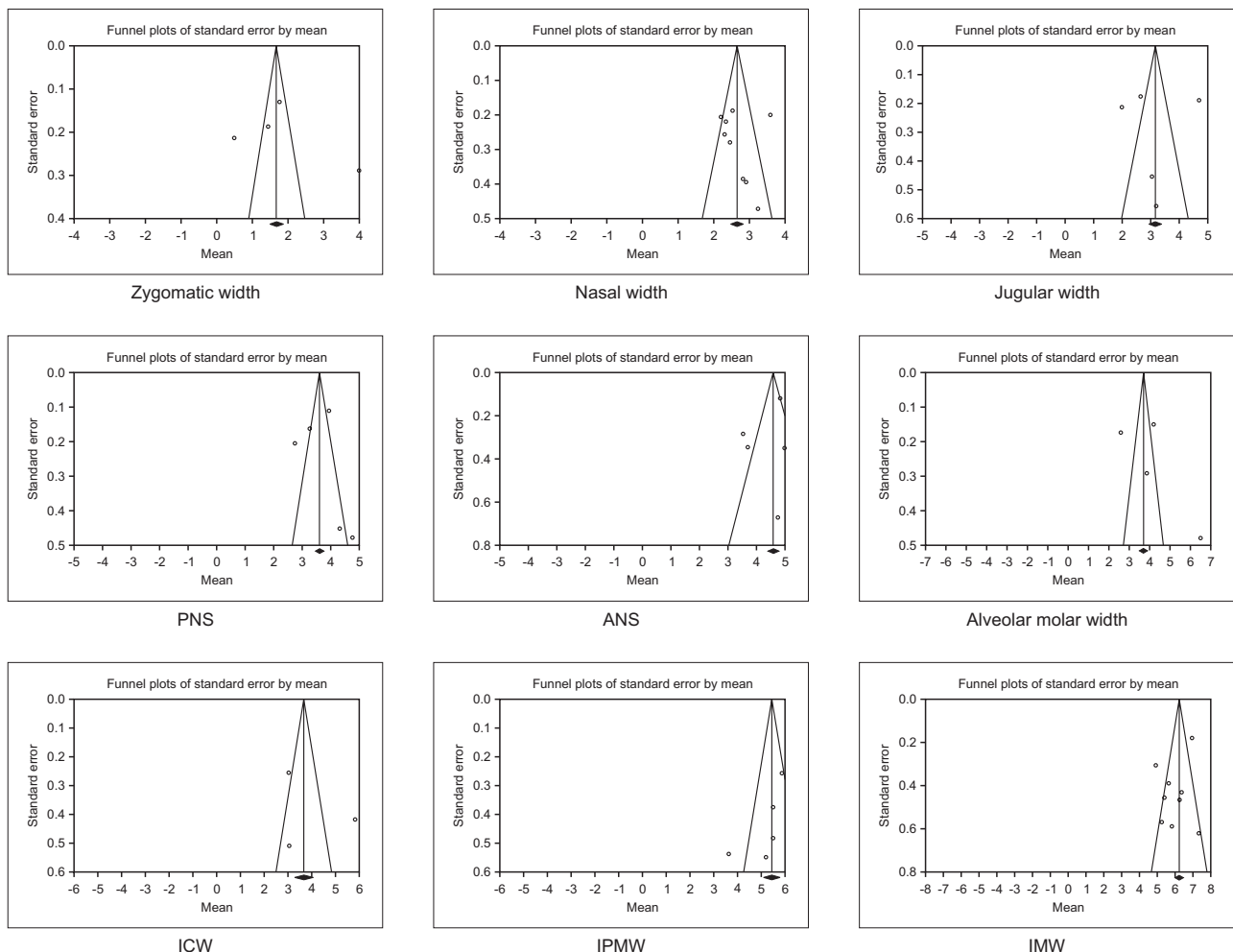


Figure 5. Funnel plots of skeletal, alveolar molar width, and dental expansion from meta-analysis. PNS, midpalatal suture at the posterior nasal spine; ANS, midpalatal suture at the anterior nasal spine; ICW, inter-canine width; IPMW, inter-premolar width; IMW, inter-molar width.

Sensitivity analysis

Owing to the small sample size (< 10) and the possible visual detection of the asymmetric distribution in the funnel plots, the possibility of publication bias could not be excluded. The results from the method of trim and fill is shown in Figure 6. The adjusted pooled mean values are shown in Table 6 as the values in parenthesis. The new pooled mean are as follows: ZMW (2.385 mm), PNS (3.337 mm), ANS (4.562 mm), AMW (4.799 mm), and IPMW (4.992 mm).

Finally, subgroup analysis could not be performed since the small sample size of each parameter was less than three in this study.

Risk of bias within studies

The quality assessment of each study is shown in Table 7. All the studies show low level of quality (scores

4–5), mostly due to the study design, which was a retrospective setting. Five studies showed the method of sample size calculation and considered as score 1.^{11,13,16,25,26} None of the studies showed blinding of the measurement. Only two studies performed the comparison of the confounding factors in the intervention.^{22,24}

DISCUSSION

Our systematic review and meta-analysis included data from 14 studies, which assessed the treatment effects of MARPE in late adolescents and adult patients using CBCT evaluation.

In the coronal view, we found the progressive skeletal and dental expansion following a pyramidal pattern (Figure 7). For skeletal change, the greatest expansion was at the ANS (4.56 mm) followed by the PNS (3.34

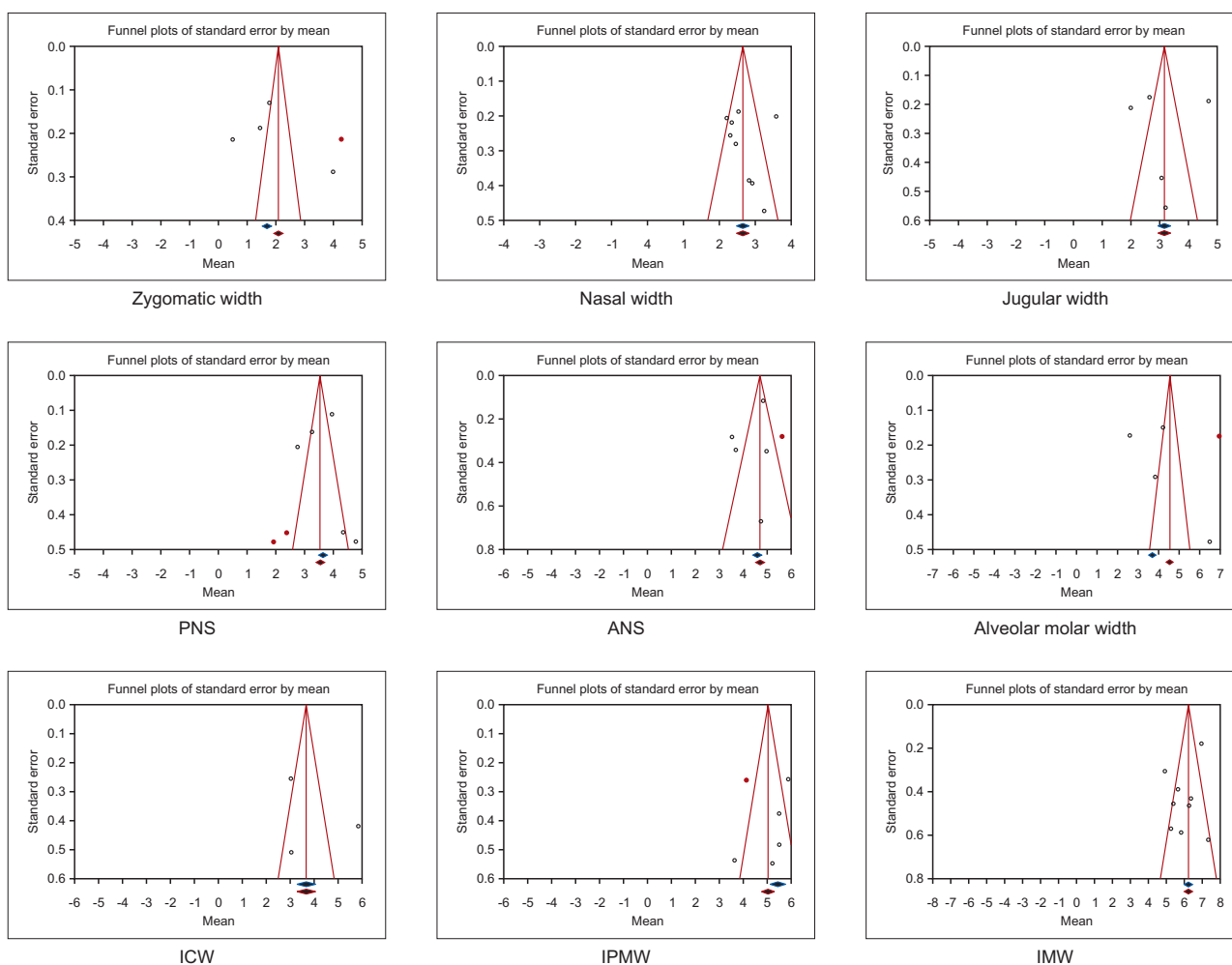


Figure 6. Trim and fill funnel plots of the skeletal, alveolar molar width, and dental expansion from the meta-analysis. Blue diamonds, mean effect size before trim and fill method; Red diamonds, mean effect size after trim and fill method; PNS, posterior nasal spine; ANS, anterior nasal spine; ICW, inter-canine width; IPMW, inter-premolar width; IMW, inter-molar width.

Table 7. Assessment of the risk of bias within studies

Study	Study design	Sample size	Selection description	Valid measurement method	Method error analysis	Blinding	Statistics	Confounding factors	Total score	Judged quality standard
Calil et al. ¹³ (2021)	0	1	1	1	1	0	1	0	5	Low
Cantarella et al. ¹⁶ (2017)	0	1	1	1	1	0	1	0	5	Low
Clement et al. ²⁰ (2017)	1	0	1	1	0	0	1	0	4	Low
Elkenawy et al. ²⁵ (2020)	0	1	1	1	1	0	1	0	5	Low
Jesus et al. ²² (2021)	0	0	1	1	1	0	1	1	5	Low
Li et al. ²⁶ (2020)	0	1	1	1	1	0	1	0	5	Low
Li et al. ¹¹ (2020)	0	1	1	1	1	0	1	0	5	Low
Lim et al. ¹⁵ (2017)	0	0	1	1	1	0	1	0	4	Low
Moon et al. ²⁷ (2020)	0	0	1	1	1	0	1	0	4	Low
Ngan et al. ¹⁸ (2018)	0	0	1	1	1	0	1	0	4	Low
Nguyen et al. ²⁸ (2021)	0	0	1	1	1	0	1	0	4	Low
de Oliveira et al. ²⁴ (2021)	0	0	1	1	1	0	1	1	5	Low
Park et al. ²⁹ (2017)	0	0	1	1	1	0	1	0	4	Low
Tang et al. ⁷ (2021)	0	0	1	1	1	0	1	0	4	Low
Overall estimate									4.5	Low

Study design: Randomized controlled trial = 3, Prospective = 1, Retrospective = 0, Case series/Case report = 0; Sample size: Adequate (number of samples at least 25 patients) = 1, Inadequate = 0; Selection description: Adequate = 1, Need recalculation = 0; Measurement method: Valid = 1, Invalid = 0; Method error analysis: Yes = 1, No = 0; Blinding in measurement: Yes = 1, No = 0; Statistics: Adequate = 1, Inadequate = 0; Confounding factor stated: Yes = 1, No = 0. Criteria was modified from the method by Bondemark and Feldmann (Angle Orthod 2006;76:493-501).²³

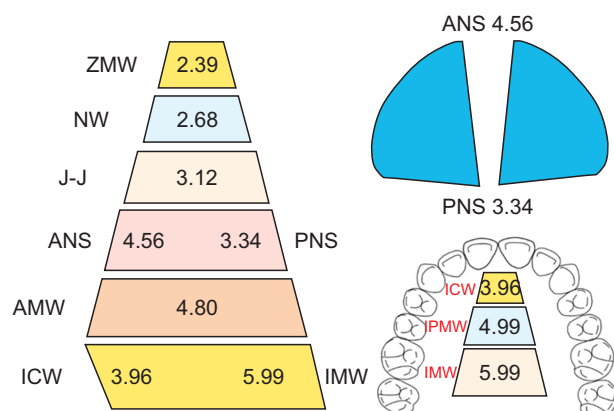


Figure 7. Summary of the adjusted pooled mean estimate of the skeletal, alveolar molar width and dental expansion, unit is millimeters (mm).

ZMW, zygomatic width; NW, nasal width; J-J, jugular width; PNS, midpalatal suture at the posterior nasal spine; ANS, midpalatal suture at the anterior nasal spine; AMW, alveolar molar width; ICW, inter-canine width; IPMW, inter-premolar width; IMW, inter-molar width.

mm), J-J width (3.12 mm), NW (2.68 mm), and ZMW (2.39 mm). The amount of AMW change was 4.80 mm. Considering the dental change, the greatest expansion was at the IMW (5.99 mm), followed by the IPMW (4.99 mm), and the least expansion was at the ICW (3.96 mm). Overall, the results indicated that MARPE could deliver maxillary expansion in late adolescents and adult patients with differential amount of skeletal expansion, alveolar bone bending, and dental tipping effects.

Skeletal expansion

Our meta-analysis results were generally in agreement with most studies that found the expansion pattern, in coronal perspective, to be largest at the inferior level, which gradually decreased superiorly.^{7,8,29} The greatest skeletal expansion was at the palate and least expansion at the anatomical structures farther away from the MARPE device. This phenomenon could be explained by the finite element study. It was demonstrated that the stresses distributed from MARPE resulted in tension and compression directed to the palate.³⁰

Midpalatal suture separation

Considering the midpalatal suture separation, majority of the studies reported that MARPE created the parallel split pattern of midpalatal suture.^{8,12,13,16,17}

However, our study showed V-shape expansion pattern with more opening in the anterior (ANS) and less opening in the posterior part (PNS) with a posterior-anterior ratio of 73.25% (adjusted value of PNS 3.34 mm/ANS 4.56 mm). This ratio was less than the value reported by

Baik et al.⁸ who reported a 90% ratio and Cantarella et al.¹⁶ who reported an 89.6% ratio (PNS 4.3 mm/ANS 4.8 mm).

Although the skeletal and dental effects of MARPE had been reported by several studies, to our knowledge, only one systematic review paper by Coloccia et al.³¹ and 1 meta-analysis paper by Kapetanović et al.¹ were found. Following the comparative assessment, we found that our study showed superior strength than these two publications, which was attributed to our robust inclusion criteria and homogenous study characteristics.

Comparison of our study with Coloccia et al.³¹ revealed that only 3 of the recruited papers were the same; however, 11 papers differed from our study. The reason of this dissimilarity was the average age of the several papers in Coloccia et al.'s³¹ included young children (mean age ranged from 9.3 to 22.6 years). In addition, they also included both bone-borne and hybrid expander supported with either two or four miniscrews, while our study recruited only the hybrid expander with four miniscrews.

In the meta-analysis study by Kapetanović et al.,¹ five recruited papers were the same but four papers were different from our study. It should be noted that Kapetanović et al.¹ recruited the mixed outcomes measured from CBCT images, two-dimensional radiographs, or dental casts while our study strictly recruited only the CBCT studies. Moreover, the skeletal width increase (2.33 mm) in their study was pooled from various anatomical landmarks, such as the midpalatal suture, jugular, nasal floor, or hard palate while our study separated the levels of these landmarks. Similarly, only one IMW value was reported for dental expansion by Kapetanović et al.¹ while our study included the ICW, IPMW, and IMW. Therefore, the validity of the values reported in their study could be questionable. Thus, the pattern of skeletal and dental expansion could be better distinguished in our study.

To our knowledge, only two retrospective cohort studies by Jesus et al.²² and de Oliveira et al.²⁴ compared the effectiveness between MARPE and SARPE in late adolescents and adults. They concluded that MARPE could produce better skeletal changes and parallel palatal expansion with less dentoalveolar changes than SARPE. Our result also demonstrated that MARPE could create skeletal changes with the percentage two times greater than the dental change. However, our V-shape midpalatal suture expansion was not in agreement with the above two papers. Owing to this conflicting point, more cohort or RCT studies are warranted to verify the expansion effect of MARPE in comparison with SARPE.

Dental effect

According to Figure 7 and Table 6, we found that the

pattern of dental expansion was dissimilar to the mid-palatal suture expansion. The mean dental expansion was greatest at molars, which then reduced progressively towards the canine contradictory to the PNS-ANS expansion pattern. This phenomenon could imply a greater buccally tipping of the maxillary first molar than the premolar and canines, respectively. This buccal tipping of the molar was observed following MARPE, which ranged from 2–8°. ^{15,18,27} Thus, it may be suggested to clinicians that some dental tipping could still occur upon using the MARPE appliance.

Percentage expansion

In our study, the percentage of skeletal expansion (PNS) was 55.76%, AMW expansion was 24.37%, and dental expansion (IMW) was 19.87%. Our results indicated that MARPE promotes twice the amount of skeletal than dental expansion.

Interestingly, the percentage expansion was different among the CBCT studies. Our study and Clement et al.'s²⁰ demonstrated that the percentage of midpalatal suture expansion was above 50%, which was greater than the dental expansion; while the other three CBCT studies showed greater dental expansion than skeletal expansion. ^{15,18,29} These contradictory results could be attributed to the various confounding parameters, such as difference in the anatomical landmarks, appliance design, appliance position, or cortical engagement of miniscrews, etc.

Indirect comparison with SARPE

Most clinicians are interested to know whether MARPE and SARPE with pterygoid dysjunction had comparable effects. Thus far, only one meta-analysis of SARPE was published by Bortolotti et al.³² Indirect comparison with our study demonstrated that the skeletal expansion in SARPE (3.3 mm) accounted for nearly 50% of the total expansion, which was comparable with a MARPE value of 55.76% in our study (3.34 mm at PNS). However, SARPE created greater dental expansion (IMW 7.0 mm) than MARPE (IMW 5.99 mm). The limited evidence at present could imply that MARPE was capable of a more skeletal than dental effect, which could be considered comparable to SARPE.

Limitations

Owing to the fact that the included papers in this study were mostly of retrospective one-group pretest-posttest study design with a small sample size (< 25), it failed to attain high-level quality of evidence, which is a crucial point in evidence-based decision-making.

Residual heterogeneity could also exist in some studies, which could have influenced the results slightly. For example, the mean age of the patients in the studies of

Cantarella et al.,¹⁶ Li et al.,¹¹ and Moon et al.,²⁷ which was 17.2, 19.4, and 19.2 respectively, may include a few participants who could be around 15 years old. Considering the device design, two studies had the extension arm to the premolars while the rest of studies did not. Also, ICW was included only in three of the studies. In addition, factors which may be associated with MARPE outcomes such as mono- or bi-cortical miniscrew, asymmetric expansion, pterygomaxillary dysjunction could not be evaluated owing to very few studies (less than 3 papers). Thus, these parameters should be included in future studies.

Lastly, clinicians should interpret this conclusion with caution and should consider the potential benefits of the effectiveness of the treatment against its side effects. Besides, further well-designed cohort studies or randomized clinical trials should be conducted in the future to strengthen the conclusion and determine the effectiveness of MARPE.

CONCLUSION

- In the coronal view, MARPE resulted in skeletal and dental expansion following a pyramidal pattern.
- The pooled mean effects of skeletal expansion were as follows: ZMW, 2.39 mm; NW, 2.68 mm; J-J, 3.12 mm; PNS, 3.34 mm; and ANS, 4.56 mm.
- Midpalatal suture split demonstrated a V-shape pattern with greater expansion at the ANS than PNS.
- Posterior-anterior ratio (PNS/ANS) of midpalatal suture separation was 73.24%.
- The pooled mean effect of AMW was 4.80 mm.
- The pooled mean effects of dental expansion were as follows: ICW, 3.96 mm; IPMW, 4.99 mm; and IMW, 5.99 mm.
- The percentage of effects of the skeletal (PNS), AMW, and dental (IMW) expansion were 55.76%, 19.87%, and 24.37%, respectively.
- MARPE could expand the constricted maxilla in late adolescents to adult patients.

CONFLICTS OF INTEREST

No potential conflict of interest relevant to this article was reported.

ACKNOWLEDGEMENTS

The authors would like to acknowledge Faculty of Dentistry, Mahidol University for research funding support.

REFERENCES

- Kapetanović A, Theodorou CI, Bergé SJ, Schols JGJH, Xi T. Efficacy of Miniscrew-Assisted Rapid Palatal Expansion (MARPE) in late adolescents and adults: a systematic review and meta-analysis. *Eur J Orthod* 2021;43:313-23.
- Baccetti T, Franchi L, Cameron CG, McNamara JA Jr. Treatment timing for rapid maxillary expansion. *Angle Orthod* 2001;71:343-50.
- Melsen B, Melsen F. The postnatal development of the palatomaxillary region studied on human autopsy material. *Am J Orthod* 1982;82:329-42.
- Jimenez-Valdivia LM, Malpartida-Carrillo V, Rodríguez-Cárdenas YA, Dias-Da Silveira HL, Arriola-Guillén LE. Midpalatal suture maturation stage assessment in adolescents and young adults using cone-beam computed tomography. *Prog Orthod* 2019;20:38.
- Handelman CS, Wang L, BeGole EA, Haas AJ. Non-surgical rapid maxillary expansion in adults: report on 47 cases using the Haas expander. *Angle Orthod* 2000;70:129-44.
- Carvalho PHA, Moura LB, Trento GS, Holzinger D, Gabrielli MAC, Gabrielli MFR, et al. Surgically assisted rapid maxillary expansion: a systematic review of complications. *Int J Oral Maxillofac Surg* 2020;49:325-32.
- Tang H, Liu P, Liu X, Hou Y, Chen W, Zhang L, et al. Skeletal width changes after mini-implant-assisted rapid maxillary expansion (MARME) in young adults. *Angle Orthod* 2021;91:301-6.
- Baik HS, Kang YG, Choi YJ. Miniscrew-assisted rapid palatal expansion: a review of recent reports. *J World Fed Orthod* 2020;9(3S):S54-8.
- Sarraj M, Akyalcin S, He H, Xiang J, AlSaty G, Celenk-Koca T, et al. Comparison of skeletal and dentoalveolar changes between pure bone-borne and hybrid tooth-borne and bone-borne maxillary rapid palatal expanders using cone-beam computed tomography. *APOS Trends Orthod* 2021;11:32-40.
- Lee SY, Choi YJ. Reader's forum: skeletal and dentoalveolar changes after miniscrew-assisted rapid palatal expansion in young adults: a cone-beam computed tomography study. *Korean J Orthod* 2017;47:213-4.
- Li N, Sun W, Li Q, Dong W, Martin D, Guo J. Skeletal effects of monocortical and bicortical mini-implant anchorage on maxillary expansion using cone-beam computed tomography in young adults. *Am J Orthod Dentofacial Orthop* 2020;157:651-61. Erratum in: *Am J Orthod Dentofacial Orthop* 2020;158:318.
- Brunetto DP, Sant'Anna EF, Machado AW, Moon W. Non-surgical treatment of transverse deficiency in adults using Microimplant-assisted Rapid Palatal Expansion (MARPE). *Dental Press J Orthod* 2017;22:110-25.
- Calil RC, Marin Ramirez CM, Otazu A, Torres DM, Gurgel JA, Oliveira RC, et al. Maxillary dental and skeletal effects after treatment with self-ligating appliance and miniscrew-assisted rapid maxillary expansion. *Am J Orthod Dentofacial Orthop* 2021;159:e93-101.
- Choi SH, Shi KK, Cha JY, Park YC, Lee KJ. Nonsurgical miniscrew-assisted rapid maxillary expansion results in acceptable stability in young adults. *Angle Orthod* 2016;86:713-20.
- Lim HM, Park YC, Lee KJ, Kim KH, Choi YJ. Stability of dental, alveolar, and skeletal changes after miniscrew-assisted rapid palatal expansion. *Korean J Orthod* 2017;47:313-22.
- Cantarella D, Dominguez-Mompell R, Mallya SM, Moschik C, Pan HC, Miller J, et al. Changes in the midpalatal and pterygopalatine sutures induced by micro-implant-supported skeletal expander, analyzed with a novel 3D method based on CBCT imaging. *Prog Orthod* 2017;18:34.
- Colak O, Paredes NA, Elkenawy I, Torres M, Bui J, Jahangiri S, et al. Tomographic assessment of palatal suture opening pattern and pterygopalatine suture disarticulation in the axial plane after midfacial skeletal expansion. *Prog Orthod* 2020;21:21.
- Ngan P, Nguyen UK, Nguyen T, Tremont T, Martin C. Skeletal, dentoalveolar, and periodontal changes of skeletally matured patients with maxillary deficiency treated with microimplant-assisted rapid palatal expansion appliances: a pilot study. *APOS Trends Orthod* 2018;8:71-85.
- Shin H, Hwang CJ, Lee KJ, Choi YJ, Han SS, Yu HS. Predictors of midpalatal suture expansion by miniscrew-assisted rapid palatal expansion in young adults: a preliminary study. *Korean J Orthod* 2019;49:360-71.
- Clement EA, Krishnaswamy NR. Skeletal and dentoalveolar changes after skeletal anchorage-assisted rapid palatal expansion in young adults: a cone beam computed tomography study. *APOS Trends Orthod* 2017;7:113-9.
- Lee SR, Lee JW, Chung DH, Lee SM. Short-term impact of microimplant-assisted rapid palatal expansion on the nasal soft tissues in adults: a three-dimensional stereophotogrammetry study. *Korean J Orthod* 2020;50:75-85.
- Jesus AS, Oliveira CB, Murata WH, Gonçalves ES, Pereira-Filho VA, Santos-Pinto A. Nasomaxillary effects of miniscrew-assisted rapid palatal expansion and two surgically assisted rapid palatal expansion

- approaches. *Int J Oral Maxillofac Surg* 2021;50:1059-68.
23. Feldmann I, Bondemark L. Orthodontic anchorage: a systematic review. *Angle Orthod* 2006;76:493-501.
 24. de Oliveira CB, Ayub P, Ledra IM, Murata WH, Suzuki SS, Ravelli DB, et al. Microimplant assisted rapid palatal expansion vs surgically assisted rapid palatal expansion for maxillary transverse discrepancy treatment. *Am J Orthod Dentofacial Orthop* 2021;159:733-42.
 25. Elkenawy I, Fijany L, Colak O, Paredes NA, Gargoum A, Abedini S, et al. An assessment of the magnitude, parallelism, and asymmetry of micro-implant-assisted rapid maxillary expansion in non-growing patients. *Prog Orthod* 2020;21:42.
 26. Li Q, Tang H, Liu X, Luo Q, Jiang Z, Martin D, et al. Comparison of dimensions and volume of upper airway before and after mini-implant assisted rapid maxillary expansion. *Angle Orthod* 2020;90:432-41.
 27. Moon HW, Kim MJ, Ahn HW, Kim SJ, Kim SH, Chung KR, et al. Molar inclination and surrounding alveolar bone change relative to the design of bone-borne maxillary expanders: a *CBCT* study. *Angle Orthod* 2020;90:13-22.
 28. Nguyen H, Shin JW, Giap HV, Kim KB, Chae HS, Kim YH, et al. Midfacial soft tissue changes after maxillary expansion using micro-implant-supported maxillary skeletal expanders in young adults: a retrospective study. *Korean J Orthod* 2021;51:145-56.
 29. Park JJ, Park YC, Lee KJ, Cha JY, Tahk JH, Choi YJ. Skeletal and dentoalveolar changes after miniscrew-assisted rapid palatal expansion in young adults: a cone-beam computed tomography study. *Korean J Orthod* 2017;47:77-86.
 30. MacGinnis M, Chu H, Youssef G, Wu KW, Machado AW, Moon W. The effects of micro-implant assisted rapid palatal expansion (MARPE) on the nasomaxillary complex--a finite element method (FEM) analysis. *Prog Orthod* 2014;15:52.
 31. Coloccia G, Inchingolo AD, Inchingolo AM, Mancangi G, Montenegro V, Patano A, et al. Effectiveness of dental and maxillary transverse changes in tooth-borne, bone-borne, and hybrid palatal expansion through cone-beam tomography: a systematic review of the literature. *Medicina (Kaunas)* 2021;57:288.
 32. Bortolotti F, Solidoro L, Bartolucci ML, Incerti Parenti S, Paganelli C, Alessandri-Bonetti G. Skeletal and dental effects of surgically assisted rapid palatal expansion: a systematic review of randomized controlled trials. *Eur J Orthod* 2020;42:434-40.

Appendix. Classification of the used search strategy by the electronic database source

Database	Search strategy
PubMed	<p>Search: (((microimplant assisted rapid palatal expan*[Title/Abstract] OR microimplant assisted palatal expan*[Title/Abstract] OR microimplant assisted rapid maxillary expan*[Title/Abstract] OR microimplant assisted maxillary expan*[Title/Abstract] OR mini implant assisted rapid palatal expan*[Title/Abstract] OR mini implant assisted palatal expan*[Title/Abstract] OR mini implant assisted rapid maxillary expan*[Title/Abstract] OR mini implant assisted maxillary expan*[Title/Abstract] OR mini implant maxillary expan*[Title/Abstract] OR miniscrew assisted rapid palatal expan*[Title/Abstract] OR miniscrew assisted palatal expan*[Title/Abstract] OR miniscrew assisted rapid maxillary expan*[Title/Abstract] OR miniscrew assisted maxillary expan*[Title/Abstract] OR microscrew assisted rapid palatal expan*[Title/Abstract] OR microscrew assisted palatal expan*[Title/Abstract] OR microscrew assisted rapid maxillary expan*[Title/Abstract] OR microscrew assisted maxillary expan*[Title/Abstract] OR Bone anchored rapid palatal expan*[Title/Abstract] OR Bone anchored rapid maxillary expan*[Title/Abstract] OR Bone-anchored hybrid Hyrax expan*[Title/Abstract] OR hybrid rapid maxillary expan*[Title/Abstract] OR miniscrew supported hybrid hyrax[Title/Abstract] OR Hybrid Hyrax expan*[Title/Abstract] OR maxillary skeletal expan*[Title/Abstract] OR Tooth bone borne rapid maxillary expan*[Title/Abstract] OR Tooth[Title/Abstract] AND bone borne expan*[Title/Abstract] OR Tooth bone borne RME[Title/Abstract] OR Tooth bone borne RPE[Title/Abstract] OR Surgically assisted rapid palatal expan*[Title/Abstract] OR SARPE[Title/Abstract] OR surgically assisted rapid maxillary expan*[Title/Abstract] OR SARME[Title/Abstract] OR Surgically Assisted Rapid Palatomaxillary Expan*[Title/Abstract] OR MARPE[Title/Abstract] OR MSE[Title/Abstract] OR MARME[Title/Abstract]) AND (CBCT[Title/Abstract] OR Cone Beam CT[Title/Abstract] OR Cone beam computed tomography[Title/Abstract])) AND (Expansion[Title/Abstract])) AND (Maxilla[Title/Abstract] OR Maxillary[Title/Abstract])</p>
Embase	<p>((('microimplant assisted rapid palatal expan*':ab,ti OR 'microimplant assisted palatal expan*':ab,ti OR 'microimplant assisted rapid maxillary expan*':ab,ti OR 'microimplant assisted maxillary expan*':ab,ti OR 'mini implant assisted rapid palatal expan*':ab,ti OR 'mini implant assisted palatal expan*':ab,ti OR 'mini implant assisted rapid maxillary expan*':ab,ti OR 'mini implant assisted maxillary expan*':ab,ti OR 'mini implant maxillary expan*':ab,ti OR 'miniscrew assisted rapid palatal expan*':ab,ti OR 'miniscrew assisted palatal expan*':ab,ti OR 'miniscrew assisted rapid maxillary expan*':ab,ti OR 'miniscrew assisted maxillary expan*':ab,ti OR 'microscrew assisted rapid palatal expan*':ab,ti OR 'microscrew assisted palatal expan*':ab,ti OR 'microscrew assisted rapid maxillary expan*':ab,ti OR 'microscrew assisted maxillary expan*':ab,ti OR 'bone anchored rapid palatal expan*':ab,ti OR 'bone anchored rapid maxillary expan*':ab,ti OR 'bone anchored hybrid hyrax expan*':ab,ti OR 'hybrid rapid maxillary expan*':ab,ti OR 'miniscrew supported hybrid hyrax':ab,ti OR 'hybrid hyrax expan*':ab,ti OR 'maxillary skeletal expan*':ab,ti OR 'tooth bone borne rapid maxillary expan*':ab,ti OR 'tooth bone borne rme':ab,ti) AND 'bone borne expan*':ab,ti OR 'tooth bone borne rpe':ab,ti OR 'tooth bone borne rpe':ab,ti OR 'surgically assisted rapid palatal expan*':ab,ti OR sarpe:ab,ti OR 'surgically assisted rapid maxillary expan*':ab,ti OR sarme:ab,ti OR 'surgically assisted rapid palatomaxillary expan*':ab,ti OR marpe:ab,ti OR mse:ab,ti OR marme:ab,ti) AND (cbct:ab,ti OR 'cone beam ct':ab,ti OR 'cone beam computed tomography':ab,ti) AND expansion:ab,ti AND (maxilla:ab,ti OR maxillary:ab,ti))</p>
Scopus	<p>(TITLE-ABS-KEY("microimplant assisted rapid palatal expan*" OR "microimplant assisted palatal expan*" OR "microimplant assisted rapid maxillary expan*" OR "microimplant assisted maxillary expan*" OR "mini implant assisted rapid palatal expan*" OR "mini implant assisted palatal expan*" OR "mini implant assisted rapid maxillary expan*" OR "mini implant assisted maxillary expan*" OR "mini implant maxillary expan*" OR "miniscrew assisted rapid palatal expan*" OR "miniscrew assisted palatal expan*" OR "miniscrew assisted rapid maxillary expan*" OR "miniscrew assisted palatal expan*" OR "miniscrew assisted maxillary expan*" OR "microscrew assisted rapid palatal expan*" OR "microscrew assisted palatal expan*" OR "microscrew assisted rapid maxillary expan*" OR "microscrew assisted maxillary expan*" OR "Bone anchored rapid palatal expan*" OR "Bone anchored rapid maxillary expan*" OR "Bone anchored hybrid Hyrax expan*" OR "hybrid rapid maxillary expan*" OR "miniscrew supported hybrid hyrax" OR "Hybrid Hyrax expan*" OR "maxillary skeletal expan*" OR "Tooth bone borne rapid maxillary expan*" OR "Tooth and bone borne expan*" OR "Tooth bone borne RME" OR "Tooth bone borne RPE" OR "Surgically assisted rapid palatal expan*" OR SARPE OR "surgically assisted rapid maxillary expan*" OR SARME OR "Surgically Assisted Rapid Palatomaxillary Expan*" OR MARPE OR MSE OR MARME) AND TITLE-ABS-KEY(CBCT OR "Cone Beam CT" OR "Cone beam computed tomography") AND TITLE-ABS-KEY(Expansion) AND TITLE-ABS-KEY(Maxilla OR Maxillary))</p>

Appendix. Continued

Database	Search strategy
Web of Science	ALL FIELDS: ("microimplant assisted rapid palatal expan*" OR "microimplant assisted palatal expan*" OR "microimplant assisted rapid maxillary expan*" OR "microimplant assisted maxillary expan*" OR "mini implant assisted rapid palatal expan*" OR "mini implant assisted palatal expan*" OR "mini implant assisted rapid maxillary expan*" OR "mini implant assisted maxillary expan*" OR "mini implant maxillary expan*" OR "miniscrew assisted rapid palatal expan*" OR "miniscrew assisted palatal expan*" OR "miniscrew assisted rapid maxillary expan*" OR "miniscrew assisted maxillary expan*" OR "microscrew assisted rapid palatal expan*" OR "microscrew assisted palatal expan*" OR "microscrew assisted rapid maxillary expan*" OR "microscrew assisted maxillary expan*" OR "Bone anchored rapid palatal expan*" OR "Bone anchored rapid maxillary expan*" OR "Bone anchored hybrid Hyrax expan*" OR "hybrid rapid maxillary expan*" OR "miniscrew supported hybrid hyrax" OR "Hybrid Hyrax expan*" OR "maxillary skeletal expan*" OR "Tooth bone borne rapid maxillary expan*" OR "Tooth and bone borne expan*" OR "Tooth bone borne RME" OR "Tooth bone borne RPE" OR "Surgically assisted rapid palatal expan*" OR SARPE OR "surgically assisted rapid maxillary expan*" OR SARME OR "Surgically Assisted Rapid Palatomaxillary Expan*" OR MARPE OR MSE OR MARME) AND ALL FIELDS: (CBCT OR "Cone Beam CT" OR "Cone beam computed tomography") AND ALL FIELDS: (Expansion) AND ALL FIELDS: (Maxilla OR Maxillary)
Cochrane Library	"microimplant assisted rapid palatal expan*" OR "microimplant assisted palatal expan*" OR "microimplant assisted rapid maxillary expan*" OR "microimplant assisted maxillary expan*" OR "mini implant assisted rapid palatal expan*" OR "mini implant assisted palatal expan*" OR "mini implant assisted rapid maxillary expan*" OR "mini implant assisted maxillary expan*" OR "mini implant maxillary expan*" OR "miniscrew assisted rapid palatal expan*" OR "miniscrew assisted palatal expan*" OR "miniscrew assisted rapid maxillary expan*" OR "miniscrew assisted maxillary expan*" OR "microscrew assisted rapid palatal expan*" OR "microscrew assisted palatal expan*" OR "microscrew assisted rapid maxillary expan*" OR "microscrew assisted maxillary expan*" OR "Bone anchored rapid palatal expan*" OR "Bone anchored rapid maxillary expan*" OR "Bone anchored hybrid Hyrax expan*" OR "hybrid rapid maxillary expan*" OR "miniscrew supported hybrid hyrax" OR "Hybrid Hyrax expan*" OR "maxillary skeletal expan*" OR "Tooth bone borne rapid maxillary expan*" OR "Tooth and bone borne expan*" OR "Tooth bone borne RME" OR "Tooth bone borne RPE" OR "Surgically assisted rapid palatal expan*" OR SARPE OR "surgically assisted rapid maxillary expan*" OR SARME OR "Surgically Assisted Rapid Palatomaxillary Expan*" OR MARPE OR MSE OR MARME in Title Abstract Keyword AND CBCT OR "Cone Beam CT" OR "Cone beam computed tomography" in Title Abstract Keyword AND Expansion in Title Abstract Keyword AND Maxilla OR Maxillary in Title Abstract Keyword - (Word variations have been searched)