



# A Cohen syndrome patient whose muscle-relaxant effect may have been prolonged during general anesthesia: a case report

Emi Ishikawa, Makiko Shibuya, Yukifumi Kimura, Nobuhito Kamekura, Toshiaki Fujisawa

Department of Dental Anesthesiology, Faculty of Dental Medicine and Graduate School of Dental Medicine, Hokkaido University, Sapporo, Japan

Cohen syndrome is a rare genetic disorder associated with mutations in the VPS13B gene. Individuals with this disorder present with diverse clinical manifestations, including muscle hypotonia, intellectual disabilities, and typical facial characteristics, such as prominent upper central incisors and micrognathia. General anesthesia was administered to a 23-year-old man with Cohen syndrome. Although we observed prominent upper central incisors, an overjet of 10 mm, micrognathia, and thyromental distance of 4 cm, hypotonia was not observed in the patient. Intubation was rendered difficult when performing a direct laryngoscopy. However, smooth intubation was achieved using a video laryngoscope. The patient's train of four (TOF) count remained zero close to 60 min after rocuronium administration, suggesting that the drug's muscle-relaxant effect may have been prolonged. A TOF ratio of 0.79 was confirmed 130 min after rocuronium administration, and a TOF ratio of 1.0 was confirmed after administration of 150 mg of sugammadex. The patient's respiration remained stable after extubation, and no recurarization of muscle relaxation was observed. As demonstrated in this case report, it is important to closely monitor recovery from muscle relaxation and prepare multiple techniques for airway management in general anesthesia management of patients with Cohen syndrome.

**Keywords:** Anesthesia, General; Cohen Syndrome; Muscle Hypotonia; Rocuronium.



This is an Open Access article distributed under the terms of the Creative Commons Attribution Non-Commercial License (<http://creativecommons.org/licenses/by-nc/4.0/>) which permits unrestricted non-commercial use, distribution, and reproduction in any medium, provided the original work is properly cited.



## INTRODUCTION

Cohen syndrome is a rare autosomal recessive disorder with diverse clinical manifestations, including obesity, muscle hypotonia, mental deficiency, intellectual disabilities, and neutropenia. Typical facial characteristics of individuals with Cohen syndrome include prominent upper central incisors, an open-mouth appearance due to the presence of a short upper lip, maxillary hypoplasia, and micrognathia [1-4]. Cohen syndrome is associated

with mutations in VPS13B, a transmembrane protein that plays a role in the development and function of the eye, hematological system, and central nervous system [2]. However, the mechanism by which abnormalities in this protein lead to the Cohen syndrome phenotype is currently unknown [2]. The mutation detection rate is high among Finnish and Old (Order) Amish populations [4] but not particularly high among Japanese populations. Approximately 100-200 cases of Cohen's syndrome have been reported worldwide [1-4]. Although there are a few case reports on general anesthesia management in the

Received: February 2, 2022 • Revised: March 9, 2022 • Accepted: March 11, 2022

Corresponding Author: Emi Ishikawa, Department of Dental Anesthesiology, Faculty of Dental Medicine and Graduate School of Dental Medicine, Hokkaido University, Sapporo, Kita 13, Nishi 7, Kita-ku, Sapporo 060-8586, Japan

Phone & Fax: +81-11-706-4336 E-mail: [esmuint28@den.hokudai.ac.jp](mailto:esmuint28@den.hokudai.ac.jp)

Copyright© 2022 Journal of Dental Anesthesia and Pain Medicine

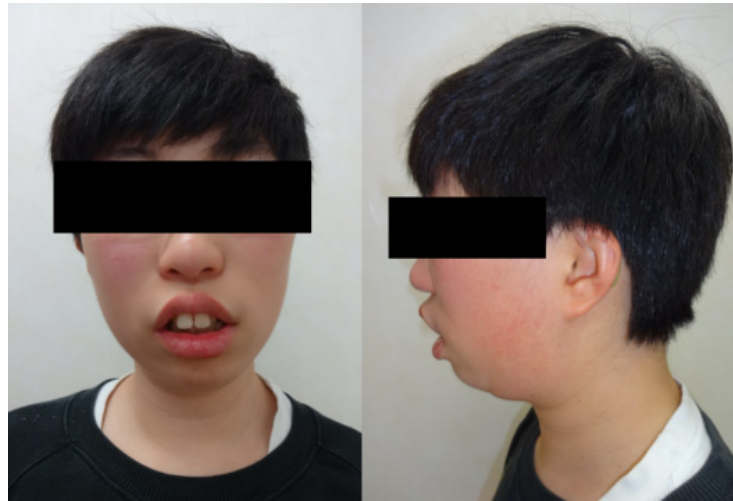

Fig. 1. Patient's facial features. Prominent upper central incisors (overjet of 10 mm), micrognathia, and short thyromental distance (4 cm) were observed.

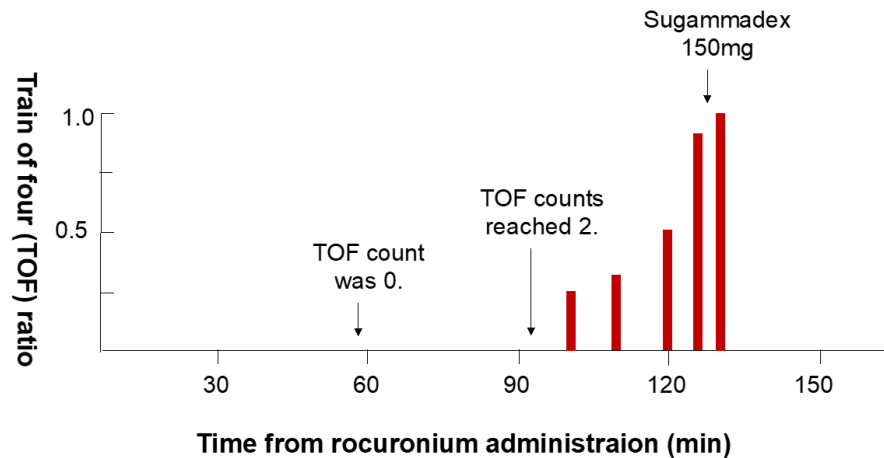


Fig. 2. Process of recovery from muscle relaxation. We used a neuromuscular monitor (TOF Watch) at various timepoints during the surgical procedure. A train of four (TOF) count of 0 was confirmed at 56 min, and TOF counts 1 and 2 were confirmed 95 min after rocuronium administration. A TOF ratio of 1.0 was confirmed after administration of 150 mg of sugammadex.

literature [5-7], no case of prolonged muscle relaxant effects has been reported. This case report details our clinical experience that the muscle-relaxant effect may have been prolonged during general anesthesia in a patient with Cohen syndrome.

## CASE REPORT

A 23-year-old man (height 169 cm; weight 56.6 kg; body mass index 19.8 kg/m<sup>2</sup>) with Cohen syndrome was scheduled to undergo extraction of four impacted wisdom teeth and dental treatment. Both procedures were

scheduled to be performed under general anesthesia because the patient was uncooperative with dental treatment due to intellectual disability.

The patient had been followed up by a pediatrician since childhood and did not take any medications or have a history of aspiration. He had no muscular weakness or hypotonia that could interfere with his daily life, and he had never been diagnosed with hypotonia or musculoskeletal abnormalities. Prominent upper central incisors (overjet of 10 mm), micrognathia, and a short thyromental distance (4 cm) were observed (Fig. 1). It was unclear whether the patient could move the mandible forward because of his intellectual disability. Chest radiography,

12-lead electrocardiography, and blood test results were unremarkable.

The patient entered the operating room while shouting and resisting. Anesthesia was induced with sevoflurane, nitrous oxide, and oxygen. After confirming that assisted ventilation was possible, we administered 40 mg of rocuronium and 100  $\mu$ g of fentanyl. Mask ventilation was possible even after spontaneous breathing had disappeared. Direct laryngoscopy using a Macintosh No. 3 blade (Medtronic, Minneapolis, MS, USA) revealed a Cormack–Lehane score of grade 3. The patient's prominent upper central incisors and narrowed pharyngeal space made intubation using direct laryngoscopy difficult. We successfully visualized the glottis using the McGrath™ MAC video laryngoscope (Medtronic, Minneapolis, MS, USA) and subsequently intubated the patient nasally without complications.

General anesthesia was maintained with sevoflurane and remifentanyl. Rocuronium was not administered after the first dose. Sixty minutes after rocuronium administration, the train of four (TOF) at the adductor pollicis muscle was measured using a neuromuscular monitor (TOF Watch™ SX; MSD, Tokyo, Japan). The TOF count 0 was confirmed to be 56 min, and TOF counts 1 and 2 were confirmed 95 min after rocuronium administration (Fig. 2). The surgery ended 130 min after rocuronium administration, at which point the TOF ratio was 0.79. A TOF ratio of 1.0 was confirmed after administration of 150 mg of sugammadex. After confirming eye opening, reflexes, and recovery of spontaneous breathing, the endotracheal tube was removed. The patient's respiratory condition remained stable after extubation. The operation and anesthesia times were 95 min and 146 min, respectively. The patient's vital signs were stable and unremarkable during post-anesthesia recovery, and no re-occurarization of muscle relaxation was observed.

## DISCUSSION

This case report details safe airway management and

the potential effects of prolonged muscle relaxant usage during general anesthesia in a 23-year-old man with Cohen syndrome.

There is no report that the muscle relaxing effect of muscle relaxants has been prolonged in the general anesthetic management of patients with Cohen syndrome [5-7]. In this case, hypotonia was not observed during the pre-anesthetic evaluation. Regarding the duration of effectiveness, it was not possible to make a simple comparison with drug label information because we were unable to measure control values prior to muscle relaxant administration and did not use continuous neuromuscular monitoring throughout the surgical procedure.

Taguchi et al. [8] reported that the median (25%-75% quartile) time to the appearance of "TOF count 1" in the normocapnia group was 24 (20-30) min. Kim et al. [9] reported that the mean (standard deviation) time to the appearance of "TOF count 2" in the control group was 39 (13) min. In both these studies, the initial dose of rocuronium was 0.6 mg/kg [7], which was 0.1 mg/kg lower than the rocuronium dosage administered in this case. In the present case, the TOF count was zero, close to 60 min after rocuronium administration. Although a simple comparison cannot be made because of the differences in anesthetics used, we suggest that the effects of muscle relaxants were prolonged in this case even though the patient demonstrated no clinical manifestations of hypotonia. Therefore, it is important to confirm recovery from muscle relaxation using neuromuscular monitoring, regardless of the presence or absence of hypotonia, in the management of general anesthesia. Furthermore, we speculate that (1) minimizing the administered dosage of muscle relaxants by using a neuromuscular monitor from the induction of anesthesia until the end of surgery or (2) switching to total intravenous anesthesia for the maintenance of anesthesia from inhalation anesthesia should be considered as inhalational anesthetics with muscle relaxant and muscle relaxant-enhancing effects. Further data accumulation is required to clarify this point.

Preoperative airway assessment using objective

measures should be performed thoroughly in individuals with Cohen's syndrome. This is because the characteristic facial features of patients with Cohen's syndrome can make airway management difficult. Some studies [5,6] have reported no findings suggestive of difficulty in airway management in Cohen syndrome, including intubation in the pre-anesthetic evaluation, and have reported that there was no problem in actual airway management. Conversely, Meng et al. [7] reported that intubation was difficult due to micrognathia and the presence of prominent upper central incisors. It must be considered that sufficient data collection related to mouth opening or relationship of maxillary and mandibular incisors may not be possible in cases in which patients cannot fully cooperate with clinicians' instructions due to intellectual disability [6]. Moreover, it is difficult to attempt awake fiberoptic intubation in uncooperative patients with intellectual disabilities. For all the above reasons, it is important that, as the difficult airway algorithm developed by the American Society of Anesthesiologists [8] states, anesthesiologists should first seek to assess potential problems with patient cooperation and consent in addition to difficulties with mask ventilation, intubation, and surgical airway access. Additionally, multiple techniques for managing difficult airways should be developed. In this case, we predicted that intubation using direct laryngoscopy might be difficult, and prepared a video laryngoscope and a fiber-optic bronchoscope in advance.

In summary, the muscle-relaxant effect may be prolonged even if hypotonia is not observed in patients with Cohen syndrome. Thus, it is important to confirm recovery from muscle relaxation using a neuromuscular monitor. In addition, a preoperative airway assessment using objective measures should be thoroughly performed, and multiple techniques for airway management should be prepared in anticipation of encountering the typical facial characteristics of Cohen syndrome, such as prominent upper central incisors and a short thyromental distance.

#### AUTHOR ORCIDS

**Emi Ishikawa:** <https://orcid.org/0000-0002-5675-1167>  
**Makiko Shibuya:** <https://orcid.org/0000-0003-1476-9921>  
**Yukifumi Kimura:** <https://orcid.org/0000-0002-7334-5179>  
**Nobuhito Kamekura:** <https://orcid.org/0000-0002-7648-0632>  
**Toshiaki Fujisawa:** <https://orcid.org/0000-0001-8694-232X>

#### AUTHOR CONTRIBUTIONS

**Emi Ishikawa:** Conceptualization, Writing - original draft  
**Makiko Shibuya:** Supervision, Writing - review & editing  
**Yukifumi Kimura:** Writing - review & editing  
**Nobuhito Kamekura:** Writing - review & editing  
**Toshiaki Fujisawa:** Supervision, Writing - review & editing

**CONFLICTS OF INTEREST:** The authors declare no conflict of interest.

**CONSENT:** Informed consent was obtained from the patient in this case report.

#### REFERENCES

- Rodrigues JM, Fernandes HD, Caruthers C, Braddock SR, Knutsen AP. Cohen syndrome: review of the literature. *Cureus* 2018; 10: e3330.
- Momtazmanesh S, Rayzan E, Shahkarami S, Rohlf M, Klein C, Rezaei N. A novel VPS13B mutation in Cohen syndrome: a case report and review of literature. *BMC Med Genet* 2020; 21: 140.
- National Organization for Rare Disorders. Rare Disease Database. Cohen syndrome. [Accessed November 28, 2021]. Available from <https://rarediseases.org/rare-diseases/cohen-syndrome/>.
- Genetic and Rare Diseases Information Center. Cohen syndrome. [Accessed November 28, 2021]. Available from <https://rarediseases.info.nih.gov/diseases/6126/cohen-syndrome>.
- Sakanashi M, Miyata Y, Sugahara K. Anesthesia for a patient with Cohen syndrome. *J Clin Anesth* 2003; 27: 1189-90.
- Cavaliere F, Cormaci S, Cormaci M, Alberti A. General anesthesia in Cohen syndrome. Report of a clinical case.

- Minerva Anesthesiol 1995; 61: 163-6.
7. Meng L, Quinlan JJ, Sullivan E. The anesthetic management of a patient with Cohen syndrome. *Anesth Analg* 2004; 99: 697-8.
  8. Taguchi S, Ono K, Hidaka H, Koyama Y. Effect of lung-protective ventilation-induced respiratory acidosis on the duration of neuromuscular blockade by rocuronium. *J Anesth* 2016; 30: 994-8.
  9. Kim MH, Hwang JW, Jeon YT, Do SH. Effects of valproic acid and magnesium sulphate on rocuronium requirement in patients undergoing craniotomy for cerebrovascular surgery. *Br J Anaesth* 2012; 109: 407-12.