



Cystic lesion between a deciduous tooth and the succeeding permanent tooth: a retrospective analysis of 87 cases

Changmo Sohn, Jihye Ryu, Inhye Nam, Sang-Hun Shin, Jae-Yeol Lee

Department of Oral and Maxillofacial Surgery, School of Dentistry, Pusan National University, Yangsan, Korea

Abstract (J Korean Assoc Oral Maxillofac Surg 2022;48:342-347)

Objectives: The purpose of this study is to investigate the characteristics of dentigerous and radicular cysts that occur between deciduous and succeeding permanent teeth and to propose considerations for differential diagnosis of cysts at the treatment planning stage in the outpatient clinic.

Materials and Methods: A total of 87 patients with a cystic lesion located between a deciduous tooth and the succeeding permanent tooth participated in the study. Twelve variables were analyzed to diagnose such a cyst. For data analysis, Fisher's exact test was used to determine the statistical significance of the variables.

Results: Of the total 87 patients who participated in this study, 69 were diagnosed with dentigerous cysts and 18 were diagnosed with radicular cysts. Seven of the 12 differential factors analyzed in this study were statistically significant: age, location, symptoms, dental caries, endodontic treatment, delayed eruption, and size.

Conclusion: Several criteria can be considered for diagnosis of dentigerous cysts or radicular cysts. Age, location, presence of symptoms and dental caries, previous endodontic treatment, cystic size, and delayed eruption of impacted permanent teeth are reliable factors that should be considered when diagnosing dentigerous and radicular cysts.

Key words: Dentigerous cyst, Radicular cyst, Deciduous tooth, Unerupted tooth

[paper submitted 2022. 8. 19 / revised 2022. 9. 20 / accepted 2022. 9. 24]

I. Introduction

Cystic lesions in the jaw can be diagnosed from clinical, radiological, and histopathological features¹. According to the WHO Classification of Head and Neck Tumors updated in 2017, odontogenic cysts can be classified as developmental and inflammatory cysts². Among odontogenic cysts, dentigerous and radicular cysts are the most common developmental and inflammatory types, respectively³⁻⁵. Dentigerous cysts develop from dental follicles of unerupted teeth⁶. Radicular cysts occur as an inflammatory reaction associated with necrotic tooth pulp⁷. Dentigerous cysts are found in the crown

portion of impacted teeth, whereas radicular cysts are observed in the roots^{8,9}.

These two cysts are believed to be easily distinguished depending on location on the tooth. However, they can be ambiguous when they are present in between roots of erupted teeth and the crown of impacted teeth^{10,11}. (Fig. 1) Diagnosis can be difficult in such mixed dentition because root resorption of deciduous teeth and growth and eruption of succeeding permanent teeth can lead to confusion between radicular cysts of deciduous teeth or dentigerous cysts of permanent teeth¹².

Although cyst enucleation is considered for treatment in both cases, supplemental treatment methods can be added depending on the type of cyst. If the pathology is identified as a dentigerous cyst, extraction of the impacted permanent tooth may be included in the treatment. With a radicular cyst, however, extraction or caries treatment on the primary tooth can be considered¹³⁻¹⁶. Proper diagnosis is critical not only to treat patients, but also for patient education, follow-up treatment planning, and future research. Through an accurate diagnosis, patients can be well-educated and have positive attitudes in

Jae-Yeol Lee

Department of Oral and Maxillofacial Surgery, School of Dentistry, Pusan National University, 49 Busandaehak-ro, Mulgeum-eup, Yangsan 50612, Korea

TEL: +82-55-360-5100

E-mail: omslly@pusan.ac.kr

ORCID: <https://orcid.org/0000-0003-0678-2499>

© This is an open-access article distributed under the terms of the Creative Commons Attribution Non-Commercial License (<http://creativecommons.org/licenses/by-nc/4.0/>), which permits unrestricted non-commercial use, distribution, and reproduction in any medium, provided the original work is properly cited.

Copyright © 2022 The Korean Association of Oral and Maxillofacial Surgeons.

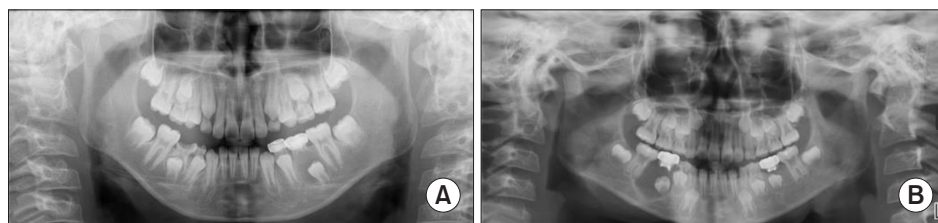


Fig. 1. The panoramic radiographs. A. Dentigerous cyst. B. Radicular cyst. Changmo Sohn et al: Cystic lesion between a deciduous tooth and the succeeding permanent tooth: a retrospective analysis of 87 cases. *J Korean Assoc Oral Maxillofac Surg* 2022

following the doctor's instructions for preventing complications. In addition, medical staff can establish a reasonable treatment plan.

The purpose of this study is to investigate the characteristics of radicular and dentigerous cysts that occur in a location between deciduous and succeeding permanent teeth and to propose outpatient treatment considerations for differential diagnosis of cysts.

II. Materials and Methods

Among the patients who visited Pusan National University Dental Hospital (Yongsan, Korea) from January 2015 to December 2021, we screened 2,189 who were diagnosed with dentigerous or radicular cyst. This study was approved by the Institutional Review Board (IRB) of Pusan National University Dental Hospital (No. PNUDH 2022-05-005-003). Due to its retrospective nature, exemption from informed consent was obtained from the IRB. For case selection, the first criterion involved the location of cysts between deciduous and permanent succeeding teeth, resulting in a total of 183 patients. Patients then were excluded for absence of histopathological results, discrepancy between clinical and histopathological findings, and presence of oligodontia or systemic disease inhibiting normal tooth development. Based on the clinical, radiological, and histopathological examinations of the patients who underwent cyst enucleation surgery, 87 cases were obtained for analysis. The following variables were analyzed: sex, age, location in the jaw, position, symptoms, presence or absence of dental caries and endodontic treatment, bilateral occurrence, size, delayed eruption of the succeeding permanent tooth, vertical distance between the deciduous and permanent teeth, and root length of the deciduous tooth¹⁷.

In order to determine the location of the cyst, jaws were anatomically categorized into maxilla and mandible and into anterior and posterior regions. Positioning was classified as central and lateral types¹⁸⁻²¹. The symptom was subjective patient discomfort. Dental caries and endodontic treatment

were identified through clinical and radiological examinations. Previous endodontic treatment can produce a periapical lesion due to insufficient treatment or deterioration, which can affect cysts²². Bilateral occurrences were sagittally symmetrical in the panoramic radiograph. For cystic size, cone-beam computed tomography images were used to measure the widest diameter in the axial view as measured by a virtual ruler provided in Marosis M-view 5.4 (Marotech, Seoul, Korea). Considering the age of the patient, delayed eruption was confirmed when the succeeding permanent teeth did not erupt more than 2 years from the expected chronological eruption age^{23,24}. Panoramic radiography was used to measure the vertical distance between the closest point of the crown of the succeeding permanent tooth and the root of the deciduous tooth. In addition, the root length of the deciduous tooth were recorded. If there was more than one root, the mean length of the roots of the deciduous tooth was calculated.

For data analysis, we performed Fisher's exact test in IBM SPSS Statistics (ver. 26.0; IBM, Armonk, NY, USA). Factors that demonstrated a P -value below 0.05 ($P < 0.05$) were considered statistically significant.

III. Results

Of the 87 patients who participated in this study, 69 were diagnosed with dentigerous cysts and 18 with radicular cysts. The most common location for dentigerous cysts was the maxillary anterior region, while radicular cysts were most frequently observed in the mandibular posterior region. (Fig. 2) The position of the cyst was categorized into central and lateral. (Fig. 3)

The contributing factors of dentigerous and radicular cysts were analyzed. (Table 1) Among the 69 patients with dentigerous cysts, 27 had cysts with a radius of 15 mm or more, with the cyst being a central type in 50 patients. For 68 patients, no pain was observed, and clinical findings such as dental caries were not observed in 48 patients. The mean vertical distance between the deciduous and succeeding permanent teeth was 2.73 mm. Among the 18 patients with radicular cysts, 13 had

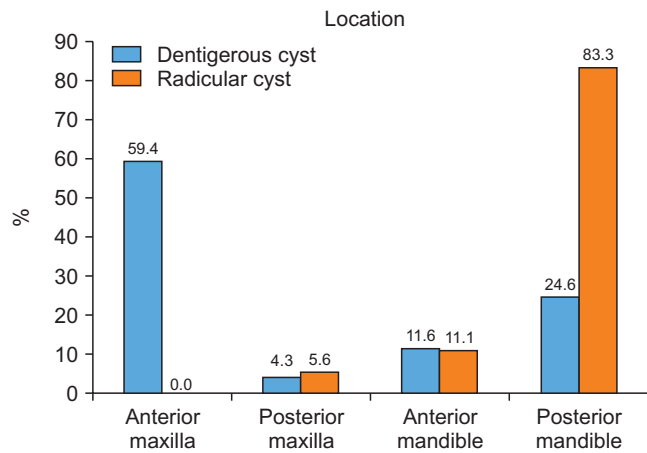


Fig. 2. The location of dentigerous cyst and radicular cyst in the jaw. Changmo Sohn et al: Cystic lesion between a deciduous tooth and the succeeding permanent tooth: a retrospective analysis of 87 cases. J Korean Assoc Oral Maxillofac Surg 2022

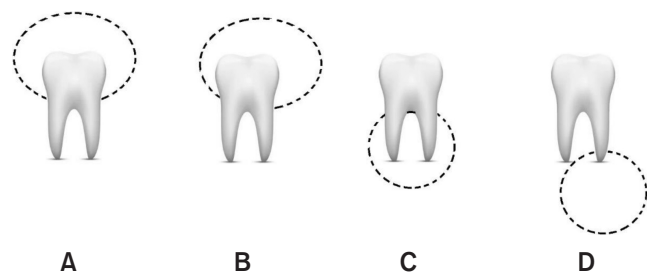


Fig. 3. The position of the dentigerous cyst and the radicular cyst. A. Central type of the dentigerous cyst. B. Lateral type of the dentigerous cyst. C. Central type of the radicular cyst. D. Lateral type of the radicular cyst. Changmo Sohn et al: Cystic lesion between a deciduous tooth and the succeeding permanent tooth: a retrospective analysis of 87 cases. J Korean Assoc Oral Maxillofac Surg 2022

a cyst radius of 15 mm or more, and 10 had a central type cyst. Seven patients complained of pain, while 17 patients had dental caries. The mean vertical distance between the deciduous and succeeding permanent teeth was 2.04 mm.

IV. Discussion

A unicystic and well-defined circumscribed radiolucent lesion in the jaw can be difficult to diagnose but should be accurately discerned. In this study, the factors affecting differential diagnosis of odontogenic cysts between deciduous and permanent teeth were investigated. The main focus was to find measures that were easy to determine in clinical settings. Seven of the 12 differential factors analyzed in this study were significantly different between the two cysts observed in mixed dentition—age, location, symptoms, dental caries, endodontic treatment, delayed eruption, and size.

In the current study, the prevalence of dentigerous cysts

Table 1. Comparison of the clinical and radiological features of dentigerous and radicular cysts

Contributing factors	Dentigerous cyst (n=69)	Radicular cyst (n=18)	P-value
Sex			
Male	36 (52.2)	10 (55.6)	>0.9999
Female	33 (47.8)	8 (44.4)	
Age (yr)			
<10 yr	21 (30.4)	12 (66.7)	0.0067
≥ 10 yr	48 (69.6)	6 (33.3)	
Mean	10.29	8.83	
Range	5-17	6-12	
Location			
Maxilla	44 (63.8)	1 (5.6)	0.0001
Mandible	25 (36.2)	17 (94.4)	
Position			
Center	50 (72.5)	10 (55.6)	0.2515
Lateral	19 (27.5)	8 (44.4)	
Symptoms			
Present	1 (1.4)	7 (38.9)	0.0001
Absent	68 (98.6)	11 (61.1)	
Dental caries			
Present	21 (30.4)	17 (94.4)	0.0001
Absent	48 (69.6)	1 (5.6)	
Endodontic treatment			
Present	9 (13.0)	14 (77.8)	0.0001
Absent	60 (87.0)	4 (22.2)	
Bilateral occurrence			
Present	10 (14.5)	0 (0)	0.1135
Absent	59 (85.5)	18 (100)	
Delayed eruption			
Present	46 (66.7)	6 (33.3)	0.0148
Absent	23 (33.3)	12 (66.7)	
Size (mm)			
<15 mm	42 (60.9)	5 (28.8)	0.0167
≥ 15 mm	27 (39.1)	13 (72.2)	
Mean	14.80	16.38	
Vertical distance (mm)			
<2.5 mm	42 (60.9)	14 (77.8)	0.1855
≥ 2.5 mm	27 (39.1)	4 (22.2)	
Mean	2.73	2.04	
Root length (mm)			
<3.5 mm	35 (50.7)	6 (33.3)	0.2890
≥ 3.5 mm	34 (49.3)	12 (66.7)	
Mean	3.96	3.32	

Values are presented as number (%), mean only, or range only. Changmo Sohn et al: Cystic lesion between a deciduous tooth and the succeeding permanent tooth: a retrospective analysis of 87 cases. J Korean Assoc Oral Maxillofac Surg 2022

was 79.3%, much higher than that of radicular cysts (20.7%). Many studies involving patients of all ages have demonstrated that radicular cysts were the most common odontogenic cyst, followed by dentigerous cysts^{3,4,7,18,25,26}. However, in children, because of the biological mechanism of the development of radicular cyst and permanent teeth, dentigerous cysts are the most common²⁷⁻³⁰. Moreover, children who have previously suffered dental caries have a high rate of new carious lesions due to factors such as dietary habits, oral hygiene practices, and socioeconomic status³¹. The majority of patients with dentigerous cysts had not experienced dental caries and endodontic treatment in the primary tooth, whereas more than 70% of the patients with radicular cysts had dental caries or endodontic treatment. Considering that radicular cysts are associated with dental caries and inflammation,

cystic lesions in the presence of dental caries or endodontic treatment are likely to be diagnosed as radicular cysts.

Although periapical lesions in radicular cysts are due to inflammatory conditions, they do not always cause pain¹². Most patients were asymptomatic for both dentigerous (98.6%) and radicular cysts (61.1%). Dentigerous cysts generally are asymptomatic. However, when infections affect dentigerous cysts, the size can be increased by expansion of the epithelial lining the cortical bone, resulting in pain and complications, such as pathologic fracture¹⁹⁻²¹. The mean diameters of dentigerous and radicular cysts were 14.80 mm and 16.38 mm, respectively. Dentigerous cysts have been found to be greater than 5 mm³². In other studies, a diameter size of 10 mm was used as the landmark in the analysis of the size of odontogenic cysts^{33,34}. In the present study, the majority of dentigerous cysts (60.9%) had diameters smaller than 15 mm, while radicular cysts (72.2%) had diameters of 15 mm or greater. There is no significant difference in the volumes (sizes) of dentigerous and radicular cysts³⁵.

According to Benn and Altini³⁶, are most closely related to mandibular third molars, followed by maxillary canines and mandibular second premolars. In this study, dentigerous cysts were more common in the anterior maxilla region (59.4%) because mandibular third molars were not observed in most children. In the absence of mandibular third molars, 49.3% of the dentigerous cysts were associated with impacted maxillary canines, followed by 21.7% with impacted mandibular second premolars. Compared to dentigerous cysts, radicular cysts are more frequent in mandibular molars³⁷. In the present study, 83.3% of radicular cysts were observed in the mandibular posterior region. Based on the results of this study, there is a high probability that cysts found in the maxillary anterior region during childhood are dentigerous cysts. On the other hand, cysts in the mandibular posterior region have a high probability of being radicular cysts.

Of the succeeding permanent teeth with dentigerous cyst, 66.7% were not clinically observed within the 2 years after the chronologic eruption time. In radicular cysts, 33.3% of the succeeding permanent teeth exhibited the same issue. Dentigerous cysts are often related to delayed eruption of the succeeding permanent tooth³⁸. The mechanism behind failure of eruption of the succeeding permanent tooth in dentigerous cysts is unknown¹¹. Delayed eruption or displacement of an impacted tooth can be observed in dentigerous cysts, but further studies are needed to determine the factors influencing tooth eruption in the presence of such cysts³⁹.

There were no significant differences in sex, position of the

cyst, bilateral occurrence, vertical distance between deciduous and succeeding permanent teeth, and root length of the deciduous tooth in both dentigerous and radicular cysts. In general, males had a higher incidence of cysts than females. Regarding position, both cyst types could be located between the root and crown. The mean distance between teeth in dentigerous cysts was 2.73 mm, and that in radicular cysts was 2.04 mm. For root length, the mean of the deciduous tooth above dentigerous cysts was 3.96 mm, and that above radicular cysts was 3.32 mm. These results suggest that development of the cystic wall in dentigerous cysts has a greater effect on root resorption than does inflammation of radicular cysts. Of the dentigerous cysts, 14.5% occurred bilaterally in either the maxilla or mandible, while radicular cysts occurred in a single location. Radicular cysts occur unilaterally because the inflammation associated with dental caries leads to a periapical lesion. In dentigerous cysts, such lesions are uncommon but can occur bilaterally since the impacted permanent teeth exist bilaterally and the cyst has a developmental origin⁴⁰.

There are several limitations in this study. From the 183 patients who had cystic lesions between deciduous and succeeding permanent teeth, only 89 cases remained in for final analysis due to the lack of biopsy result or ambiguity in diagnosis, such as benign squamous epithelium-lined cysts or chronic inflammation with epithelial lining. Another limitation was that this study was a retrospective analysis of patients. In future research, a larger number of cases of odontogenic cysts and tumors should be analyzed through multidisciplinary studies and randomized controlled trials.

V. Conclusion

Despite the difficult diagnosis of dentigerous and radicular cysts in mixed dentition, cystic lesions should be examined thoroughly and diagnosed carefully because radicular cysts typically result in pulp necrosis requiring endodontic treatment or tooth extraction. From this study, 7 variables were significant in diagnosis of dentigerous or radicular cysts in mixed dentition. A cyst is most likely radicular if the patient presents with a cystic lesion with characteristics of age less than 10 years, located in the mandible, presence of symptoms, caries and previous history of endodontic treatment, no delayed eruption of the permanent tooth, or diameter of 15 mm or greater. Other cases likely can be differentially diagnosed as a dentigerous cyst.

ORCID

Changmo Sohn, <https://orcid.org/0000-0001-5296-6681>

Jihye Ryu, <https://orcid.org/0000-0001-5791-7387>

Inhye Nam, <https://orcid.org/0000-0002-2555-0469>

Sang-Hun Shin, <https://orcid.org/0000-0002-0467-6206>

Jae-Yeol Lee, <https://orcid.org/0000-0003-0678-2499>

Authors' Contributions

C.S. participated in data collection and wrote the manuscript. J.R., I.N., and S.H.S. participated in the design of the study. J.Y.L. participated in the study design, coordination, and helped to draft the manuscript. All authors read and approved the final manuscript.

Acknowledgements

This work was supported by a 2-Year Research Grant of Pusan National University.

Ethics Approval and Consent to Participate

This study was approved by the IRB of Pusan National University Dental Hospital (No. PNUDH 2022-05-005-003). Due to its retrospective nature, exemption from informed consent was obtained from the IRB.

Conflict of Interest

No potential conflict of interest relevant to this article was reported.

References

1. Weber M, Ries J, Büttner-Herold M, Geppert CI, Kesting M, Wehrhan F. Differences in inflammation and bone resorption between apical granulomas, radicular cysts, and dentigerous cysts. *J Endod* 2019;45:1200-8. <https://doi.org/10.1016/j.joen.2019.06.014>
2. Sivapathasundharam B, Biswas PG, Preethi S. The World Health Organization classification of odontogenic and maxillofacial bone tumors: an appraisal. *J Oral Maxillofac Pathol* 2019;23:178-86. https://doi.org/10.4103/jomfp.JOMFP_211_19
3. Meningaud JP, Oprean N, Pitak-Arnop P, Bertrand JC. Odontogenic cysts: a clinical study of 695 cases. *J Oral Sci* 2006;48:59-62. <https://doi.org/10.2334/josnusd.48.59>
4. Monteiro L, de la Peña J, Fonseca L, Paiva A, Amaral B. Odontogenic cysts - a descriptive clinicopathological study. *Braz J Oral Sci* 2015;4:670-5. <https://doi.org/10.20396/bjos.v4i12.8641795>
5. Mosqueda-Taylor A, Irigoyen-Camacho ME, Diaz-Franco MA, Torres-Tejero MA. Odontogenic cysts. Analysis of 856 cases. *Med Oral* 2002;7:89-96.
6. Noujeim Z, Nasr L. The prevalence, distribution, and radiological evaluation of dentigerous cysts in a Lebanese sample. *Imaging Sci Dent* 2021;51:291-7. <https://doi.org/10.5624/isd.20210075>
7. Avelar RL, Antunes AA, Carvalho RW, Bezerra PG, Oliveira Neto PJ, Andrade ES. Odontogenic cysts: a clinicopathological study of 507 cases. *J Oral Sci* 2009;51:581-6. <https://doi.org/10.2334/josnusd.51.581>
8. Johnson NR, Gannon OM, Savage NW, Batstone MD. Frequency of odontogenic cysts and tumors: a systematic review. *J Investig Clin Dent* 2014;5:9-14. <https://doi.org/10.1111/jicd.12044>
9. Shear M. Developmental odontogenic cysts. An update. *J Oral Pathol Med* 1994;23:1-11. <https://doi.org/10.1111/j.1600-0714.1994.tb00246.x>
10. Daley TD, Wysocki GP. The small dentigerous cyst. A diagnostic dilemma. *Oral Surg Oral Med Oral Pathol Oral Radiol Endod* 1995;79:77-81. [https://doi.org/10.1016/s1079-2104\(05\)80078-2](https://doi.org/10.1016/s1079-2104(05)80078-2)
11. Narang RS, Manchanda AS, Arora P, Randhawa K. Dentigerous cyst of inflammatory origin-a diagnostic dilemma. *Ann Diagn Pathol* 2012;16:119-23. <https://doi.org/10.1016/j.anndiagpath.2011.07.004>
12. Boudaoud Z, Maou S, Badi Y. Radicular cyst on deciduous molar or dentigerous cyst on permanent tooth? *Int J Dent Oral Sci* 2016;3:331-5. <https://doi.org/10.19070/2377-8075-1600066>
13. Aoki N, Ise K, Inoue A, Kosugi Y, Koyama C, Iida M, et al. Multidisciplinary approach for treatment of a dentigerous cyst - marsupialization, orthodontic treatment, and implant placement: a case report. *J Med Case Rep* 2018;12:305. <https://doi.org/10.1186/s13256-018-1829-2>
14. Matijević S, Jović B, Bubalo M, Dukić S, Cutović T. Treatment of a large radicular cyst-enucleation or decompression? *Vojnosanit Pregl* 2015;72:372-4. <https://doi.org/10.2298/vsp1504372m>
15. Rajae EG, Karima EH. Dentigerous cyst: enucleation or marsupialization? (a case report). *Pan Afr Med J* 2021;40:149. <https://doi.org/10.11604/pamj.2021.40.149.28645>
16. Talukdar M, Kumar A, Goenka S, Mahajani M, Ambhore MP, Tattu VD. Management of radicular cyst in deciduous molar: a case report. *J Family Med Prim Care* 2020;9:1222-5. https://doi.org/10.4103/jfmpe.jfmpe_1147_19
17. Manekar VS, Chavan A, Wadde K, Dewalwar V. Cysts in periradicular region of deciduous molars in mixed dentition: retrospective study of five cases. *Int J Clin Pediatr Dent* 2014;7:229-35. <https://doi.org/10.5005/jp-journals-10005-1273>
18. McKinney SL, Lukes SM. Dentigerous cyst in a young child: a case report. *Can J Dent Hyg* 2021;55:177-81.
19. Mohan KR, Natarajan B, Mani S, Sahuthullah YA, Kannan AV, Doraiswamy H. An infected dentigerous cyst associated with an impacted permanent maxillary canine, inverted mesiodens and impacted supernumerary teeth. *J Pharm Bioallied Sci* 2013;5(Suppl 2):S135-8. <https://doi.org/10.4103/0975-7406.114307>
20. Patil AS, Jathar PN, Panse AM, Bahutule SR, Patil RU, Patil M. Infected dentigerous cyst and its conservative management: a report of two cases. *Int J Clin Pediatr Dent* 2019;12:68-72. <https://doi.org/10.5005/jp-journals-10005-1578>
21. Rajendra Santosh AB. Odontogenic cysts. *Dent Clin North Am* 2020;64:105-19. <https://doi.org/10.1016/j.cden.2019.08.002>
22. Huh JK, Yang DK, Jeon KJ, Shin SJ. Progression of periapical cystic lesion after incomplete endodontic treatment. *Restor Dent Endod* 2016;41:137-42. <https://doi.org/10.5395/rde.2016.41.2.137>
23. Khan AS, Nagar P, Singh P, Bharti M. Changes in the sequence of eruption of permanent teeth; correlation between chronological and dental age and effects of body mass index of 5-15-year-old schoolchildren. *Int J Clin Pediatr Dent* 2020;13:368-80. <https://doi.org/10.5005/jp-journals-10005-1797>
24. Verma N, Bansal A, Tyagi P, Jain A, Tiwari U, Gupta R. Eruption chronology in children: a cross-sectional study. *Int J Clin Pediatr Dent* 2017;10:278-82. <https://doi.org/10.5005/jp-jour->

- nals-10005-1450
25. Kammer PV, Mello FW, Rivero ERC. Comparative analysis between developmental and inflammatory odontogenic cysts: retrospective study and literature review. *Oral Maxillofac Surg* 2020;24:73-84. <https://doi.org/10.1007/s10006-019-00816-8>
 26. Soluk Tekkesin M, Tuna EB, Olgac V, Aksakallı N, Alatlı C. Odontogenic lesions in a pediatric population: review of the literature and presentation of 745 cases. *Int J Pediatr Otorhinolaryngol* 2016;86:196-9. <https://doi.org/10.1016/j.ijporl.2016.05.010>
 27. Arjona-Amo M, Serrera-Figallo MA, Hernández-Guisado JM, Gutiérrez-Pérez JL, Torres-Lagares D. Conservative management of dentigerous cysts in children. *J Clin Exp Dent* 2015;7:e671-4. <https://doi.org/10.4317/jced.52248>
 28. Bhardwaj B, Sharma S, Chitlangia P, Agarwal P, Bhamboo A, Rastogi K. Mandibular dentigerous cyst in a 10-year-old child. *Int J Clin Pediatr Dent* 2016;9:281-4. <https://doi.org/10.5005/jp-journals-10005-1378>
 29. Kajjari S, Gowtham A, Meharwade P, Uppin C, Hugar SM, Badakar C. Infected radicular cyst of deciduous second molar mimicking dentigerous cyst of second premolar in a young child: a rare entity. *Int J Clin Pediatr Dent* 2021;14:434-7. <https://doi.org/10.5005/jp-journals-10005-1954>
 30. Kozelj V, Sotosek B. Inflammatory dentigerous cysts of children treated by tooth extraction and decompression--report of four cases. *Br Dent J* 1999;187:587-90. <https://doi.org/10.1038/sj.bdj.4800339a>
 31. Corrêa-Faria P, Paixão-Gonçalves S, Paiva SM, Pordeus IA. Incidence of dental caries in primary dentition and risk factors: a longitudinal study. *Braz Oral Res* 2016;30:S1806-83242016000100254. <https://doi.org/10.1590/1807-3107BOR-2016.vol30.0059>
 32. Batra P, Roychoudhury A, Balakrishnan P, Parkash H. Bilateral dentigerous cyst associated with polymorphism in chromosome 1qh+. *J Clin Pediatr Dent* 2004;28:177-81. <https://doi.org/10.17796/jcpd.28.2.m21q8vx78084374v>
 33. Bilodeau EA, Collins BM. Odontogenic cysts and neoplasms. *Surg Pathol Clin* 2017;10:177-222. <https://doi.org/10.1016/j.path.2016.10.006>
 34. Tsesis I, Krepel G, Koren T, Rosen E, Kfir A. Accuracy for diagnosis of periapical cystic lesions. *Sci Rep* 2020;10:14155. <https://doi.org/10.1038/s41598-020-71029-3>
 35. Kubota Y, Yamashiro T, Oka S, Ninomiya T, Ogata S, Shirasuna K. Relation between size of odontogenic jaw cysts and the pressure of fluid within. *Br J Oral Maxillofac Surg* 2004;42:391-5. <https://doi.org/10.1016/j.bjoms.2004.02.032>
 36. Benn A, Altini M. Dentigerous cysts of inflammatory origin. A clinicopathologic study. *Oral Surg Oral Med Oral Pathol Oral Radiol Endod* 1996;81:203-9. [https://doi.org/10.1016/s1079-2104\(96\)80416-1](https://doi.org/10.1016/s1079-2104(96)80416-1)
 37. Mass E, Kaplan I, Hirshberg A. A clinical and histopathological study of radicular cysts associated with primary molars. *J Oral Pathol Med* 1995;24:458-61. <https://doi.org/10.1111/j.1600-0714.1995.tb01134.x>
 38. Sumer M, Baş B, Yildiz L. Inferior alveolar nerve paresthesia caused by a dentigerous cyst associated with three teeth. *Med Oral Patol Oral Cir Bucal* 2007;12:E388-90.
 39. Nahajowski M, Hnitecka S, Antoszevska-Smith J, Rumin K, Dubowik M, Sarul M. Factors influencing an eruption of teeth associated with a dentigerous cyst: a systematic review and meta-analysis. *BMC Oral Health* 2021;21:180. <https://doi.org/10.1186/s12903-021-01542-y>
 40. Vasiappan H, Christopher PJ, Kengasubbiah S, Shenoy V, Kumar S, Paranthaman A. Bilateral dentigerous cyst in impacted mandibular third molars: a case report. *Cureus* 2018;10:e3691. <https://doi.org/10.7759/cureus.3691>

How to cite this article: Sohn C, Ryu J, Nam I, Shin SH, Lee JY. Cystic lesion between a deciduous tooth and the succeeding permanent tooth: a retrospective analysis of 87 cases. *J Korean Assoc Oral Maxillofac Surg* 2022;48:342-347. <https://doi.org/10.5125/jkaoms.2022.48.6.342>