

# Analysis of the root position and angulation of maxillary premolars in alveolar bone using cone-beam computed tomography

Yun-Hoa Jung<sup>1</sup>, Bong-Hae Cho<sup>1</sup>, Jae-Joon Hwang<sup>1,\*</sup>

<sup>1</sup>Department of Oral and Maxillofacial Radiology, School of Dentistry, Pusan National University, Yangsan, Korea

## ABSTRACT

**Purpose:** This study investigated whether the relationship between the maxillary sinus and the root of the maxillary premolar is correlated with the root position and whether there is a difference in the long axis angle of premolars and the buccal bone thickness according to the sinus-root relationship and root position.

**Materials and Methods:** Cone-beam computed tomographic images of 587 maxillary first premolars and 580 second premolars from 303 patients were retrospectively reviewed. The maxillary sinus floor-root relationship was classified into 4 types, and the root position in the alveolar bone was evaluated as buccal, middle, or palatal. The long axis angle of the maxillary premolars in the alveolar bone and the buccal bone thickness were measured. The correlation between these parameters was analyzed.

**Results:** The maxillary sinus floor-root relationship showed a statistically significant correlation with the root position in the alveolar bone. Most maxillary first premolars were buccally located, and more than half of the second premolars had their roots in the middle. The long axis angle of the premolars was significantly larger in buccal-positioned teeth than in middle-positioned teeth, and the buccal bone was thinner.

**Conclusion:** When the root of the maxillary premolar was separated from the sinus floor, the premolar was often located on the buccal side. Most of the maxillary first premolars had a thinner buccal bone and larger inclination than the second premolars. It is recommended to evaluate the root position, sagittal angle and buccal bone thickness using CBCT for implant treatment planning. (*Imaging Sci Dent* 2022; 52: 365-73)

**KEY WORDS:** Maxilla; Premolar; Maxillary Sinus; Cone-Beam Computed Tomography

## Introduction

Knowledge of the relationship between a root and the adjacent anatomical structures, and the root position in the alveolar bone is helpful in planning treatment for dental conditions and preventing complications.<sup>1,2</sup> Since the maxillary premolars are located at the transition point from the maxillary anterior teeth to the maxillary molars, the relationship with the maxillary sinus should be considered, and the root position in the alveolar bone reflects the complex characteristics of the anterior teeth and molars.<sup>3</sup>

When the maxillary sinus is close to the root, there is a

risk of perforation of the maxillary sinus or the expansion of foreign substances into the maxillary sinus.<sup>1</sup> Many studies have investigated the relationship between the maxillary molars and the maxillary sinus using cone-beam computed tomography (CBCT);<sup>1,4-6</sup> however, studies on the relationship between the maxillary premolars and the maxillary sinus are rare.<sup>3,7</sup>

Determining the location of the root in the alveolar bone is necessary when evaluating an implant placement site or assessing bone grafting criteria.<sup>2,8</sup> In particular, the position of the root in the maxillary esthetic region is vital for predicting implant stability and bone perforation during implant placement.<sup>9</sup> Lau et al.<sup>10</sup> classified the position of the maxillary central incisor root in the alveolar bone as buccal, middle, or palatal. Although many studies have investigated the location of the maxillary central incisor root in the alveolar bone,<sup>8,10-13</sup> there have been few studies on the loca-

This work was supported by a 2-Year Research Grant of Pusan National University. Received July 10, 2022; Revised August 3, 2022; Accepted August 9, 2022  
Published online September 7, 2022

\*Correspondence to : Prof. Jae-Joon Hwang

Department of Oral and Maxillofacial Radiology, Pusan National University Dental Hospital, 20 Geumo-ro, Mulgeum-eup, Yangsan-si, Gyeongsangnam-do 50612 Korea  
Tel) 82-55-360-5108, E-mail) softdent@pusan.ac.kr

Copyright © 2022 by Korean Academy of Oral and Maxillofacial Radiology

This is an Open Access article distributed under the terms of the Creative Commons Attribution Non-Commercial License (<http://creativecommons.org/licenses/by-nc/3.0>) which permits unrestricted non-commercial use, distribution, and reproduction in any medium, provided the original work is properly cited.

Imaging Science in Dentistry · pISSN 2233-7822 eISSN 2233-7830

tion of the maxillary premolar root in the alveolar bone.<sup>9</sup>

Evaluating the angle between the long axis of the tooth and the long axis of the alveolar bone is also necessary when planning implant treatment.<sup>14</sup> Studies have reported that the distance between the maxillary sinus floor and the root correlates with the angle of the long axis of the tooth.<sup>3,7</sup> That is, when the distance between the sinus floor and the root is larger, the angle of the long axis of the tooth is also larger.<sup>3,7</sup> It has also been reported that the long axis angle of the tooth in the alveolar bone is affected by the root position, with incisors located on the buccal side exhibiting the largest angle.<sup>9</sup>

Alveolar bone is generally reduced after tooth extraction,<sup>15</sup> and this change is more prominent on the buccal side than on the palatal side.<sup>16</sup> Thinner buccal bone before tooth extraction is associated with more severe buccal bone loss;<sup>17</sup> hence, it is important to examine the buccal bone thickness before extraction. It has been reported that the degree of alveolar bone resorption is affected by the thickness of the pre-extraction buccal bone,<sup>18</sup> and that at least 1 mm of buccal bone is required to prevent buccal bone resorption after tooth extraction.<sup>19,20</sup> Thin buccal bone increases the risk of labial perforation when an implant is immediately inserted.<sup>8,21</sup> Furthermore, for endodontic treatment in the maxillary posterior region, both the relationship with the maxillary sinus and the buccal bone thickness at the apex should be considered.<sup>1</sup> Since the sinus tract is likely to follow the path of least resistance through the alveolar bone, thin buccal bone may increase the likelihood of sinus tract formation.<sup>22,23</sup>

In most studies, the thickness of the buccal bone in the maxillary anterior region has been measured;<sup>24-27</sup> while the thickness has rarely been measured in the maxillary first and second premolar regions.<sup>28</sup> In addition, the buccal bone thickness has been found to be related to the root position. In the maxillary anterior region, the buccal bone is thinner when the root is in the buccal position in the alveolar bone than when the root is in the middle or palatal position.<sup>21</sup>

Therefore, this study evaluated the relationship between the maxillary sinus floor and the root of the premolars, as well as the position of the root in the alveolar bone. The long axis angle of the maxillary premolars in the alveolar bone and the buccal bone thickness were measured. The correlations between these parameters were analyzed.

## Materials and Methods

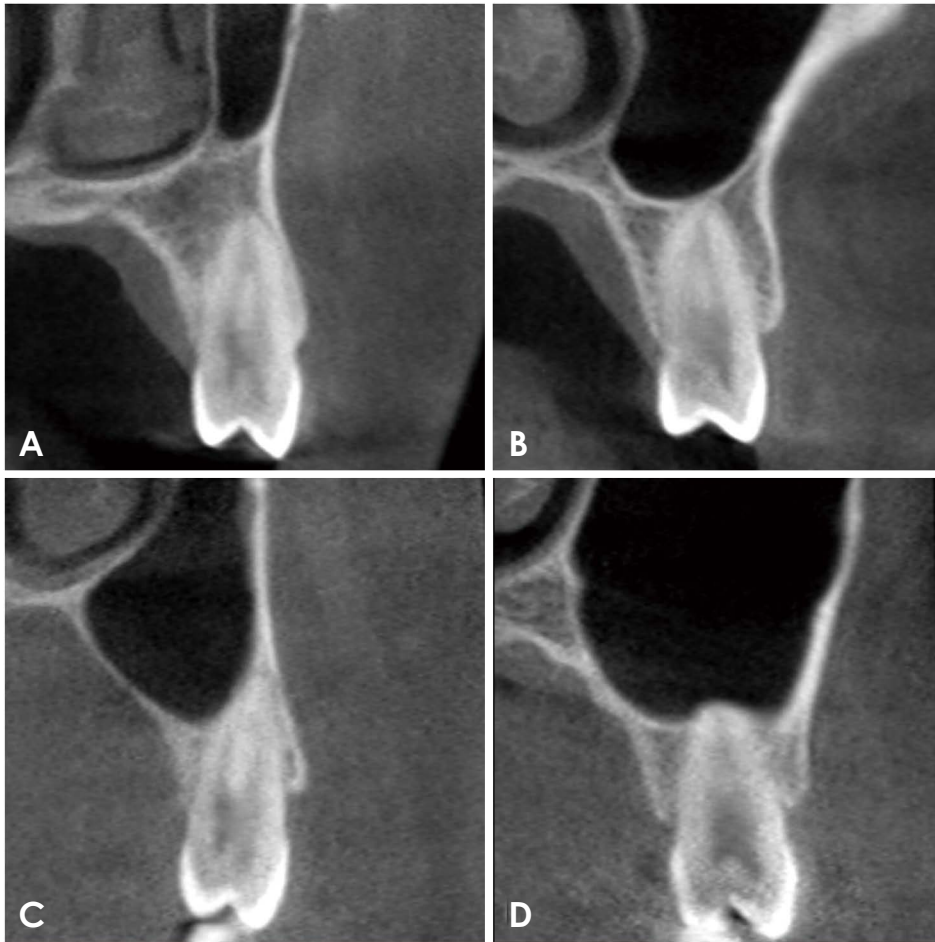
This study was approved by the Institutional Review Board of Pusan National University Dental Hospital. The

subjects of this retrospective study were randomly selected from patients who visited Pusan National University Dental Hospital and had CBCT examinations between 2013 and 2014. The subjects were 20 years of age or older with maxillary premolars and adjacent teeth. Patients with periapical lesions, pathological lesions in the maxilla, alveolar bone loss of more than 4 mm from the cemento-enamel junction, a history of orthodontic treatment, and blurred radiographic images were excluded from the study. The final sample group included 303 patients (162 men and 141 women; mean age:  $28.5 \pm 7.1$  years; age range: 20-50 years). A total of 1,167 teeth were selected for the study: 587 first premolars and 580 second premolars.

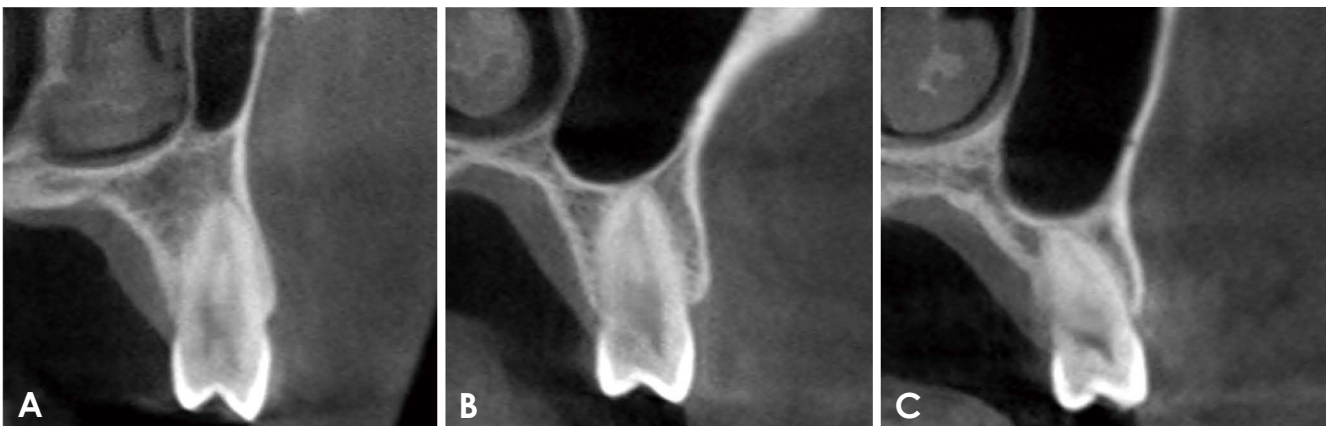
CBCT scans were performed using a PaX-Zenith 3D (Vatech Co, Hwaseong, Korea) with settings of 5.2-5.7 mA, 106-110 kV, an exposure time of 24 s, a voxel size of 0.2 mm, and a field of view of  $16 \times 14$  cm. The CBCT data were saved in the Digital Imaging and Communications in Medicine format, and the images were analyzed using Ez3D Plus Professional CBCT software (Ver. 1.2.6.27, Vatech Co, Hwaseong, Korea). Cross-sectional CBCT images were used to analyze the relationship between the maxillary sinus and the root of the maxillary premolar, the position of the root in the alveolar bone, the angle between the long axis of the tooth and the long axis of the alveolar bone, and the thickness of the buccal bone.

The relationship between the sinus floor and the root was classified into 4 types, as follows: type 0, the root was separate from the sinus floor; type 1, the root was in close contact with the sinus floor; type 2, the sinus floor was located below the level of the root apex without apical protrusion into the sinus; and type 3, the root protruded into the sinus cavity (Fig. 1). The root position, angulation, and buccal bone thickness were evaluated by viewing the cross-sectional images made at the midpoint of the tooth parallel to its long axis. The root position of the maxillary premolar was classified as follows: buccal type, the root apex of the premolar was within the buccal third of the alveolar bone and the root was closer to the buccal cortical bone; middle type, the root apex of the premolar was within the middle third of the alveolar bone and the buccal and palatal bone thicknesses were approximately equal; and palatal type, the root apex of the premolar was within the palatal third of the alveolar bone and the root was closer to the palatal cortical bone (Fig. 2).

The long axis of the tooth was defined as a line passing the midpoint of the cervical and the apical region. The long axis of the alveolar bone was a straight line connecting the midpoint of the alveolar crest and the apical alveolar bone.



**Fig. 1.** The relationship between the maxillary sinus floor and the roots is classified into 4 types on cone-beam computed tomographic images. A. Type 0: the root is separate from the sinus floor. B. Type 1: the root is in close contact with the sinus floor. C. Type 2: the sinus floor is located below the level of root apex without apical protrusion into the sinus. D. Type 3: the root protrudes into the sinus cavity.



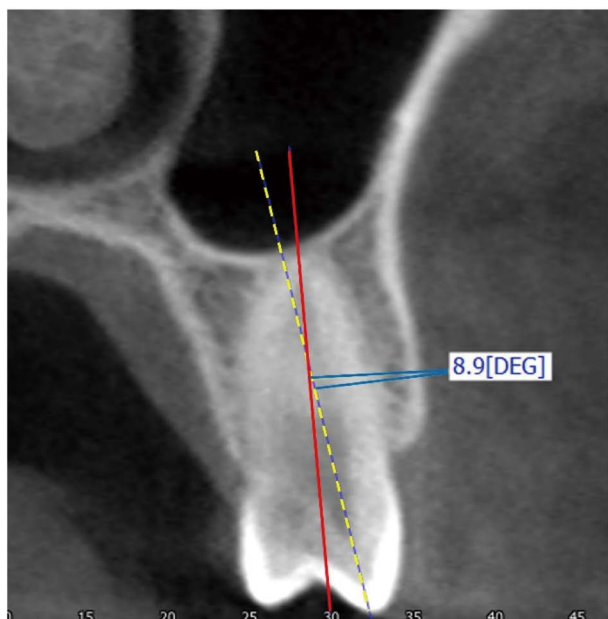
**Fig. 2.** The root position of the premolar in the alveolar bone is classified into the buccal, middle, and palatal types. A. Buccal type: the root apex of the premolar is within the buccal third of the alveolar bone and the root is closer to the buccal cortical bone. B. Middle type: the root apex of the premolar is within the middle third of the alveolar bone and the buccal and palatal bone thicknesses are approximately equal. C. Palatal type: the root apex of the premolar is within the palatal third of the alveolar bone and the root is closer to the palatal cortical bone.

The angle formed by the long axis of the maxillary premolar and the long axis of the alveolar bone was measured (Fig. 3). The thickness of the buccal bone was measured at 1 mm

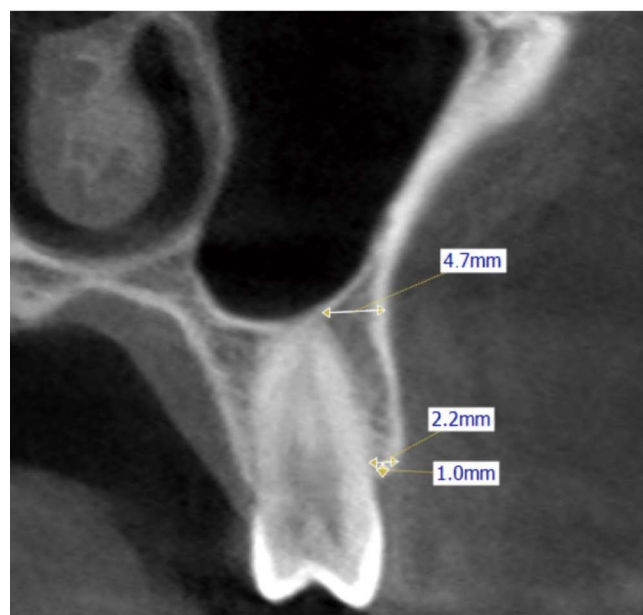
below the alveolar crest and at the apex perpendicular to the long axis of the tooth. When the buccal bone was very thin and difficult to measure, the thickness of the buccal

bone was recorded as 0.1 mm (Fig. 4).

All images were evaluated by a single oral and maxillo-facial radiologist. To estimate the intra-examiner deviations in the measurements, assessments of the maxillary premolars



**Fig. 3.** The long axis of the tooth is a line passing the midpoint of the cervical and the apical region (solid line). The long axis of the alveolar bone is a straight line connecting the midpoint of the alveolar crest and the apical alveolar bone (dotted line). The angle between the long axis of the tooth and the long axis of the corresponding alveolar bone is measured.



**Fig. 4.** Buccal bone thickness is measured at 1 mm below the alveolar crest and at the root apex.

of 30 patients were performed twice at an interval of four weeks. The prevalence of root positions according to the relationship with the maxillary sinus was analyzed with the chi-square test. The paired t-test was used to compare the angulation and buccal bone thickness between the maxillary first and second premolars. One-way analysis of variance and the t-test were performed to determine whether there was a statistically significant difference in the angle of the long axis and the thickness of the buccal bone according to the relationship between the maxillary sinus and root, and the root position in the alveolar bone. To analyze statistically significant differences between groups, Games-Howell *post-hoc* analysis was performed. Buccal bone thickness was categorized as < 1 mm, 1-2 mm, and > 2 mm for the descriptive analysis. A *P* value less than 0.05 was assumed to indicate a statistically significant difference, and analysis was performed using SPSS version 25.0 (IBM Corp, Armonk, NY, USA).

### Results

The intra-examiner intraclass correlation coefficient was 0.99. The relationship between the sinus floor and the root was examined using the CBCT images. In the maxillary first premolars, the type 0 relationship was the most common (83.0%). It was also the most common (40.2%) in the maxillary second premolars, followed by type 1 (36.0%) (Table 1).

Most of the maxillary first premolars were positioned more buccally in the alveolar bone and none were of palatal type. More than half of the second premolars were positioned in the middle of the alveolar bone. A statistically significant difference was found in the root position according to the relationship between the sinus floor and the root (*P*<0.05). Among the maxillary first premolars, most of those that were type 0, type 1, and type 2 were the buccal type, and half of the type 3 maxillary first premolars were

**Table 1.** The relationship between the sinus floor and the root of the maxillary premolars on cone-beam computed tomographic images

	First premolar	Second premolar
Type 0	487 (83.0%)	233 (40.2%)
Type 1	59 (10.1%)	209 (36.0%)
Type 2	33 (5.6%)	46 (7.9%)
Type 3	8 (1.4%)	92 (15.8%)
Total	587 (100.0%)	580 (100.0%)

**Table 2.** The root position of maxillary premolars according to the relationship between the sinus floor and the root

		Buccal	Middle	Palatal	Total
First premolar	Type 0	452 (92.8%)	35 (7.2%)	—	487 (100.0%)
	Type 1	54 (91.5%)	5 (8.5%)	—	59 (100.0%)
	Type 2	33 (100.0%)	0 (0.0%)	—	33 (100.0%)
	Type 3	4 (50.0%)	4 (50.0%)	—	8 (100.0%)
	Subtotal	543 (92.7%)	44 (7.5%)	—	587 (100.0%)
Second premolar	Type 0	117 (51.2%)	107 (45.9%)	9 (3.9%)	233 (100.0%)
	Type 1	60 (28.7%)	141 (67.5%)	8 (3.8%)	209 (100.0%)
	Type 2	34 (73.9%)	6 (13.0%)	6 (13.0%)	46 (100.0%)
	Type 3	17 (18.5%)	68 (73.9%)	7 (7.6%)	92 (100.0%)
	Subtotal	228 (39.3%)	322 (55.5%)	30 (5.2%)	580 (100.0%)

**Table 3.** The angle between the long axis of the maxillary premolar and that of the alveolar bone according to the maxillary sinus floor-root relationship (unit: degrees)

	First premolar	Second premolar	Total	<i>P</i>
Type 0	18.4 ± 4.8	13.7 ± 4.7	16.9 ± 5.2 <sup>a</sup>	<0.05
Type 1	12.0 ± 3.8	9.1 ± 4.3	9.7 ± 4.4 <sup>b</sup>	
Type 2	16.9 ± 4.9	14.6 ± 4.9	15.6 ± 5.0 <sup>a</sup>	
Type 3	8.5 ± 1.1	7.6 ± 3.6	7.7 ± 3.5 <sup>c</sup>	
Total	17.5 ± 5.2	11.1 ± 5.2	14.3 ± 6.1	

<sup>a-c</sup>same letters not significant ( $\alpha=0.05$ ), Games-Howell *post-hoc* test

the middle type. Among the maxillary second premolars, more than half of those that were type 0 and type 2 were the buccal type, and those that were type 1 and type 3 were mostly the middle type (Table 2).

The inclination of the long axis of the tooth was the greatest in type 0 first premolars and type 2 second premolars. Type 3 teeth had the smallest long axis inclinations. There was a statistically significant difference in the angulation of the tooth according to maxillary sinus-root relationship. The Games-Howell *post-hoc* test showed that there was no significant difference between type 0 and type 2, while there was a statistically significant difference between other types (Table 3). The mean long axis angle of the maxillary first premolars was significantly greater than that of the second premolars ( $P<0.05$ ). The long axis angle of the buccal-type teeth was significantly larger than that of the middle- and palatal-type teeth ( $P<0.05$ ) (Table 4).

The maxillary first premolars demonstrated significantly thinner buccal bone than the second premolars. The buccal bone thickness associated with buccal-type teeth was signi-

**Table 4.** The angle between the long axis of the maxillary premolar and the long axis of the alveolar bone according to the sagittal root position (unit: degrees)

	First premolar	Second premolar	Total	<i>P</i>
Buccal	17.9 ± 5.0	14.5 ± 4.3	16.9 ± 5.0	<0.05
Middle	12.8 ± 4.9	9.2 ± 4.3	9.6 ± 4.5	
Palatal	—	6.9 ± 5.7	6.9 ± 5.7	
Total	17.5 ± 5.2	11.1 ± 5.2	14.3 ± 6.1	

ficantly thinner than that associated with middle- and palatal-type teeth ( $P<0.05$ ) (Table 5). According to the relationship between the sinus floor and the root, the buccal bone thickness at the root apex was the thinnest in type 0 premolars. There was only a statistically significant difference at the root apex of the maxillary second premolars (Table 6).

At 1 mm apical to the crest, 32.7% of the first premolars had buccal bone that was less than 1 mm thick, and most of the second premolars had buccal bone that was more than 1 mm thick (Fig. 5). At the root apex, more than half of the maxillary first premolars exhibited buccal bone less than 1 mm thick, and most of the second premolars had buccal bone that was more than 2 mm thick (Fig. 6).

## Discussion

This study investigated the relationship between the sinus floor and the root of maxillary premolars and the root position in the alveolar bone and evaluated the long axis angle and buccal bone thickness of maxillary premolars. It is important to understand the maxillary sinus-root relationship when planning treatment. In particular, the proximity

**Table 5.** Buccal bone thickness of maxillary premolars according to the sagittal root position at 1 mm apical to the crest and at the root apex (unit: mm)

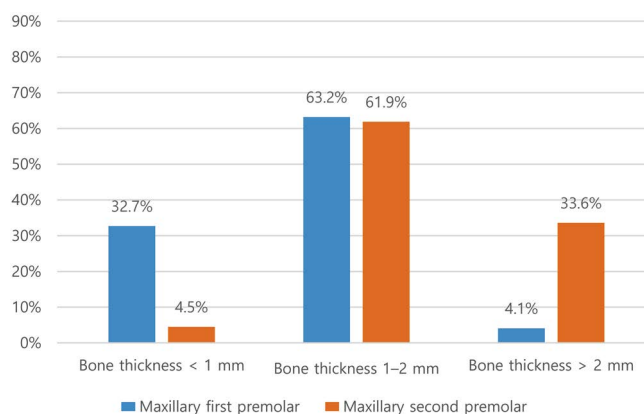
	First premolar		Second premolar	
	1 mm apical to the crest*	Root apex*	1 mm apical to the crest*	Root apex*
Buccal	1.10 ± 0.46	0.86 ± 0.71	1.58 ± 0.50	1.94 ± 0.73
Middle	1.60 ± 0.47	2.63 ± 0.86	2.00 ± 0.62	3.90 ± 1.13
Palatal	–	–	2.49 ± 0.74	6.43 ± 2.05
Total	1.14 ± 0.48	0.99 ± 0.86	1.86 ± 0.63	3.26 ± 1.60

\*P < 0.05

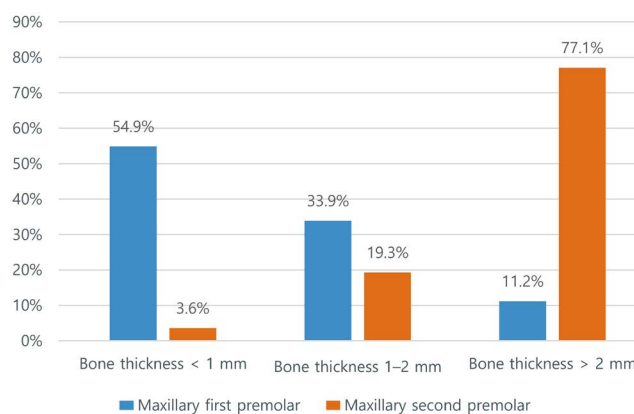
**Table 6.** Buccal bone thickness of maxillary premolars according to the relationship between the sinus floor and the root (unit: mm)

	First premolar		Second premolar	
	1 mm apical to the crest	Root apex	1 mm apical to the crest	Root apex*
Type 0	1.15 ± 0.48	0.94 ± 0.86	1.86 ± 0.65	2.84 ± 1.35
Type 1	1.00 ± 0.43	1.21 ± 0.97	1.89 ± 0.60	3.36 ± 1.33
Type 2	1.16 ± 0.57	1.06 ± 0.64	1.76 ± 0.66	2.96 ± 2.19
Type 3	1.15 ± 0.51	1.43 ± 1.11	1.85 ± 0.66	4.25 ± 1.95
Total	1.14 ± 0.48	0.98 ± 0.87	1.86 ± 0.63	3.26 ± 1.60

\*P < 0.05



**Fig. 5.** Frequency distribution of the buccal bone thickness of the maxillary premolar at 1 mm apical to the crest.



**Fig. 6.** Frequency distribution of the buccal bone thickness of the maxillary premolar at the root apex.

of the root to the maxillary sinus should be considered while planning endodontic treatment, implantations, and periapical surgery for maxillary posterior teeth.<sup>29-31</sup>

Some previous studies have analyzed the relationship between the maxillary sinus and the root,<sup>3,5,6</sup> whereas others have examined the distance between the maxillary sinus and root.<sup>7,32,33</sup> However, few studies have explored the relationship between the maxillary sinus and teeth by comparing the maxillary first and second premolars.<sup>3</sup> The maxillary

second premolars are considerably closer to the sinus floor than the first premolars,<sup>32</sup> and the maxillary first premolar root is the furthest from the maxillary sinus among the maxillary posterior teeth.<sup>33</sup> In this study, type 0 teeth, in which the maxillary premolar root was separated from the maxillary sinus, were the most frequent type observed. There were more type 1 teeth, in which the root was in contact with the sinus floor, among the second premolars than among the first premolars studied. Root protrusion into the maxillary

sinus (type 3) was rare in the maxillary first premolars but more frequent in the second premolars, as found in a previous study.<sup>1</sup>

The sagittal root position in the alveolar bone should be considered when planning implant treatment.<sup>11</sup> Others have shown that most maxillary incisors<sup>10-12</sup> and maxillary first premolars<sup>9</sup> are positioned buccally in the alveolar bone. In the present study, most of the maxillary first premolars were the buccal type, the middle type was more common in the second premolars, and there were no palatal-type teeth among the maxillary first premolars, which aligned with the findings of a previous study.<sup>9</sup> In the results of this study, the sinus floor-root relationship was significantly correlated with the root position in the alveolar bone. In the maxillary second premolars, more than half of the type 0 and type 2 teeth were the buccal type, and most of the type 1 and type 3 teeth were the middle type.

In addition to the root position, it is also necessary to evaluate the angle between the long axis of the tooth and the long axis of the alveolar bone for implant placement<sup>10,14</sup> or orthodontic treatment.<sup>34</sup> The implant placement angle should be as close as possible to the long axis angle of the tooth in the alveolar bone.<sup>35</sup> A greater difference between the implant angle and the long axis angle of the tooth results in a greater stress value.<sup>36</sup> The results of this study showed that the mean long axis angle of the maxillary first premolars was significantly larger than that of the second premolars, as reported in a previous study.<sup>3</sup> The angle between the tooth axis and the alveolar bone axis is influenced by the root position, and buccally positioned teeth show the largest angulation.<sup>9</sup> In our study, the angulation of buccal-type teeth was larger than that of middle-type teeth. Yoshimine et al.<sup>7</sup> reported that the long axis angle of the tooth in the alveolar bone increases as the distance between the maxillary sinus and the root increases in the posterior part of the maxilla. The present study showed that the long axis angle of the maxillary first premolar was largest in type 0 teeth, and that of the maxillary second premolar was largest in type 2 teeth, followed by type 0 teeth.

After tooth extraction, the alveolar ridge shows a significant dimensional change, with reduction of the overall ridge volume and changes in the ridge shape.<sup>15</sup> It has been shown that pre-extraction facial bone thickness is a major factor that affects the degree of vertical dimension change of the alveolar crest after tooth extraction and immediate implant placement.<sup>17,37</sup> When the buccal bone is less than 1 mm thick, vertical bone resorption is more severe than when it is more than 1 mm thick.<sup>17,37</sup> Previous studies have shown that the anterior teeth, including the maxillary pre-

molars, have thin buccal bone.<sup>24,38</sup>

In previous studies, the thickness of the buccal bone has been measured at various locations along the root below the alveolar ridge using CBCT imaging.<sup>14,21,28,38</sup> In this study, the thickness of the buccal bone was measured at two locations: at 1 mm below the alveolar crest (which greatly affects bone resorption after tooth extraction) and at the apical area (which is important for implant placement or apical surgery). The buccal bone of the maxillary first premolars was statistically significantly thinner than that of the maxillary second premolars, which aligned with the findings of previous studies.<sup>14,28</sup> In the apical region, more than half of the first premolars had buccal bone that was less than 1 mm thick, and most of the second premolars had buccal bone that was more than 2 mm thick. In the present study, the apical region buccal bone was thinnest in type 0 teeth and thickest in type 3 teeth; however, there was only a statistically significant difference in the apical region of the maxillary second premolars.

In conclusion, when the maxillary premolar was separated from the sinus floor, the maxillary premolars were more likely to be in the buccal position. The maxillary first premolars were positioned more buccally in the alveolar bone and had thinner buccal bone and larger angulation than the second premolars. Additional attention would be required for root canal treatment or extraction of the maxillary second premolars because the second premolars protruded into the maxillary sinus more frequently than the first premolars. The maxillary first premolars would also be expected to have more bone resorption after extraction than the second premolars because of the thin buccal bone. It is recommended to evaluate the root position and sagittal angle using CBCT for implant treatment planning.

**Conflicts of Interest:** None

## References

1. Kang SH, Kim BS, Kim Y. Proximity of posterior teeth to the maxillary sinus and buccal bone thickness: a biometric assessment using cone-beam computed tomography. *J Endod* 2015; 41: 1839-46.
2. Kim JH, Lee JG, Han DH, Kim HJ. Morphometric analysis of the anterior region of the maxillary bone for immediate implant placement using micro-CT. *Clin Anat* 2011; 24: 462-8.
3. Nishihara K, Yoshimine SI, Goto T, Ishihata K, Kume KI, Yoshimura T, et al. Topographic analysis of the maxillary premolars relative to the maxillary sinus and the alveolar bone using cone beam computed tomography. *Oral Surg Oral Med Oral Pathol Oral Radiol* 2017; 123: 606-12.
4. Jung YH, Cho BH. Assessment of the relationship between the

maxillary molars and adjacent structures using cone beam computed tomography. *Imaging Sci Dent* 2012; 42: 219-24.

5. Gu Y, Sun C, Wu D, Zhu Q, Leng D, Zhou Y. Evaluation of the relationship between maxillary posterior teeth and the maxillary sinus floor using cone-beam computed tomography. *BMC Oral Health* 2018; 18: 164.
6. Razumova S, Brago A, Howijeh A, Manvelyan A, Barakat H, Baykulova M. Evaluation of the relationship between the maxillary sinus floor and the root apices of the maxillary posterior teeth using cone-beam computed tomographic scanning. *J Conserv Dent* 2019; 22: 139-43.
7. Yoshimine S, Nishihara K, Nozoe E, Yoshimine M, Nakamura N. Topographic analysis of maxillary premolars and molars and maxillary sinus using cone beam computed tomography. *Implant Dent* 2012; 21: 528-35.
8. Sung CE, Cochran DL, Cheng WC, Mau LP, Huang PH, Fan WH, et al. Preoperative assessment of labial bone perforation for virtual immediate implant surgery in the maxillary esthetic zone: a computer simulation study. *J Am Dent Assoc* 2015; 146: 808-19.
9. Petaibunlue S, Serichetaphongse P, Pimkhaokham A. Influence of the anterior arch shape and root position on root angulation in the maxillary esthetic area. *Imaging Sci Dent* 2019; 49: 123-30.
10. Lau SL, Chow J, Li W, Chow LK. Classification of maxillary central incisors-implications for immediate implant in the esthetic zone. *J Oral Maxillofac Surg* 2011; 69: 142-53.
11. Kan JY, Roe P, Rungcharassaeng K, Patel RD, Waki T, Lozada JL, et al. Classification of sagittal root position in relation to the anterior maxillary osseous housing for immediate implant placement: a cone beam computed tomography study. *Int J Oral Maxillofac Implants* 2011; 26: 873-6.
12. Xu D, Wang Z, Sun L, Lin Z, Wan L, Li Y, et al. Classification of the root position of the maxillary central incisors and its clinical significance in immediate implant placement. *Implant Dent* 2016; 25: 520-4.
13. Chung SH, Park YS, Chung SH, Shon WJ. Determination of implant position for immediate implant placement in maxillary central incisors using palatal soft tissue landmarks. *Int J Oral Maxillofac Implants* 2014; 29: 627-33.
14. Wang HM, Shen JW, Yu MF, Chen XY, Jiang QH, He FM. Analysis of facial bone wall dimensions and sagittal root position in the maxillary esthetic zone: a retrospective study using cone beam computed tomography. *Int J Oral Maxillofac Implants* 2014; 29: 1123-9.
15. Hämmerle CH, Araújo MG, Simion M, Osteology Consensus Group 2011. Evidence-based knowledge on the biology and treatment of extraction sockets. *Clin Oral Implants Res* 2012; 23 Suppl 5: 80-2.
16. Araújo MG, Silva CO, Misawa M, Sukekava F. Alveolar socket healing: what can we learn? *Periodontol 2000* 2015; 68: 122-34.
17. Tomasi C, Sanz M, Cecchinato D, Pjetursson B, Ferrus J, Lang NP, et al. Bone dimensional variations at implants placed in fresh extraction sockets: a multilevel multivariate analysis. *Clin Oral Implants Res* 2010; 21: 30-6.
18. Rossi F, Romanelli P, Ricci E, Marchetti C, Botticelli D. A cone beam tomographic evaluation of hard tissue alterations at immediate implants: a clinical prospective study. *Int J Periodontics Restorative Dent* 2013; 33: 815-23.
19. Buser D, Chappuis V, Belser UC, Chen S. Implant placement post extraction in esthetic single tooth sites: when immediate, when early, when late? *Periodontol 2000* 2017; 73: 84-102.
20. Chappuis V, Engel O, Reyes M, Shahim K, Nolte LP, Buser D. Ridge alterations post-extraction in the esthetic zone: a 3D analysis with CBCT. *J Dent Res* 2013; 92(12 Suppl): 195S-201S.
21. Khoury J, Ghosn N, Mokbel N, Naaman N. Buccal bone thickness overlying maxillary anterior teeth: a clinical and radiographic prospective human study. *Implant Dent* 2016; 25: 525-31.
22. Wong J, Lee A, Zhang C. Diagnosis and management of apical fenestrations associated with endodontic diseases: a literature review. *Eur Endod J* 2021; 6: 25-33.
23. Gupta R, Hasselgren G. Prevalence of odontogenic sinus tracts in patients referred for endodontic therapy. *J Endod* 2003; 29: 798-800.
24. Januário AL, Duarte WR, Barriviera M, Mesti JC, Araújo MG, Lindhe J. Dimension of the facial bone wall in the anterior maxilla: a cone-beam computed tomography study. *Clin Oral Implants Res* 2011; 22: 1168-71.
25. Fuentes R, Flores T, Navarro P, Salamanca C, Beltrán V, Borie E. Assessment of buccal bone thickness of aesthetic maxillary region: a cone-beam computed tomography study. *J Periodontal Implant Sci* 2015; 45: 162-8.
26. Farahamnd A, Sarlati F, Eslami S, Ghassemian M, Youssefi N, Jafarzadeh Esfahani B. Evaluation of impacting factors on facial bone thickness in the anterior maxillary region. *J Craniofac Surg* 2017; 28: 700-5.
27. Gakonyo J, Mohamedali AJ, Mungure EK. Cone beam computed tomography assessment of the buccal bone thickness in anterior maxillary teeth: relevance to immediate implant placement. *Int J Oral Maxillofac Implants* 2018; 33: 880-7.
28. Rojo-Sanchis J, Viña-Almunia J, Peñarrocha-Oltra D, Peñarrocha-Diogo M. Facial alveolar bone width at the first and second maxillary premolars in healthy patients: a cone beam computed tomography study. *J Oral Implantol* 2017; 43: 261-5.
29. Hauman CH, Chandler NP, Tong DC. Endodontic implications of the maxillary sinus: a review. *Int Endod J* 2002; 35: 127-41.
30. Manor Y, Anavi Y, Gershonovitch R, Lorean A, Mijiritsky E. Complications and management of implants migrated into the maxillary sinus. *Int J Periodontics Restorative Dent* 2018; 38: e112-8.
31. Oberli K, Bornstein MM, von Arx T. Periapical surgery and the maxillary sinus: radiographic parameters for clinical outcome. *Oral Surg Oral Med Oral Pathol Oral Radiol Endod* 2007; 103: 848-53.
32. von Arx T, Fodich I, Bornstein MM. Proximity of premolar roots to maxillary sinus: a radiographic survey using cone-beam computed tomography. *J Endod* 2014; 40: 1541-8.
33. Jang JK, Kwak SW, Ha JH, Kim HC. Anatomical relationship of maxillary posterior teeth with the sinus floor and buccal cortex. *J Oral Rehabil* 2017; 44: 617-25.
34. Zhang S, Shi X, Liu H. Angulations of anterior teeth with reference to the alveolar bone measured by cbct in a chinese population. *Implant Dent* 2015; 24: 397-401.
35. Araújo MG, Sukekava F, Wennström JL, Lindhe J. Ridge alter-



- ations following implant placement in fresh extraction sockets: an experimental study in the dog. *J Clin Periodontol* 2005; 32: 645-52.
36. Rito-Macedo F, Barroso-Oliveira M, Paranhos LR, Rodrigues-Brum J, Pereira-Lima IF, Gomes-França FM, et al. Implant insertion angle and depth: peri-implant bone stress analysis by the finite element method. *J Clin Exp Dent* 2021; 13: e1167-73.
37. Ferrus J, Cecchinato D, Pjetursson EB, Lang NP, Sanz M, Lindhe J. Factors influencing ridge alterations following immediate implant placement into extraction sockets. *Clin Oral Implants Res* 2010; 21: 22-9.
38. Vera C, De Kok IJ, Reinhold D, Limpiphipatanakorn P, Yap AK, Tyndall D, et al. Evaluation of buccal alveolar bone dimension of maxillary anterior and premolar teeth: a cone beam computed tomography investigation. *Int J Oral Maxillofac Implants* 2012; 27: 1514-9.