



# Diplopia following posterior superior alveolar nerve block: a case report and review of literature

Aditya Mohan Alwala<sup>1</sup>, Padminii Ellapakurthi<sup>2</sup>, Sushma Mudhireddy<sup>3</sup>, Ramanarayana Boyapati<sup>4</sup>

<sup>1</sup>Department of Oral and Maxillofacial Surgery, MNR Dental College and Hospital, Sangareddy, Telangana, India

<sup>2</sup>Oral and Maxillofacial Surgeon-Sree AM Dental Care, Hyderabad, Telangana, India

<sup>3</sup>Public Health Dentistry-Sree AM Dental Care, Hyderabad, Telangana, India

<sup>4</sup>Department of Periodontics, Sibar Institute of Dental Sciences, Takkellapadu, Guntur, Andhra Pradesh, India

Posterior superior alveolar nerve block (PSANB) is one of the most common and safe injection techniques in the field of dentistry. As with any other procedure, it also has inherent complications, of which ophthalmic complications are relatively rare. Transient diplopia following the administration of PSANB is rare and daunting for both the patient and the clinician. We present a case of transient diplopia in a 26-year-old female patient following administration of PSANB and review its probable pathophysiology and management and prevention.

**Keywords:** Dental Anesthesia; Diplopia; Nerve Block; Ocular Complications; Superior Alveolar Nerve.



This is an Open Access article distributed under the terms of the Creative Commons Attribution Non-Commercial License (<http://creativecommons.org/licenses/by-nc/4.0/>) which permits unrestricted non-commercial use, distribution, and reproduction in any medium, provided the original work is properly cited.



## INTRODUCTION

Posterior superior alveolar nerve block is one of the most frequently administered injection techniques in dentistry. However, hematoma is among the most common complications of this technique, which includes mandibular nerve and V3 division anesthesia [1]. Other unusual complications attributed to drugs and procedural complications include pain on injection, edema, needle breakage, and post-anesthetic lesions, while toxicity and allergic reactions may be related to drug-body responses.

In addition to these local complications, ocular complications are also rare. To date, a very limited number of ophthalmologic complications secondary to intraoral anesthetic injections have been recorded.

Posterior superior alveolar nerve block anesthesia is, however, a common cause of ophthalmic complications after intraoral local anesthetic administration [2].

Motor/sensory complications, such as diplopia, occur due to the spread of the local anesthetic solution through the vascular, neurological, myofascial, or lymphatic networks [3]. These symptoms are generally temporary and regain normal function after the anesthetic effect is weaned off. However, such an event is distressing for both patients and clinicians. Hence, awareness of such situations is important for the management of unwarranted complications. Herein, the authors discuss one such case, in which the patient developed signs of diplopia after undergoing tooth extraction.

**Received:** September 4, 2021 • **Revised:** October 19, 2021 • **Accepted:** December 5, 2021

**Corresponding Author:** Ramanarayana Boyapati, MDS, Associate Professor, Department of Periodontics, Sibar Institute of Dental Sciences, Takkellapadu, Guntur, Andhra Pradesh, PIN Code- 522509, India

Tel: +91-9490144365 E-mail: [dr.ramanarayana@gmail.com](mailto:dr.ramanarayana@gmail.com)

Copyright© 2022 Journal of Dental Anesthesia and Pain Medicine

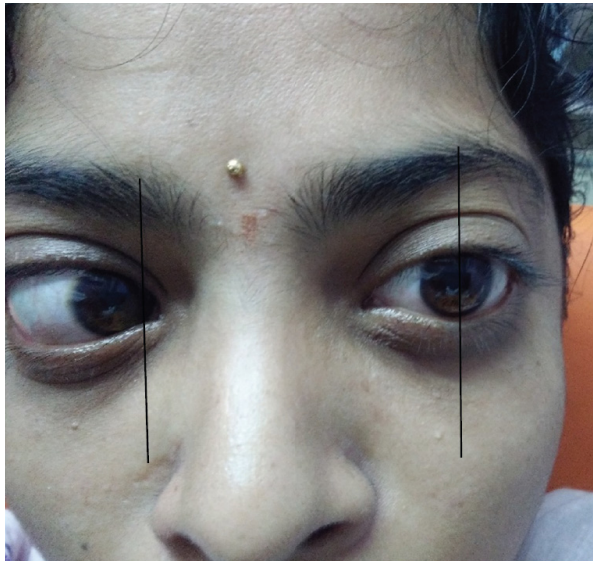

Fig. 1. No abduction in the left eye

## CASE REPORT

A 26-year-old, otherwise healthy, woman was admitted to a private dental clinic for continuous pain in the upper left side of her jaw. Routine clinical and radiological assessments revealed chronic irreversible pulpitis with a grossly decayed maxillary left-third molar. After determining that there was no significant previous medical or dental history, extraction of the maxillary left third molar was planned. On the day of the extraction, routine preoperative vital signs were monitored and found to be normal. After obtaining consent for the tooth removal, a standard protocol was followed. Posterior superior alveolar and greater palatine nerve blocks were administered with 2% lignocaine HCl with 1:80,000 adrenaline in volumes of 1.5 ml and 0.5 ml, respectively. After confirmation of the signs and symptoms in the patient, the tooth was extracted with minimal trauma.

Just before discharge, she complained of double vision. Local measures were taken to control the hematoma. On examination, the pupils were equal, round, reactive to light, and accommodating. The patient complained of inadequate abduction in the left eye (Fig. 1). However, movement of the eye in all other directions was apparent. A clinical evaluation of the facial nerve was performed

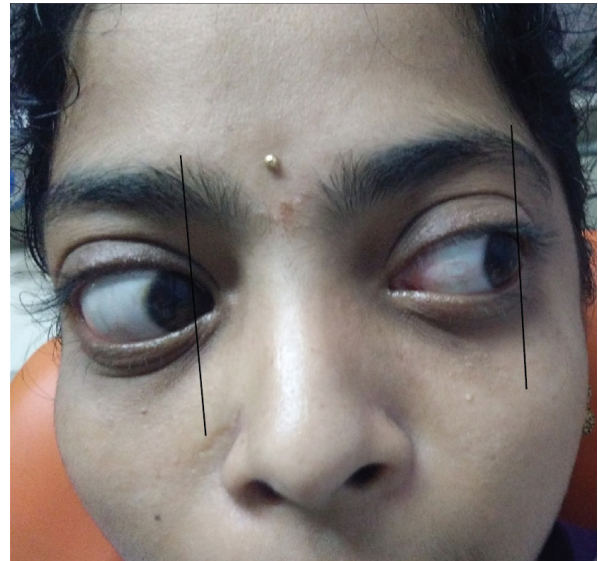

Fig. 2. Restoration of the abductive movement in the left eye

using various methods and no abnormalities were observed.

A provisional diagnosis of transient diplopia, secondary to a posterior superior alveolar nerve block, was made based on the events leading to her clinical symptoms. The affected eyelid was taped in a closed position to provide corneal protection and to prevent further damage. Diplopia was checked every 15 min, and complete recovery was reported after 30 min. Ocular movements were reassessed to confirm restoration of the full range of movement in all gazes of the left eye (Fig. 2). The patient was kept under observation and no further complaints were noted at that time. The patient was referred to an ophthalmologist to rule out diplopia and ocular mobility. Appropriate tests were conducted to prove adequate mobility and to rule out diplopia. These were the forced duction test, Hess chart, and diplopia chart.

## DISCUSSION

With myths related to loss of vision following removal of the upper teeth being very prevalent in the general public, extraction of maxillary teeth remains fearsome for a majority of patients. Despite a number of conversations

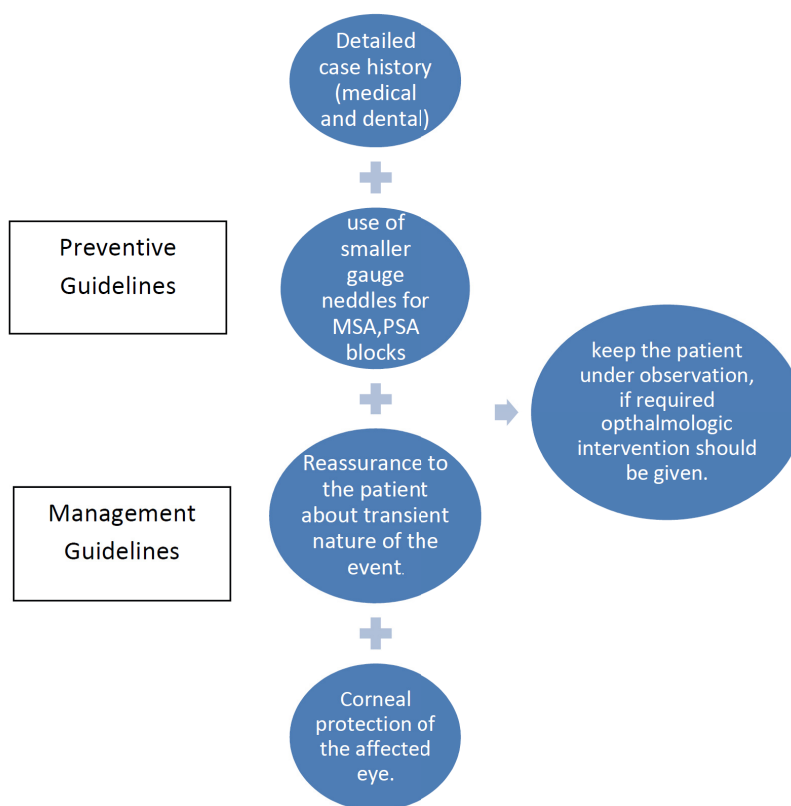


Fig. 3. Preventive and management guidelines

and solaces, patients tend to remain worried. Of all the intraoral procedures performed by a dental surgeon, local anesthetic injections are associated with the mainstream course of ophthalmologic complications. von Arx T et al. [2] reviewed typical incidences of ophthalmologic complications after intraoral local anesthesia and noted that conditions such as diplopia accounted for 39.8% of difficulties in their study. A case of permanent loss of vision in one eye after the administration of intraoral local anesthesia was also reported by Rishiraj et al. in 2005 [4]. Maxillary nerve block causes complications through the following pathways:

1) Direct diffusion of the anesthetic solution from the pterygomaxillary fossa to the orbit, through a defect in the bone.

2) Vascular causes in which the anesthetic solution is diffused through myofascial spaces or bony openings, such as through the inferior orbital fissure, to affect the extra ocular muscles [3].

Confluence of the orbital branch of the middle

meningeal artery and the recurrent meningeal division of the lacrimal branch of the ophthalmic artery leads to paralysis of the lateral rectus muscle and diplopia, in instances of intra-arterial deposition of local anesthesia [5]. Intraluminal injection into the inferior ophthalmic vein can also affect the extrinsic muscles of the eye through the inferior orbital foramen [6]. Diffusion of the anesthetic agent to the orbital cavity can also attain a pathway along the pterygomaxillary fossa through the sphenomaxillary cavity, indirectly impacting nerve endings [7]. As the authors discuss the occurrence of diplopia after posterior superior alveolar nerve block, the literature reveals that diplopia is more common in maxillary than in mandibular anesthesia techniques because of the difference in bone density due to increased dissipation. There are studies suggesting a higher prevalence of ophthalmic complications in female patients compared to men, and more, following usage of 2% articaine than any other local anesthetic agents [8,9]. In the present case, 2% lignocaine HCl was used

as a local anesthetic agent for a posterior superior alveolar nerve block in the recumbent position. Walker et al.[10] identified that the recumbent position of a patient during anesthesia delivery, along with the porous nature of the maxilla, may play a role in causing ophthalmologic complications.

### Prevention and management

Awareness of the complications that can occur after a procedure will keep the practitioner prepared to handle the situation. Owing to the fact that ocular complications post-intra-oral local anesthesia are mostly transient, preventive measures taken can reduce anxiety in both patient and doctor. Some authors [5,11] have established preventive and management measures. We have summarized the same for the easier understanding of students and educators (Fig. 3).

In conclusion, complications of local and regional blocks may be less frequent in most cases, but certain conditions such as diplopia and ocular complications occur in rare situations. Correct knowledge and implementation of medical care is helpful in the management of such rare situations.

#### AUTHOR ORCID*s*

**Aditya Mohan Alwala:** <https://orcid.org/0000-0002-0242-2966>

**Padmini Ellapakurthi:** <https://orcid.org/0000-0003-1307-5987>

**Sushma Mudhireddy:** <https://orcid.org/0000-0003-2510-233X>

**Ramanarayana Boyapati:** <https://orcid.org/0000-0002-9196-0183>

#### AUTHOR CONTRIBUTIONS

**Aditya Mohan Alwala:** Conceptualization, Data curation, Investigation, Project administration, Visualization, Writing - original draft

**Padmini Ellapakurthi:** Conceptualization, Project administration, Writing - original draft

**Sushma Mudhireddy:** Conceptualization

**Ramanarayana Boyapati:** Project administration, Resources, Writing - review & editing

**CONFLICTS OF INTEREST:** The authors declare no conflict of interest.

**CONSENT:** Informed consent was obtained from the

patient in this case report.

The Ethical Committee constituted by MNR Dental College & Hospital, Sangareddy has approved the case for Publication. Reference Number – IEC/MNRD/2019/ 013

### REFERENCES

1. Malamed S. Handbook of local anesthesia. 5th ed. St Louis. Mosby, 2004.
2. von Arx T, Lozanoff S, Zinkernagel M. Ophthalmologic complications after intraoral local anesthesia. *Swiss Dent J* 2014; 124: 784-806.
3. Boynes SG, Echeverria Z, Abdulwahab M. Ocular complications associated with local anesthesia administration in dentistry. *Dent Clin North Am* 2010; 54: 677-86.
4. Rishiraj B, Epstein JB, Fine D, Nabi S, Wade NK. Permanent vision loss in one eye following administration of local anesthesia for a dental extraction. *Int J Oral Maxillofac Surg* 2005; 34: 220-3.
5. Chun-kei L. Ocular complications after inferior alveolar nerve block. *Dent Bull* 2006; 11: 4-5.
6. Crean SJ, Powis A. Neurological complications of local anaesthetics in dentistry. *Dent Update* 1999; 26: 344-9.
7. Peñarrocha-Diago M, Sanchis-Bielsa JM. Ophthalmologic complications after intraoral local anesthesia with articaine. *Oral Surg Oral Med Oral Pathol Oral Radiol Endod* 2000; 90: 21-4.
8. Steenen SA, Dubois L, Saeed P, de Lange J. Ophthalmologic complications after intraoral local anesthesia: case report and review of literature. *Oral Surg Oral Med Oral Pathol Oral Radiol* 2012; 113: e1-5.
9. Magliocca KR, Kessel NC, Cortright GW. Transient diplopia following maxillary local anesthetic injection. *Oral Surg Oral Med Oral Pathol Oral Radiol Endod* 2006; 101: 730-3.
10. Walker M, Drangsholt M, Czartoski TJ, Longstreth WT Jr. Dental diplopia with transient abducens palsy. *Neurology* 2004; 63: 2449-50.
11. van der Bijl P, Meyer D. Ocular complications of dental local anaesthesia. *SADJ* 1998; 53: 235-8.