


# Enhancement of chronic wound healing with maltodextrin/ascorbic acid gel: a clinical evaluation of distal limb wounds in horses

Ibrahim E. Helal<sup>1,2</sup>, Hatim A. Al-Abbadi<sup>3</sup>, Mohamed H. El-Daharawy<sup>1</sup> and Mahmoud F. Ahmed<sup>1\*</sup>

<sup>1</sup>Department of Surgery, Anesthesiology and Radiology, Faculty of Veterinary Medicine, Suez Canal University, Ismailia 41522, Egypt

<sup>2</sup>Equestrian Center Clinic, King Abdulaziz University, Jeddah 80212, Saudi Arabia

<sup>3</sup>University Hospital, Faculty of Medicine, King Abdulaziz University, Jeddah 80212, Saudi Arabia



Received: Mar 30, 2022

Revised: Jun 1, 2022

Accepted: Jun 16, 2022

## \*Corresponding author

Mahmoud F. Ahmed

Department of Surgery, Anesthesiology and Radiology, Faculty of Veterinary Medicine, Suez Canal University, Ismailia 41522, Egypt.

Tel: +20-64-320-7052

E-mail: mahmoud\_ali@vet.suez.edu.eg

Copyright © 2022 Korean Society of Animal Sciences and Technology.

This is an Open Access article distributed under the terms of the Creative Commons Attribution Non-Commercial License (<http://creativecommons.org/licenses/by-nc/4.0/>) which permits unrestricted non-commercial use, distribution, and reproduction in any medium, provided the original work is properly cited.

## ORCID

Ibrahim E. Helal

<https://orcid.org/0000-0003-2378-7961>

Hatim A. Al-Abbadi

<https://orcid.org/0000-0002-1258-693X>

Mohamed H. El-Daharawy

<https://orcid.org/0000-0002-9452-5857>

Mahmoud F. Ahmed

<https://orcid.org/0000-0002-4654-5909>

## Competing interests

No potential conflict of interest relevant to this article was reported.

## Funding sources

Not applicable.

## Abstract

Delayed healing associated with distal limb wounds is highly challenging in equine clinical practice. This study aimed to evaluate healing rates between chronic non-granulating wounds of horse distal limbs that were treated with maltodextrin/ascorbic acid gel alone or in combination with povidone-iodine 1% solution and those treated with povidone-iodine 1% only throughout the study period (35 days) in clinical settings. The study was conducted on 18 adult horses (3–15 years old). Based on the treatment regimen utilized, the horses were divided into three groups (n = 6), with each group having a similar mean wound area. The percentages of wound contraction, epithelialization, and overall wound healing were determined weekly for each wound. By the end of the study, the total wound healing percentage was significantly increased between the study groups ( $p < 0.05$ ). The use of maltodextrin/ascorbic acid gel resulted in considerable wound contraction, rapid epithelialization, and complication-free wound healing. Based on the findings of this study, maltodextrin/ascorbic acid gel, independently or in combination with a 1% povidone-iodine solution, might be applied as a safe and effective wound healing promoting agent in horses with chronic non-granulating wounds.

**Keywords:** Horses, Maltodextrin/ascorbic acid gel, Chronic non-granulating wounds, Wound healing, Clinical study

## INTRODUCTION

The wound is the second most prevalent emergency condition in horses [1]. Additionally, traumatic wounds are common in horses, and a large percentage of these develop into chronic wounds [2]. Horses often display a difficult challenge in distal limb wound healing [3,4]. A large percentage of horses are likely to be impacted by aberrant limb wound healing at some point in their lives [5]. Many horse skin wounds are not healed by the first intention due to difficult suturing owing to substantial soft tissue loss,

### Acknowledgements

The authors would thank Prof. Dr. Ibrahim H. Ahmed, Dr. Mohamed A. Hashem and Mr. Saad L. Saad from Faculty of Veterinary Medicine, Suez Canal University for their professional technical assistance during the course of this study. Authors would like to express their gratitude to the veterinarians at Equestrian Center Clinic, King Abdulaziz University, Jeddah, Kingdom of Saudi Arabia for their practical contribution to the study.

### Availability of data and material

Upon reasonable request, the datasets of this study can be available from the corresponding author.

### Authors' contributions

Conceptualization: Helal IE, Ahmed MF.

Data curation: Helal IE, Ahmed MF.

Formal analysis: Helal IE, Al-Abbadi HA, El-Daharawy MH, Ahmed MF.

Methodology: Helal IE, Al-Abbadi HA, El-Daharawy MH, Ahmed MF.

Software: Ahmed MF.

Validation: Ahmed MF.

Investigation: Helal IE, Al-Abbadi HA, Ahmed MF.

Writing - original draft: Helal IE, Al-Abbadi HA, El-Daharawy MH, Ahmed MF.

Writing - review & editing: Helal IE, Al-Abbadi HA, El-Daharawy MH, Ahmed MF.

### Ethics approval and consent to participate

The Institutional Animal Use and Care Committee of the Faculty of Veterinary Medicine at Suez Canal University reviewed and authorized all experimental procedures (Approval Number 2021022).

high skin tension, motion, infection susceptibility, inadequate blood supply, partial or full wound dehiscence, or a long interval after injury [6,7]. Clinically, horses with improperly healed distal limb injuries provide an ongoing challenge due to the prolonged inflammatory phase, decreased contraction, and epithelialization [8,9]. All these factors directly interfere with wound healing; thus, often making healing with a secondary intention the only choice [5,10]. Affected horses lose their economic value and become unsuitable for work over long periods, or their athletic careers are ended [5,11].

Treatment may be challenging owing to the wide range of wound types, locations, and severity, as well as a lack of primary data on optimal treatment techniques. The wound care literature primarily comprises expert opinion or case series, and there are presently no evidence summaries to guide therapeutic decision-making [12].

There are a wide variety of wound care medications for horse practitioners; however, only a few have been clinically studied for their effect on chronic wound healing in horses [13,14]. Various topical wound therapies have been tested in horses' distal limb models to enhance second-intention wounds, with varying degrees of success [13,15]. Furthermore, several medications had inconclusive outcomes for improving wound healing when compared to the control group [16–21]. Thus, equine veterinarians should be aware that positive findings from these research studies have not been replicated consistently when evaluated *in vivo* on horse wounds [22].

Polysaccharides are some of the most ancient and popular drugs that promote wound healing [23,24]. Maltodextrins are highly specialized carbohydrates with the intriguing potential to enhance wound healing. Several reports have confirmed the general effectiveness of maltodextrins as a feasible alternative for the treatment of chronic wounds [25–27]. The maltodextrin/ascorbic acid gel combination has exhibited encouraging outcomes, such as softening of necrotic tissues to facilitate debridement and promoting granulation tissue formation and epithelialization in treating chronic wounds. Moreover, it showed efficacy in both infected and non-infected wounds, without being toxic or absorbed systemically [25,28]. Furthermore, it has a quick ability to penetrate wound irregularities to fill tunneling and undermining tissues [29,30]. Several studies have shown that maltodextrin/ascorbic acid gel appears to improve chronic wound healing via increased transforming growth factor  $\beta$ 1 protein expression, collagen turnover, and cytokine attraction [25,31]. In addition, maltodextrins have the potential to deliver nutrients to the wound bed by delivering glucose for cell metabolism via hydrolysis [32,33]. Furthermore, maltodextrin not only has chemotactic properties but also has antibacterial and bacteriostatic properties [31,32].

To the best of our knowledge, this is the first clinical study to use maltodextrin/ascorbic acid gel to treat chronic cutaneous wounds on horses' distal limbs that heal by second intention. This investigation aimed to test the effectiveness of this wound care product in field settings to assist horse practitioners in treating these types of delayed wounds.

## MATERIALS AND METHODS

### Study design

A randomized, multi-center clinical study including horses with distal limb old wounds was performed from January to September 2021. Horses were admitted to the Department of Surgery, Anesthesiology, and Radiology, Faculty of Veterinary Medicine, Suez Canal University, Ismailia, Egypt, and the Equestrian Center Clinic, King Abdulaziz University, Jeddah, Kingdom of Saudi Arabia. The study included 18 adult horses of both sexes ranging in age from 3 to 15 years. The horse breeds were as follows: six Baladi, eight Thoroughbred, and four Arabian. Based on the therapeutic protocol used, the horses were randomly allocated to different groups based on the

priority of their attendance at the clinic using regular sampling. Horses were divided into one of three groups following wound preparation, with a similar mean wound area in each group. Group 1 (n = 6): As a control group, wounds were irrigated using a sterile 0.9% physiological saline solution before applying a wet dressing moistened with 1% povidone-iodine solution (BETADINE®, Nile Pharma, Cairo, Egypt). Group 2 (n = 6) wounds were irrigated with a sterile 0.9% physiological saline solution before being dressed with maltodextrin/ascorbic acid gel (Multidex®, DeRoyal, Powell, TN, USA). Wounds in Group 3 (n = 6) were irrigated with a sterile 0.9% physiological saline solution followed by a 1% povidone-iodine solution before being dressed with Multidex®.

Before treatment, horse owners were informed of their animals' participation in the clinical study. The Institutional Animal Use and Care Committee of the Faculty of Veterinary Medicine at Suez Canal University in Egypt evaluated and approved the research protocol (2021022). All treatments were performed with the utmost consideration for animal welfare.

### The inclusion criteria

Horses were selected based on predetermined selection criteria as follows: Mature (non-geriatric) healthy horses without signs of infection or other systemic diseases. Cutaneous chronic wounds were included when they were at the distal limbs under the level of the carpus or tarsus, with an incomplete granulating bed (approximately 0.5–1.0 cm depth when measured with a probe). Wounds had nearly the same mean surface area in the different groups ( $12.67 \pm 1.2$ ,  $12.67 \pm 3.71$ , and  $12.67 \pm 2.73$  cm<sup>2</sup> for groups 1, 2, and 3, respectively).

### Surgical management of wounds

Horses were restrained if necessary, either by application of a nose twitch or by intravenous doses of 1.1 mg/kg Xylazine HCL (Thiazine 100, Ceva Animal Health, Glenorie, NSW, Australia) [34]. The wounded areas were routinely clipped and aseptically prepared. Chronic incomplete granulating wounds were debrided, all necrotic tissues were removed, cleansed with isotonic saline, and the treatment regimen for the assigned group was applied daily. After application of the prescribed treatment, the wound surface was covered with a non-adherent, non-occlusive dressing (MultiPad™, DeRoyal) which was secured in place by cohesive elastic bandages (STRAP BAND, Génia, Saint-Hilaire-de-Chaléons, France). Following this, the second layer of cotton padding was applied and covered using cohesive elastic bandages. Bandages were changed once a day as prescribed by Howard et al. [26] until healthy granulation tissue had filled the wound depth, and treatment was subsequently provided without the need for a bandage cover. The bandage was changed with caution to retain the healthy granulation tissue that had grown. If the dressing stuck to the wound, it was soaked in saline for several minutes before being removed to prevent disrupting the delicate granulation tissue.

### Gross observation of wound healing

Wound healing quality was evaluated at week intervals by clinical examination of the appearance, color, contraction, regularity of granulation tissue, epithelization, and wound exudation.

### Wound measurement and evaluation

Wounds were assessed weekly by a blinded investigator for signs of complications and, later complete epithelialization, which was then recorded. Digital photographs and subjective wound data were collected all over the study period (35 days). The wounds were gently wiped clean using sterile saline before closer evaluation to facilitate data acquisition. Before photographing, the hair at the wound borders was clipped, and a tape measure was used as a calibration reference. These

images were used for the evaluation and scoring of the measured parameters. Each parameter was measured thrice and the mean was used for calculation. Wounds were measured using Fiji in Image J software, version 1 (National Institutes of Health, Bethesda, MD, USA) [35]. The surface area was calculated by multiplying the greatest length by the perpendicular greatest width [36]. For each wound, the percentage of wound contraction, epithelialization, and overall wound healing was determined using the formulae provided by Bohling et al. [37]. The wound contraction % was calculated as follows: the total wound area on day  $n$  as a % of the original wound = (total wound area at day  $n \times 100$ ) / original wound area at day zero, then the % of wound contraction at day  $n$  =  $100 -$  total wound area at day  $n$  as a % of the original wound size. The epithelization % at day  $n$  = (area of epithelization day  $n \times 100$ ) / total wound area day  $n$ . The total wound healing % was calculated as follows: the open wound day  $n$  as a % of the original wound size = (open wound area at day  $n \times 100$ ) / original wound area at day zero, then the % of total wound healing at day  $n$  =  $100 -$  open wound day  $n$  as a % of the original wound size.

### Statistical analysis


All quantitative data are expressed as the mean  $\pm$  standard deviation. SPSS software version 21 (IBM, Armonk, NY, USA) was used for statistical analysis. Data were analyzed using a two-way analysis of variance followed by Tukey's post hoc test. The  $p$ -value was estimated at  $p < 0.05$ . GraphPad Prism software version 6 was used to create the graphs (GraphPad Software, La Jolla, CA, USA).

## RESULTS

During the study period, the horses were clinically healthy without the use of any antibacterial or anti-inflammatory drugs. Additionally, there were no exclusions of any horses due to the topical treatment applied. Wound debridement was extremely significant for the elimination of dead and necrotized tissues providing a suitable environment for the treatment's action for efficient and clean healing till the wound surface became bright red and moist. Packing was used to halt and control any bleeding that may have occurred as a result of debridement.

The wounds in all study groups were filled with granulation tissue (Fig. 1) with varying periods. Bandages were removed from all horses when healthy granulation tissue had filled the wound depth between 9–16 days (mean  $13.83 \pm 2.48$ ), 7–12 days (mean  $9.67 \pm 1.97$ ) and 7–10 days (mean  $8.83 \pm 1.17$ ) for groups 1, 2 and 3 respectively. No exuberant granulation tissue was reported in any of the wounds, and there were no adverse side effects related to the Multidex® application.

The percentages of macroscopic wound contraction showed no significance between groups 2 and 3 on days 7 and 35 ( $p > 0.05$ ) (Fig. 2). The wound area contracted fast in horses treated with Multidex® in groups 2 and 3, compared to horses treated with BETADINE® only in the control group. As presented in Fig. 3, the epithelialization rates increased in different groups during the observation period. However, group 3 demonstrated the greatest increase in epithelialization rates compared to the control group by the end of the study. The mean epithelization percentage between groups by the end of the study was  $74.96 \pm 1.67$ ,  $87.23 \pm 2.33$ , and  $92.03 \pm 3.38$  for groups 1, 2, and 3, respectively. Regarding the total healing time, wounds irrigated with BETADINE® before the application of Multidex® healed faster than other wounds. The mean total wound healing percentage by the end of the study in different groups was  $79.59 \pm 4.16$ ,  $89.36 \pm 2.6$ , and  $94.71 \pm 3.2$  for groups 1, 2, and 3, respectively (Fig. 4). The total wound healing percentage for group 3 was significantly increased ( $p < 0.05$ ) than that for group 2 and the control group by the end of the study period.

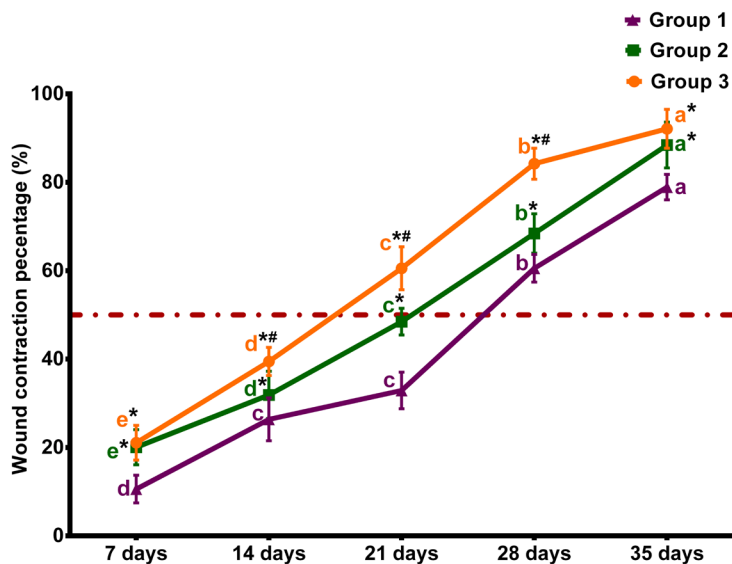


**Fig. 1.** Representative wound images of different study groups show the progress of wound healing from the first day of treatment (0 day), after filling of the non-granulating bed with granulation tissue, and at the end of the study period (35 days), respectively. Group 1 is a control group in which wounds are cleaned using a sterile 0.9% physiological saline solution before being dressed with BETADINE®; Group 2 is irrigated with a sterile 0.9% physiological saline solution before being dressed with Multidex®; and Group 3 is irrigated with a sterile 0.9% physiological saline solution followed by BETADINE® solution before being dressed with Multidex®.

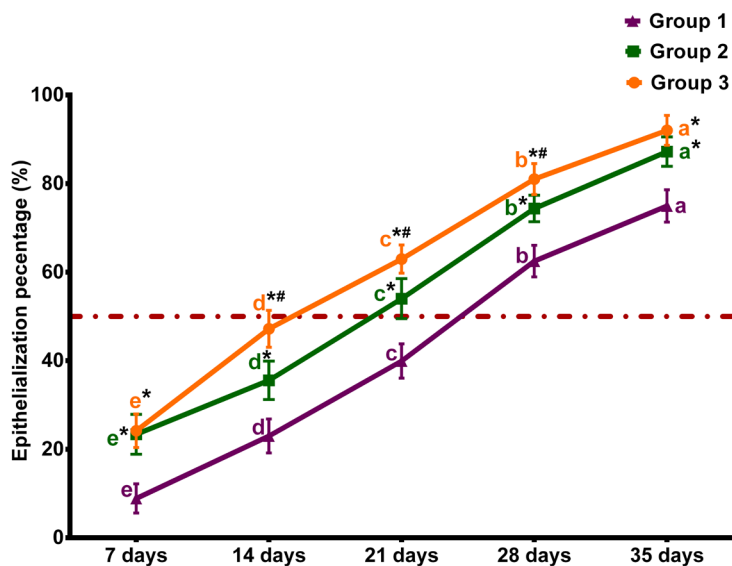
## DISCUSSION

Wound healing by second intention aims to restore the tissue defect by the creation of granulation tissue, which provides a matrix for epithelial cell migration [38]. Although the benefits of maltodextrin/ascorbic acid gel have been established for long, research or clinical studies performed on its use in horse wounds are limited. This clinical study aims to assess the healing efficacy of maltodextrin/ascorbic acid gel on distal limb chronic non-granulating wounds in horses.

We chose to focus on distal limb chronic non-granulating wounds in horses since wounds on the distal limb do not appear to heal or contract as well as other kinds. According to several studies, the rates of wound contraction differed depending on the location of the wound on the horse. Clinical findings have demonstrated that horse limb wounds recover at around half the pace of body wounds [39,40]. Furthermore, small wounds on the equine distal limb that are expected to heal without any significant contraction may fail to heal [5]. Horses in this research ranged in age from 3 to 15 years, with geriatric horses being excluded to avoid reduced fibroplasia and an increased infection risk [41].

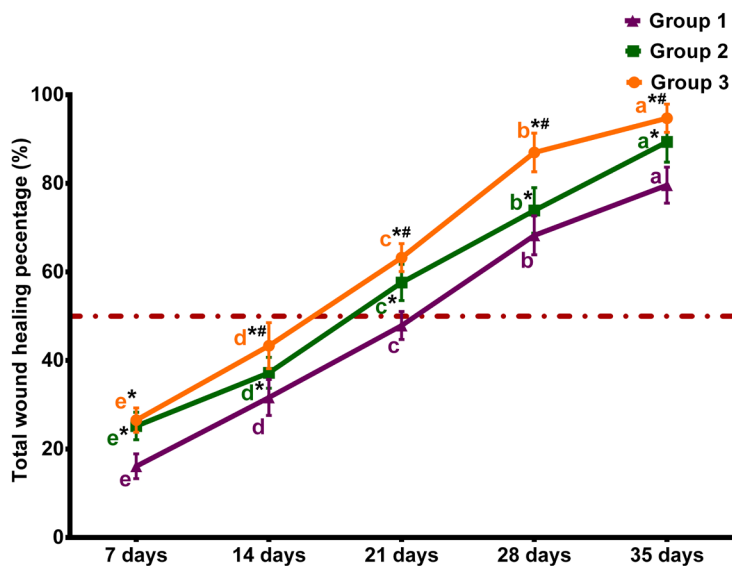


**Fig. 2. Wound contraction percentage of various treatment groups weekly.** The quantitative data are presented as the mean  $\pm$  SD. Multi-group comparisons are evaluated using a two-way analysis of variance (ANOVA), followed by Tukey's post hoc test, where, in the same group, different letters indicate  $p < 0.05$ , and the same letter indicates  $p > 0.05$ . At the same time point, \*means  $p < 0.05$  vs. group 1, while #means  $p < 0.05$  vs. group 2. The dashed line denotes the amount of wound contraction at 50%.



**Fig. 3. Wound epithelialization percentage of various treatment groups weekly.** The quantitative data are presented as the mean  $\pm$  SD. Multi-group comparisons are evaluated using a two-way analysis of variance (ANOVA), followed by Tukey's post hoc test, where, in the same group, different letters indicate  $p < 0.05$ , and the same letter indicates  $p > 0.05$ . At the same time point, \*means  $p < 0.05$  vs. group 1, while #means  $p < 0.05$  vs. group 2. The dashed line denotes the amount of wound epithelialization at 50%.

In this study, it was found that using maltodextrin/ascorbic acid gel in chronic wounds in the equine distal limb, either alone or in conjunction with povidone-iodine 1%, enhanced granulation tissue formation and epithelialization, which is consistent with prior research results in experimental models or human clinical cases [13,22,26,27,30,32,42,43]. There were no clinical consequences



**Fig. 4. Total wound healing percentage of various treatment groups weekly.** The quantitative data are presented as the mean  $\pm$  SD. Multi-group comparisons are evaluated using a two-way analysis of variance (ANOVA), followed by Tukey's post hoc test, where, in the same group, different letters indicate  $p < 0.05$ , and the same letter indicates  $p > 0.05$ . At the same time point, \*means  $p < 0.05$  vs. group 1, while #means  $p < 0.05$  vs. group 2. The dashed line denotes the amount of wound repair at 50%.

detected during the maltodextrin/ascorbic acid gel application or healing period, which might be attributed to the fact that maltodextrin/ascorbic acid gel is manufactured from natural components such as maltodextrin and ascorbic acid [30,43].

Wound debridement and washing with an isotonic saline solution were conducted before treatment application to eliminate any necrotic tissue or debris that might serve as a potential source for infection and prevent wound contraction and epithelialization [23,44]. Although chronic wounds should be considered infected [44], the use of an antiseptic to lessen the wound's estimated bacterial population may be beneficial [45]. The general consensus is that using antiseptic dressings sparingly can be a valuable alternative for controlling infection and promoting healing in open wounds [8,46,47]. Povidone-iodine 1% [28] was selected since it is the most commonly used iodine in clinical settings, which retains broad-spectrum antibacterial, anti-fungal, and anti-viral effects while reducing tissue toxicity as recommended in contaminated wounds [8,12,45].

In this study, wounds treated with maltodextrin/ascorbic acid gel had no septic complications. This could be attributed to the use of diluted povidone-iodine, which showed a faster healing rate than equivalent wounds treated with isotonic saline solution [48,49]. In the same context, local antibiotics were not used with caution owing to bacterial resistance risk [45]. Regardless, antibiotics were not used in horses with distal limb wounds, instead of relying on the antibacterial activity of povidone-iodine as an antiseptic and the action of maltodextrin/ascorbic acid gel, which reduces wound pH and causes an osmotic effect that promotes bacterial lysis [26,50]. Furthermore, nonsteroidal anti-inflammatory drugs were specifically avoided since they would have interfered with the treatment's effectiveness [11,51].

Following each treatment, bandages were used to keep the area clean, protect the newly granulated tissue from drying out too rapidly, and keep the product on the wound surface [52]. Once a healthy layer of infection-resistant granulation tissue had formed, the bandages were removed as soon as possible to prevent the formation of exuberant granulation tissue [8].

A substantial improvement in overall wound contraction and epithelialization percentage, as

well as total wound healing percentage, was recorded throughout the study period when using maltodextrin/ascorbic acid gel alone or in conjunction with 1% povidone-iodine compared to using 1% povidone-iodine alone. On the other hand, povidone-iodine alone in the control group, delayed the development of granulation tissue and epithelialization process [23]. In agreement with previously reported findings, maltodextrin seemed to alleviate discomfort and induce granulation and epithelialization in an equine model when compared to topical antibiotics [13,29].

Our study was in contrast to the study by Howard et al. [26] who found no differences in assessed parameters between maltodextrin treated and control wounds throughout time or at any one-time point in the experimentally created wounds in equines. The difference in overall wound healing percentage between using maltodextrin/ascorbic acid gel alone and in combination with povidone-iodine could be attributed to the combined antibacterial activity of both compounds on bacterial infection because clinically relevant infections caused by bacterial infection can cause delayed wound healing [23].

In the current clinical investigation, maltodextrin/ascorbic acid gel increased wound filling with granulation tissue; however, unlike other experimental models using sugar-based dressings [7,26], the granulation tissue did not extend above the level of the epithelium, and the proliferative phase of wound healing was followed by epithelization.

Finally, regarding the regularity with which horses incur wounds and the inherent challenges associated with distal limb wound healing, maltodextrin/ascorbic acid gel exerts both host and antimicrobial effects, holding tremendous potential as an equine wound care product. The present clinical study proved the ability of maltodextrin/ascorbic acid gel to achieve better wound-healing capacity and cosmetic appearance under field conditions when compared with the conventional treatment of equine distal limb wounds.

The limitations of this research include the inability to identify the numerous bacterial species that developed on the wounds using bacterial cultures and the authors' reliance only on the clinical appearance of the wounds. Another limitation of the study is that it did not include larger and deeper cutaneous wounds and different age groups of horses (geriatric animals).

## CONCLUSION

The use of maltodextrin/ascorbic acid gel, alone or in conjunction with 1% povidone-iodine, results in the healing of chronic non-granulating wounds of the distal limb in horses when compared to the use of povidone-iodine alone. This combination provides a better mix for hastening and enhancing the healing process. Therefore, maltodextrin/ascorbic acid gel is being advocated as a safe, rapid, and effective alternative therapy for long-term non-healing wounds in equines.

## REFERENCES

1. Bowden A, England GCW, Burford JH, Mair TS, Furness W, Freeman SL. Prevalence and outcome of conditions seen at out-of-hours primary assessment at two practices over a 3-year period (2011–2013). *Equine Vet J.* 2017;49:11. [https://doi.org/10.1111/evj.14\\_12732](https://doi.org/10.1111/evj.14_12732)
2. Singer ER, Saxby F, French NP. A retrospective case-control study of horse falls in the sport of horse trials and three-day eventing. *Equine Vet J.* 2003;35:139-45. <https://doi.org/10.2746/042516403776114180>
3. Wilmlink JM, Ladefoged S, Jongbloets A, Vernooij JCM. The evaluation of the effect of probiotics on the healing of equine distal limb wounds. *PLOS ONE.* 2020;15:e0236761. <https://doi.org/10.1371/journal.pone.0236761>



4. Pereira RCF, De La Côte FD, Brass KE, da Silva Azevedo M, Gallio M, Cantarelli C, et al. Evaluation of three methods of platelet-rich plasma for treatment of equine distal limb skin wounds. *J Equine Vet Sci.* 2019;72:1-7. <https://doi.org/10.1016/j.jevs.2017.10.009>
5. Knottenbelt DC. Equine wound management: are there significant differences in healing at different sites on the body? *Vet Dermatol.* 1997;8:273-90. <https://doi.org/10.1111/j.1365-3164.1997.tb00273.x>
6. Theoret CL, Wilmink JM. Aberrant wound healing in the horse: naturally occurring conditions reminiscent of those observed in man. *Wound Repair Regen.* 2013;21:365-71. <https://doi.org/10.1111/wrr.12018>
7. Bischofberger AS, Dart CM, Perkins NR, Dart AJ. A preliminary study on the effect of manuka honey on second-intention healing of contaminated wounds on the distal aspect of the forelimbs of horses. *Vet Surg.* 2011;40:898-902. <https://doi.org/10.1111/j.1532-950X.2011.00886.x>
8. Dart AJ, Sole-Guitart A, Stashak TS, Theoret C. Management practices that influence wound infection and healing. In: Theoret C, Schumacher J, editors. *Equine wound management*. 3rd ed. Ames, IA: John Wiley & Sons; 2016. p. 47-74.
9. Wilmink JM, van Weeren PR. Second-intention repair in the horse and pony and management of exuberant granulation tissue. *Vet Clin North Am Equine Pract.* 2005;21:15-32. <https://doi.org/10.1016/j.cveq.2004.11.014>
10. Hendrickson DA. Management of superficial wounds, deep and chronic wounds, sinus tracts, and fistulas. In: Auer JA, Stick JA, Kümmerle JM, Prange T, editors. *Equine surgery*. 5th ed. Philadelphia, PA: W.B. Saunders; 2019. p. 403-25.
11. Iacopetti I, Perazzi A, Ferrari V, Busetto R. Application of platelet-rich gel to enhance wound healing in the horse: a case report. *J Equine Vet Sci.* 2012;32:123-8. <https://doi.org/10.1016/j.jevs.2011.08.012>
12. Freeman SL, Ashton NM, Elce YA, Hammond A, Hollis AR, Quinn G. BEVA primary care clinical guidelines: wound management in the horse. *Equine Vet J.* 2021;53:18-29. <https://doi.org/10.1111/evj.13289>
13. Dart AJ, Dowling BA, Smith CL. Topical treatments in equine wound management. *Vet Clin North Am Equine Pract.* 2005;21:77-89. <https://doi.org/10.1016/j.cveq.2004.11.003>
14. Khafaga AF, Abu-Ahmed HM, El-Khamary AN, Elmehasseb IM, Shaheen HM. Enhancement of equid distal limb wounds healing by topical application of silver nanoparticles. *J Equine Vet Sci.* 2018;61:76-87. <https://doi.org/10.1016/j.jevs.2017.11.013>
15. Stashak TS, Farstvedt E, Othick A. Update on wound dressings: indications and best use. *Clin Tech Equine Pract.* 2004;3:148-63. <https://doi.org/10.1053/j.ctep.2004.08.006>
16. Dart AJ, Cries L, Jeffcott LB, Hodgson DR, Rose RJ. The effect of equine recombinant growth hormone on second intention wound healing in horses. *Vet Surg.* 2002;31:314-9. <https://doi.org/10.1053/jvet.2002.33589>
17. Tracey AK, Alcott CJ, Schleining JA, Safayi S, Zaback PC, Hostetter JM, et al. The effects of topical oxygen therapy on equine distal limb dermal wound healing. *Can Vet J.* 2014;55:1146-52.
18. Kelleher ME, Kilcoyne I, Dechant JE, Hummer E, Kass PH, Snyder JR. A preliminary study of silver sodium zirconium phosphate polyurethane foam wound dressing on wounds of the distal aspect of the forelimb in horses. *Vet Surg.* 2015;44:359-65. <https://doi.org/10.1111/j.1532-950X.2014.12240.x>
19. Steel CM, Robertson ID, Thomas J, Yovich JV. Effect of topical rh-TGF- $\beta$ 1 on second intention wound healing in horses. *Aust Vet J.* 1999;77:734-7. <https://doi.org/10.1111/j.1751->

- 0813.1999.tb12916.x
20. Bischofberger AS, Tsang AS, Horadagoda N, Dart CM, Perkins NR, Jeffcott LB, et al. Effect of activated protein C in second intention healing of equine distal limb wounds: a preliminary study. *Aust Vet J.* 2015;93:361-6. <https://doi.org/10.1111/avj.12363>
  21. Anis A, Sharshar A, Hanbally SE, Sadek Y. A novel organic composite accelerates wound healing: experimental and clinical study in equine. *J Equine Vet Sci.* 2021;99:103406. <https://doi.org/10.1016/j.jevs.2021.103406>
  22. Jacobsen S. Topical wound treatments and wound-care products. In: Theoret C, Schumacher J, editors. *Equine wound management.* 3rd ed. Ames, IA: John Wiley & Sons; 2016. p. 75-103.
  23. Davidson JR. Current concepts in wound management and wound healing products. *Vet Clin North Am Small Anim Pract.* 2015;45:537-64. <https://doi.org/10.1016/j.cvsm.2015.01.009>
  24. Biswas A, Bharara M, Hurst C, Gruessner R, Armstrong D, Rilo H. Use of sugar on the healing of diabetic ulcers: a review. *J Diabetes Sci Technol.* 2010;4:1139-45. <https://doi.org/10.1177/193229681000400512>
  25. Salgado RM, Cruz-Castañeda O, Elizondo-Vázquez F, Pat L, De la Garza A, Cano-Colín S, et al. Maltodextrin/ascorbic acid stimulates wound closure by increasing collagen turnover and TGF- $\beta$ 1 expression in vitro and changing the stage of inflammation from chronic to acute in vivo. *J Tissue Viability.* 2017;26:131-7. <https://doi.org/10.1016/j.jtv.2017.01.004>
  26. Howard DJ, Anderson SL, Nahar VK. A preliminary study on second-intention healing of full-thickness wounds on equine distal forelimbs treated with maltodextrin. *J Equine Vet Sci.* 2019;74:90-4. <https://doi.org/10.1016/j.jevs.2018.12.018>
  27. Hartzell LD, Havens TN, Odom BH, Stillman TG, Boswell JL, Bower CM, et al. Enhanced tracheostomy wound healing using maltodextrin and silver alginate compounds in pediatrics: a pilot study. *Respir Care.* 2014;59:1857-62. <https://doi.org/10.4187/respcare.02822>
  28. Swaim SF. Initial wound management of contaminated and infected wounds. In: Swaim SF, Welch J, Gillette RL, editors. *Management of small animal distal limb injuries.* Jackson, WY: Teton NewMedia; 2015. p. 19-37.
  29. Krahwinkel DJ, Boothe HW Jr. Topical and systemic medications for wounds. *Vet Clin North Am Small Anim Pract.* 2006;36:739-57. <https://doi.org/10.1016/j.cvsm.2006.04.001>
  30. McFadden EA. Multidex gel for use in wound care. *J Pediatr Nurs.* 1997;12:125. [https://doi.org/10.1016/s0882-5963\(97\)80037-1](https://doi.org/10.1016/s0882-5963(97)80037-1)
  31. Pavletic MM. Topical wound care products and their use. In: Pavletic MM, editor. *Atlas of small animal wound management and reconstructive surgery.* 4th ed. Hoboken:Wiley Blackwell.; 2018. p. 53-93.
  32. MacPhail C, Fossum TW. Surgery of the integumentary system. In: Fossum TW, editor. *Small animal surgery.* 5th ed. St. Louis, MO: Mosby; 2018. p. 187.
  33. Purna SK, Babu M. Collagen based dressings — a review. *Burns.* 2000;26:54-62. [https://doi.org/10.1016/s0305-4179\(99\)00103-5](https://doi.org/10.1016/s0305-4179(99)00103-5)
  34. Clarke KW, Trim CM, Hall LW. Anaesthesia of the horse. In: Clarke KW, Trim CM, Hall LW, editors. *Veterinary anaesthesia.* 11th ed. Philadelphia, PA: W.B. Saunders; 2014. p. 248.
  35. Schindelin J, Arganda-Carreras I, Frise E, Kaynig V, Longair M, Pietzsch T, et al. Fiji: an open-source platform for biological-image analysis. *Nat Methods.* 2012;9:676-82. <https://doi.org/10.1038/nmeth.2019>
  36. Chang AC, Dearman B, Greenwood JE. A comparison of wound area measurement techniques: visitrak versus photography. *Eplasty.* 2011;11:e18.
  37. Bohling MW, Henderson RA, Swaim SF, Kincaid SA, Wright JC. Comparison of the role of the subcutaneous tissues in cutaneous wound healing in the dog and cat. *Vet Surg.* 2006;35:3-

14. <https://doi.org/10.1111/j.1532-950X.2005.00105.x>
38. Theoret C. hysiology of wound healing. In: Theoret C, Schumacher J, editors. Equine wound management. 3rd ed. Ames, IA: John Wiley & Sons; 2016. p. 1-13.
39. Jacobs KA, Leach DH, Fretz PB, Townsend HGG. Comparative aspects of the healing of excisional wounds on the leg and body of horses. *Vet Surg.* 1984;13:83-90. <https://doi.org/10.1111/j.1532-950X.1984.tb00765.x>
40. Wilmink JM, Stolk PWT, van Weeren PR, Barneveld A. Differences in second-intention wound healing between horses and ponies: macroscopic aspects. *Equine Vet J.* 1999;31:53-60. <https://doi.org/10.1111/j.2042-3306.1999.tb03791.x>
41. Bertone AL. Principles of wound healing. *Vet Clin North Am Equine Pract.* 1989;5:449-63. [https://doi.org/10.1016/S0749-0739\(17\)30568-0](https://doi.org/10.1016/S0749-0739(17)30568-0)
42. Hogge J, Krasner D, Nguyen H, Harkless LB, Armstrong DG. The potential benefits of advanced therapeutic modalities in the treatment of diabetic foot wounds. *J Am Podiatr Med Assoc.* 2000;90:57-65. <https://doi.org/10.7547/87507315-90-2-57>
43. White GW. Maltodextran, NF powder: a new concept in equine wound healing. *J Equine Vet Sci.* 1995;15:296-8. [https://doi.org/10.1016/S0737-0806\(06\)81725-9](https://doi.org/10.1016/S0737-0806(06)81725-9)
44. Hanson RR. Complications of equine wound management and dermatologic surgery. *Vet Clin North Am Equine Pract.* 2008;24:663-96. <https://doi.org/10.1016/j.cveq.2008.10.005>
45. Frees KE. Equine practice on wound management: wound cleansing and hygiene. *Vet Clin North Am Equine Pract.* 2018;34:473-84. <https://doi.org/10.1016/j.cveq.2018.07.004>
46. Sibbald RG, Williamson D, Orsted HL, Campbell K, Keast D, Krasner D, et al. Preparing the wound bed-debridement, bacterial balance, and moisture balance. *Ostomy Wound Manage.* 2000;46:14-22, 24-8, 30-5; quiz 36-7.
47. White RJ, Cutting K, Kingsley A. Topical antimicrobials in the control of wound bioburden. *Ostomy Wound Manag.* 2006;52:26-58.
48. Fernandez R, Griffiths R. Water for wound cleansing. *Cochrane Database Syst Rev.* 2012;CD003861. <https://doi.org/10.1002/14651858.CD003861.pub3>
49. Sanchez IR, Swaim SF, Nusbaum KE, Hale AS, Henderson RA, McGuire JA. Effects of chlorhexidine diacetate and povidone-iodine on wound healing in dogs. *Vet Surg.* 1988;17:291-5. <https://doi.org/10.1111/j.1532-950x.1988.tb01019.x>
50. Mohamed Amin Z, Koh SP, Yeap SK, Abdul Hamid NS, Tan CP, Long K. Efficacy study of broken rice maltodextrin in in vitro wound healing assay. *Biomed Res Int.* 2015;2015:687694. <https://doi.org/10.1155/2015/687694>
51. Hanson RR, Schumacher J. Degloving injuries of the distal aspect of the limb. In: Theoret C, Schumacher J, editors. Equine wound management. 3rd ed. Ames, IA: John Wiley & Sons; 2016. p. 352-68.
52. Fahie MA, Shettko D. Evidence-based wound management: a systematic review of therapeutic agents to enhance granulation and epithelialization. *Vet Clin North Am Small Anim Pract.* 2007;37:559-77. <https://doi.org/10.1016/j.cvsm.2007.02.001>