



## Case Report

# Leg Amputation due to Buerger's Disease: Management with Combined Korean Medicine



Eun Sol Won, Hyun Lee, Hwa Yeon Ryu, Yong Ho Ku, Ga Hyeon Jung, Chae Hyun Park, Jae Hui Kang \*

Department of Acupuncture and Moxibustion Medicine, College of Korean Medicine, Daejeon University, Cheonan, Korea

## ABSTRACT

### Article history:

Submitted: July 12, 2021  
Revised: October 05, 2021  
Accepted: October 14, 2021

### Keywords:

amputation, Berger's disease, Korean traditional medicine, prostheses

In this Case Report, a patient with Buerger's disease who had a leg amputation below his lower right knee and a vascular bypass of right leg, developed a wound caused by his prosthetic leg and subjective discomfort. The patient received skin flap surgery but the wound did not heal properly. He was admitted to the Korean Medicine Hospital where his wound, right leg coldness, and phantom pain were treated with combined Korean medicine. The patient was hospitalized again where he underwent micro-drilling surgery. The patient was re-admitted to the Korean Medicine Hospital where he received combined Korean medicine treatment (CKMT) and carbon arc light treatment (CALT) for his wound, leg coldness, stiffness, and hypoplasia. The temperature of his right leg increased, the numeric rating scale score for assessing pain fell from 5 to 1.5, and subjective discomfort was reduced (< 20%) suggesting this may be an effective treatment.

<https://doi.org/10.13045/jar.2021.00150>  
pISSN 2586-288X eISSN 2586-2898

©2021 Korean Acupuncture & Moxibustion Medicine Society. This is an open access article under the CC BY-NC-ND license (<http://creativecommons.org/licenses/by-nc-nd/4.0/>).

## Introduction

Buerger's disease, also known as thromboangiitis obliterans, was first described by Buerger in 1908, and was reviewed recently [1]. It is a non-lethal atherosclerotic and fractional inflammatory disease that usually occurs in small and medium arteries and veins of the extremities [2]. An amputation can be performed if ischemic ulcers develop and progress to gangrene. The risk of amputation rises gradually over 5 years, to 38% over 10 years, and to 56% over 20 years. Amputation can cause coldness, phantom pain, numbness, stiffness, and hypoesthesia for the amputated leg [3]. There is research on the primary treatment of Burger's disease, but little research has been performed on the management of symptoms post-amputation, and how to treat wounds created around the amputated area due to prosthetics. A case report following amputation of a limb affected by Buerger's disease was reported in the Korean traditional medicine field [4] where claudication was addressed but not coldness, phantom pain, numbness, stiffness, and hypoesthesia. This current study used carbon arc light

treatment (CALT) with combined Korean medicine treatment (CKMT) which demonstrated a beneficial effect on coldness and other discomforts in a patient with an amputated limb.

## Case Report

### Patient

OOO (M/59)

### Chief complaint

Phantom pain, coldness, numbness, stiffness, and hypoesthesia.

### Medical history

He had been smoking for approximately 20 years, stopped smoking for approximately 1 year in 2020, and then started smoking again in January 2021. No disease history relevant for blood clotting conditions. No diabetes. No autoimmune disease.

\*Corresponding author. Jae Hui Kang

Department of Acupuncture and Moxibustion Medicine, College of Korean Medicine, 4, Notaesan-ro, Seobuk-gu, Cheonan, Chungcheongnam, 331-958, Korea  
E-mail: [rkd12@hanmail.net](mailto:rkd12@hanmail.net)

ORCID: Eun Sol Won <https://orcid.org/0000-0002-0335-0976>, Hyun Lee <https://orcid.org/0000-0002-5160-7000>, Hwa Yeon Ryu <https://orcid.org/0000-0002-9468-1227>, Yong Ho Ku <https://orcid.org/0000-0001-7553-4144>, Ga Hyeon Jung <https://orcid.org/0000-0002-7759-0972>, Chae Hyun Park <https://orcid.org/0000-0001-5672-9026>, Jae Hui Kang <https://orcid.org/0000-0003-4812-0557>

©2021 Korean Acupuncture & Moxibustion Medicine Society. This is an open access article under the CC BY-NC-ND license (<http://creativecommons.org/licenses/by-nc-nd/4.0/>).

**Family history**

None

**Western medications**

Anpl-one sustained release tablet 300 mg (B/pc, sarpogrelate HCl 300 mg)

Aspirin protect tablet 100 mg (B/pc, aspirin enteric coated 100 mg)

Vastinan modified release tablet (B, D/pc, trimetazidine 2HCl 35 mg)

Trental tablet 400 mg (B, D/pc, pentoxifylline 400 mg)

Bisibe tablet 10/20 mg (B, D/pc, ezetimibe 10 mg S imvastatin 20 mg)

Gliatamin tablet (B, L, D/pc, choline alfoscerate 400 mg)

Esomezol capsule 20 mg (B/pc, esomeprazole strontium tetrahydrate 24.6 mg)

Sodium fusidate ointment greencross (p.r.n, sodium fusidate)

**Present illness**

Necrosis occurred after being stamped on the back of the foot in December 2019 after which the patient underwent lower right knee amputation and vascular bypass of right leg at Soonchunhyang university hospital. By April 2020, the patient had undergone right knee rehabilitation treatment at the local hospital rehabilitation medicine department. The patient experienced right leg coldness, stiffness, and hypoesthesia. In July 2020, while walking on the prosthetic leg, an open wound measuring 2 cm occurred due to skin abrasions. Since then, he received skin flap surgery at Soonchunhyang university hospital. However, the open wound remained unchanged. From February 5, 2021, to March 21, 2021, the patient was hospitalized in the Korean Medicine Hospital. After

the patient was discharged, he underwent micro-drilling surgery at Soonchunhyang University Hospital and was hospitalized again. After treatment from March 29, 2021, to April 27, 2021, the patient improved significantly, the wound healed, and he was discharged.

**Duration of treatment**

The 1<sup>st</sup> hospitalization period was for 44 days, between February 5 and March 3, 2021. The 2<sup>nd</sup> hospitalization period was for 29 days between March 21 - April 27, 2021.

**Treatments**

**Acupuncture**

The acupuncture points were ST32, ST33, ST34, ST35, SP10, LR9, GB31, GB32, GB33, Ex-LE2. It was performed with 0.25 × 30 mm stainless steel (Eastern acupuncture equipment manufacturer, Boryong, Korea). Acupuncture was performed about 2 cm away from wound. It was performed with pharmacopuncture and electroacupuncture. Electroacupuncture STN-110 (Stratek, Seoul, Korea) was performed once daily for 15 minutes, at a stimulation frequency of 3 Hz.

**Pharmacopuncture**

Pharmacopuncture (Korean Pharmacopuncture Institute, Seoul, Korea) was performed only during the first hospitalization. Hominis placenta pharmacopuncture was mainly used for this treatment. The acupoints ST34, ST33, ST32, SP10, and muscles and ligaments around the amputated area were selected, and 1.0 mL disposable syringes and needles (Jungrim Medical, Seoul, Korea, 30 G × 12.7 mm needle) were used. Doses of 0.05-0.3 mL were injected into the knee wound periphery, and the total dose injected was 1.0 mL.

**Herbal medicine**

Two herbal medicines were used, Bojungkitang soft extract during the 1<sup>st</sup> hospitalization and Palmultang soft extract during the 2<sup>nd</sup> hospitalization (Table 2).

**Physiotherapy**

Interferential current therapy and hot pack treatment were administered to the quadriceps femoris to improve peripheral blood circulation and soften the stiffness of the amputated area.

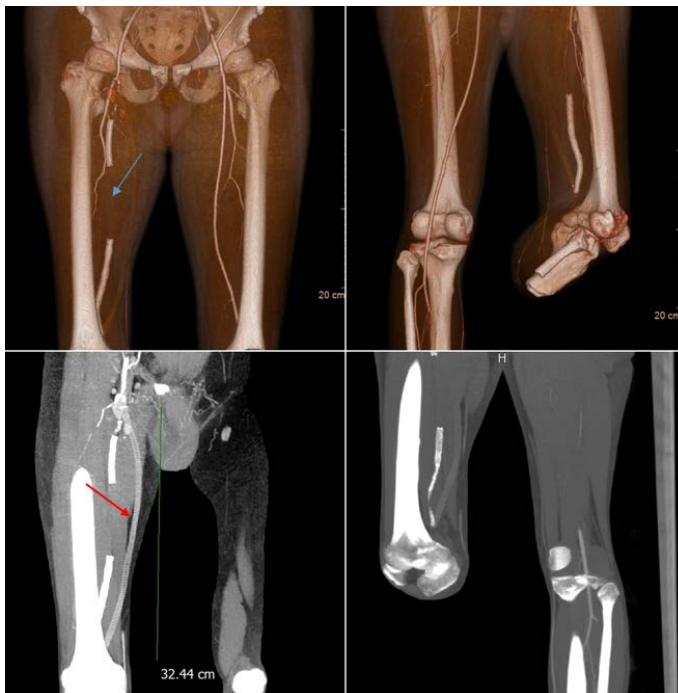


Fig. 1. Lower extremity angiogram of a varicose vein in 3D (three dimensional). The image shows a femoropopliteal vascular bypass of right leg (red arrow). A vascular bypass was performed using blood vessel prosthesis. It was about 32.44 cm long. In the angiogram of the lower extremities, blood flow was cut off in the distal femoral artery of the right lower extremities (blue arrow).

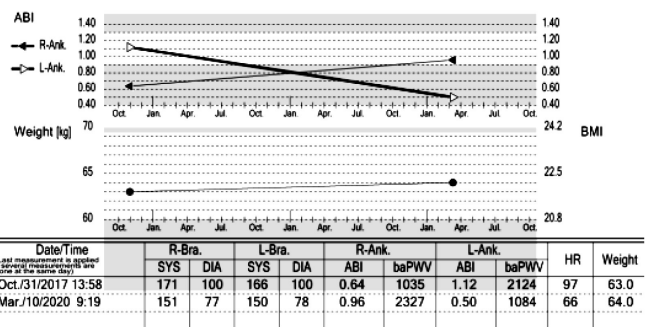


Fig. 2. Pulse wave diagnostic results. The image shows the ankle brachial index (ABI). On October 31, 2017, the ABI of the right ankle was 0.65 indicating severe peripheral artery occlusive disease and the left ABI was normal at 1.12. After right leg amputation, on March 10, 2020, the right ABI improved to 0.96, but the left ABI fell to 0.50.

**Moxibustion treatment**

Indirect electric moxibustion (Technoscience, Seoul, Korea) therapy was administered once daily at ST34, ST33, ST32, and SP10 to make the effect of temperature rise and blood flow smooth.

**CALT**

CALT (Hyumedi, Seoul, Korea) was performed daily. It was applied to the amputated area at 10:00 AM for about 15 minutes at a distance of about 35 cm. CALT was performed completely in the first hospitalization and only half the treatment was performed in the 2<sup>nd</sup> hospitalization.

**Evaluation**

**Digital infrared thermal imaging**

On the day of the test, the accuracy of the test was ensured by excluding various external factors such as preventing the attachment of aids, accessories, and patches that could irritate the patient's skin. The digital infrared thermal imaging (DITI; OsongLife, Bucheon, Korea) test was conducted in an environment where light and heat were blocked from the outside. Humidity was 60-65% and the temperature was 21-23°C. The patient stood in the examination room for approximately 15 minutes, adjusted to room temperature, and was photographed using an infrared body heat diagnostic device (Fig. 3). DITI of right leg was measured every week in the 1<sup>st</sup> hospitalization period.

**Numeric rating scale**

The patient's pain was assessed daily using the numeric rating scale (NRS). A score of 0 indicated no pain, and 10 indicated the

most severe pain. The patient usually complained of night pain and had phantom pain with his legs moving uncontrollably. After the treatment, the patient said the amputated area had become softer and he felt little phantom pain. The symptoms of legs moving independently decreased from 2-3 times at admission to 0 at discharge (Fig. 4).

**Open wound photographs**

To record the wound healing, pictures of the wound around the knee were taken periodically. The image shows the healing process of the wound (Fig. 5).

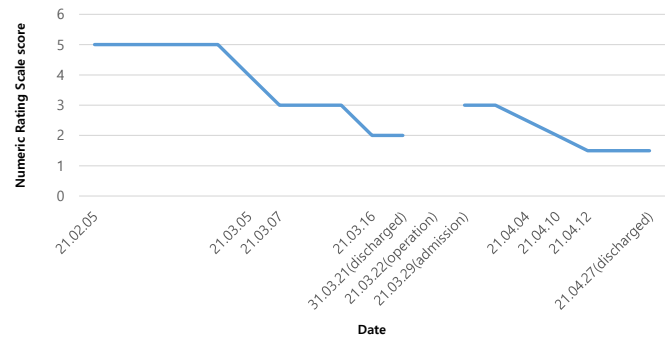


Fig. 4. Changes in the NRS score for pain. The NRS score remained similar until March 5<sup>th</sup>, then decreased significantly between March 5<sup>th</sup> and 7<sup>th</sup>. NRS score improved once again around March 16<sup>th</sup>; when discharged and re-admitted, March 29<sup>th</sup>, the NRS score had increased slightly to approximately 3. However, after steady treatment, the NRS score dropped to 1.5 by the time of discharge, April 29<sup>th</sup>.

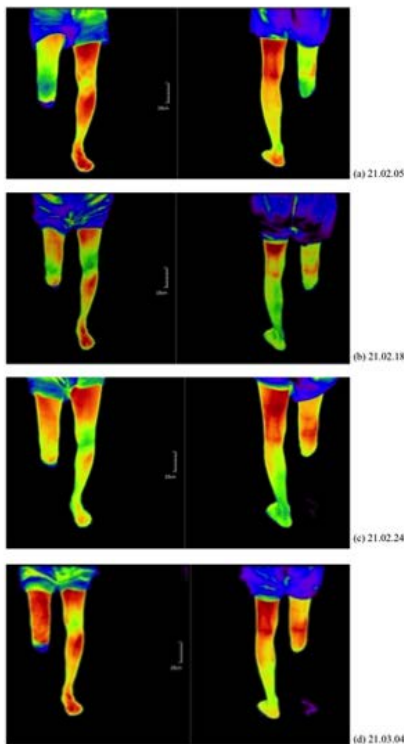


Fig. 3. DITI of the improvement in temperature of the right amputated knee over the treatment period (February 5<sup>th</sup>, February 18<sup>th</sup>, February 24<sup>th</sup>, March 4<sup>th</sup> 2021).

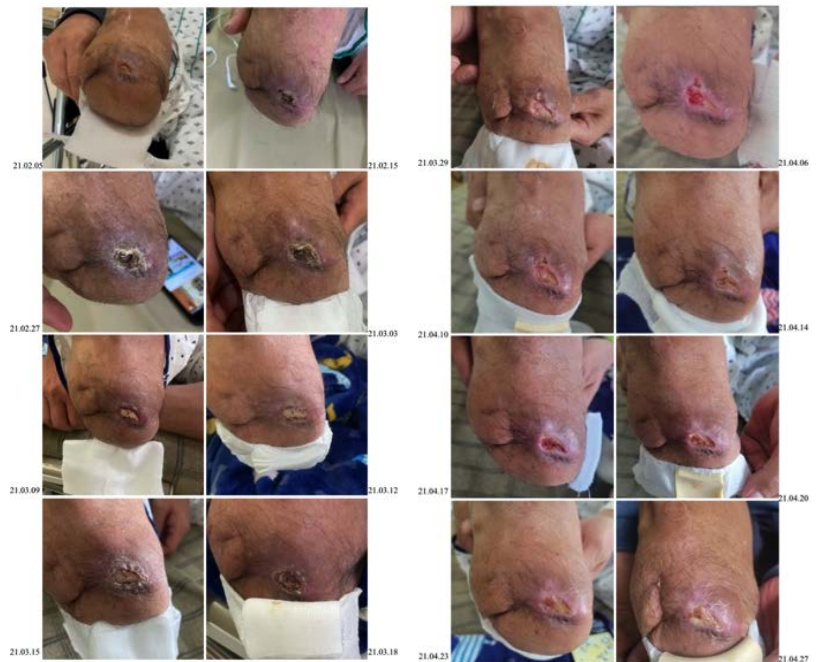

Fig. 5. The wound healing process.

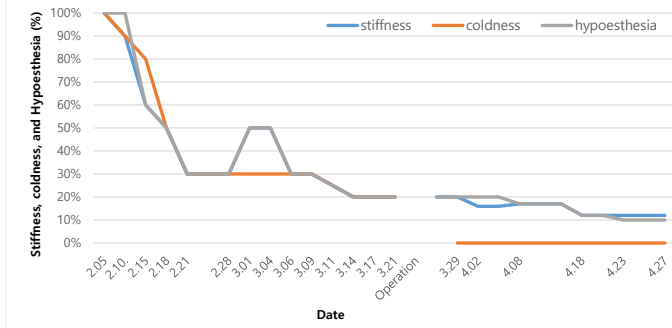


Fig. 6. Subjective evaluation of the patient during the 1st hospitalization. Subjective assessments of the patient were recorded in the electronic medical records system. Stiffness and coldness declined equally. The patient complained of 16% stiffness and 10% hypoesthesia at discharge. In the 1<sup>st</sup> hospitalization, the patient complained of 20% coldness at discharge, but did not complain of coldness at the 2<sup>nd</sup> hospitalization because the patient underwent surgery.

### Subjective state of the patient

On day 1 of hospitalization, the patient complained of hyperesthesia, stiffness, numbness, coldness, and sensory degradation. On day 11, and day 35 of hospitalization, his discomfort remained approximately 60% and 30%, respectively. On April 27, 2021, the pain remained approximately 10%. His senses were approximately 90% normal throughout the day (Fig. 6).

## Discussion

When Buerger's disease worsens, the leg frequently feels cold and painful, and if it gets worse, amputation may be necessary. In this case report, a patient with Berger's disease, post-amputation, complained of discomfort and wounds from wearing a medical prosthetic device. However, following CKMT with CALT, the right leg temperature increased not only according to the patient but also as measured by DITI. This device detects temperature and shows the distribution of heat on the body's surface [5] (Fig. 3). The patient experienced pain relief as observed using the NRS; the score was 5 at the time of admission and 1.5 at discharge (Fig. 4). At admission, subjective symptoms stiffness, hypoesthesia, and coldness declined from 100% to 16%, 10%, and 0%, respectively, at discharge (Fig. 6). In addition, the patient said that the muscle around his knee was very soft and the night pain had improved a lot.

The patient's discomfort and wound were treated with CKMT (Table 1). Acupuncture can increase temperature and blood flow [6], it can control local pain and act downstream on inhibition systems such as serotonin, and serotonin [7]. Seo et al [7] used LI1, LI2, LI3, HT8, PC8, PC7, LU9 acupoints for phantom limb pain after amputation, and Kang [4] used LI11, SP6, GB34, BL60, SP3, KI6, BL62 acupoints for toe amputation due to Buerger's disease. In this current case, acupoints were also selected around wounds and muscles for a healing effect which would have anti-inflammatory effects on the joints and nerves [4,8]. Hominis placenta pharmacopuncture was also used because it has a wound

Table 1. Treatment Intervention.

Intervention	Category	Details
Sterilization	No. times	Once a day at 5 AM
	Ingredient	Saline, povidone (Dongindang, Seoul, Korea), ointment (Greencross, Seoul, Korea, Sodium fusidate 20 mg), hydrogel dressing (Genewell, Hwaseong, Korea), band, superfix (BANDGOLD, Anyang, Korea)
	Method	Apply phobidone first and saline 1 min later. Third, apply ointment. After attaching the hydrogel dressing, fix it with Superfix.
Needling details	point used	ST32, ST33, ST34, ST35, SP10, LR9, GB31, GB32, GB33, Ex-LE2 and Ashi-point
	No. needles	Approximately 15
	Distance to the wound	1-2 cm away from the wound
	Depths of insertion	0.3-0.5 cm on acupoints
CALT	Combination	Electro-acupuncture, pharmacopuncture
	Region to be treated	Amputated leg (the area above the knee)
	Duration	15 min
	No. times	Once a day at 10 AM
	Distance to region	Approximately 35 cm
	Period	50 d

CALT, carbon arc light treatments.

Table 2. Composition of Herbal Medicine.

Jungwoo Bojungkitang soft extract 2021.02.05-2021.03.21		Hanshin Palmultang soft extract 2021.03.29-2021.04.27	
Scientific name	g	Scientific name	g
Glycyrrhizae Radix	0.43	Cnidii Rhizoma	0.524
Astragali Radix	0.61	Ginseng Radix	0.627
Ginseng Radix	0.29	Atractylodes macrocephala Koidz	0.59
Atractylodis Rhizoma Alba	0.57	Wolfiporiae Radix	0.046
Angelicae gigantis Radix	0.24	Glycyrrhizae Radix	0.484
Citri Pericarpium	0.33	Rehmanniae Radix	0.732
Cimicifugae Rhizoma	0.07	Paeoniae Radix Alba	0.556
Bupleuri Radix	0.11	Angelica Gigantis Radix	0.537

healing effect [9]. Of note, there was no symptoms of infection when acupuncture and pharmacopuncture are performed on the amputated area.

Bojungkitang and Palmultang soft extracts for the 1<sup>st</sup> and 2<sup>nd</sup> admissions, respectively, were used for improving various symptoms of discomfort and wound healing, in another case report, Palmulgunjatang (other forms of Palmultang) was prescribed for Raynaud due to Buerger's disease [10]. It was also reported that Bojungkitang increased the proliferation response of T cells [11]. Palmultang was also used to rid diseases in the gi and the blood in some studies [12,13].

There have also been cases of CKMT for Buerger's disease with Raynaud phenomenon and claudication, ulcer and other symptoms. [10,14,15]. However, there is a lack of studies on post-amputation in patients with Berger's disease. This study showed that discomfort and pain from a wound after amputation was successfully reduced by CKMT. Furthermore, this current study used CALT which had a great effect on sensations of coldness and other discomfort in patient.

CALT has been widely used in the treatment of bedsores, but it is the first time this treatment has been used for symptoms due to amputation in Buerger's disease. In CKMT, CALT corresponds to Jeonggyeongrak therapy and acts to promote metabolism [16]. CALT has similarities to western medicine laser therapy, but it is not widely used in CKMT.

CALT appears to be an effective treatment post-amputation in Berger's disease but may be effective in the treatment of other types of wounds. The limitation of this study is that only 1 case was investigated, and no treatment was used in isolation so the individual effect of a particular treatment cannot be ascertained. The length of the hospitalization treatment was long, so improvements may be due to the period of time post-surgery but this was due to micro-drilling surgery for the skin flap. Without a large number of patients and a control group, further studies are necessary to determine the effects of CKMT with CALT. However, the study is a rare case of a patient who underwent amputation due to Buerger's disease had CKMT with CALT to treat phantom pain,

coldness, numbness, stiffness, hypoesthesia, and a wound caused by a prosthetic, and recovered successfully. This case suggests that CKMT with CALT are effective for post-amputation treatment of Buerger's disease.

### Conflicts of Interest

The authors have no conflicts of interest to declare.

### Acknowledgments

The report is an independent from the sponsor and competing interest.

### Ethical Statement

This research did not involve any human or animal experiment.

### References

- [1] Rivera-Chavarria IJ, Brenes-Gutiérrez JD. Thromboangiitis obliterans (Buerger's disease). *Ann Med Surg* 2016;29:79-82.
- [2] Buerger L. Landmark publication from the American Journal of the Medical Sciences, 'Thrombo-angiitis obliterans: a study of the vascular lesions leading to presenile spontaneous gangrene'. 1908. *Am J Med Sci* 2009;337:274-284.
- [3] Göçen U, Atalay A, Deniz LM. Successful multidisciplinary treatment in a case of Buerger. *J Cardiovasc Dis Res* 2013;4:198-200.
- [4] Kang AR, Hyun SH, Woo JM, Kim YS, Cho KH, Moon SK et al. A Case Study of a Thromboangiitis Obliterans (Buerger's Disease) Patient with Lower Extremity Pain and Claudication Treated by Traditional Korean Medicine. *J Int Korean Med* 2014;35:271-275.
- [5] Cheon MN, Lee KM. Classification of Herniated Nucleus Pulposus and Results of DITI. *J Acupunct Res* 1996;13:283-291. [in Korean].
- [6] Changes of Facial Temperature and Blood Flow Rates by Treatment of Miso Facial Rejuvenation Acupuncture. *J Physiol Pathol Korean Med* 2013;27:481-486. [in Korean].
- [7] Barlas P, Lundeberg T. Transcutaneous electrical nerve stimulation and acupuncture. In: Melzack and Wall's Textbook of Pain (eds McMahon SB, Koltzenburg M), 5th ed. London (UK): Elsevier Churchill Livingstone;

2006. p. 583-590.
- [8] Seo H, Bae G, Choi J, Seo H, Shim S, Han C et al. A Case Report on a Phantom Limb Pain Patient after Below Knee Amputation using Korean Medicine Treatment. *J Int Korean Med* 2018;39:1306-1312. [in Korean].
- [9] Park JY, Lee JY, Jeong MS, Min SR. Effect of Hominis Placenta on cutaneous wound healing in normal and diabetic mice. *Nutr Res Pract* 2014;8:404-409. [in Korean].
- [10] Lee HJ, Lee BY, Lee YE, Yang SB, Cho SY, Park JM et al. Phenomenon due to Buerger's Disease: A Case Report. *J Int Korean Med* 2015;36:427-435. [in Korean].
- [11] Chae SY, Shin SH, Ha MH, Cho SK, Kim SH, Byun BW et al. Effect of Bu - Zhong - Yi - Qi - Tang on Proliferation of T Cells. *Korean Food Nutr Sci J* 2004;33:1085-1091. [in Korean].
- [12] Heo MK, Hong HY, Kam CW, Park DI. Experimental Study on the Anti-allergic Effects of Pamul-tang. *J Physiol Pathol Korean Med* 2003;17:1075-1081. [in Korean].
- [13] Oh JJ, Won JH, Lee EJ, Moon SJ. Effects of Paljintanggagambang extract on antitumoral immunological response and the side effect induced by antitumoral Agents. *J Intern Korean Med* 1998;19:219-232. [in Korean].
- [14] Eom JY, Chae JS, Ko TH, Son SS, Choi IS. Case of Ulcer resulting from Buerger's disease Improve by Acupuncture Therapy. *J Acupunct Res* 2004;21:263-268. [in Korean].
- [15] Ock MK, Park SE, Kim CH, Lim WK. A Case Report of Thromboangitis Obliterans. *J Korean Med Ophthalmol Otolaryngol Dermatol* 2005;18:108-113.
- [16] Lim HW, Yoon CH, Kim JH. A Case of Decubitus Ulcer Treated with CALT-Arc-Light Treatment. *J Stroke* 2006;7:83-87. [in Korean].

### Appendix A. Timeline of order according to hospitalization.

