



Case Report

Thread Embedding Acupuncture and Complex Korean Medicine Treatment for Lumbar Spinal Stenosis with Degenerative Scoliosis: A Clinical Case Report



Yu-Kyeong Park, Jung Hee Lee, Jae Soo Kim, Yun Kyu Lee, Hyun-Jong Lee *

Department of Acupuncture and Moxibustion, College of Korean Medicine, Daegu Haany University, Daegu, Korea

ABSTRACT

Article history:

Submitted: June 25, 2021

Revised: August 16, 2021

Accepted: September 09, 2021

Keywords:

case report, herbal medicine, acupuncture, conservative treatment, Korean traditional medicine, lumbar region, spinal stenosis

Lumbar spinal stenosis (LSS) is a common degenerative spinal condition that can have unpredictable improvement and worsening of symptoms which include low back pain, radiating pain, claudication, and degenerative lumbar scoliosis affecting quality of life. In this study, thread embedding acupuncture (TEA) was used as a conservative treatment for LSS in combination with complex Korean medicine treatments (acupuncture, herbal medicines, and physical therapy). The treatment was evaluated using the numerical rating scale, walking distance and duration, and inclination of radiological lumbar scoliosis according to antalgic posture. TEA was performed 27 times between June 8, 2020, and March 16, 2021. The patient showed improvement in numerical rating scale score from 7 to 2, pain-free walking distance from 10 m to 900 m, and scoliosis inclination following treatment. The findings of this study suggest that TEA may be helpful in the treatment of LSS.

<https://doi.org/10.13045/jar.2021.00108>
pISSN 2586-288X eISSN 2586-2898

©2021 Korean Acupuncture & Moxibustion Medicine Society. This is an open access article under the CC BY-NC-ND license (<http://creativecommons.org/licenses/by-nc-nd/4.0/>).

Introduction

Lumbar spinal stenosis (LSS) is a condition caused by compression of the dural sac or nerve root due to a decrease in the size of the spinal canal which is in the spinal nerve channel [1-2]. The symptoms of LSS are diverse, including low back pain, radiating pain, claudication, and degenerative lumbar scoliosis [1]. LSS shows a stable pattern in 50% of patients, but in 25% of patients, there is a repeated unpredictable improvement and worsening of symptoms [2]. This condition is emerging as a social problem of the modern era in an aging society because the morbidity rate increases as the elderly age and the condition progresses gradually [3].

Conservative treatment of LSS may be offered (drug therapy, physical therapy, injection therapy), or surgical therapy, such as decompression laminectomy, can be considered [2]. With the exception of severe spinal canal stenosis, there is no clear

evidence that surgical therapy is more beneficial than continuous conservative therapy [4]. The choice of treatment varies depending on the severity and location of the stenosis, and the severity of symptoms. Therefore, a minimally invasive treatment method should be used first in cases of mild or moderate LSS [5]. Acupuncture [6], pharmacopuncture [7], and acupotomy [8] are used as conservative methods of Korean medicine treatment. Based on the results of a recent study that showed asymmetry in surface electromyography in patients with low back pain [9], thread embedding acupuncture (TEA), is thought to reduce pain by strengthening the muscles around the weakened lumbar spine [10]. Although there are studies on the effectiveness of TEA for chronic low back pain [10] and widespread disc herniation [11] as a single condition, few case studies have focused on the improvement of degenerative lumbar scoliosis and antalgic posture resulting from TEA.

*Corresponding author. Hyun-Jong Lee

Department of Acupuncture and Moxibustion, College of Korean Medicine, Daegu Haany University, 136, Sincheondong-ro, Suseong-gu, Daegu, Korea

Email: whiteyou@hanmail.net

ORCID: Yu-Kyeong Park <https://orcid.org/0000-0003-0087-953X>, Jung Hee Lee <https://orcid.org/0000-0002-2771-659X>, Jae Soo Kim <https://orcid.org/0000-0003-4101-8058>,

Yun Kyu Lee <https://orcid.org/0000-0001-8806-9501>, Hyun-Jong Lee <https://orcid.org/0000-0003-0779-8433>

©2021 Korean Acupuncture & Moxibustion Medicine Society. This is an open access article under the CC BY-NC-ND license (<http://creativecommons.org/licenses/by-nc-nd/4.0/>).

Case Report

Case presentation

The patient was diagnosed with LSS on lumbar spine magnetic resonance imaging (MRI), and presented with low back pain, radiating pain, claudication, and degenerative lumbar scoliosis. She did not have non-vertebral and soft tissue lesions that could cause low back pain or lower extremity pain and did not undergo surgery due to lumbar disc herniation. This study was conducted with the approval of review exemption from the institutional review board of the Daegu Haany University Korean Medicine Hospital (IRB no.: DHUMC-D-21a004-ETC-01).

Chief complaints

Low back pain
Left lower extremity radiating pain
Neurogenic claudication
Onset date
Early February 2020

Present illness

This patient suffered from low back pain, which repeatedly improved and worsened. In early February 2020, she suddenly worsened more than usual during her daily activities. She visited a local anesthesiology hospital for an examination. As a result of lumbar spine radiography and MRI scans, she was diagnosed with degenerative changes in the spine, spondylolisthesis at L4, and LSS at L4-5 and at L5-S1. Although she received injection therapy and analgesic medicines orally several times, her pain did not improve. She was hospitalized at the Daegu Haany University Korean Medicine Hospital on June 8, 2020.

Past medicine history

Osteoarthritis of both knees
Hyperlipidemia
Hypertension

Simple radiography images

Refer to Fig. 1.

MRI

Refer to Fig. 2.

Methods of treatment

TEA

The TEA was administered between June 8, 2020 and March 16, 2021 (the patient was hospitalized from June 8 to July 11, 2020 and received outpatient treatment thereafter). The TEA was performed once or twice a week (9 times) during hospitalization. During outpatient treatment, the patient visited the hospital for TEA once a week over 5 weeks, and then once a month (18 times). The TEA was performed 27 times in total.

A sterilized stainless-steel needle (Dongbang Medical, Bundang, Korea) was used. The TEA device was covered with a protective cap before use and comprised 4 parts: needle hub, needle, thread (polydioxanone suture thread), and sponge. The thread was absorbable when buried in the treatment areas. The needles were 27 gauge \times 40 mm, and 27 gauge \times 60 mm, and the thread length was 50 mm and 90 mm, respectively. Among the core muscle groups supporting the lumbar spine and pelvis, treatment was mainly applied to the painful side to reduce pain and scoliosis by strengthening the muscles [10-14]. Treatment was also performed

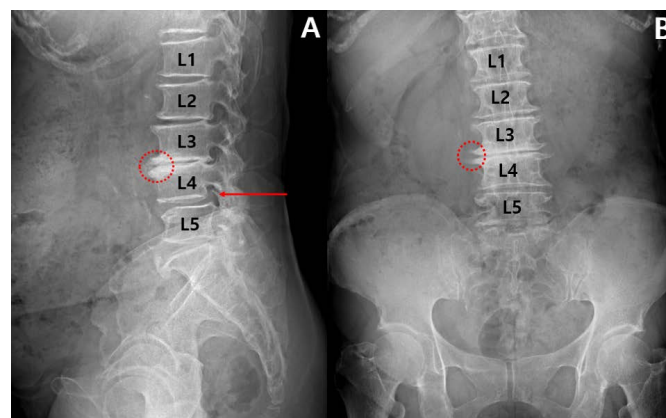


Fig. 1. Simple radiography image of the time of onset. (A) Sagittal view. (B) Coronal view. In the sagittal view image, the red arrow indicates a bone spur on the L4-5 level of the intervertebral foramen and it is because of degenerative changes, which causes stenosis of the L4-5 level. The red circle shows the endplate change on L3-4. In the coronal view image, the red circle shows a bone spur on the L3-4 vertebra. *The above images were read by a radiologist as lumbar scoliosis, disc space narrowing, L1-2-3-4-5-S1, degenerative spondylosis.

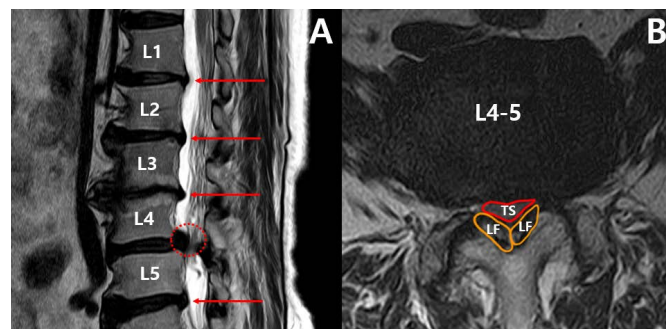
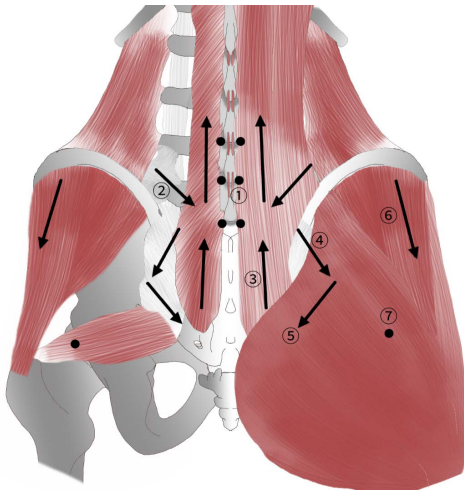


Fig. 2. L spine MRI of the patient at the time of onset. (A) Oblique view. (B) Axial view. In the oblique view image, the red arrows indicate the herniations of the discs and the red dot indicates the stenosis on the L4-5 level. In the axial view image of L4-5 level, the red solid line indicates compressed thecal sac, and the yellow solid lines indicate both ligamentum flavum thickened. TS, thecal sac; LF, ligamentum flavum.

on the other side of the lumbar spine and pelvis muscles to balance the muscle of the entire lumbar spine [14] (Fig. 3). After sterilizing the treatment site with povidone-iodine, the TEA needle was inserted toward the treatment sites. The tip of the needle was held according to the direction of insertion, the depth, and the shape of the muscle: perpendicular (90°), oblique (about 45°), and transverse (about 15°). When the needles were inserted into the treatment sites, the absorbable thread was internally buried in the areas that helped maintain the stability of the muscles until the thread was absorbed.

Other complex Korean medicine treatments

Acupuncture was performed on the day the patient did not receive TEA. During hospitalization, acupuncture was performed twice a day (morning and afternoon). During outpatient treatment, acupuncture was performed once a week on the day the patient did not receive TEA. For acupuncture, 0.20 \times 30 mm



	Muscle	Skeleton	Direction of insertion	Needle Length (mm)	No. of pieces inserted
①	Intrinsic muscle (Spinalis, rotatores)	L3-4, L4-5, L5-S1	Perpendicular	40	6
②	Multifidus muscle	L4-5	Oblique	60	2
③	Lumbar erector spinae	Sacrum-L5, L3-L1	Transverse	60	4
④	Iliolumbar ligament	L5-iliac crest	Oblique	60	2
⑤	Sacroiliac ligament	Posterior inferior iliac spine-coccyx	Oblique	60	2
⑥	Gluteus medius	-	Transverse	40	2
⑦	Piriformis	-	Perpendicular	60	2

Fig. 3. Thread embedding acupuncture treatment sites.

*This figure is a schematic diagram of the muscle, such as intrinsic muscle (spinalis, rotatores), multifidus muscle, lumbar erector spinae, iliolumbar ligament, sacroiliac ligament, gluteus medius, piriformis. It is marked with respect to the direction of thread embedding acupuncture (TEA) insertion. Black arrows represent oblique or transverse insertion, and black dots represent perpendicular insertion.

disposable sterilized needles made of stainless steel (Dongbang Medical, Ungcheon, Korea) were used and kept in place for 15 minutes. Acupuncture was performed by choosing the acupoints between BL23, BL25, BL40, BL24, BL52, BL57, BL60, GB30, GB34, and ST36, which are frequently used in LSS treatment [6-8]. During the hospitalization period, 3 packs of herbal medicines were taken orally each day (approximately 120 cc per pack) after meals, this treatment lasted for 34 days in total. For 14 days, Hwallagtang (mainly consisted of Chaenomelis fructus 10 g, Corydalis yanhusuo 8 g, Chelidonium Herba 8 g, Paeonia lactiflora 6 g, Cyperus rotundus 6 g, Angelica japonica 6 g, Aralia cordata 4 g per day) was used for relieving pain in the acute phase. After that, Gamiganghwalsogdantang (mainly consisted of Phlomis umbrosa Turcz. 12 g, Eucommia ulmoides 8 g, Glehnia littoralis 6 g, Angelica japonica 6 g, Rehmannia glutinosa 4 g, Achyranthes 4 g, Clematis florida 4 g per day) was used for 20 days, to control

pain and reinforce the lumbar spine. During the hospitalization period, analgesic medicine was administered orally whenever the pain was severe [more than numerical rating scale (NRS) score 7]. Traphen Tab (acetaminophen 325 mg, Tramadol hydrochloride 37.5 mg) was used to relieve worse pain. It was a medication the patient usually took at home whenever the pain worsened, and even though she was hospitalized, the pain was severe, so she carried on taking it. One dose was 1 tablet, and the daily dose did not exceed 3 tablets. Following 10 days after hospitalization, the patient stopped taking analgesic medicines because the pain had been relieved. During outpatient treatment, the patient stopped taking herbal medicines and analgesic medicine. Physical therapy including interferential current therapy and microwave therapy, dry cupping treatment, and percutaneous transdermal muscle thermotherapy (hot pack) were applied to the pain points in the lumbar region once a day after TEA or acupuncture during the hospitalization and outpatient treatment periods.

Evaluation criteria

NRS

The questionnaire using the NRS was recorded before and after the treatment. In the NRS, 0 represents the painless state and 10 the most severe pain, and the patient indicated their pain using the scale accordingly. The NRS measurements were obtained at each treatment.

Pain-free walking distance

To evaluate the degree of improvement in claudication, the distance that could be walked without pain was evaluated. This was used to measure and evaluate the linear distance from the start of gait to the start of lameness, or to the time when pain occurred. The measurements were made based on patient statements and were recorded at each treatment.

Scoliosis radiography

Degenerative scoliosis in this patient was due to deformation and curvature at the part of the 3rd and 4th lumbar vertebrae, resulting in degenerative changes such as spondylolisthesis, intervertebral disc degeneration, LSS, and antalgic posture. Therefore, radiographical examinations were performed to observe recovery from scoliosis resulting from the treatment. Radiology was performed 4 times during the treatment period (at hospitalization, at the discharge from the hospital, at the outpatient visitation, and at the end of treatment) to observe changes in scoliosis (Fig. 4). The curvature was also compared with the onset period.

Results

The patient showed improvement in NRS scores, pain-free walking distance, and scoliosis radiography. When she was first hospitalized, she needed to take analgesics before sleeping because of her fear of pain in the night. After 4 treatments and 10 days after hospitalization, she said, "It had become easier to bear the fear of pain," and she stopped taking analgesics at that time. At that point, she indicated an NRS score of 6. Earlier in the treatment, there were times when the pain was aggravated after the TEA, as it was accompanied by pain when the TEA needle was inserted. However, the pain caused by TEA was alleviated within a few hours, and after adapting to the procedure, the pain improved steadily. When she was discharged from the hospital, the NRS score was 4, and with no more pain or fear of pain in the night, she was satisfied. Upon hospitalization, she could walk 10 m without pain or claudication. After 7 treatments, 20 days after, she

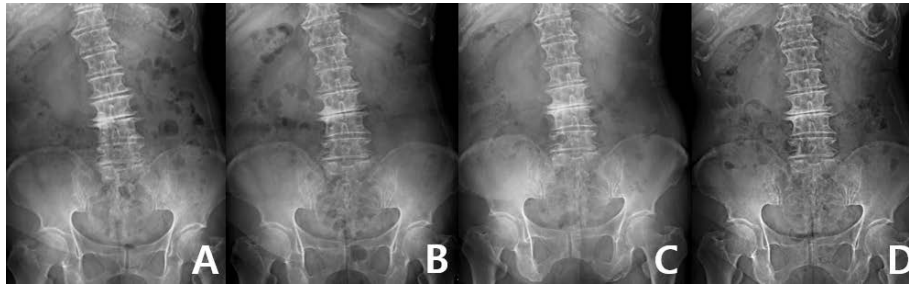


Fig. 4. The change of scoliosis observed on the radiographs. (A) Before treatment. (B-D) Progression during treatment. Before hospitalized treatment began, the inclination of the scoliosis was most steep. As the treatment progressed, the inclination gradually decreased, and was maintained.

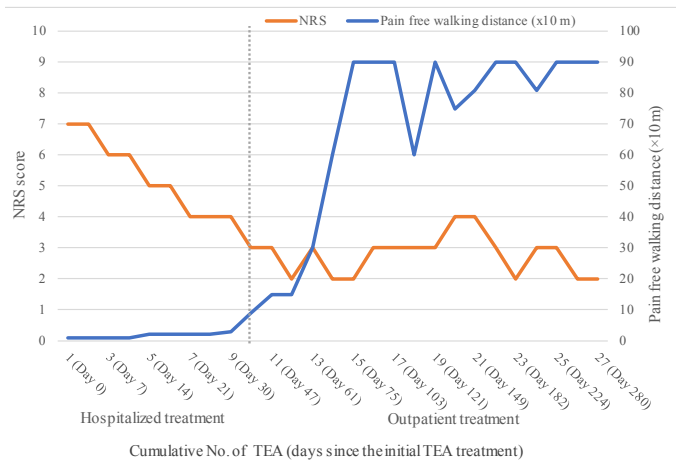


Fig. 5. The change in NRS score and the pain-free walking distance after TEA. NRS, numerical rating scale; TEA, thread embedding acupuncture.

could walk 20 m. When she was discharged from the hospital, she could walk 30 m without pain and claudication. After hospitalized treatment, when outpatient treatment was given once a week, her gaiting improved remarkably such that she could walk 150 m in 10 minutes. Four months after the treatment, she could maximally walk 900 m for 30 min without pain or claudication, although she could not perform indoor cycling exercises (Fig. 5). In the case of scoliosis radiography, the inclination of the lumbar spine was most severe when she was hospitalized. Upon improving the pain and the claudication, the inclination of the vertebra from the center of the body decreased. The antalgic posture gradually improved until the follow-up 6 months later. At the 11-month follow-up, the pain had improved, and the claudication, and scoliotic inclination were maintained (Fig. 4).

Discussion

LSS is caused by degenerative changes in the lumbar spine [1]. Clinically, many patients experience fluctuating improvement and worsening of symptoms [2]. The symptoms of LSS are

diverse, but the claudication accompanying low back pain has been reported to be associated with the inability to perform basic activities of daily living [1]. Although, the surgical decompression achieved by performing a laminectomy is considered the gold standard, choosing the optimal management strategy for LSS is usually guided by a set of clinical, radiological, and measurement indices [1,4]. There is no clear evidence that surgical therapy has an excellent effect over continuous conservative therapy [4]. Therefore, in this study, we chose TEA for a patient with LSS who had suffered from fluctuating symptoms of low back pain and claudication for about 20 years. The patient's lumbar spine showed various degenerative changes (Figs. 1 and 2) and these were causing chronic lumbar pain. The patient complained of worsening pain compared with the pain at the time of hospitalization, so she was taking analgesics. To differentiate the cause of this symptom from the acute disc herniation, a straight leg raising test was performed and it was confirmed to be negative.

TEA is acupuncture therapy based on the theory of meridians. It uses a specially designed device to embed foreign substances into derma meridians to continuously stimulate the muscles and treat diseases and conditions. TEA has typically been studied in the treatment of facial palsy [15], cosmetic and plastic surgery [16], and obesity [17]. Recently, studies on TEA for treatment of pain in conditions such as degenerative knee arthritis [18], plantar fasciitis [19], and lumbar disc herniation [20], chronic nonspecific neck pain [21] have been published.

The current number of publications related to TEA treatment that have been published in Korean medicine journals, and between 2003 and 2020, reached a total of 49 studies in the last 18 years since the first publication by Park et al in 2003 [13]. There have been 10 review articles (20.4%), 16 original articles (32.6%), and 23 case reports (46.9%). Internationally a randomized controlled pilot trial on the treatment of pain with TEA was performed by Lee et al [14], and randomized controlled trials by Kim et al [21] and Sung et al [22] have been reported.

Implanted bioresorbable threads can induced Type 3 collagen production which is associated with scar tissue formation and is fundamental in the formation of contiguous interstitium in the skin of rats and pigs [23-25]. Implanted bioresorbable threads may strengthen the tissues around the lumbar spine. A recent clinical study in patients with low back pain reported asymmetry in erector spinae muscle response to nerve stimulation using electromyography [9]. TEA treatment has been reported to reduce pain by reducing the asymmetry index of both erector spinae

muscles in patients with chronic low back pain [10].

TEA may cause pain during the procedure. The practitioner needs to inform the patient about predictable side effects, including bruising, local pain, small wounds in the TEA insertion area, numbness, dizziness, exhaustion, nausea, vomiting, cold limbs, and chest tightness. In this current study, during the first TEA treatment, the patient complained of worsening pain during the procedure, which was relieved within hours.

Maintaining the treatment over a 9-month period allowed the patients pain to improve, and claudication and antalgic posture to correct by performing walking, and indoor cycling exercises following discharge from hospital. Although the symptoms improved as the treatment continued, the walking distance decreased temporarily after the 19th TEA treatment of 27 (pain-free walking of 600 m). The reason was due to a sudden increase in the amount of indoor cycling exercise. As the amount of cycling exercise was adjusted, an increase in the amount of walking was observed (pain-free walking of 900 m). Although exercise may strengthen muscles and improve gait, we recommend that patients only increase the amount of exercise taken if they are acutely aware of an increased level of pain which may be caused by the amount of exercise taken.

Following TEA and complex Korean medicine treatment, the patient's symptoms of discomfort whilst performing daily activities were improved. This study did not focus only on TEA treatment for LSS, but rather on a combination of acupuncture, herbal medicine, and physical therapy. During treatment the patient underwent TEA, and the change in symptoms was clearly observed. TEA can be considered as a useful method for improving the pain caused by stenosis and scoliosis caused by the antalgic posture. However, this treatment was not given alone, it was given in a combination of treatments. Further pragmatic clinical studies should be conducted to provide evidence of the effectiveness of TEA. In addition, it is considered that a study on the exact mechanism by which TEA aids pain in chronic lumbar conditions including stenosis, is also needed. To derive more objective and effective results, more studies with more patients receiving TEA, with appropriately adjusted variables, and randomized controlled clinical trials are necessary.

Conflicts of Interest

The authors have no conflicts of interest to declare.

Ethical Statement

This research did not involve any human or animal experiment.

References

- [1] Abou-Al-Shaar H, Adogwa O, Mehta AI. Lumbar spinal stenosis: Objective measurement scales and ambulatory status. *Asian Spine J* 2018;12:765-774.
- [2] Amundsen T, Weber H, Nordal H, Magnaes B, Abdelnoor M, Lilleås F. Lumbar spinal stenosis: conservative or surgical management? A prospective 10-year study. *Spine J* 2000;25:1424-1436.
- [3] Watters III WC, Baisden J, Gilbert TJ, Kreiner S, Resnick DK, Bono CM et al. Degenerative lumbar spinal stenosis: An evidence-based clinical guideline for the diagnosis and treatment of degenerative lumbar spinal stenosis. *Spine J* 2008; 8:305-310.
- [4] Zaina F, Tomkins-Lane C, Carragee E, Negrini S. Surgical versus nonsurgical treatment for lumbar spinal stenosis. *Spine J* 2016;41:E857-868.
- [5] Deer TR, Grider JS, Pope JE, Falowski S, Lamer TJ, Calodney A et al. The MIST Guidelines: The lumbar spinal stenosis consensus group guidelines for minimally invasive spine treatment. *Pain Pract* 2019;19:250-274.
- [6] Cho JH, Lee HE, Moon JY, Lim MJ, Kang I, Kim JH. The clinical study on spinal stenosis of lumbar spine. *J Korea Chuna Man Med Spine Nerves* 2008;3:77-85. [in Korean].
- [7] Han KW, Kim ES, Woo JH, Lee SJ, Lee JS, Nam JH et al. Clinical observation on 119 patients with lumbar spinal stenosis treated with bee venom pharmacopuncture therapy. *J Acupunct Res* 2011;28:21-31. [in Korean].
- [8] Yoon SH, Kim YS, Kwon MG, Kwon CY. Randomized controlled trials of miniscalpel acupuncture for lumbar spinal stenosis cited in the China National Knowledge Infrastructure Database. *J Acupunct Res* 2017;34:59-69.
- [9] Reger SI, Shah A, Adams TC, Endredi J, Ranganathan V, Yue GH et al. Classification of large array surface myoelectric potentials from subjects with and without low back pain. *J Electromyogr Kinesiol* 2006;16:392-401.
- [10] Yoo DJ, Jung JY, Chung SH. Effects of the embedding acupuncture treatments for chronic low back pain patients. *J Orient Res Med* 2015;25:105-112. [in Korean].
- [11] Park SH, Jeon YT, Han KI, Kim MJ, Lee HI, Lee JH et al. Literature review of catgut-embedding therapy for lumbar disk herniation. *J Orient Res* 2015;25:29-40. [in Korean].
- [12] Choi SY, Bae JM, Choi JW, Yang GY, Lee BR, Kim KH. Patient's Perception for developing research questions of a clinical practice guideline of Korean medicine for degenerative lumbar spinal stenosis: A descriptive cross-sectional survey. *Korean J Acupunct* 2018;35:130-138. [in Korean].
- [13] Park CH, Kim JH, Wu TS, Park EJ, Shin JC, Han SG et al. A study of Literature review on the retaining needle. *J Acupunct Res* 2003;20:85-96. [in Korean].
- [14] Lee HJ, Choi BI, Jun SA, Park MS, Oh SJ, Lee JH et al. Efficacy and safety of thread embedding acupuncture for chronic low back pain: A randomized controlled pilot trial. *Trials* 2018;19:680.
- [15] Lee CW, Lee SM, Jeon JH, Kim JI, Kim YI. Effects of needle-embedding therapy on sequelae of peripheral facial palsy: A case series. *J Acupunct Res* 2011;28:93-103. [in Korean].
- [16] Lee SM, Lee CW, Jeon JH, Kim YI. The Effect of needle-embedding therapy on the improvement against facial wrinkles: A case series. *J Acupunct Res* 2011;28:143-147. [in Korean].
- [17] Nam EY. The Systematic Review on Clinical studies of traditional Korean medicine treatment for obesity in menopausal women. *J Korean Med Obes Res* 2019;19:56-67. [in Korean].
- [18] Lee JH, Yang TJ, Lee DG, Lee OJ, Wei TS. The effect of needle-embedding therapy on osteoarthritis of the knee combined with Korean medical treatment: Report of five cases. *J Acupunct Res* 2014;31:195-204. [in Korean].
- [19] Noh SH, Kim YR, Kim KH, Yang GY, Kim JK, Lee BR. Effects of Catgut-embedding acupuncture therapy on plantar fasciitis: Case report. *J Acupunct Res* 2013;30:227-233. [in Korean].
- [20] Hong SP, Bae JM, Kim DH, Yang GI, Lee BR. The effect of Korean medicine with needle-embedding therapy on a lumbar herniated intervertebral disc: A case report. *J Acupunct Res* 2016;33:219-224. [in Korean].
- [21] Kim ES, Kim YS, Kim YI, Jeon JH, Yoo HR, Park YC et al. Effectiveness and safety of polydioxanone thread-embedding acupuncture as an adjunctive therapy for patients with chronic nonspecific neck pain: A randomized controlled trial. *J Altern Complement Med* 2019;25:417-426.
- [22] Sung WS, Hong YJ, Jeon SR, Yoon JM, Chung EK, Jo HG, et al. Efficacy and safety of thread embedding acupuncture combined with acupuncture for chronic low back pain: A randomized, controlled, assessor-blinded, multicenter clinical trial. *Medicine* 2020;99:e22526.
- [23] Lee CG, Jung JY, Hwang SN, Park CO, Hwang SJ, Jo MJ, et al. Histological evaluation of bioresorbable threads in rats. *Korean J Clin Lab Sci* 2018;50:217-224.
- [24] Kim YJ, Kim HN, Shin MS, Choi BT. Thread embedding acupuncture inhibits ultraviolet B irradiation-induced skin photoaging in hairless mice. *Evid Based Complement Alternat Med* 2015;2015:539172.
- [25] Ko HJ, Choi JY, Moon HJ, Lee JW, Jang SI, Bae IH. Multi-polydioxanone (PDO) scaffold for forehead wrinkle correction: A pilot study. *J Cosmet Laser Ther* 2016;18:405-408.