

Changes in Blood Pressure and Heart Rate during Decompressive Craniectomy

Kwang Wook Jo,¹ Hyun-Ju Jung,² Do Sung Yoo,³ Hae-Kwan Park³

Department of Neurosurgery,¹ Bucheon St. Mary's Hospital, College of Medicine, The Catholic University of Korea, Seoul, Korea
Department of Anesthesiology,² Uijeongbu St. Mary's Hospital, College of Medicine, The Catholic University of Korea, Seoul, Korea
Department of Neurosurgery,³ Eunpyeong St. Mary's Hospital, College of Medicine, The Catholic University of Korea, Seoul, Korea

Objective : Rapid increase in intracranial pressure (ICP) can result in hypertension, bradycardia and apnea, referred to as the Cushing phenomenon. During decompressive craniectomy (DC), rapid ICP decreases can cause changes in mean arterial blood pressure (mABP) and heart rate (HR), which may be an indicator of intact autoregulation and vasomotor reflex.

Methods : A total of 82 patients who underwent DC due to traumatic brain injury (42 cases), hypertensive intracerebral hematoma (19 cases), or major infarction (21 cases) were included in this prospective study. Simultaneous ICP, mABP, and HR changes were monitored in one minute intervals during, prior to and 5–10 minutes following the DC.

Results : After DC, the ICP decreased from 38.1 ± 16.3 mmHg to 9.5 ± 14.2 mmHg ($p < 0.001$) and the mABP decreased from 86.4 ± 14.5 mmHg to 72.5 ± 11.4 mmHg ($p < 0.001$). Conversely, overall HR was not significantly changed in HR, which was 100.1 ± 19.7 rate/min prior to DC and 99.7 ± 18.2 rate/min ($p = 0.848$) after DC. Notably when the HR increased after DC, it correlated with a favorable outcome ($p < 0.001$), however mortality was increased ($p = 0.032$) when the HR decreased or remained unchanged.

Conclusion : In this study, ICP was decreased in all patients after DC. Changes in HR were an indicator of preserved autoregulation and vasomotor reflex. The clinical outcome was improved in patients with increased HR after DC.

Key Words : Prognosis · Decompressive craniectomy · Heart rate · Intracranial pressure · Mean arterial blood pressure.

INTRODUCTION

Despite highly developed medical and neurosurgical treatments, the mortality and morbidity of patients with intractable increased intracranial pressure (ICP) remains challenging^{3,14,19,36,37}. Prior studies have reported both benefits and limitations associated with decompressive craniectomy (DC) in patients with hypertensive intracerebral hemorrhage (H-

ICH)^{4,17}, traumatic brain injury (TBI)^{3,14,24,36}, and major infarction (MI)^{12,16,24,27,36,37}. Often DC is the last choice of treatment, though, it remains the most effective treatment for patients with uncontrollable brain swelling. The surgical procedures for DC include removing the bone over large areas of the calvarium, converting a “closed box” with a finite volume into an open one. It is a rapid and effective surgical method for uncontrollable increase in ICP. After DC, surgery the ICP

• Received : December 21, 2020 • Revised : February 3, 2021 • Accepted : April 28, 2021

• Address for reprints : **Do Sung Yoo**

Department of Neurosurgery, Eunpyeong St. Mary's Hospital, College of Medicine, The Catholic University of Korea, 1021 Tongil-ro, Eunpyeong-gu, Seoul 03312, Korea
Tel : +82-2-2030-4491, Fax : +82-2-2030-4626, E-mail : yooman@catholic.ac.kr, ORCID : https://orcid.org/0000-0003-2569-6502

This is an Open Access article distributed under the terms of the Creative Commons Attribution Non-Commercial License (<http://creativecommons.org/licenses/by-nc/4.0>) which permits unrestricted non-commercial use, distribution, and reproduction in any medium, provided the original work is properly cited.

will be decreased, and cerebral perfusion pressure can be improved to an adequate level. Moreover, DC will allow an edematous brain to herniate through the craniectomy opening rather than through the tentorial incisura, thereby avoiding brain stem compression^{5,36,37}.

Rapidly increasing ICP can trigger the Cushing reflex which cause hypertension, bradycardia, and respiratory irregularities, all of which are signs of subsequent brain herniation and death^{1,6,11,18,31,38}. In situations where there is acute elevation of ICP, the Cushing reflex occurs. Decreasing the ICP may be critical to improving clinical outcomes and saving the patient's life. Several pathophysiological studies refined Cushing's findings by showing an initial tachycardia associated with hypertension followed by bradycardia. The initial hypertensive and tachycardia symptoms were due to the elevated activity of the sympathetic nervous system and late bradycardia was mediated by parasympathetic nerve activation^{1,6,7,10,11,20-23,29,31}.

In the current study, it was hypothesized that the Cushing's reflex could be an indicator of intact autoregulation. Under this hypothesis, increased heart rate (HR) compensated for decreased mean arterial blood pressure (mABP) following DC may reflect an intact vasomotor reflex. Patients with intact autoregulation and vasomotor reflex showed more favorable outcomes compared to patients without these reflexes^{1,23}.

The current results indicate that the mABP was generally decreased during DC, while the ICP decreased rapidly. Thus,

changes in the HR were also investigated. If autoregulation and the vasomotor response were intact, the mABP decrease might influence the HR to preserve cerebral perfusion. Patients with intact autoregulation and vasomotor responses, may have better clinical outcomes than patients without intact responses.

MATERIALS AND METHODS

This prospective, observational study was approved by the Institutional Review Board of Eunpyeong St. Mary's Hospital. The treatment protocol (Fig. 1) was also approved by the Institutional Review Board of Eunpyeong St. Mary's Hospital (PC17RESI0027). All patients or their representatives provided written consent to treatment.

Patient selection

Eighty-two patients with massive brain swelling due to TBI (42 cases), H-ICH (19 cases) or MI (21 cases), that were treated by DC with dura expansion between January 2017 and June 2020, were included in the current study. Patients were successfully monitored for ventricular ICP, mABP, and HR changes before and after the DC (Table 1). This study included 82 patients. There were 59 males and 23 females with a mean age of 49.7±156.4 years (range, 8–77; median age, 53 years).

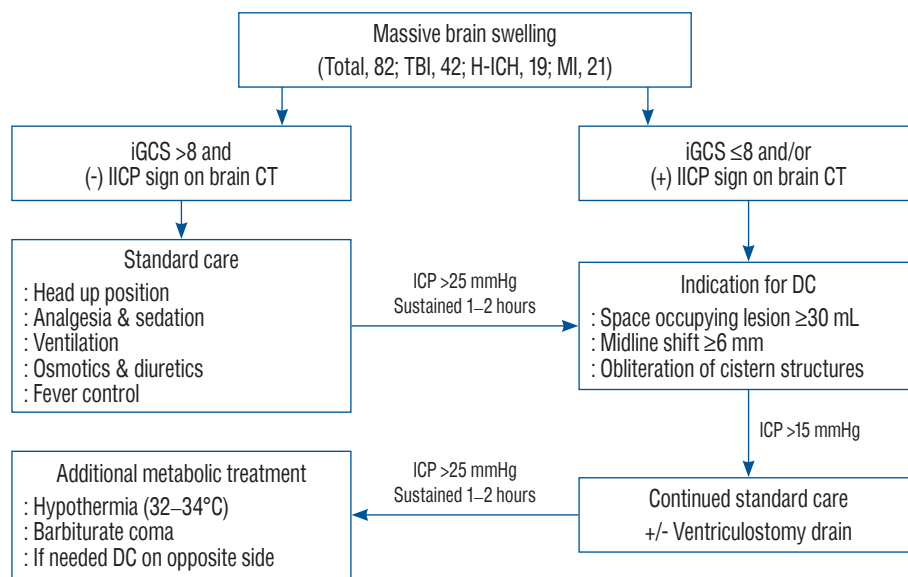


Fig. 1. Flow sheet of treatment protocol. TBI : traumatic brain injury, H-ICH : hypertensive intracerebral hemorrhage, MI : major infarction, iGCS : initial Glasgow coma scale, ICP : increased intracranial pressure, CT : computed tomography, DC : decompressive craniectomy.

Standard management was performed including computed tomography (CT) scan as rapidly as possible when neurological deterioration was apparent. ICP was monitored during the DC surgery, 58 patients were monitored with a CPP-monitoring device (CPP-monitor; Spiegelberg, Hamburg, Germany) and the remaining 24 with a Philips patient monitor (IntelliVue MX700; Phillips Medizin Systeme Boeblingen GmbH, Böblingen, Germany).

Indications for surgery and postoperative management

Indications for DC were the appearance of massive uni- or bilateral brain swelling on CT scans, with correlating clinical deterioration; worsening of Glasgow coma scale (GCS) less than 8–9 and/or dilation of the pupils unresponsive to light; a midline shift of more than 6 mm; and/or obliteration of the perimesencephalic cistern on CT scans. None of the patients

Table 1. Characteristics and clinical outcomes of the 82 patients treated with DC

	Etiology			Total cases	p-value*
	TBI	H-ICH	MI		
Patient	42	19	21	82	
Age (years)					
Mean±SD	48.3±19.1	50.2±11.8	52.2±14.3	49.7±16.4	TBI vs. H-ICH ($p=0.015$)
Median	46	55	55	53	
Range	8–77	25–65	25–76	8–77	
Male sex	37 (88.1)	11 (57.9)	11 (52.4)	59 (72.0)	
GCS score					
Mean±SD	5.5±2.0	5.8±1.9	6.0±1.8	5.7±1.9	
Median	5	6	6	5	
Range	3–10	3–9	4–10	3–10	
Initial ICP	32.8±12.7	44.6±16.2	42.2±19.0	38.1±16.0	TBI vs. MI ($p=0.027$)
Post DC ICP	10.4±19.9	7.4±4.4	10.1±4.7	9.5±14.1	
ICP difference	22.3±19.5	37.2±16.1	32.1±19.2	28.7±19.4	
Initial mABP	83.1±11.9	91.7±16.3	88.0±16.3	86.4±14.5	
Post DC mABP	70.5±11.7	75.9±10.5	73.5±11.2	72.5±14.5	
mABP difference	12.5±11.2	15.8±14.5	14.5±17.3	13.8±13.6	
Initial HR	101.6±18.2	97.1±20.4	99.8±22.6	100.1±19.7	
Post DC HR	102.1±20.1	96.6±15.3	97.7±16.8	99.7±18.2	
HR difference	0.5±17.1	-0.5±20.0	-2.1±15.0	-0.4±17.2	
Clinical outcomes					
GOS					
5	17	7	4	28	
4	4	2	2	8	
Favorable	21 (50.0)	9 (47.4)	6 (28.6)	36 (43.9)	0.005, TBI vs. MI
3	1	2	2	5	
2	16	2	2	20	
1 Death	4 (9.5)	6 (31.6)	11 (52.4)	21 (25.6)	
Median	2	3	6	3	

Values are presented as mean±standard deviation or number (%). *Fisher's exact test. SD : standard deviation, DC : decompressive craniectomy, TBI : traumatic brain injury, H-ICH : hypertensive intracerebral hemorrhage, MI : major infarction, GCS : Glasgow coma scale, ICP : intracranial pressure, mABP : mean arterial pressure, HR : heart rate, GOS : Glasgow outcome scale

displayed Cushing's phenomenon corresponding to increased ICP were apparent. Initial ICP monitored after ventricular puncture was high. Patients with primary fatal brainstem failure, indicated by no spontaneous respiration and a persistent GCS score of 3 and/or bilaterally fixed and dilated pupils, did not undergo surgical decompression. Surgical methods (unilateral or bilateral hemicraniectomy) and DC bone size were decided by the operating surgeon. After DC, conventional medical managements, including hyperosmotic agents, hyperventilation, and extraventricular drainage (EVD), were initiated if the ventricular pressure exceeded 20 mmHg (Fig. 1).

Anesthesia and surgical procedures

All patients were operated on under endotracheal general anesthesia in the supine position. Upon arrival in the operating room, the patient was connected to standard monitoring devices.

Bispectral index (BIS) electrode was positioned on the patient's mandible, contralateral to the lesion. Propofol and remifentanyl infusion rate was targeted to keep BIS values between 40 and 60. A radial arterial catheter was inserted for the continuous monitoring of arterial blood pressure. Anesthesia was induced and maintained with propofol, remifentanyl and cisatracurium. Blood pressure was managed by a bolus or continuous infusion of norepinephrine or phenylephrin, as appropriate.

In all patients, ventricular puncture was performed before DC and ICP was monitored during and after the surgery. The EVD tube (EVD catheter; Yushin Medical, Seoul, Korea) was connected to a continuous monitor (CPP-monitor; Spiegelberg, Hamburg, Germany or IntelliVue MX700; Philips Medizin Systeme Boehringer GmbH, Böhlingen, Germany) via a transducer device (Druckmeß-set; Smiths Industries, Grasbrunn, Germany or Pressure Monitoring Set; Edward Lifesciences, Irvine, CA, USA). A large inverted question mark shaped or bicoronal skin flap was used. The limbs were placed just behind the parietal eminence, extending inferiorly to the zygoma and curving anteriorly to the mid-line. The reference points for the bone flaps were: 1) the burr holes in the pterion of frontal bone; 2) the burr holes at the parietal eminences; and 3) the burr holes in the squamous portions. After the ventricular ICP was stabilized, the burr holes were connected using a pneumatic saw, with subsequent removal of the bone flap. The removed bone size was at least 12×15 cm. The frontal

median segment of the bone, which was measured approximately 3 to 4 cm in width along the sagittal sinus, was saved to avoid damage to the sagittal sinus and to function as a framework for later cranioplasty. An additional bone was removed at the temporal region to the floor of the middle fossa. Immediately after the craniectomy, the dura was opened, within 5–10 minutes. Cortical resection of the brain was not performed. In all patient, artificial dura (Lyoplast; B. Braun MelsungenAG, Melsungen, Germany) was placed underneath the incised dura, and secured with several sutures, to allow the brain to herniate outward in a more controlled manner, and to prevent cortical adhesion. Several pieces of Gelform (Gelfoam Sponge; ACE Surgical Supply, Brockton, MA, USA) were inserted to control postoperative epidural bleeding, and preserve the dissection plane, after cranioplasty. The temporalis muscle and skin flap were reapproximated with sutures¹⁹. In general situation, during DC, expected blood loss was from about 250 to 500 mL. The blood loss could be somewhat variable according to the patients but it was not definitely influent on the vital sign changes. Typically, the bone flap was maintained in wet gauze at -70°C until reinsertion, at 6 or 8 weeks after the initial surgery. If the autologous bone was not appropriate for reinsertion, the bone fragment for cranioplasty was made using a 3D printer.

Data collection

The initial ICP checked after ventricular tapping was considered to be the highest sustained ventricular pressure. The ventricular pressure obtained after craniectomy and dura opening was considered the DC state ICP and dura opening state ICP, respectively. The ventricular pressure was continuously monitored during the operation. The ICP, mABP and HR changes were monitored every minute, and the data just prior the DC and the most extreme values measured within 10 minutes after the DC were compared. The HR increase or unchanged vs. decrease before and after DC (Table 2). Clinical outcomes were analyzed by Glasgow outcome scale (GOS) score after 6 months after DC. And GOS 5–4 was defined as favorable outcome, GOS 3–2 was defined as a poor outcome and GOS score of 1 was defined as death.

Statistical analysis

All data were presented as the mean±standard deviation (median value). Comparisons between the data collected be-

Table 2. Clinical outcomes according to the HR change

	Outcome			
	Favorable (GOS=5-4; n=36)	Poor (GOS=3-2; n=25)	Dead (GOS=1; n=21)	Total (n=82)
HR \approx or \downarrow	13	17	18	48
HR \uparrow	23	8	3	34
<i>p</i> -value*	0.001		0.032	

*Fisher's exact test. HR : heart rate, GOS : Glasgow outcome scale

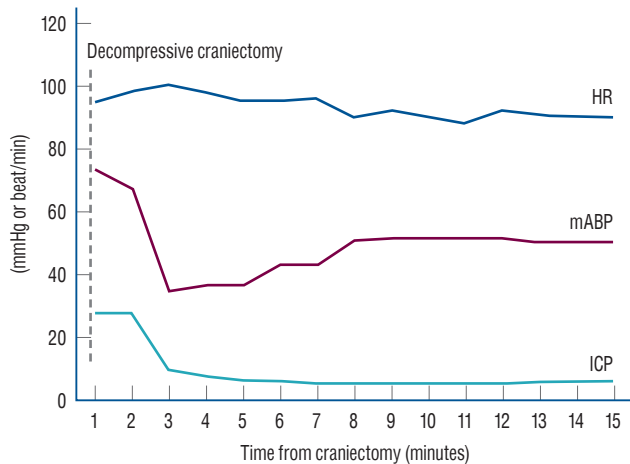


Fig. 2. Demonstration of ICP, mABP, and HR changes during the decompressive craniectomy surgery. HR : heart rate, mABP : mean arterial blood pressure, ICP : intracranial pressure.

fore and after surgery were performed using the two-tailed, paired Student's *t*-test. Differences between categories were compared using a Fisher's exact *t*-test. Statistical significance set at a value of $p < 0.05$. For statistical analysis of the data, non-parametric correlations were determined using SPSS ver. 11.0 (SPSS Inc., Chicago, IL, USA).

RESULTS

ICP changes during DC surgery

Before and after DC, the ICP decreased from 38.1 ± 16.3 mmHg to 9.5 ± 14.2 mmHg ($p < 0.001$, Table 1). In all patients, the ICP decreased after DC surgery, and the degree of ICP decrease was correlated with neurologic outcomes ($p = 0.013$).

mABP changes during DC surgery

On average, the mABP decreased from 86.4 ± 14.5 mmHg to 72.5 ± 11.4 mmHg ($p < 0.001$). In most patients, the mABP was

decreased after DC surgery with the exception of eight patients, where the mABP increased after DC surgery. The mABP changes, before and after DC, were not correlated with clinical outcomes (favorable outcome, $p = 0.200$; mortality, $p = 0.466$).

HR changes during the DC surgery

The mean HR decreased from 100.1 ± 19.7 rate/min to 99.7 ± 18.2 rate/min ($p = 0.848$) during DC surgery. In 34 patients, the HR was increased, 23 of the 34 patients displayed favorable outcomes. In the remaining 48 patients, the HR was decreased or unchanged, and 18 of those patients were dead. Increased HR after DC was significantly correlated with favorable outcomes ($p < 0.001$). While decreased HR after DC was correlated with mortality ($p = 0.032$, Table 2).

Comparisons of statistical results according to the data after DC

In most patients, systolic blood pressure was decreased by approximately 15 mmHg. In some patients, the systolic blood pressure after DC was decreased to below 60 mmHg. In these cases, the anesthesiologist typically administered a bolus or continuous infusion of an inotropic agent (norepinephrine or epinephrine). The anesthetic interventions affected mABP and HR approximately about 5–10 minutes after administration. Data collected during a wide time interval (approximately 30 minute before and after DC), showed quite different values compared with the data with a short range of time interval (data collected before and within 5 minutes after DC) (Fig. 2).

Statistical results of data collected over a wide time interval of about 30 minutes showed no significant difference in favorable outcomes ($p = 0.199$) or mortality ($p = 0.243$) (data not shown), but the results of data collected over a short time interval of about 5–10 minutes were significantly correlated with clinical outcomes. When the HR increased after DC,

there were significant correlations with favorable outcomes ($p < 0.001$), whereas if HR was unchanged or decreased after DC, significantly with mortality ($p = 0.032$, Table 2).

DISCUSSION

Elevated ICP has been found to correlate with adverse outcomes from massive brain swelling. Therefore, accurate knowledge and proper management of ICP are important tools in improving outcomes in patients with massive brain swelling. Many attempts have been made to control massive brain swelling using various medical and surgical treatment modalities, each associated with moderate success^{13,15,37}. Over the past several decades, many studies have shown that DC is an effective treatment strategy in patients with intractable increased ICP caused by a variety of neurosurgical diseases^{3,4,8,12,14,16,17,24,27,28,32,33,35-37}.

Hypertension, bradycardia, and respiratory irregularities are the signs of critically increased ICP, which may predict impending brain herniation and death. It is better known as the Cushing reflex, the Cushing reaction, the Cushing phenomenon, the Cushing response, and Cushing's law^{1,6,11,18,31,38}.

Several animal, pathophysiological and clinical observational studies have reported elevated blood pressure in subjects with severely increased ICP. This increase can result from an autoregulation response to maintain cerebral perfusion pressure and cerebral blood flow^{1,6,10,11,18,20-22,29,31}, which may be associated with paroxysmal sympathetic hyperactivity^{7,10,18,21-23,25}. The respiratory irregularity, characterized by Harvey Cushing, is believed to be a phenomenon caused by tonsillar herniation^{1,6,11,31}, which is better known as the Cushing reflex, the Cushing reaction, the Cushing phenomenon, the Cushing response, and Cushing's law^{1,6,11,18,31,38}.

Since the brain is encased in the unyielding vault of the skull, and the brain injury which causes edema and increased blood flow results in elevated ICP³⁰. DC surgery is performed to increase the volume of the space available for expanding edematous brain tissue, inducing a shift to the right of the pressure volume curve^{9,15,24}. This results in effectively lowering of the increased ICP, improving cerebral oxygenation and preventing secondary brain damage^{1,12,15,26,34,37}.

In the current study, it was hypothesized that the Cushing's reflex could be an indicator of intact autoregulation. Under

this hypothesis, HR compensated for decreased mABP following DC may reflect an intact vasomotor reflex. During clinical observation, the initial mABP was not high as we expected in a patient meeting the criteria for the Cushing phenomenon state where the increased ICP could change the mABP and HR.

It is possible that general anesthesia influences the mABP in increased ICP patients. Patients with intact autoregulation showed more favorable outcomes compared to patients without it^{1,23}. Once the ICP dropped after DC, the mABP also decreased as the intact autoregulation maintained the cerebral perfusion pressure. The mABP then decreased suddenly and the HR increased as a reflex of the vasomotor response. This phenomenon appears to be the reverse phenomenon of the Cushing reflex²³.

A previous study that monitored hemodynamic changes during DC in patients with TBI under general anesthesia found that HR was not changed before and after DC and authors hypothesized that this unchanged HR may have been the result of the data acquisition time, as data were collected before the skin incision and after the hematoma removal². The prior study compared data obtained over a wide range of time before and after DC, however in the current study the data were acquired in a short time range just before and within 5–10 minutes after the DC. This short acquisition time interval was less influenced by the anesthesia that affected the patient's vital signs. If the patient's mABP dropped after DC, the anesthesiologist immediately infused inotropic agents to maintain a stable mABP. Most of the medications given by the anesthesiologist during the operation exerted their pharmacologic effects within several minutes after administration.

In the current study results indicate that the ICP was decreased in all patients and the mABP was decreased in most patients after the DC procedure. However, the HR change was variable among patients, and correlated with clinical outcomes. In patients where the HR decreased after DC surgery, mortality was significantly increased. Conversely, in patients where the HR increased, the chance of a favorable outcome increased as well. A large study using a greater number of patients is needed to determine the robustness and clinical usefulness of this response. Most DC procedures are conducted on critical patients where the anesthetic medications that are used can influence the vital signs.

There were limitations to this study. First, though this was a

prospective study, but the population may be a homogeneous sample as it was performed in one institution. Second, there was no fixed protocol for anesthesia during DC surgery, therefore the administration of vasoactive medications was not done in a controlled manner, possibly causing bias in statistical analysis. Third, at the beginning of this study, data collection was done by two monitors, one for ICP monitoring device and the other for vital signs monitoring anesthetic machine. Merging data from these two different sources and basing the time measurements on each monitor may have caused bias as well.

CONCLUSION

ICP and mABP were decreased in most patients after DC, however the HR changes were variable. The DC procedure was performed in acute critical patients with highly elevated ICP, which was not a result of the Cushing phenomenon. If the HR decreased during DC, the probability of mortality was increased. When HR increased, the probability of a favorable outcome increased. These results suggest that the clinical outcomes differ based on HR changes after DC which may be the result of an intact autoregulation and vasomotor reflex.

CONFLICTS OF INTEREST

No potential conflict of interest relevant to this article was reported.

INFORMED CONSENT

Informed consent was obtained from all individual participants included in this study.

AUTHOR CONTRIBUTIONS

Conceptualization : KWJ, DSY

Data curation : HJJ, HKP

Formal analysis : HJJ, HKP

Funding acquisition : KWJ, DSY

Methodology : KWJ, DSY

Project administration : KWJ, DSY

Visualization : HJJ, HKP

Writing - original draft : KWJ, HJJ, DSY

Writing - review & editing : KWJ, DSY

ORCID

Kwang Wook Jo <https://orcid.org/0000-0001-7993-3409>

Hyun-Ju Jung <https://orcid.org/0000-0001-7258-6758>

Do Sung Yoo <https://orcid.org/0000-0003-2569-6502>

Hae-Kwan Park <https://orcid.org/0000-0001-7132-7009>

• Acknowledgements

Authors appreciate the help of Neurosurgical nurse specialist (Min-Hee Kim) to collect the data and the grammatical review of our manuscript by Ann C Rice, PhD of the J. Sargeant Reynolds Community College, Richmond, VA, USA.

References

1. Barbiro-Michaely E, Mayevsky A : Effects of elevated ICP on brain function: can the multiparametric monitoring system detect the 'Cushing Response'? **Neurol Res** **25** : 42-52, 2003
2. Bharath S, Radhakrishnan M, Umamaheswara Rao GS : Hemodynamic changes during surgical decompression in traumatic brain injury patients. **World Neurosurg** **136** : e553-e558, 2020
3. Brain Trauma Foundation; American Association of Neurological Surgeons; Congress of Neurological Surgeons; Joint Section on Neurotrauma and Critical Care, AANS/CNS, Bratton SL, et al. : Guidelines for the management of severe traumatic brain injury. VIII. Intracranial pressure thresholds. **J Neurotrauma** **24 Suppl 1** : S55-S58, 2007
4. Broderick JP, Adams HP Jr, Barsan W, Feinberg W, Feldmann E, Grotta J, et al. : Guidelines for the management of spontaneous intracerebral hemorrhage: a statement for healthcare professionals from a special writing group of the Stroke Council, American Heart Association. **Stroke** **30** : 905-915,1999
5. Carney N, Totten AM, O'Reilly C, Ullman JS, Hawryluk GW, Bell MJ, et al. : Guidelines for the management of severe traumatic brain injury, fourth edition. **Neurosurgery** **80** : 6-15, 2017
6. Fodstad H, Kelly PJ, Buchfelder M : History of the cushing reflex. **Neurosurgery** **59** : 1132-1137; discussion 1137, 2006
7. Furuichi S, Endo S, Haji A, Takeda R, Nisijima M, Takaku A : Related changes in sympathetic activity, cerebral blood flow and intracranial

- pressure, and effect of an alpha-blocker in experimental subarachnoid haemorrhage. **Acta Neurochir (Wien)** **141** : 415-423; discussion 423-424, 1999
8. Georgiadis D, Schwarz S, Aschoff A, Schwab S : Hemicraniectomy and moderate hypothermia in patients with severe ischemic stroke. **Stroke** **33** : 1584-1588, 2002
 9. Guerra WK, Gaab MR, Dietz H, Mueller JU, Piek J, Fritsch MJ : Surgical decompression for traumatic brain swelling: indications and results. **J Neurosurg** **90** : 187-196, 1999
 10. Guild SJ, Saxena UA, McBryde FD, Malpas SC, Ramchandra R : Intracranial pressure influences the level of sympathetic tone. **Am J Physiol Regul Integr Comp Physiol** **315** : R1049-R1053, 2018
 11. Heymans C : The control of heart rate consequent to changes in the cephalic blood pressure and in the intracranial pressure. **Am J Physiol** **85** : 498-506, 1928
 12. Hofmeijer J, van der Worp HB, Kappelle LJ : Treatment of space-occupying cerebral infarction. **Crit Care Med** **31** : 617-625, 2003
 13. Holtkamp M, Buchheim K, Unterberg A, Hoffmann O, Schielke E, Weber JR, et al. : Hemicraniectomy in elderly patients with space occupying media infarction: improved survival but poor functional outcome. **J Neurol Neurosurg Psychiatry** **70** : 226-228, 2001
 14. Hutchinson PJ, Koliakos AG, Timofeev IS, Corteen EA, Czosnyka M, Timothy J, et al. : Trial of decompressive craniectomy for traumatic intracranial hypertension. **N Engl J Med** **375** : 1119-1130, 2016
 15. Jiang JY, Xu W, Li WP, Xu WH, Zhang J, Bao YH, et al. : Efficacy of standard trauma craniectomy for refractory intracranial hypertension with severe traumatic brain injury: a multicenter, prospective, randomized controlled study. **J Neurotrauma** **22** : 623-628, 2005
 16. Jüttler E, Schwab S, Schmiedek P, Unterberg A, Hennerici M, Woitzik J, et al. : Decompressive surgery for the treatment of malignant infarction of the middle cerebral artery (DESTINY): a randomized, controlled trial. **Stroke** **38** : 2518-2525, 2007
 17. Juvela S, Heiskanen O, Poranen A, Valtonen S, Kuurne T, Kaste M, et al. : The treatment of spontaneous intracerebral hemorrhage. A prospective randomized trial of surgical and conservative treatment. **J Neurosurg** **70** : 755-758, 1989
 18. Kalmar AF, Van Aken J, Caemaert J, Mortier EP, Struys MM : Value of cushioning reflex as warning sign for brain ischaemia during neuroendoscopy. **Br J Anaesth** **94** : 791-799, 2005
 19. Kim KT, Park JK, Kang SG, Cho KS, Yoo DS, Jang DK, et al. : Comparison of the effect of decompressive craniectomy on different neurosurgical diseases. **Acta Neurochir (Wien)** **151** : 21-30, 2009
 20. Kocsis B, Fedina L, Pasztor E : Effect of preexisting brain ischemia on sympathetic nerve response to intracranial hypertension. **J Appl Physiol (1985)** **70** : 2181-2187, 1991
 21. Krasney JA, Koehler RC : Heart rate and rhythm and intracranial pressure. **Am J Physiol** **230** : 1695-1700, 1976
 22. Matsuura S, Sakamoto H, Hayashida Y, Kuno M : Efferent discharges of sympathetic and parasympathetic nerve fibers during increased intracranial pressure in anesthetized cats in the absence and presence of pressor response. **Brain Res** **305** : 291-301, 1984
 23. McBryde FD, Malpas SC, Paton JF : Intracranial mechanisms for preserving brain blood flow in health and disease. **Acta Physiol (Oxf)** **219** : 274-287, 2017
 24. Münch E, Horn P, Schürer L, Piepgras A, Paul T, Schmiedek P : Management of severe traumatic brain injury by decompressive craniectomy. **Neurosurgery** **47** : 315-322; discussion 322-323, 2000
 25. Rangel-Castilla L, Gopinath S, Robertson CS : Management of intracranial hypertension. **Neurol Clin** **26** : 521-541, x, 2008
 26. Reithmeier T, Speder B, Pakos P, Brinker G, Löhr M, Klug N, et al. : Delayed bilateral craniectomy for treatment of traumatic brain swelling in children: case report and review of the literature. **Childs Nerv Syst** **21** : 249-253; discussion 254, 2005
 27. Robertson SC, Lennarson P, Hasan DM, Traynelis VC : Clinical course and surgical management of massive cerebral infarction. **Neurosurgery** **55** : 55-61; discussion 61-62, 2004
 28. Ruf B, Heckmann M, Schroth I, Hügens-Penzel M, Reiss I, Borkhardt A, et al. : Early decompressive craniectomy and duraplasty for refractory intracranial hypertension in children: results of a pilot study. **Crit Care** **7** : R133-R138, 2003
 29. Schmidt EA, Despas F, Pavy-Le Traon A, Czosnyka Z, Pickard JD, Rahmouni K, et al. : Intracranial pressure is a determinant of sympathetic activity. **Front Physiol** **9** : 11, 2018
 30. Schwab S, Aschoff A, Spranger M, Albert F, Hacke W : The value of intracranial pressure monitoring in acute hemispheric stroke. **Neurology** **47** : 393-398, 1996
 31. Shelton BA, O'Hara E, Tubbs RS, Shoja MM, Barker FG, Cohen-Gadol AA : Emergency suboccipital decompression for respiratory arrest during supratentorial surgery: the untold story of a surgeon's courage in times of despair. **J Neurosurg** **110** : 391-394, 2009
 32. Smith ER, Carter BS, Ogilvy CS : Proposed use of prophylactic decompressive craniectomy in poor-grade aneurysmal subarachnoid hemorrhage patients presenting with associated large sylvian hematomas. **Neurosurgery** **51** : 117-124; discussion 124, 2002
 33. Stefani R, Latronico N, Cornali C, Rasulo F, Bollati A : Emergent decompressive craniectomy in patients with fixed dilated pupils due to cerebral venous and dural sinus thrombosis: report of three cases. **Neurosurgery** **45** : 626-629; discussion 629-630, 1999
 34. Stiefel MF, Heuer GG, Smith MJ, Bloom S, Maloney-Wilensky E, Gracias VH, et al. : Cerebral oxygenation following decompressive hemicraniectomy for the treatment of refractory intracranial hypertension. **J Neurosurg** **101** : 241-247, 2004
 35. Vahedi K, Vicaut E, Mateo J, Kurtz A, Orabi M, Guichard JP, et al. : Sequential-design, multicenter, randomized, controlled trial of early decompressive craniectomy in malignant middle cerebral artery infarction (DECIMAL trial). **Stroke** **38** : 2506-2517, 2007
 36. Winter CD, Adamides A, Rosenfeld JV : The role of decompressive craniectomy in the management of traumatic brain injury: a critical review. **J Clin Neurosci** **12** : 619-623, 2005
 37. Yoo DS, Kim DS, Cho KS, Huh PW, Park CK, Kang JK : Ventricular pressure monitoring during bilateral decompression with dural expansion. **J Neurosurg** **91** : 953-959, 1999

38. Yumoto T, Mitsuhashi T, Yamakawa Y, Iida A, Nosaka N, Tsukahara K, et al. : Impact of cushing's sign in the prehospital setting on predicting the need for immediate neurosurgical intervention in trauma patients: a na-

tionwide retrospective observational study. **Scand J Trauma Resusc Emerg Med** 24 : 147, 2016