

Radiographic analysis of the management of tooth extractions in head and neck-irradiated patients: a case series

Samanta V. Oliveira¹, Renata S. Vellei¹, Daniele Heguedusch¹, Carina Domaneschi¹,
Claudio Costa¹, Camila de Barros Gallo^{1,*}

¹Stomatology Department, Universidade de São Paulo School of Dentistry, São Paulo, Brazil

ABSTRACT

Tooth extraction after head and neck radiotherapy exposes patients to an increased risk for osteoradionecrosis of the jaw. This study reports the results of a radiographic analysis of bone neoformation after tooth extraction in a case series of patients who underwent radiation therapy. No patients developed osteoradionecrosis within a follow-up of 1 year. Complete mucosal repair was observed 30 days after surgery, while no sign of bone formation was observed 2 months after the dental extractions. Pixel intensity and fractal dimension image analyses only showed significant bone formation 12 months after the tooth extractions. These surgical procedures must follow a strict protocol that includes antibiotic prophylaxis and therapy and complete wound closure, since bone formation at the alveolar socket occurs at a slower pace in patients who have undergone head and neck radiotherapy. (*Imaging Sci Dent* 2021; 51: 323-8)

KEY WORDS: Radiography, Dental; Radiotherapy; Tooth Extraction; Osteoradionecrosis

Osteoradionecrosis (ORN) is the most severe consequence of head and neck radiotherapy (HNRT) for cancer treatment. It frequently affects the maxillary and mandibular bones, especially in the first 3 years after HNRT, with an incidence of 5%. ORN can occur spontaneously or traumatically, and tooth extraction trauma accounts for 88% of cases.^{1,2}

After its onset, ORN has no cure, but it can be controlled. Currently, there is no universal protocol for its treatment, which can be based on conservative approaches, such as local irrigation with chlorhexidine, non-surgical debridement, ultrasound therapy, hyperbaric oxygen therapy, pentoxifylline associated with a tocopherol regimen, and low-level laser and photodynamic therapy. Alternatively, total necrotic bone removal surgery, in combination with systemic antibiotics, with complete wound closure is still considered the treatment of choice for ORN.¹⁻³ However, the management of ORN is a difficult task, requiring multidisci-

plinary specialized care.

The greatest efforts in the dental management of head and neck cancer patients treated with HNRT are focused on ORN prevention. Some protocols proposed for the treatment of this condition have also been suggested for ORN prevention in post-radiotherapy extractions, thus significantly reducing the incidence of ORN.²

Studies that analyzed panoramic images of HNRT patients revealed alterations such as a widened periodontal ligament space,⁴ reduced thickness of the mandibular canal and cortex,⁵ and decreased mean pixel intensity and fractal dimension values of the mandibular bone as side effects of ionizing irradiation on bone tissue.⁶ These results suggest that research into post-radiotherapy jaw changes on imaging exams may predict ORN risk and provide insights into the need for conservative dental treatment or other preventive measures. However, the imaging profile of bone repair processes after invasive procedures, such as tooth extractions, in HNRT patients remains unknown.

Thus, the objective of this study was to report the results from a radiographic analysis of a cohort of patients who underwent HNRT and tooth extraction.

This study was financed in part by the Coordenação de Aperfeiçoamento de Pessoal de Nível Superior - Brasil (CAPES) - Finance Code 001.

Received December 19, 2020; Revised February 4, 2021; Accepted February 5, 2021

*Correspondence to : Prof. Camila de Barros Gallo

Stomatology Department of the Universidade de São Paulo School of Dentistry, Av. Prof. Lineu Prestes, 2227 - Butantã, São Paulo - SP, Brazil

Tel) 55-11-2648-8148, E-mail) camilabg@usp.br

Case Report

Five participants with a history of head and neck squamous cell carcinoma (HNSCC) who had undergone 3-dimensional conformation radiotherapy underwent tooth extraction. The local Ethics Committee approved this study (CEP-FOUSP CAAE: 99191518.2.0000.0075), and all patients signed an informed consent form.

The clinical data of this case series are summarized in Table 1. None of the patients had used any antiresorptive drugs, were receiving head and neck cancer treatment, or presented with local recurrence or ORN. The average total dose of radiotherapy was 65.1 Gy and the mean timeframe after HNRT was 6.6 years.

The tooth extractions followed the protocol proposed by Nabil and Samman,² which mainly consists of antibiotic prophylaxis and therapy in combination with tooth extraction and complete wound closure. The patients started the

systemic antibiotic regimen 24 hours before the surgical procedure and continued for 7 days. The antibiotic of choice was amoxicillin (500 mg) in tablets or oral suspension, depending on the patient’s degree of dysphagia. Clindamycin (300 mg) was the replacement antibiotic for patients allergic to penicillin. In addition, analgesics and anti-inflammatories were also prescribed to promote post-operative comfort.

Tooth extractions were performed under locoregional anesthesia with 2% mepivacaine with adrenaline as a vasoconstrictor (1 : 100,000) (Mepiadre, DFL, Rio de Janeiro, Brazil), following the principles of minimal trauma with consecutive bone plasty, curettage, irrigation with sterile saline solution, and occlusive suturing of the dental socket. The patients were instructed to clean the area with a chlorhexidine rinse and to return for weekly or monthly follow-ups to evaluate the remodeling process of the tissue.

Eleven teeth were extracted, all of which were residual

Table 1. Characteristics of patients included in this case series

	Patient 1	Patient 2	Patient 3	Patient 4	Patient 5
Sex	Male	Female	Female	Male	Male
Age (years)	67	71	74	60	53
Ethnicity	Black	White	Black	White	Black
Alcohol use	Ex-drinker	Non-drinker	Non-drinker	Non-drinker	Non-drinker
Smoking	Ex-smoker	Ex-smoker	Non-smoker	Ex-smoker	Current smoker
Smoking duration	>40 years	50 years	–	13 years	30 years
SSC location	Nasopharynx	Alveolar ridge	Hard palate	Tongue border	Floor of the mouth
TNM staging	T4N1Mx	T4N2aM0	T4N0M0	T4N1M0	T4N1M0
Oncological treatment	SUR + 3DRT + QT	SUR + RT	SUR + RT + QT	SUR + RT	RT + QT
Total radiation dose	65 Gy	60 Gy	64 Gy	66.4 Gy	70 Gy
Oral sequelae due to cancer treatment	MU, T, DG, RRC, X, DF	MT, MU, T, DG, X, RRC	MT, MU, T, DG, RRC, X	T, MU, DG, RRC, X, DF, ORN	MU, T, DG, X, DF
Time after HNRT	5 years	4 years	4 years	14 years	6 years
Extracted tooth	Lower right first premolar	Lower left central and right lateral incisors	Lower incisors	Lower right central and lateral incisors	Upper left central and lateral incisors
Estimated radiation dose in the tooth extraction area	44.40 Gy	29.68 Gy for the lower left central incisor 38.33 Gy for the lower right lateral incisor	40.87 Gy for the left incisors 31.66 Gy for the right incisors	56.29 Gy	34.62 Gy

SSC: squamous cell carcinoma, TNM: tumor, nodes, and metastases classification of malignant tumors; SUR: surgery, 3DRT: 3-dimensional radiotherapy; QT: chemotherapy, MT: mutilation, MU: mucositis, DF: dysphasia, DG: dysgeusia, T: trismus, RRC: radiation-related caries, X: xerostomia and hyposalivation, ORN: osteoradionecrosis, HNRT: head and neck radiotherapy

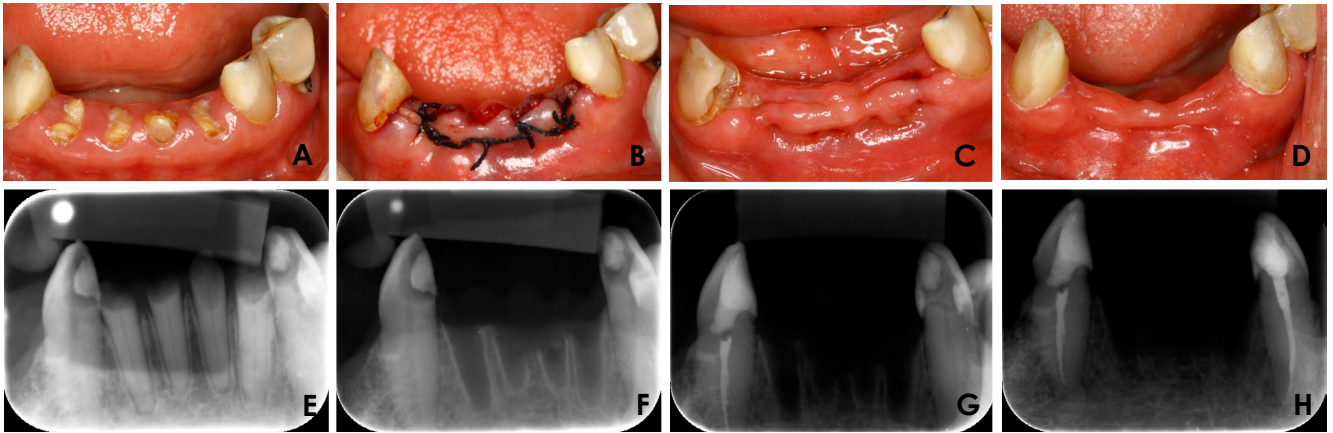


Fig. 1. Clinical photographs. A. Preoperative. B. Immediately after the extraction of the 4 residual roots with subsequent alveoloplasty and occlusive suturing. C. Advanced process of primary intention healing at 7 days postoperatively. D. Complete soft tissue repair 30 days after the surgical procedure without evidence of any area of bone exposure. E. Preoperative digital periapical radiographs. F. Immediately after dental extraction. G. Two months after dental extraction. H. Twelve months after dental extraction. All postoperative images were analyzed to evaluate the average of bone formation.

roots. In 4 patients, the roots were located at the anterior region of the mandible (Fig. 1A), and in the remaining patient, the roots were located at the anterior maxilla. The tooth extraction protocol was followed in all cases, ending with primary suture closure (Fig. 1B). The average visual analog scale (VAS) score for painful symptoms during the 7-day postoperative period was 2.5.

Soft tissue repair was considered adequate when proximity of the wound edge, absence of infection, and minimal edema were observed. Three patients presented an advanced process of primary intention healing at 7 days postoperatively (Fig. 1C), while 2 patients presented with wound dehiscence at the first week's appointment and were rescheduled for a second follow-up visit 15 days after surgery. Complete closure by secondary intention was observed in these 2 patients after 15 days. At the end of the first month of follow-up visits, all patients had complete soft tissue repair (Fig. 1D), without pain or areas of bone exposure.

For bone neoformation analysis, the patients underwent periapical radiography using phosphor plates and the Digora Optime DXR-60 (Soredex Orion Corporation, Helsinki, Finland) digital intraoral system, under conditions of 70 kVp, 7 mA and 0.63 seconds using a periapical X-ray machine (Timex 70E, Gnatus, Ribeirão Preto, Brazil), preoperatively (Fig. 1E), immediately postoperatively (Fig. 1F), and at 2 months (Fig. 1G) and 12 months (Fig. 1H) after the tooth extractions. The radiographic positioners were individualized with silicone bite blocks (Optosil® Comfort Putty, Kulzer GmbH, Hanau, Germany) in order to reproduce the radiographic images in the same position using the paral-

lelism technique. The photostimulable phosphor plates were scanned by the Digora Optime DXR-60 digital radiographic system (Soredex, Tuusula, Finland). The pixel intensity and fractal dimension of each image were analyzed using ImageJ 1.52a (Wayne Rasband, National Institutes of Health, Bethesda, MD, USA).

For the pixel intensity analysis, the region of interest (ROI) was obtained from the immediate postoperative radiographic image (D0) and the images taken 2 months (D2) and 12 months (D12) after tooth extraction. The radiographic density of alveolar bone at each timeframe was measured in the ROI using the histogram analysis function of ImageJ. Gray values ranged from 0 (black) to 255 (white).

The fractal dimension analysis was performed with the aid of a box-counting algorithm developed by White and Rudolph⁷ in the previously determined ROI (Figs. 2A and B). The image was subjected to several filters: Gaussian blur (sigma = 35 pixels) (Fig. 2C), image subtraction obtained from the initial image (Fig. 2D), addition of 128 pixels (Fig. 2E), conversion to a binary image (Fig. 2F), erosion (Fig. 2G), dilation (Fig. 2H), and finally skeletonization (Fig. 2I). The latter demonstrated the trabeculae present in the selected ROI (Fig. 2J).

The results of bone neoformation assessed by pixel intensity and fractal dimension are depicted in Table 2. These data were compared statistically using the paired Student t-test in BioEstat v.5.3 software (Instituto Mamirauá, Amazonas, Brazil). There were no statistically significant differences between D0 and D2 in either pixel intensity or fractal dimension. Furthermore, there was no statistically signifi-




Fig. 2. Fractal dimension analysis. A. Region of interest (ROI) selection in a digital periapical radiographic image immediately after dental extraction. B. Selected ROI. C. ROI after the application of a Gaussian blur filter (sigma = 35 pixels). D. Image resulting from subtracting the blurred ROI from the initial image. E. Image resulting from the addition of 128 pixels. F. Image resulting from conversion to a binary image. G. Image resulting from erosion and dilatation. H. Image resulting from inversion. I. Skeletonization. J. Superimposition onto the initial selected ROI to confirm the trabecular structures.

Table 2. Pixel intensity and fractal dimension data obtained from the analysis of digital periapical radiographs

	Immediate after teeth extraction (D0)	Two months after teeth extraction (D2)	Twelve months after teeth extraction (D12)
Pixel intensity	88.95 ± 34.51	67.20 ± 37.49	41.68 ± 6.69
Fractal dimension	1.09 ± 0.06	1.10 ± 0.09	1.28 ± 0.08*

*: $P < 0.05$ compared with D0 by the Student t-test

cant difference between D0 and D12 for pixel intensity, and the only statistically significant difference for fractal dimension was found between D0 and D12 ($P < 0.05$).

Discussion

Tooth extraction after HNRT is the main event that predisposes patients to ORN.^{1,2} Thus, traditionally, it is recommended that tooth extractions must precede RT as a prevention strategy. However, the retrospective cohort analysis conducted by Beech et al.⁸ pointed out that this measure, instead of being a protective factor, led to ORN in the dental sockets, since these alveoli were not repaired before radiation exposure.

Kuo et al.⁹ observed, in a cohort study, that ORN occurred on average 3 years after HNRT. According to these authors, tooth extractions within the first 6 months post-radiotherapy or during radiotherapy, and extractions involving 5 or fewer dental elements, significantly reduced the incidence of ORN. The results of their study also demonstrated that the risk of developing ORN was higher in patients with poor oral hygiene, periodontal disease, malnutrition, immunodeficiency, and impaired health conditions. HNSCC location and the distribution of the radiation dose may influence the risk of

ORN. Finally, patients who receive a total radiation dose above 60 Gy are at a higher risk of developing ORN.¹⁰

In this case series, all patients received a total dose above 60 Gy. Regarding the HNSCC location and distribution of radiation dose, 3 patients exhibited lesions in lower regions of the oral cavity (mandibular alveolar ridge, tongue, and floor of the mouth). These patients, as well as a fourth patient who had a nasopharyngeal lesion, presented cervical metastasis, and therefore the neck region was irradiated. Both situations led to considerable damage of bone structures of the maxillomandibular complex, especially the mandible. The mandible has higher bone density and less blood supply than the maxilla, which predisposes to a greater risk of ORN.²

The root extractions performed in this study involved mainly premolars and incisors located at the mandible. Mandibular molars within the radiation field present a higher risk of ORN.² The estimated radiation dose¹¹ in the region of the extracted roots was 30 Gy to 60 Gy in this cohort, suggesting that the tooth extraction took place at areas with a moderate to high risk for ORN. Nevertheless, the radiographic findings from digital periapical radiography in this study did not exhibit significant bone formation within 60 days postoperatively. This could be explained by

the impaired bone metabolism of the HNRT patients, which may worsen as the interval between HNRT and extraction increases.¹² In this study, the average interval between HNRT and extraction was 6.6 years (range: 4-14 years), which might have contributed to an increased risk of developing ORN.^{9,12} Thus, these extractions require preventive measures and monitoring.

The first stage of the healing process after tooth extractions begins with the formation of a clot inside the dental socket. Complete closure of the surrounding soft tissue ensures that the clot is retained in the alveolus in order to provide structure for the formation of granulation tissue, which in the future is replaced by new bone tissue.¹³ An occlusive suture was performed after the tooth extraction, and 2 patients presented with dehiscence after 7 days. Despite this, mucosal healing was observed 15 days after surgery in these patients, with no signs of infection or significant painful symptoms, implying that the healing process of the dental socket was adequate.

All measures proposed in the systematic review by Nabil and Samman² were adopted and no case of ORN was diagnosed in this study. Amoxicillin and clindamycin are common antibiotics that can be obtained free of charge in Brazil through the public health system pharmacy service. For patients with dysphagia, the antibiotic in aqueous suspension was prescribed because it allows greater comfort in swallowing, enhancing the patients' adherence with treatment. Some surgical procedures were strenuous because the patients had restricted surgical access and could not remain open-mouthed for prolonged periods due to trismus.

The radiographic findings from digital periapical radiography did not show a statistically significant difference in terms of new bone formation 60 days after tooth extraction. However, a statistically significant difference was observed between the first digital periapical radiographs and those taken 1 year after the tooth extraction. In healthy patients, bone formation after oral surgery can be observed on radiography even within a short period of time (from 6 to 45 days).¹⁴⁻¹⁸ Some studies have suggested that photobiomodulation with a low-level laser may be used to accelerate the bone repair process, with a significant improvement.¹⁴⁻¹⁸

It has been postulated that HNRT negatively affects the trabecular microarchitecture and mandibular bone mass due to hypoxia and fibrotic changes induced by ionizing radiation.¹² However, few studies have demonstrated evidence of such damage through panoramic image evaluations of HNRT patients.^{4,6}

In the present case series, the radiographic analysis indicated that HNRT patients presented a compromised bone

healing process, thus requiring regular follow-up visits, which may lead to early detection of exposed bone that can progress to ORN. No studies have been published regarding the assessment of periapical radiographic or tomographic images for the analysis of bone repair in HNRT patients who undergo tooth extractions.

A few preclinical studies have assessed the influence of photobiomodulation on the repair of bone tissue of irradiated animals after wound induction¹⁹⁻²⁴ or after mandibular distraction osteogenesis.²⁵ Two of these studies evaluated bone formation through radiographic analysis,^{19,25} and considered that ionizing radiation compromises bone regeneration. In animals, this process can be stimulated using low-power laser photobiomodulation or mandibular distraction osteogenesis. However, the bone turnover rate in the studied animals is faster than that of human beings.

Thus, this study reinforced the importance of a strict surgical protocol with clinical monitoring of HNRT patients after tooth extraction, in order to follow up the slow process of bone formation evidenced through the radiographic analysis. Indubitably, there is a lack of knowledge on the process of bone repair in HNRT patients, suggesting the need for further studies with different modalities of imaging examinations and also including adjuvant therapies such as photobiomodulation to contribute to ORN prevention.

Acknowledgments

The authors would like to thank the Interdisciplinary Academic League of Oral Cancer (Liga Interdisciplinar das Neoplasias Bucais - LINB) and the funding agencies Coordenação de Aperfeiçoamento de Pessoal de Nível Superior (CAPES - Brazilian Government) and Programa Unificado de Bolsas de Estudos para Apoio e Formação de Estudantes de Graduação (PUB-Universidade de São Paulo USP) for the scholarships (Samanta Vicente Oliveira and Renata dos Santos Vellei). Finally, we would like to thank Solange Kobayashi-Velasco for the English grammar and style review.

Conflicts of Interest: None

References

1. Chronopoulos A, Zarra T, Ehrenfeld M, Otto S. Osteoradionecrosis of the jaws: definition, epidemiology, staging and clinical and radiological findings. A concise review. *Int Dent J* 2018; 68: 22-30.
2. Nabil S, Samman N. Incidence and prevention of osteoradionecrosis after dental extraction in irradiated patients: a systematic review. *Int J Oral Maxillofac Surg* 2011; 40: 229-43.

3. Notani K, Yamazaki Y, Kitada H, Sakakibara N, Fukuda H, Omori K, et al. Management of mandibular osteoradionecrosis corresponding to the severity of osteoradionecrosis and the method of radiotherapy. *Head Neck* 2003; 25: 181-6.
4. Chan KC, Perschbacher SE, Lam EW, Hope AJ, McNiven A, Atenafu EG, et al. Mandibular changes on panoramic imaging after head and neck radiotherapy. *Oral Surg Oral Med Oral Pathol Oral Radiol* 2016; 121: 666-72.
5. Khojastepour L, Bronoosh P, Zeinalzade M. Mandibular bone changes induced by head and neck radiotherapy. *Indian J Dent Res* 2012; 23: 774-7.
6. Palma LF, Tateno RY, Remondes CM, Marcucci M, Cortes AR. Impact of radiotherapy on mandibular bone: a retrospective study of digital panoramic radiographs. *Imaging Sci Dent* 2020; 50: 31-6.
7. White SC, Rudolph DJ. Alterations of the trabecular pattern of the jaws in patients with osteoporosis. *Oral Surg Oral Med Oral Pathol Oral Radiol Endod* 1999; 88: 628-35.
8. Beech NM, Porceddu S, Batstone MD. Radiotherapy-associated dental extractions and osteoradionecrosis. *Head Neck* 2017; 39: 128-32.
9. Kuo TJ, Leung CM, Chang HS, Wu CN, Chen WL, Chen GJ, et al. Jaw osteoradionecrosis and dental extraction after head and neck radiotherapy: a nationwide population-based retrospective study in Taiwan. *Oral Oncol* 2016; 56: 71-7.
10. Jawad H, Hodson NA, Nixon PJ. A review of dental treatment of head and neck cancer patients, before, during and after radiotherapy: part 2. *Br Dent J* 2015; 218: 69-74.
11. Morais-Faria K, Menegussi G, Marta G, Fernandes PM, Dias RB, Ribeiro AC, et al. Dosimetric distribution to the teeth of patients with head and neck cancer who underwent radiotherapy. *Oral Surg Oral Med Oral Pathol Oral Radiol* 2015; 120: 416-9.
12. Marx RE, Johnson RP. Studies in the radiobiology of osteoradionecrosis and their clinical significance. *Oral Surg Oral Med Oral Pathol* 1987; 64: 379-90.
13. Sculean A, Gruber R, Bosshardt DD. Soft tissue wound healing around teeth and dental implants. *J Clin Periodontol* 2014; 41 Suppl 15: S6-22.
14. Kimura-Fujikami T, Cabrera-Munoz ML, Del Valle-Espinoza A. Laser therapy in orthognathic surgery. *Gac Med Mex* 2005; 141: 27-33.
15. Abd-Elal AZ, El-Mekawii HA, Saafan AM, El Gawad LA, El-Hawary YM, Abdelrazik MA. Evaluation of the effect of low-level diode laser therapy applied during the bone consolidation period following mandibular distraction osteogenesis in the human. *Int J Oral Maxillofac Surg* 2015; 44: 989-97.
16. Refai H, Radwan D, Hassanien N. Radiodensitometric assessment of the effect of pulsed electromagnetic field stimulation versus low intensity laser irradiation on mandibular fracture repair: a preliminary clinical trial. *J Maxillofac Oral Surg* 2014; 13: 451-7.
17. Metin R, Tatli U, Evlice B. Effects of low-level laser therapy on soft and hard tissue healing after endodontic surgery. *Lasers Med Sci* 2018; 33: 1699-706.
18. Mikhail FF, El-Din M, Ibrahim T, Zekry K, Nemat A, Nasry S. Effect of laser therapy on the osseointegration of immediately loaded dental implants in patients under vitamin C, omega-3 and calcium therapy. *Open Access Maced J Med Sci* 2018; 6: 1468-74.
19. Da Cunha SS, Sarmiento V, Ramalho LM, De Almeida D, Veeck EB, Da Costa NP, et al. Effect of laser therapy on bone tissue submitted to radiotherapy: experimental study in rats. *Photomed Laser Surg* 2007; 25: 197-204.
20. Freire MR, Almeida D, Santos JN, Sarmiento VA. Evaluation of bone repair after radiotherapy by photobiomodulation - an animal experimental study. *Laser Phys* 2011; 21: 958.
21. Korany NS, Mehanni SS, Hakam HM, El-Maghraby EM. Evaluation of socket healing in irradiated rats after diode laser exposure (histological and morphometric studies). *Arch Oral Biol* 2012; 57: 884-91.
22. El-Maghraby EM, El-Rouby DH, Saafan AM. Assessment of the effect of low-energy diode laser irradiation on gamma irradiated rats' mandibles. *Arch Oral Biol* 2013; 58: 796-805.
23. Maman Fracher Abramoff M, Pereira MD, de Seixas Alves MT, Segreto RA, Guilherme A, Ferreira LM. Low-level laser therapy on bone repair of rat tibiae exposed to ionizing radiation. *Photomed Laser Surg* 2014; 32: 618-26.
24. Batista JD, Zanetta-Barbosa D, Cardoso SV, Dechichi P, Rocha FS, Pagnoncelli RM. Effect of low-level laser therapy on repair of the bone compromised by radiotherapy. *Lasers Med Sci* 2014; 29: 1913-8.
25. Zhang WB, Zheng LW, Chua D, Cheung LK. Bone regeneration after radiotherapy in an animal model. *J Oral Maxillofac Surg* 2010; 68: 2802-9.