

Foramen transversarium enlargement caused by vertebral artery tortuosity: Diagnosis with cone-beam computed tomography and magnetic resonance angiography

Galal Omami ^{1,*}

¹Division of Oral Medicine, Diagnosis and Radiology, Department of Oral Health Practice, University of Kentucky College of Dentistry, Lexington, USA

ABSTRACT

A markedly enlarged foramen transversarium was discovered incidentally on a cone-beam computed tomography scan of a 72-year-old male patient who was referred for dental implant placement. Further evaluation with magnetic resonance angiography revealed that the foramen enlargement was caused by a tortuosity in the course of the vertebral artery. This case report highlights the importance of recognizing significant incidental findings on diagnostic images and the potential need for additional imaging as part of the complete interpretative process. (*Imaging Sci Dent* 2021; 51: 329-32)

KEY WORDS: Cervical Vertebrae; Cone-Beam Computed Tomography; Magnetic Resonance Angiography

Cone-beam computed tomography (CBCT) scanners, coupled with advances in virtual simulation and computer-guided surgical techniques, have revolutionized diagnostic imaging for the preoperative planning of dental implant placement. Consequently, a growing number of dental patients are being considered for CBCT imaging.¹

Unlike conventional radiographs, CBCT images demonstrate extended coverage of the skull and cervical spine, a factor contributing to a higher prevalence of incidental findings - that is, observations of potential clinical significance that are unrelated to the purpose of the study. The majority of incidental findings reported during the interpretation of CBCT images are associated with the paranasal sinuses, pharyngeal airway, temporomandibular joint, and soft tissues of the neck.^{2,3}

The author reports a rare case of foramen transversarium enlargement due to tortuosity of the vertebral artery discovered incidentally on CBCT and confirmed by magnetic resonance (MR) angiography. This case report underscores the importance of systematically reviewing all images in

CBCT studies for dental implant patients in order to detect significant incidental findings.

Case Report

A 72-year-old man was referred to the oral radiology clinic at the University of Kentucky College of Dentistry for CBCT imaging for dental implant treatment planning. The patient's past medical history was significant for chronic obstructive airway disease, benign prostatic hyperplasia, and arthritis. The CBCT image was taken using i-CAT FLX V-Series (Imaging Sciences, Hatfield, PA, USA) with a 16 cm × 8 cm field of view, 120 kVp, 5 mA, and 3.7 seconds, as per the departmental imaging protocol for pre-implant surgical evaluation. Incidentally, marked enlargement of the right C4 foramen transversarium was noted during the interpretation of the volumetric data set (Fig. 1). Upon questioning, the patient reported no history of previous trauma and no history of cervical symptoms. The enlarged foramen had an ovoid shape with a smooth cortical margin. The transverse diameter was 13 mm and the anterior-posterior diameter was 8 mm (the average normal diameter of the transverse foramen is 6 mm).⁴ Additionally, the cervical spine showed multilevel degenerative changes (Fig. 1B). There was no widening of the adjacent intervertebral foramen.

Received January 6, 2021; Revised February 28, 2021; Accepted March 13, 2021

*Correspondence to : Prof. Galal Omami

Division of Oral Medicine, Diagnosis and Radiology, Department of Oral Health Practice, University of Kentucky College of Dentistry, 800 Rose Street, Room MN-320, Lexington, KY 40536, USA

Tel) 1-859-257-5403, E-mail) Galal.Omami@uky.edu

Copyright © 2021 by Korean Academy of Oral and Maxillofacial Radiology

This is an Open Access article distributed under the terms of the Creative Commons Attribution Non-Commercial License (<http://creativecommons.org/licenses/by-nc/3.0>) which permits unrestricted non-commercial use, distribution, and reproduction in any medium, provided the original work is properly cited.

Imaging Science in Dentistry · pISSN 2233-7822 eISSN 2233-7830

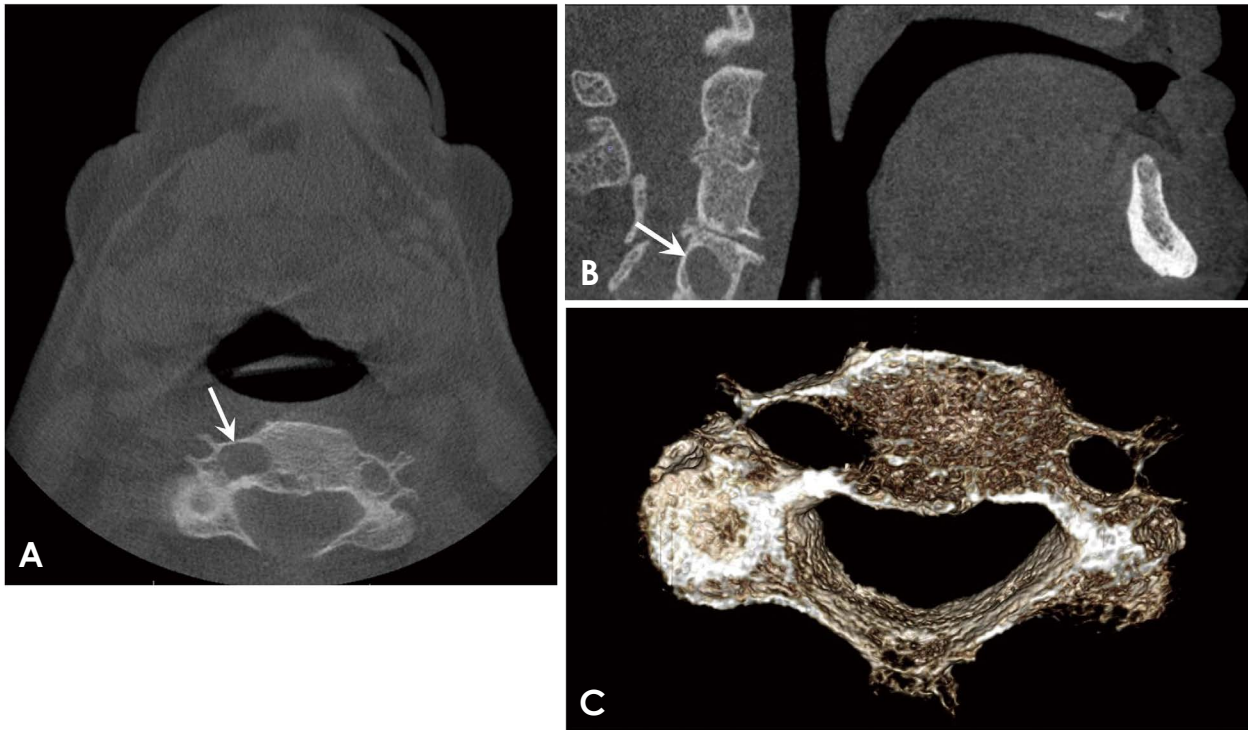


Fig. 1. A. Axial cone-beam computed tomographic (CBCT) image at the level of C4 shows marked enlargement of the right foramen transversarium (arrow). B. Sagittal CBCT image shows smooth enlargement of the right C4 foramen transversarium with a well-defined margin (arrow). Degenerative changes of the cervical spine are also noted. C. Volumetric surface rendering CBCT image of the C4 vertebra with an enlarged right transverse foramen.

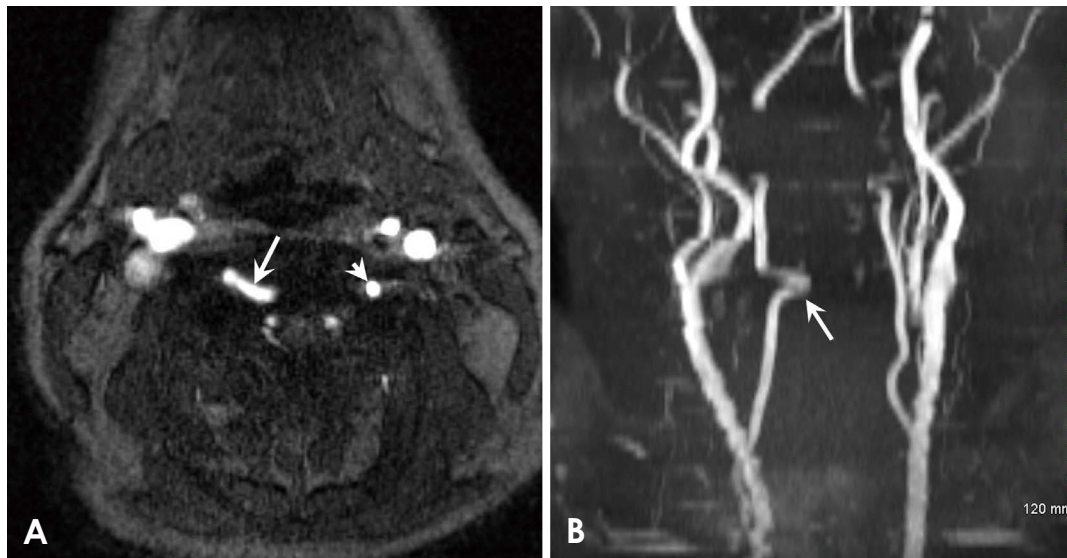


Fig. 2. A. Magnetic resonance (MR) angiogram axial source image shows abnormal tortuosity of the right vertebral artery (arrow). Note the normal vertebral artery on the left side (arrowhead). B. The vertebral artery tortuosity is well seen on this 3-dimensional time-of-flight MR angiogram at maximum intensity projection (arrow).

The oral and maxillofacial radiologist suspected a vascular malformation or dilatation and requested MR angiography of the neck to further evaluate the vertebral artery (Fig. 2).

The MR angiographic imaging was obtained with the 2-dimensional (2D) and 3-dimensional (3D) time-of-flight technique using Magnetom Avanto 1.5-T system (Siemens

Medical Solutions, Erlangen, Germany). The imaging parameters were as follows: time to echo, 2.8 ms; repetition time, 18 ms; flip angle, 20°; field of view, 210 mm; matrix, 256 × 256. The MR angiograms showed a tortuous course of the right vertebral artery at the level of the right C4 transverse foramen, which accounted for the abnormality identified on the CBCT image. There was no evidence of an aneurysm of the vertebral artery.

Discussion

The vertebral artery arises from the subclavian artery and runs cranially via the foramina transversaria of the upper 6 cervical vertebrae to the skull base, and then enters the cranial cavity through the foramen magnum. It supplies the deep muscles of the neck, cervical spinal cord, medulla oblongata, and cerebellum. The 2 vertebral arteries merge at the inferior border of the pons to form the basilar artery.

Variations in the course of the vertebral artery have rarely been reported in the literature. In a study by Paksoy et al.,⁵ foramen transversarium enlargement caused by vertebral artery tortuosity was reported in 7.5% of cases. Vertebral artery loop formations were reported in 31 (7.8%) of 400 angiograms reviewed by Palmer and Sequiera,⁶ most occurring at the level of C4-C5. Men and women were affected equally, and the left side was involved more often than the right.

Vertebral artery loop formation might be the result of degenerative atherosclerosis or cervical arthritic changes. A tortuous vertebral artery may, nonetheless, occasionally represent a congenital anomaly. Vertebral artery tortuosity is generally asymptomatic and is discovered incidentally. However, neurological symptoms may occur secondary to nerve root compression. The transverse foramen and, more commonly, the intervertebral foramen may be enlarged and/or eroded by pressure effects from the tortuous loop of the vertebral artery.⁷⁻⁹

Vertebrobasilar dolichoectasia is a vascular anomaly characterized by elongation, dilatation, and tortuosity of the vertebrobasilar artery. This condition may or may not be associated with compressive symptoms, but the incidence of symptoms appears to correlate with the degree of tortuosity.¹⁰

Aneurysms involving the extracranial part of the vertebral artery are rare, and are often the result of penetrating trauma. Small aneurysms are asymptomatic, but larger ones may present with various neurological deficits depending on the size and location of the lesion.^{11,12}

Enlargement of the foramen transversarium can be caused

by vertebral artery tortuosity or aneurysm. Both conditions may cause smooth enlargement of the foramen with well-defined corticated margins; hence, the diagnosis is established based on angiographic findings rather than osseous changes.⁸

Unenhanced MR angiographic techniques (namely, time-of-flight and phase-contrast angiography) are increasingly being used to avoid the serious complications caused by gadolinium-based contrast materials, such as nephrogenic systemic fibrosis in some patients with renal disease. Time-of-flight angiography is a gradient-echo technique in which the unsaturated blood protons flowing into the imaging plane produce high signal intensities relative to those of the in-plane background stationary tissues saturated by repeated radiofrequency excitations with a short repetition time. Through this technique, 2D or 3D volume acquisitions can be obtained, and 3D time-of-flight angiography is the main modality used to evaluate the intracranial arteries. In contrast, 2D time-of-flight angiography is used for the head and neck arteries, although the quality of images is inferior to that of contrast-enhanced MR angiography.¹³

This case report bears great relevance for clinicians' understanding of the normal anatomy, anatomical variations, and abnormalities of the vertebral artery. All CBCT studies for dental implant patients should be adequately interpreted by a qualified oral and maxillofacial radiologist; this is especially important when a large anatomical area outside the region of interest is included in the scan volume. Significant incidental findings and the potential need for additional imaging should be recognized as part of the complete interpretative process.

Conflicts of Interest: None

References

1. D'haese J, Ackhurst J, Wismeijer D, De Bruyn H, Tahmaseb A. Current state of the art of computer-guided implant surgery. *Periodontol* 2000 2017; 73: 121-33.
2. Price JB, Thaw KL, Tyndall DA, Ludlow JB, Padilla RJ. Incidental findings from cone beam computed tomography of the maxillofacial region: a descriptive retrospective study. *Clin Oral Implants Res* 2012; 23: 1261-8.
3. Edwards R, Alsufyani N, Heo G, Flores-Mir C. The frequency and nature of incidental findings in large-field cone beam computed tomography scans of an orthodontic sample. *Prog Orthod* 2014; 15: 37.
4. Sangari SK, Dossous PM, Heineman T, Mtui EP. Dimensions and anatomical variants of the foramen transversarium of typical cervical vertebrae. *Anat Res Int* 2015; 2015: 391823.
5. Paksoy Y, Levendoglu FD, Ogun CO, Ustun ME, Ogun TC. Vertebral artery loop formation: a frequent cause of cervicobra-

- chial pain. *Spine (Phila Pa 1976)* 2003; 28: 1183-8.
6. Palmer FJ, Sequiera M. Cervical vertebral erosion & vertebral artery tortuosity: an angiographic study. *Australas Radiol* 1980; 24: 20-3.
 7. Freilich M, Virapongse C, Kier EL, Sarwar M, Bhimani S. Foramen transversarium enlargement due to tortuosity of the vertebral artery. Computed tomographic appearance. *Spine (Phila Pa 1976)* 1986; 11: 95-8.
 8. Waldron T, Antoine D. Tortuosity or aneurysm? The palaeopathology of some abnormalities of the vertebral artery. *Int J Osteoarchaeol* 2002; 12: 79-88.
 9. Kim HS, Lee JH, Cheh G, Lee SH. Cervical radiculopathy caused by vertebral artery loop formation: a case report and review of the literature. *J Korean Neurosurg Soc* 2010; 48: 465-8.
 10. Smoker WR, Corbett JJ, Gentry LR, Keyes WD, Price MJ, McKusker S. High-resolution computed tomography of the basilar artery: 2. Vertebrobasilar dolichoectasia: clinical-pathologic correlation and review. *AJNR Am J Neuroradiol* 1986; 7: 61-72.
 11. Shang EK, Fairman RM, Foley PJ, Jackson BM. Endovascular treatment of a symptomatic extracranial vertebral artery aneurysm. *J Vasc Surg* 2013; 58: 1391-3.
 12. Stavrinou LC, Stranjalis G, Stavrinou PC, Bontozoglou N, Sakas DE. Extracranial vertebral artery aneurysm presenting as a chronic cervical mass lesion. *Case Rep Med* 2010; 2010: 938219.
 13. Morita S, Masukawa A, Suzuki K, Hirata M, Kojima S, Ueno E. Unenhanced MR angiography: techniques and clinical applications in patients with chronic kidney disease. *Radiographics* 2011; 31: E13-33.