



# Methemoglobinemia caused by a low dose of prilocaine during general anesthesia

Makiko Shibuya, Takayuki Hojo, Yuri Hase, Yukifumi Kimura, Toshiaki Fujisawa

Department of Dental Anesthesiology, Faculty of Dental Medicine and Graduate School of Dental Medicine, Hokkaido University, Sapporo, Japan

Methemoglobinemia is a blood disorder in which an abnormal amount of methemoglobin is produced, and prilocaine is one of the drugs that can cause this disorder. The maximum recommended dose of prilocaine is 8 mg/kg. We report a case of methemoglobinemia caused by the administration of 4.2 mg/kg of prilocaine without other methemoglobinemia-inducing drugs during general anesthesia. A 17-year-old girl with hyperthyroidism and anemia was scheduled to undergo maxillary sinus floor elevation and tooth extraction. The patient's peripheral oxygen saturation (SpO<sub>2</sub>) decreased from 100% at arrival to 95% after receiving prilocaine with felypressin following induction of general anesthesia. However, the fraction of inspired oxygen was 0.6. Blood gas analysis showed that the methemoglobin level was 3.8% (normal level, 1%–2%), fractional oxygen saturation was 93.9%, partial pressure of oxygen was 327 mmHg, and arterial oxygen saturation was 97.6%. After administration of 1 mg/kg of methylene blue, her SpO<sub>2</sub> improved gradually to 99%, and the methemoglobin value decreased to 1.2%. When using prilocaine as a local anesthetic, it is important to be aware that methemoglobinemia may occur even at doses much lower than the maximum recommended dose.

**Keywords:** Anesthesia, General; Methemoglobinemia; Oximetry; Oxyhemoglobins; Prilocaine.



This is an Open Access article distributed under the terms of the Creative Commons Attribution Non-Commercial License (<http://creativecommons.org/licenses/by-nc/4.0/>) which permits unrestricted non-commercial use, distribution, and reproduction in any medium, provided the original work is properly cited.



## INTRODUCTION

Methemoglobinemia is a condition in which the proportion of methemoglobin (MetHb), which cannot bind and carry oxygen, increases to > 1%–2% of the total hemoglobin [1]. Prilocaine is one of the drugs that cause methemoglobinemia, and a dose  $\leq$  8 mg/kg is recommended for healthy adults [2]. However, there are no definitive criteria regarding the dosage specific to young people. Herein, we report a case of methemoglobinemia during general anesthesia in a teenager, caused by 4.2 mg/kg of prilocaine, which is much lower than the maximum recommended dose, without the

administration of other methemoglobinemia-inducing drugs.

## CASE REPORT

The patient and her mother provided written informed consent to publish this report.

A 17-year-old girl (height, 170.8 cm; weight, 51.2 kg; body mass index, 17.55 kg/m<sup>2</sup>) was scheduled to undergo maxillary sinus floor elevation and tooth removal under general anesthesia. The patient was previously diagnosed with jaw deformity, excessive resorption of the maxillary alveolar ridge, and bilateral impacted mandibular wisdom

Received: May 27, 2021 • Revised: July 9, 2021 • Accepted: July 11, 2021

Corresponding Author: Makiko Shibuya, Department of Dental Anesthesiology, Faculty of Dental Medicine and Graduate School of Dental Medicine, Hokkaido University, Kita 13, Nishi 7, Kita-ku, Sapporo 060-8586, Japan

Tel: +81-11-706-4336 E-mail address: shibu@den.hokudai.ac.jp

Copyright© 2021 Journal of Dental Anesthesia and Pain Medicine

Table 1. Results of laboratory tests

		normal range
Whitebloodcells (per $\text{mm}^3 \times 10^3$ )	5.9	3.3-8.6
Redbloodcells (per $\text{mm}^3 \times 10^6$ )	4.06	3.86-4.92
Hemoglobin (g/dL)	10.2	11.6-14.8
Hematocrit (%)	32.5	35.1-44.4
Platelets (per $\text{mm}^3 \times 10^3$ )	241	158-348
AST (IU/L)	13	13-30
ALT (IU/L)	7	7-23
$\alpha$ -GT (IU/L)	11	9-32
BUN (mg/dL)	11	8.0-20.0
Creatinine (mg/dL)	0.72	0.46-0.79
eGFR (mL/min)	102.1	
TSH ( $\mu\text{IU/mL}$ )	2.85	0.5-5.0
FT3 ( $\mu\text{g/mL}$ )	2.8	2.3-4.0
FT4 (ng/mL)	1.09	0.9-1.7

AST, aspartate aminotransferase; ALT, alanine aminotransferase; BUN, bloodureanitrogen; eGFR, estimated glomerular filtration rate; TSH, thyroid stimulating hormone; FT3, free triiodothyronine; FT4, free thyroxine;  $\gamma$ -GT,  $\gamma$ -glutamyl transpeptidase.

teeth.

At the age of 15 years, the patient was diagnosed with hyperthyroidism which was being treated with 10 mg thiamazole orally. She had no reported drug or food allergies, but reported a history of administration of local anesthetic several times with no complications.

Initially, the surgery was postponed because of complications related to hyperthyroidism. During the preoperative examination, she was in a clinically euthyroid state. Laboratory tests showed a hemoglobin level of 10.2 g/dL (Table 1). No abnormalities were noted on other laboratory tests or chest radiographs. A 12-lead preoperative electrocardiogram showed normal sinus rhythm.

Given her hyperthyroidism, we planned to administer 3% prilocaine containing 0.03 IU/mL felypressin as a local anesthetic to avoid complications that may arise from adrenaline-containing drugs.

Her medications were continued orally until 14 h before surgery. Upon arrival in the operating room, her peripheral oxygen saturation ( $\text{SpO}_2$ ) on room air was 100%. General anesthesia was induced with 100  $\mu\text{g}$  of fentanyl, target-controlled infusion of propofol with an initial target plasma concentration of 5.0  $\mu\text{g/mL}$ , and 30 mg of rocuronium. The patient was intubated using a

Table 2. Blood gas analysis data

	BGA#1	BGA#2	BGA#3
pH	7.408	7.413	7.458
$\text{pCO}_2$ (mmHg)	40.9	40.4	36.7
$\text{pO}_2$ (mmHg)	327	264	182
$\text{sO}_2$ (%)	97.6	98	97.9
$\text{FCO}_2\text{Hb}$ (%)	0	0.1	0.3
FMetHb (%)	3.8	1.2	1.6
$\text{FO}_2\text{Hb}$ (%)	93.9	96.7	96
$\text{FiO}_2$	0.6	0.47	0.47
$\text{SpO}_2$ (%)	95	99	99

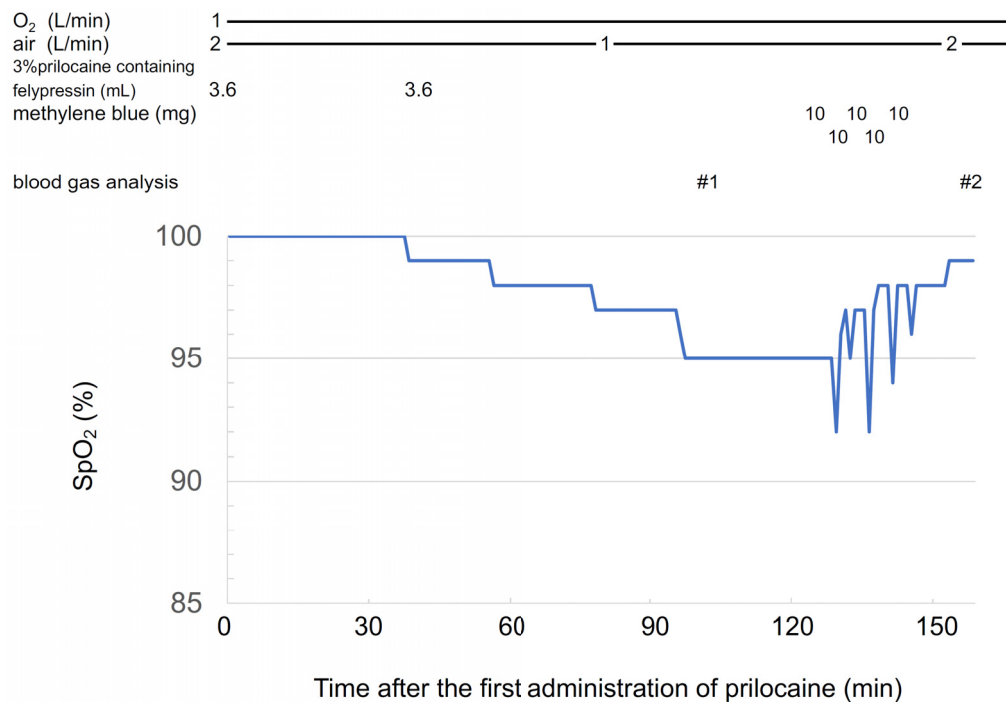
BGA, blood gas analysis;  $\text{FCO}_2\text{Hb}$ , fraction of carboxyhemoglobin;  $\text{FO}_2\text{Hb}$ , fraction of oxygenated haemoglobin; FMetHb, fraction of methaemoglobin;  $\text{FiO}_2$ , fraction of inspiratory oxygen

nasal endotracheal tube. Anesthesia was maintained using an intermittent bolus of fentanyl (total dose was 400  $\mu\text{g}$ ), propofol infusion (target plasma concentration of 2.8–3.2  $\mu\text{g/mL}$ ), and remifentanyl (0.3–0.6 mg/h).

Approximately 61 min after inducing general anesthesia, the patient was administered 3.6 mL prilocaine with felypressin for infiltration anesthesia; the same dose was added 43 min later, which led to a gradual decrease in  $\text{SpO}_2$ , even though the fraction of inspired oxygen was increased to 0.6 (Fig. 1).

Ninety-six minutes after the first administration of prilocaine, the  $\text{SpO}_2$  level decreased to 95%. Blood gas analysis showed that the MetHb value was 3.8% and fractional oxyhemoglobin was 93.9%, despite a partial pressure of oxygen of 327 mmHg (BGA#1 in Table 2). Next, 50 mg of methylene blue was administered slowly, 127 min after the first administration of prilocaine. The  $\text{SpO}_2$  value improved gradually to 99%, and the MetHb value decreased to 1.2% (BGA#2 in Table 2).  $\text{SpO}_2$  remained above 99%, and the MetHb value 2.5 h after the administration of methylene blue was 1.6% (BGA#3 in Table 2). No noteworthy adverse respiratory findings were observed during the perioperative period.

Upon returning to her room, the patient did not present with any symptoms of methemoglobinemia, and  $\text{SpO}_2$  remained above 99% for 2 h under oxygenation with a simple face mask at 3 L/min. After 2 h, she remained asymptomatic, and her  $\text{SpO}_2$  remained at 98% after the oxygen mask was removed. From that point until the next



**Fig. 1.** Changes in SpO<sub>2</sub> after administration of prilocaine. Fifty-three minutes after the second administration of prilocaine, the SpO<sub>2</sub> level decreased to 95%. After 50 mg of methylene blue was gradually administered (in 10-mg doses), the SpO<sub>2</sub> value gradually improved to 99%. The SpO<sub>2</sub> value transiently decreased immediately after the administration of methylene blue and then improved because SpO<sub>2</sub> was affected by the color of methylene blue itself. SpO<sub>2</sub>, peripheral oxygen saturation.

day, her SpO<sub>2</sub> was measured intermittently and remained at 97%–98% on room air. The MetHb value 7 days after surgery was 1.2%, which is within normal limits, and congenital methemoglobinemia was ruled out.

## DISCUSSION

The agents that produce methemoglobinemia include local anesthetics such as prilocaine, benzocaine, and lidocaine, and nitrites such as nitroglycerin and metoclopramide. Reports of similar cases suggest that a combination of two drugs might cause methemoglobinemia [3]. Guay et al. reported that the highest number of incidents of methemoglobinemia due to local anesthetics was caused by benzocaine, followed by prilocaine [1]. It has been reported that the incidence of methemoglobinemia due to prilocaine requiring treatment was 0.008% (2/2431) in pediatric patients [4]. However, the incidence in teenagers or adults is unclear. In this

case, we concluded that methemoglobinemia was caused by prilocaine because 1) prilocaine was the only drug that might have caused methemoglobinemia during general anesthesia, 2) SpO<sub>2</sub> decreased 10 min after the second administration of prilocaine, and 3) congenital methemoglobinemia was ruled out.

When using prilocaine, methemoglobinemia may occur even at a dose much lower than the recommended maximum dose. The recommended maximum dose for healthy adults is 8 mg/kg (600 mg) [2] or 6 mg/kg (400 mg) [5]. Some reports suggest that lower doses should be administered in children and patients with renal failure [1,2,6]. It has also been reported that the dose of prilocaine should be limited to 5 mg/kg for safe use [1] because, in some cases, a dose of 5.0–7.4 mg/kg of prilocaine can cause methemoglobinemia. In the present case, methemoglobinemia occurred at a dose of 216 mg (4.2 mg/kg), although the patient was not a child and did not have renal failure. However, the patient was thin; her body mass index was 17.55 kg/m<sup>2</sup>. Consequently, a dose

of 216 mg corresponded to only 3.4 mg/kg based on a standard body weight of 64.2 kg.

The risk factors for the development of methemoglobinemia while using prilocaine in adults are as follows [1,3,7,8]:

- 1) Renal failure
- 2) Younger age: A previous study reported that the predicted level of MetHb reduced by approximately 0.3% per decade in patients older than 18 years.
- 3) Female sex
- 4) Using a higher concentration of prilocaine
- 5) An environment where prilocaine is easily absorbed: A study reported that direct injection of prilocaine into a bleeding surgical site was a contributing factor.
- 6) Concomitant administration of other oxidizing drugs

The patient presented three of the four factors for increased risk of MetHb formation reported in a prospective observational study [8]: young age, female sex, and high concentration of prilocaine. The cause may also be related to the infiltration of the anesthetic near the maxillary sinus, where blood flow is abundant and drugs are easily absorbed. However, a large inter-individual variability between the dose of prilocaine and the amount of MetHb generated has been reported, and reliable prediction of MetHb formation is difficult [8]. Therefore, it was not possible to determine the cause in this patient.

It has been reported that the MetHb level is approximately 20% in symptomatic patients and approximately 30% in asymptomatic patients before the administration of therapeutic agents [9]. Further, it has been reported that the symptoms of methemoglobinemia can appear earlier and be more severe in patients with anemia, acidosis, respiratory failure, and heart failure [9]. Therefore, these patients must be treated as early as possible. In this case, we administered methylene blue before emergence from anesthesia because 1) the patient was under general anesthesia and the presence or absence of symptoms could not be determined; 2) it was not possible to predict whether the elevation of blood

concentration of MetHb would continue, and how long it would take for MetHb to be metabolized; and 3) a decrease in the reserve respiratory capacity should be avoided during emergence from anesthesia. In addition, we believe that early intervention was appropriate because the patient was anemic with a hemoglobin level of 10.2 g/dL, and had low oxygen-carrying capacity. A study reported that anemic patients might be more sensitive to symptoms of methemoglobinemia because of their lower functional hemoglobin reserve [10]. Ascorbic acid administration can be considered as an alternative treatment. However, the slow onset of action may be problematic [11,12]. If there are no factors that exacerbate methemoglobinemia, such as anemia, oxygen therapy with close monitoring may be preferred. There are no reports describing the criteria for the treatment of methemoglobinemia during general anesthesia. Therefore, additional case reports and studies are required.

When MetHb levels increase, the SpO<sub>2</sub> value, measured by a conventional two-wavelength pulse oximeter, is higher than the actual oxygen saturation, resulting in an underestimation of hypoxemia. This type of pulse oximeter does not consider abnormal hemoglobin, including MetHb, while determining the percentage of oxyhemoglobin. However, conventional pulse oximeters can provide clues for detecting methemoglobinemia [13]. Therefore, when SpO<sub>2</sub> gradually decreases after administration of prilocaine, methemoglobin levels should always be checked even if the dose is small. For the correct diagnosis of methemoglobinemia and accurate evaluation of hypoxemia, a blood gas analysis apparatus including a carbon monoxide oximeter or a multi-wavelength pulse oximeter is needed. These devices can determine MetHb and fractional oxyhemoglobin levels, including the percentage of oxyhemoglobin in all types of hemoglobin, including abnormal hemoglobin.

In conclusion, when using prilocaine as a local anesthetic, clinicians should be aware that methemoglobinemia may occur even at doses lower than the recommended maximum dose.

**AUTHOR ORCID*s*****Makiko Shibuya:** <https://orcid.org/0000-0003-1476-9921>**Takayuki Hojo:** <https://orcid.org/0000-0001-8236-290X>**Yuri Hase:** <https://orcid.org/0000-0002-5306-9808>**Yukifumi Kimura:** <https://orcid.org/0000-0002-7334-5179>**Toshiaki Fujisawa:** <https://orcid.org/0000-0001-8694-232X>**AUTHOR CONTRIBUTIONS****Makiko Shibuya:** Conceptualization, Data curation, Visualization, Writing - original draft, Writing - review & editing**Takayuki Hojo:** Conceptualization, Writing - review & editing**Yuri Hase:** Writing - review & editing**Yukifumi Kimura:** Conceptualization, Writing - review & editing**Toshiaki Fujisawa:** Supervision, Writing - review & editing**DECLARATION OF INTERESTS:** There are no conflicts of interest to declare.**REFERENCES**

1. Guay J. Methemoglobinemia related to local anesthetics: a summary of 242 episodes. *Anesth Analg* 2009; 108: 837-45.
2. Wilburn-Goo D, Lloyd LM. When patients become cyanotic: acquired methemoglobinemia. *J Am Dent Assoc* 1999; 130: 826-31.
3. Hojo T, Kimura Y, Ohiwa D, Fujisawa T. A case of methemoglobinemia thought to have been caused by the combined use of propitocaine and nitroglycerin during general anesthesia. *Anesth Prog* 2020; 67: 170-1.
4. Arslan D, Yıldız G, Şahin MO. The incidence of methemoglobinemia due to prilocaine use in circumcision. *J Urol Surg* 2019; 6: 38-41.
5. Becker DE, Reed KL. Local anesthetics: review of pharmacological considerations. *Anesth Prog* 2012; 59: 90-102.
6. Alanazi MQ. Drugs may be induced methemoglobinemia. *J Hematol Thrombo Dis* 2017; 5: 1-5.
7. Kreutz RW, Kinni ME. Life-threatening toxic methemoglobinemia induced by prilocaine. *Oral Surg Oral Med Oral Pathol* 1983; 56: 480-2.
8. Vasters F, Eberhart L, Koch T, Kranke P, Wulf H, Morin A. Risk factors for prilocaine-induced methaemoglobinemia following peripheral regional anaesthesia. *Eur J Anaesthesiol* 2006; 23: 760-5.
9. Wright RO, Lewander WJ, Woolf AD. Methemoglobinemia: etiology, pharmacology, and clinical management. *Ann Emerg Med* 1999; 34: 646-56.
10. Ash-Bernal R, Wise R, Wright SM. Acquired methemoglobinemia: a retrospective series of 138 cases at 2 teaching hospitals. *Medicine* 2004; 83: 265-73.
11. Lee KW, Park SY. High-dose vitamin C as treatment of methemoglobinemia. *Am J Emerg Med* 2014; 32: 936.
12. Boran P, Tokuc G, Yegin Z. Methemoglobinemia due to application of prilocaine during circumcision and the effect of ascorbic acid. *J Pediatr Urol* 2008; 4: 475-6.
13. Hurford WE, Kratz A. Case 23-2004: a 50-year-old woman with low oxygen saturation. *N Engl J Med* 2004; 351: 380-7.