

Original Article

Clin Shoulder Elbow 2021;24(1):15-20
<https://doi.org/10.5397/cise.2020.00332>

eISSN 2288-8721

Evaluation of acromial spur using ultrasonography

Hyungsuk Kim, Syungkyun Choi, Soo Bin Park, Hyun Seok Song

Department of Orthopedic Surgery, Eunpyeong St. Mary's Hospital, College of Medicine, The Catholic University of Korea, Seoul, Korea

Background: The presence of an acromial spur implies a rotator cuff disorder due to impingement between the acromial spur and the rotator cuff. The purpose of the study was to observe acromial spurs using ultrasonography and to compare measurements between plain radiographs and sonograms.

Methods: We retrospectively enrolled 51 consecutive patients with acromial spurs, which were interpreted on preoperative plain radiographs (supraspinatus outlet view and 30° caudal tilt) and preoperative sonograms. The ultrasonography transducer was held vertically and continuously moved laterally, which corresponded to the long axis of the long head of the biceps. The distance from the most distal margin of the original acromion to the most projected point of the acromial spur was measured.

Results: No significant difference was found between the plain radiograph and ultrasonography measurements ($p=0.186$). A moderate to strong correlation was detected between the ultrasonography and supraspinatus outlet-view measurements ($r=0.776$, $p=0.000$).

Conclusions: Anteriorly projected acromial spurs were well-visualized by ultrasonography. No discrepancy in acromial spur length was detected between the use of plain radiography (supraspinatus outlet view and 30° caudal-tilt view) and ultrasonography. The correlation coefficients between the plain radiography and ultrasonography measurements exceeded 0.7.

Keywords: Shoulder; Acromial spur; Ultrasonography

INTRODUCTION

Acromial spurs are a common finding in patients with shoulder pain and are known to be an extrinsic factor that can trigger rotator cuff disorders [1]. The presence of an acromial spur implies the existence of a rotator cuff disorder due to impingement between the acromial spur and the rotator cuff. Numerous studies have reported a relationship between acromial spurs and rotator cuff disorders and larger acromial spurs are reported to be an important defining factor in success with the diagnosis and treat-

ment of rotator cuff tears in patients with shoulder pain [1-3].

Acromial spurs are usually detected on plain radiographs. Bigliani et al. [1] classified the acromion, based on the shape of its undersurface on supraspinatus outlet-view radiographs, as follows: type I (flat), type II (curved), and type III (hooked). Type III acromion is strongly associated with rotator cuff tears. Kitchel [4] subsequently introduced the 30° caudal-tilt view to evaluate the anterior acromion. Later, Ono et al. [5] reported a close correlation between arthroscopic findings for acromial spur and those obtained using the 30° caudal-tilt view.

Received: December 9, 2020 Revised: January 24, 2021 Accepted: January 24, 2021

Correspondence to: Hyun Seok Song

Department of Orthopedic Surgery, Eunpyeong St. Mary's Hospital, College of Medicine, The Catholic University of Korea, 1021 Tongil-ro, Eunpyeong-gu, Seoul 03312, Korea

Tel: +82-2-2030-4628, Fax: +82-2-2030-4629, E-mail: hssongmd@hanmail.net, ORCID: <https://orcid.org/0000-0002-7844-2293>

IRB approval: Eunpyeong St. Mary's Hospital (No. PIRB-20190801-009).

Financial support: None.

Conflict of interest: None.

Copyright© 2021 Korean Shoulder and Elbow Society. All Rights Reserved.

This is an Open Access article distributed under the terms of the Creative Commons Attribution Non-Commercial License (<http://creativecommons.org/licenses/by-nc/4.0/>) which permits unrestricted non-commercial use, distribution, and reproduction in any medium, provided the original work is properly cited.

Due to its noninvasiveness and cost-effectiveness, ultrasonography is a useful diagnostic method for patients with shoulder pathology [6,7]. Ultrasonography can be used to obtain multiplanar images of fractures around the shoulder joint, while plain radiography only provides a two-dimensional view of the area of interest. Fractures of the coracoid process, greater tuberosity, and scapula are readily detected by ultrasonography, whereas they occasionally go undetected on plain radiographs [8,9]. Acromial spur, by its osseous nature, can also be easily detected using ultrasonography. By offering real-time images and the ability to recreate a shoulder-impingement condition, ultrasonography can provide meaningful clinical information regarding the relationship between the acromial spur and symptoms. However, to our knowledge, no study has yet diagnosed or measured acromial spurs using ultrasonography.

The purpose of the study was therefore to observe acromial spurs using ultrasonography and to compare measurements thereof between plain radiographs and sonograms. A close correspondence between plain radiography and ultrasonography spur measurements was expected. The hypotheses of our study were that the anteriorly projected acromial spurs would be well-visualized by ultrasonography and the lengths of the spur as measured using ultrasonography and plain radiography, respectively, would be comparable.

METHODS

This study protocol was approved by the Institutional Review Board of Eunpyeong St. Mary's Hospital, which waived the requirement for informed consent due to the retrospective nature of the study.

Patient Enrollment

Routine preoperative ultrasonography data from 95 patients who

underwent arthroscopic acromioplasty with rotator cuff repair were retrospectively reviewed. Among these 95 patients, only those patients documented to have confirmed acromial spur on both ultrasonography and plain radiography were enrolled, resulting in a total of 51 consecutive study participants. Patients with fractures, infections, tumors, or labral disorders, including instability, were excluded. All surgeries were performed at a single university hospital by a senior shoulder surgeon.

Radiological Assessment of the Acromial Spur

The acromial spur was analyzed in both the supraspinatus outlet view and the 30° caudal-tilt view on plain radiographs. The length from the anterior acromion to the most projected point of the acromial spur was measured in the supraspinatus outlet view and 30° caudal-tilt view. All measurements were performed by two orthopedic surgeons (HSS and HK) and were made with a picture archiving and communication system (Marosis M-view ver. 5.4; Marotech, Seoul, Korea) (Fig. 1).

Ultrasonography Assessment of the Acromial Spur

Preoperative ultrasonography was performed and real-time images were obtained with a linear 1- to 15-MHz transducer (Philips HD11 XE; Philips Medical Systems, Andover, MA, USA). All ultrasonography examinations were performed by the same senior shoulder surgeon (HSS), with the patient sitting on a chair and the examiner standing behind the patient. During the assessment, the patient's shoulder was positioned in a neutral position, with the elbow flexed and hand supinated, to allow examination of the acromial spur. The transducer was held vertically and continuously moved laterally to medially, which corresponded to a range from the long axis of the long head of the biceps to the short axis of the subscapularis (Fig. 2). The ultrasonography images were saved as videos for analysis.

Still images were obtained when the acromial spur was most

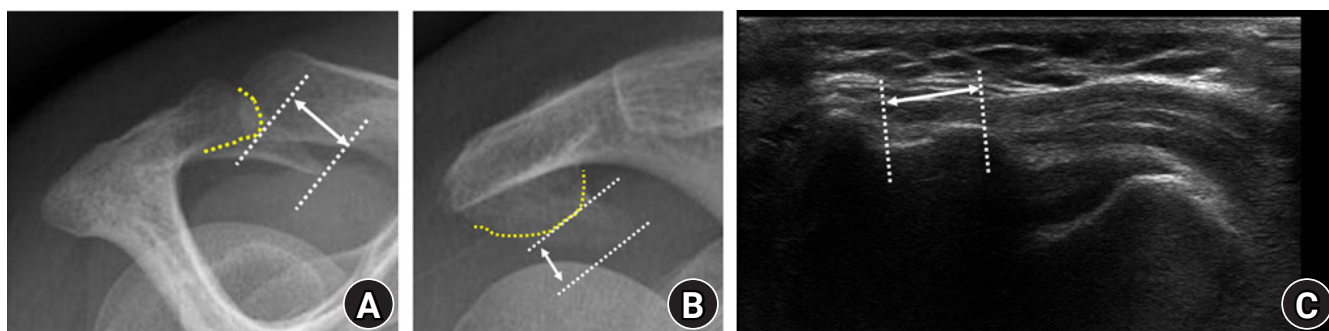


Fig. 1. Right shoulder of a 59-year-old woman. (A) The length (arrow) from the anterior acromion (yellow dotted line) to the most projected point of the acromial spur was measured on supraspinatus outlet-view radiographs. (B) The length (arrow) from the most distal margin of the original acromion (yellow dotted line) to the most projected point of the acromial spur was measured on 30° caudal-tilt view radiographs. (C) Length of the acromial spur (arrow) measured on a sonogram.

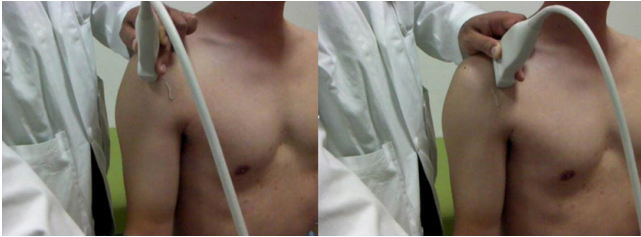


Fig. 2. The transducer was held vertically during ultrasonography and continuously moved laterally to medially, which corresponded to a scan of the long axis of the long head of the biceps to the short axis of the subscapularis.

visible in the ultrasonography videos and the distance from the anterior margin of the acromion to the most distal point of the acromial spur was measured on said still images (Fig. 1C). All measurements were performed by two orthopedic surgeons (HSS and HK), who were blinded to the diagnosis and interpreted the measurements independently of one another.

Statistical Analysis

Repeated-measures analysis of variance was used to compare the supraspinatus outlet view, 30° caudal-tilt view, and ultrasonography measurements of the distance from the anterior margin of the acromion to the most distal point of the acromial spur. The paired t-test was used to compare the measured distances between the supraspinatus outlet view and the 30° caudal-tilt view, the supraspinatus outlet view and sonogram, and the 30° caudal-tilt view and sonogram, respectively. A simple correlation analysis was used also performed to compare the collected measurements between the imaging modalities. IBM SPSS ver. 24.0 (IBM Corp., Armonk, NY, USA) was used for all statistical analyses. Significance levels for all analyses were set at $p < 0.05$.

RESULTS

Patient Demographics

The mean age of the patients was 60.6 years (range, 36–78 years) and 29 of 51 patients were women (56.9%). The dominant shoulder was affected in 42 cases (82.4%). One patient who underwent bilateral surgery was also enrolled, so 52 cases were included in the final analysis.

All patients had at least one pathology in the supraspinatus, subscapularis, and/or long head of the biceps. In total, 48 patients (92.3%) had pathologies in the supraspinatus tendon, including 35 (67.3%) with full-thickness tears and 13 (25%) with partial-thickness tears. Meanwhile, there were 28 patients (53.8%) with pathologies in the subscapularis tendon, including one (1.9%) with a full-thickness tear and 27 (51.9%) with par-

tial-thickness tears. Finally, 28 patients (53.8%) had pathologies in the biceps long head tendon, including six (11.5%) with total tendon rupture and 22 (42.3%) with partial tendon rupture.

Comparison of Measurements

The mean acromial spur length, as measured in the supraspinatus outlet view, was 4.2 ± 3.7 mm, while that in the 30° caudal-tilt view was 4.8 ± 3.9 mm. No significant difference was found between the plain radiograph (supraspinatus outlet view and 30° caudal-tilt view) and ultrasonography measurements ($p = 0.186$); however, a significant difference was found between the two plain radiographs ($p = 0.008$). Meanwhile, no significant difference was found between the ultrasonography and supraspinatus outlet-view measurements ($p = 0.363$) or between the ultrasonography and 30° caudal-tilt view measurements ($p = 0.451$).

A strong correlation was detected between the supraspinatus outlet view and 30° caudal-tilt view measurements ($r = 0.922$, $p = 0.000$), while a moderate to strong correlation was observed between the ultrasonography and supraspinatus outlet-view measurements ($r = 0.776$, $p = 0.000$) and between the ultrasonography and 30° caudal-tilt view measurements ($r = 0.734$, $p = 0.000$). A scattered plot of the plain radiograph and ultrasonography measurements is shown in Fig. 3.

DISCUSSION

In this study, no significant difference was found in the length of the acromial spur when using plain radiography (supraspinatus outlet view and 30° caudal-tilt view) versus ultrasonography. Moreover, a strong correlation was observed between the plain radiography and ultrasonography measurements.

The morphology of the acromion attracted attention following the introduction of impingement theory for rotator cuff tear by Neer [10]. Bigliani et al. [1] classified the acromion by shape and many subsequent studies have since reported that their type III acromion is associated with rotator cuff tears [11,12]. However, the reliability of the classification system by Bigliani et al. [1] remains controversial due to low interobserver reliability and the relatively poor image quality of plain radiographs [13,14].

An acromial spur forms due to traction of the coracoacromial ligament. Although the etiology of rotator cuff tears is unclear, acromial spurs are convincing as a causative factor. Several imaging studies and cadaveric studies have reported acromial spur as a degenerative change that can lead to tearing of the rotator cuff [15-17]. Ogawa et al. [2] classified acromial spurs by length, as measured in the supraspinatus outlet view, and reported that spurs measuring more than 5 mm have diagnostic value for the

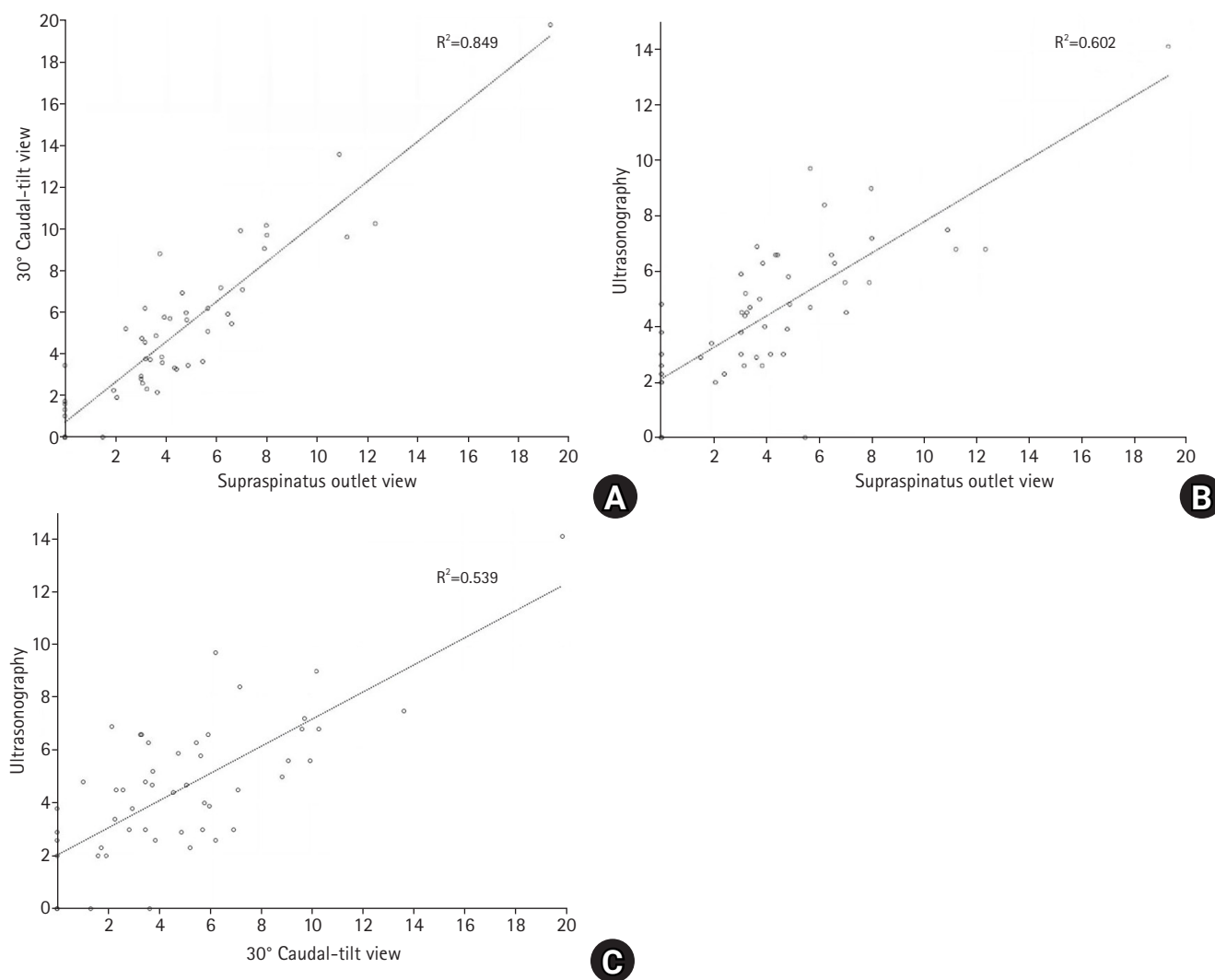


Fig. 3. Scattered plot showing a moderate correlation between plain radiography and ultrasonography measurements. (A) Supraspinatus outlet view and 30° caudal-tilt view. (B) Supraspinatus outlet view and ultrasonography. (C) Thirty-degree caudal-tilt view and ultrasonography.

occurrence of rotator cuff tear. Tucker and Snyder [3] introduced the concept of keel spurs, which resemble a sailboat keel; such spurs may be observed on the undersurface of the acromion on plain radiographs. Further, they theorized that patients with a keel spur are at significant risk of bursal sided partial-thickness and full-thickness rotator cuff tears. For such reasons, acromioplasty is commonly performed during rotator cuff repair and also as a part of subacromial bursectomy [18]. Ono et al. [5] used the 30° caudal-tilt view to evaluate an anteriorly prominent acromial spur. Inferiorly projecting spurs can be visualized more easily by tilting the X-ray beam 30° superior to inferior. Both the supraspinatus outlet view and 30° caudal-tilt view were adopted in this study.

As imaging modalities and arthroscopic techniques have progressed, acromial spurs can now be classified based on computed tomography (CT), magnetic resonance image (MRI), and ar-

throscopic findings. Oh et al. [19] classified acromial spurs based on their shape and thickness revealed by plain radiography and MRI arthrography or CT arthrography. In their study, acromial spurs were classified into six types. The heel spur was the most common type in their rotator cuff tear group; the mean acromial thickness in their cohort was 8.0 mm, but was thicker in the rotator cuff tear group. Kongmalai et al. [20] classified acromial spurs based on 30° caudal-tilt view and arthroscopic findings, where keel spur was the most common finding, followed by heel spur. These authors [20] described patients with either of these spur types as “being at-risk” of a supraspinatus tendon tear. In our study, laterally protruding or medial-type spurs on the short axis of the subscapularis or long axis of the long head of the biceps were not analyzed by ultrasonography. However, anteriorly projected spurs, which are suggested to be a risk factor for rotator cuff tears, were observed and measured on sonograms and plain

radiographs.

Ultrasonography is suitable for detecting and diagnosing soft tissue disorders, including rotator cuff tears [21-23]. Moreover, the ready accessibility and dynamic imaging of ultrasonography render it suitable for diagnosing calcific tendinitis and fractures [24,25]. Calcium deposits appear hyperechoic with or without posterior acoustic shadowing, while fractures appear as an interruption of the smooth cortical surface. Ultrasonography is commonly used to guide injections and more invasive procedures, such as needling and barbotage for treating calcific tendinitis [26,27]. In this study, it was seldom difficult to distinguish between acromial spurs and the coracoacromial ligament. Since ultrasonography provides dynamic images, the study participants were asked to extend or rotate their arm internally or externally. Acromial spurs remained still during movement of the humeral head, different from the coracoacromial ligament, which experienced some movement. This discrepancy helped to differentiate acromial spurs from the coracoacromial ligament. Also, multiplanar images, which ultrasonography provides, helped to identify the shape of the spur and to measure the length.

This study had some limitations. First, there was a degree of measurement bias associated with the picture archiving and communication system, although the mean values of two blinded interpreters were obtained to overcome this. Second, measurement bias also arose from beam projection and magnification errors on the plain radiographs. Third, acromion type—and anatomical variations therein—were not assessed. Fourth, only anteriorly projected spurs were observed on ultrasonography; medial and inferior spurs are difficult to observe using ultrasonography. Fifth, there is a possibility of selection bias as this study was a retrospective investigation and included a relatively small population sample (52 cases). However, all of the ultrasonography examinations were performed by a single surgeon with 10 years of ultrasonography experience and a case volume of 100 cases per month.

Some strengths of this study should also be discussed. First, this is the first study to our knowledge to measure acromial spurs using ultrasonography. This study revealed a correlation between plain radiography and ultrasonography findings. The results suggest that ultrasonography has diagnostic value for confirming rotator cuff disorders having an acromial spur.

Anteriorly projected acromial spurs were well-visualized by ultrasonography. No differences in acromial spur length were detected between on plain radiographs (supraspinatus outlet view and 30° caudal-tilt view) and sonograms. The correlation coefficients between the plain radiographs and ultrasonography measurements exceeded 0.7.

ORCID

Hyungsuk Kim <https://orcid.org/0000-0003-3400-0263>
 Syungkyun Choi <https://orcid.org/0000-0001-6270-4896>
 Soo Bin Park <https://orcid.org/0000-0002-6555-5803>
 Hyun Seok Song <https://orcid.org/0000-0002-7844-2293>

REFERENCES

1. Bigliani LU, Ticker JB, Flatow EL, Soslowky LJ, Mow VC. The relationship of acromial architecture to rotator cuff disease. *Clin Sports Med* 1991;10:823-38.
2. Ogawa K, Yoshida A, Inokuchi W, Naniwa T. Acromial spur: relationship to aging and morphologic changes in the rotator cuff. *J Shoulder Elbow Surg* 2005;14:591-8.
3. Tucker TJ, Snyder SJ. The keeled acromion: an aggressive acromial variant: a series of 20 patients with associated rotator cuff tears. *Arthroscopy* 2004;20:744-53.
4. Kitchel SH. The shoulder impingement syndrome. *Orthop Trans* 1984;8:510.
5. Ono K, Yamamuro T, Rockwood CA Jr. Use of a thirty-degree caudal tilt radiograph in the shoulder impingement syndrome. *J Shoulder Elbow Surg* 1992;1:246-52.
6. Churchill RS, Fehringer EV, Dubimnsky TJ, Matsen FA 3rd. Rotator cuff ultrasonography: diagnostic capabilities. *J Am Acad Orthop Surg* 2004;12:6-11.
7. Naqvi GA, Jadaan M, Harrington P. Accuracy of ultrasonography and magnetic resonance imaging for detection of full thickness rotator cuff tears. *Int J Shoulder Surg* 2009;3:94-7.
8. Botchu R, Lee KJ, Bianchi S. Radiographically undetected coracoid fractures diagnosed by sonography: report of seven cases. *Skeletal Radiol* 2012;41:693-8.
9. McCrady BM, Schaefer MP. Sonographic visualization of a scapular body fracture: a case report. *J Clin Ultrasound* 2011;39:466-8.
10. Neer CS 2nd. Impingement lesions. *Clin Orthop Relat Res* 1983;70-7.
11. MacGillivray JD, Fealy S, Potter HG, O'Brien SJ. Multiplanar analysis of acromion morphology. *Am J Sports Med* 1998;26:836-40.
12. Worland RL, Lee D, Orozco CG, SozaRex F, Keenan J. Correlation of age, acromial morphology, and rotator cuff tear pathology diagnosed by ultrasound in asymptomatic patients. *J South Orthop Assoc* 2003;12:23-6.
13. Jacobson SR, Speer KP, Moor JT, et al. Reliability of radiographic assessment of acromial morphology. *J Shoulder Elbow Surg* 1995;4:449-53.

14. Mayerhoefer ME, Breitensteiner MJ, Wurnig C, Roposch A. Shoulder impingement: relationship of clinical symptoms and imaging criteria. *Clin J Sport Med* 2009;19:83-9.
15. Jim YF, Chang CY, Wu JJ, Chang T. Shoulder impingement syndrome: impingement view and arthrography study based on 100 cases. *Skeletal Radiol* 1992;21:449-51.
16. Liotard JP, Cochard P, Walch G. Critical analysis of the supraspinatus outlet view: rationale for a standard scapular Y-view. *J Shoulder Elbow Surg* 1998;7:134-9.
17. Ozaki J, Fujimoto S, Nakagawa Y, Masuhara K, Tamai S. Tears of the rotator cuff of the shoulder associated with pathological changes in the acromion: a study in cadavera. *J Bone Joint Surg Am* 1988;70:1224-30.
18. Vitale MA, Arons RR, Hurwitz S, Ahmad CS, Levine WN. The rising incidence of acromioplasty. *J Bone Joint Surg Am* 2010;92:1842-50.
19. Oh JH, Kim JY, Lee HK, Choi JA. Classification and clinical significance of acromial spur in rotator cuff tear: heel-type spur and rotator cuff tear. *Clin Orthop Relat Res* 2010;468:1542-50.
20. Kongmalai P, Apivatgaroon A, Chernchujit B. Morphological classification of acromial spur: correlation between Rockwood tilt view and arthroscopic finding. *SICOT J* 2017;3:4.
21. Longo S, Corradi A, Michielon G, Sardanelli F, Sconfienza LM. Ultrasound evaluation of the subacromial space in healthy subjects performing three different positions of shoulder abduction in both loaded and unloaded conditions. *Phys Ther Sport* 2017;23:105-12.
22. Park BK, Hong SH, Jeong WK. Effectiveness of ultrasound in evaluation of fatty infiltration in rotator cuff muscles. *Clin Orthop Surg* 2020;12:76-85.
23. Cho CH, Lee YH, Song KS, Lee KJ, Lee SW, Lee SM. Accuracy of preoperative ultrasonography for cubital tunnel syndrome: a comparison with intraoperative findings. *Clin Orthop Surg* 2018;10:352-7.
24. Chianca V, Albano D, Messina C, et al. Rotator cuff calcific tendinopathy: from diagnosis to treatment. *Acta Biomed* 2018;89:186-96.
25. Hoffman DF, Adams E, Bianchi S. Ultrasonography of fractures in sports medicine. *Br J Sports Med* 2015;49:152-60.
26. Lanza E, Banfi G, Serafini G, et al. Ultrasound-guided percutaneous irrigation in rotator cuff calcific tendinopathy: what is the evidence? A systematic review with proposals for future reporting. *Eur Radiol* 2015;25:2176-83.
27. Messina C, Sconfienza LM. Ultrasound-guided percutaneous irrigation of calcific tendinopathy. *Semin Musculoskelet Radiol* 2016;20:409-13.