

## Review Article



# Choice of LECS Procedure for Benign and Malignant Gastric Tumors

Jae-Seok Min <sup>1</sup>, Kyung Won Seo <sup>2</sup>, Sang-Ho Jeong <sup>3</sup>

<sup>1</sup>Department of Surgery, Dongnam Institute of Radiological and Medical Sciences, Cancer Center, Busan, Korea

<sup>2</sup>Department of Surgery, Kosin University Gospel Hospital, Busan, Korea

<sup>3</sup>Department of Surgery, Gyeongsang National University Changwon Hospital, Gyeongsang National University School of Medicine, Changwon, Korea

## OPEN ACCESS

Received: Jun 6, 2021

Accepted: Jun 21, 2021

### Correspondence to

Sang-Ho Jeong

Department of Surgery, Gyeongsang National University Changwon Hospital, Gyeongsang National University College of Medicine, 11 Samjeongja-ro, Seongsan-gu, Changwon 51472, Korea.

E-mail: jshgnu@gmail.com

Copyright © 2021. Korean Gastric Cancer Association

This is an Open Access article distributed under the terms of the Creative Commons Attribution Non-Commercial License (<https://creativecommons.org/licenses/by-nc/4.0>) which permits unrestricted noncommercial use, distribution, and reproduction in any medium, provided the original work is properly cited.

### ORCID iDs

Jae-Seok Min

<https://orcid.org/0000-0002-5798-4595>

Kyung Won Seo

<https://orcid.org/0000-0002-5771-3832>

Sang-Ho Jeong

<https://orcid.org/0000-0001-9061-6236>

### Author Contributions

Conceptualization: M.J.S., J.S.H., S.K.W.; Investigation: M.J.S., J.S.H., S.K.W.; Methodology: M.J.S., J.S.H.; Project administration: M.J.S., J.S.H.; Resources: M.J.S., J.S.H., S.K.W.; Writing - original draft: M.J.S., J.S.H.; Writing - review & editing: M.J.S., J.S.H., S.K.W.

### Conflict of Interest

No potential conflict of interest relevant to this article was reported.

<https://jgc-online.org>

## ABSTRACT

Laparoscopic endoscopic cooperative surgery (LECS) refers to the endoscopic dissection of the mucosal or submucosal layers with laparoscopic seromuscular resection. We recommend a treatment algorithm for the LECS procedure for gastric benign tumors according to the protruding type. In the exophytic type, endoscopic-assisted wedge resection can be performed. In the endophytic type, endoscopic-assisted wedge resection of the anterior wall is relatively easy to perform, and endoscopic-assisted transgastric resection, laparoscopic-assisted intragastric surgery, or single-incision intragastric resection in the posterior wall and esophagogastric junction (EG Jx) can be attempted. We propose an algorithm for the LECS procedure for early gastric cancer according to the tumor location. The endoscopic submucosal dissection (ESD) procedure can be adapted for all areas of the stomach, and single-incision ESD can be performed in the mid to high body and the EG Jx. In full-thickness gastric resection, laparoscopy-assisted endoscopic full-thickness resection can be adapted for the entire area of the stomach, but it cannot be applied to the pyloric and EG Jx. In conclusion, surgeons need to select the LECS procedure according to tumor type, tumor location, the surgeon's individual experience, and the situation of the institution while also considering the advantages and disadvantages of each procedure.

**Keywords:** Laparoscopy; Endoscopes

## INTRODUCTION

Laparoscopic endoscopic cooperative surgery (LECS) refers to the endoscopic dissection of the mucosal or submucosal layers with laparoscopic seromuscular resection. The LECS procedure was first performed in 2008 by Hiki et al. [1]. Initially, LECS aimed to preserve as much of the normal stomach as possible by efficiently resecting benign tumors. In the early days of LECS, intraoperative endoscopy was also used to evaluate tumor localization [2,3]. As time passed, the endoscopic technique was developed, and gradually, collaborative surgery (endoscopic mucosal resection and endoscopic submucosal dissection [ESD]) was performed [4]. In addition, the procedure for resecting only benign gastric tumors, such as submucosal tumors (SMTs), moved to the stage of resecting malignant tumors, such as early gastric cancer (EGC) [5,6]. Endoscopic full-thickness resection (EFTR) has been performed for curative resection of EGC [4,7,8]. Non-exposure techniques such as non-exposed endoscopic wall-inversion surgery (NEWS) and clean

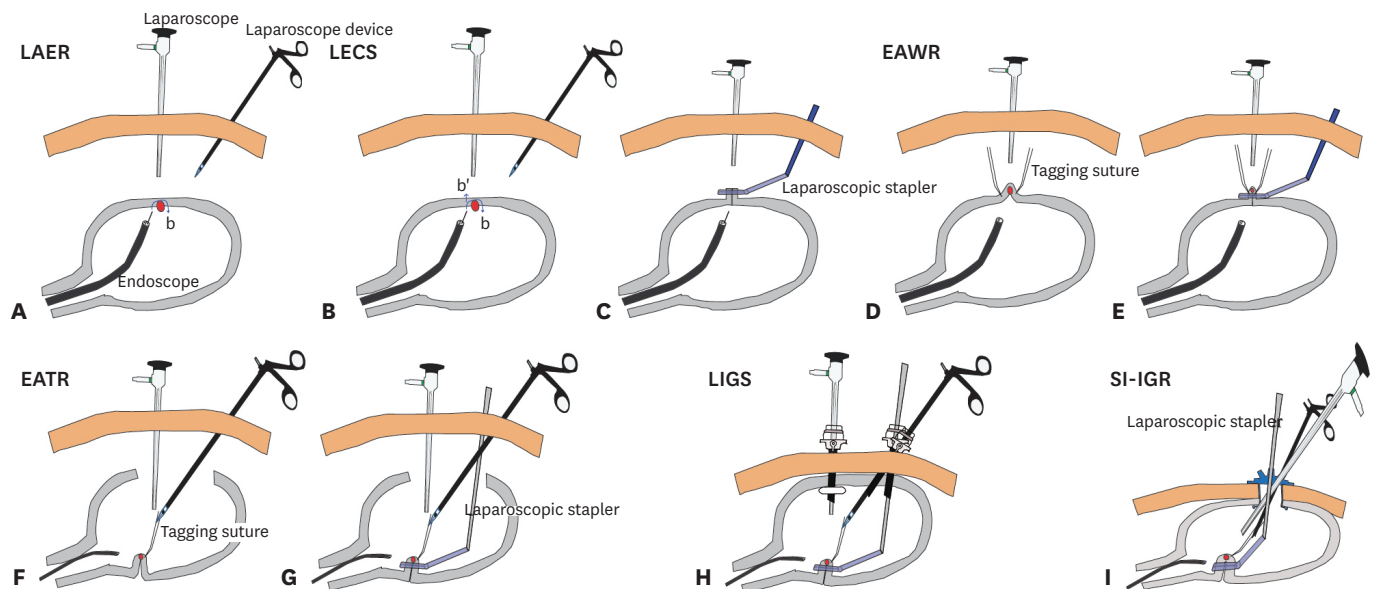
no-exposure technique (clean-NET) have been developed to minimize contamination in the intraperitoneal cavity and cancer cell spillage [9,10].

The aim of this review was to help surgeons select a method suitable for individual institutions by examining and comparing the advantages and disadvantages of each procedure. In this paper, we summarize each of the LECS procedures. The term resection is used to describe endoscopy and laparoscopy procedures that involve major resection. Assisted endoscopy or laparoscopy is not used to perform the main resection procedure, but to observe and perform the procedure if necessary. For example, in laparoscopy-assisted endoscopic resection (LAER), resection is performed mainly by endoscopy and assisted synchronously by laparoscopy. Regarding the procedure times, endoscopic procedures (ESD, EFTR) are assumed to take longer as they require more time than laparoscopic procedures.

## LECS PROCEDURES FOR BENIGN GASTRIC TUMORS

### LAER

LAER is an ESD procedure performed laparoscopically [2,11,12]. ESD or endoscopic muscular dissection is performed in gastric tumors that require removal of the muscle layer, such as SMTs, which have a high perforation risk. If perforation occurs, laparoscopic suture closure can be performed after endoscopic resection. Since LAER is mainly an endoscopic procedure assisted by laparoscopy, it takes longer to remove the tumor than laparoscopic resection. This procedure is recommended for benign endophytic tumors in the stomach (**Fig. 1A**).



**Fig. 1.** LECS procedures for benign gastric tumors. (A) LAER; red circle, benign tumor. (B) LECS; b (blue arrow), the ESD pathway; b', the direction of artificial perforation; (C) Repair with a laparoscopic stapler. (D) EAWR; (E) Tumor resected with a laparoscopic stapler. (F) EATR; (G) Tumor resected with a transgastric laparoscopic stapler. (H) LIGS. (I) SI-IGR.

LECS = laparoscopic endoscopic cooperative surgery; LAER = laparoscopy-assisted endoscopic resection; ESD = endoscopic submucosal dissection; EAWR = endoscope-assisted laparoscopic wedge resection; EATR = endoscope-assisted laparoscopic transgastric resection; LIGS = laparoscopic intragastric surgery; SI-IGR = single-incision intragastric resection.

### LECS

LECS is a classic method that was first reported in Japan [1,13,14]. LECS involves precutting around the tumor with an endoscope (b, blue arrow) and artificial perforation of the gastric wall. Next, excision of the tumor with laparoscopy and repair of the gastric wall with a stapler are performed. LECS usually takes some time because it is an endoscopic procedure, but it does not take too much time because only endoscopic pre-cut is performed. The advantage is that there are no limitations on tumor location. However, there is a risk of spillage into the abdominal cavity, and collaboration with a skilled endoscopist is required (**Fig. 1B and C**).

### Endoscope-assisted laparoscopic wedge resection (EAWR)

The concept of EAWR is contrary to that of LAER [2,12,15-17]. EAWR is performed to remove tumors with a laparoscope after localization by an endoscope during surgery. Since tumors are removed mainly by laparoscopy, EAWR can be performed faster than endoscopic resection. As normal gastric wall tissue can be lost, EAWR is difficult to implement in sites where strictures may occur, such as the esophagogastric junction (EG Jx) and pylorus. The advantage of EAWR is that unlike ESD, it does not require professional endoscopic skills (**Fig. 1D and E**).

### Endoscope-assisted laparoscopic transgastric resection (EATR)

The EATR procedure involves opening the gastric wall under the direct view of an endoscope, tagging the tumor with a laparoscopic suture, and performing wedge resection with a laparoscopic stapler [2,18-22]. The purpose of endoscopy is to assist surgeons in obtaining the proper position when they incise the stomach wall. In addition, endoscopy can play an assisting role in monitoring spillage at the repair site after laparoscopic repair of the resected gastric wall. This procedure does not take as much time as laparoscopy is mainly used. In cases of gastric tumors located at the posterior wall of the stomach, the EG Jx, or pylorus, damage to the vagus nerve or loss of normal gastric wall tissue can be minimized if wedge resection can be used appropriately with endostaplers. However, the disadvantage of EATR is that the spillage of stomach contents can occur; therefore, minimizing this limitation is key (**Fig. 1F and G**).

### Laparoscopic intragastric surgery (LIGS)

If EATR is an open surgery concept in which the stomach wall is opened, LIGS can be used in laparoscopic surgery performed within the stomach [2,15,23-25]. The incision in the gastric wall is minimized, and laparoscopic trocars are inserted into the gastric lumen. After tagging the gastric tumor with a laparoscopic suture, laparoscopic wedge resection is performed with a stapler. Because the endoscope acts like a laparoscope, the operator can see both the endoscopic and the laparoscopic field of views simultaneously. The advantage of an endoscope is that it saves time by cleaning the camera lens itself, whereas a laparoscope cannot. The disadvantage is that it is difficult and time consuming to insert the trocar by piercing the stomach wall again after introducing artificial pneumoperitoneum. In addition, current commercialized trocars have difficulty implementing LIGS. It is recommended to use a balloon trocar because a trocar inserted into the stomach can easily fall out during gastric tumor resection. When using a balloon trocar, it is difficult to insert into the stomach because of the blunt tip, and there is no commercialized 12 mm diameter balloon trocar. The insertion of an additional 12 mm non-balloon trocar is required to insert a laparoscopic stapler. To overcome these limitations, the procedure time may be longer than expected, along with the time required to overcome the learning curve (**Fig. 1H**).

### Single-incision intragastric resection (SI-IGR)

If the gastric wall is the abdominal wall, EATR is an open surgery, LIGS is a laparoscopic surgery, and SI-IGR is a single-port laparoscopic surgery [2,26,27]. In the case of SI-IGR, because there are no obstacles in trocar insertion and fixation (in contrast to LIGS), it can be performed quicker and more conveniently. After forming the pneumoperitoneum through the umbilicus, an incision is made on the front wall of the stomach, and a wound protector is placed to perform the procedure comfortably. In addition, the procedure is more comfortable if an incision is made on the left upper abdomen instead of the umbilicus. However, it is recommended to perform the procedure through the umbilicus for best cosmetic result. The disadvantage is that the devices clash in a narrow space, as in single-port laparoscopic surgery, so it is useful to use a single-port-dedicated device with curvature. The location of the tumor is more advantageous if it is closer to the posterior wall and the EG Jx than the anterior wall. In addition, tumors located in the lower stomach, such as the antrum, are too close to the wound protector, and are difficult to treat because access to the laparoscopic instrument and stapler is not easy due to angulation. Similar to LIGS, wedge resection is performed with a stapler after tagging the tumor with a laparoscopic suture. Therefore, it is expected that less nerve damage occurs when an endophytic type of gastric SMTs is removed. During the removal procedure, an endoscope is not necessarily required. Endoscopy is useful for checking leakage at the repair sites and the stricture of the EG Jx after removal (**Fig. 11**).

### LECS PROCEDURES FOR MALIGNANT GASTRIC TUMORS

All procedures performed to remove malignant gastric tumors include laparoscopic perigastric lymph node dissection (LND). In this article, we focus only on gastric tumor resection and do not describe the contents of lymph node resection.

#### ESD with laparoscopic LND (ESD+LLND)

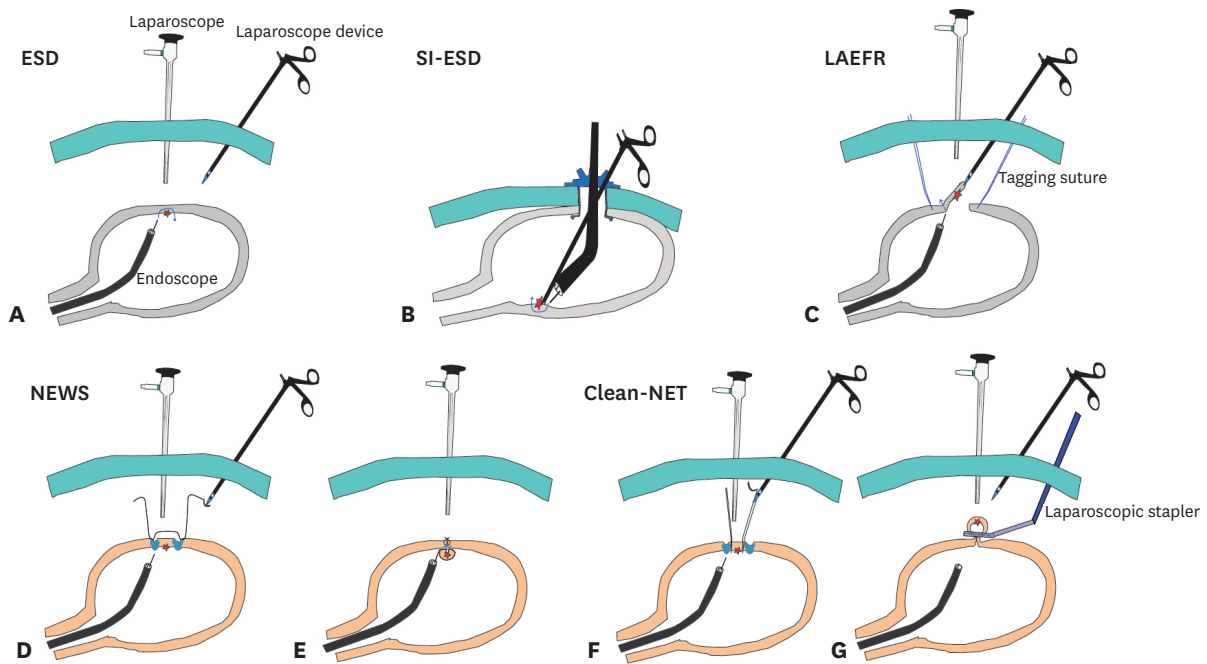
This procedure is the same as LAER with LLND, and the concept is to preserve the stomach if submucosal dissection is performed with endoscopy and if LND is performed with laparoscopy [28-33]. The advantage is that the stomach can be preserved; however, the main procedure is ESD, which requires a skilled endoscopist and is time consuming (**Fig. 2A**).

#### Single-incision endoscopic submucosa dissection (SI-ESD) with LLND

SI-ESD with LLND is similar to SI-IGR, where sentinel node navigation surgery with unilateral perigastric LLND is performed with a single-port, and then ESD is performed through a single-port. Jeong et al. [34-36] reported that ESD performed at the anterior or posterior wall of the stomach required less time than ESD performed at the lesser curvature. In addition, since 2-basin LND induces delayed perforation in 30% of gastric ulcers due to ischemic injury, it is recommended to perform only one-basin LND. The advantage is that it is a quick procedure, as the laparoscopic instrument can be used to assist with a single-port, thus reducing the ESD time by 29%–44%. The disadvantage is that there is a risk of cancer cell spillage because it approaches the stomach wall directly (**Fig. 2B**).

#### Laparoscopy-assisted EFTR (LAEFR)

LAEFR achieves safer EFTR than ESD [3,7,8,37,38]. If the tumor invades deeper than the muscle layer of the gastric wall, full-thickness resection with an endoscope is performed and a laparoscope is used for repair. In 2012, a case of EGC was reported by Nunobe et al. [39]. This technique minimizes cancer spillage by fixing the stomach to the abdominal wall (crown method). When perforation of the gastric wall occurs during endoscopic resection, it becomes difficult to complete the resection due to air leakage. After gastric perforation,



**Fig. 2.** LECS procedures for malignant gastric tumors. (A) ESD with LLND; red star, malignant tumor; blue line, dissection line. (B) SI-ESD with LLND. (C) LAEFR. (D) NEWS; blue area shows the dyed saline injection area after the inversion suture; (E) Tumor resected via endoscopic resection. (F) Clean-NET after laparoscopic seromuscular dissection; (G) Tumor resected with a laparoscopic stapler.  
LECS = laparoscopic endoscopic cooperative surgery; ESD = endoscopic submucosal dissection; LLND = laparoscopic lymph node dissection; SI-ESD = single-incision endoscopic submucosa dissection; LAEFR = laparoscopy-assisted endoscopic full-thickness resection; NEWS = non-exposed endoscopic wall-inversion surgery; Clean-NET = clean no-exposure technique.

the endoscopic field of view is not well secured, and endoscopic resection can take a long time even with the help of a laparoscope. After perforation, there are concerns regarding spillage. The advantage is that LAEFR can be applied to the whole area, even in the EG Jx and pyloric areas because of their exact localizations. The disadvantage of this procedure is the risk of cancer cell leakage and the long procedure time. Cho et al. [40] reported 14 cases in which resection was performed via the same concept as hybrid natural orifice transluminal endoscopic surgery (NOTES). However, 5 of the 14 cases were converted to conventional gastrectomy due to an abnormal anatomical shape, ischemia, and leakage (Fig. 2C).

### NEWS

NEWS was developed so that EFTR could be performed without spillage [41-45]. First, cancer marking with saline injection at the submucosal layer is performed using an endoscope. Subsequently, seromuscular cutting and suturing were performed by laparoscopy to invert the EGC site into the stomach. Finally, removal of EGCs with ESD and repair of the mucosal layer with endoscopic clips or nets are performed. The advantage of this non-exposure technique is that cancer spillage does not occur. The disadvantages are that the procedure time is long, as it involves ESD and endoscopic closure, and it is difficult to apply to the EG Jx and pyloric areas (Fig. 2D and E).

### Clean-NET

Similar to NEWS, clean-NET has also been developed to prevent cancer cell spillage [10,46,47]. First, the localization of EGC is performed with an endoscope, and saline is injected into the submucosal layer. Next, the mucosa is fixed to the muscle layer using a



laparoscopic suture. Then, seromuscular dissection is performed with a laparoscope, and resection of the externally protruding tumor is performed with a laparoscopic stapler. Clean-NET can be applied to EGCs in most locations, except for the EG Jx and pyloric areas. The advantage is that clean-NET is performed mainly by laparoscopy, so the operation time is shorter than that of NEWS. However, gastric perforation can occur, causing leakage depending on the tumor location or skill of the surgeon (Fig. 2F and G).

## COMPARISON OF LECS PROCEDURES AND THE APPROPRIATE CHOICE

### Faster procedure

Compared with endoscopic procedures, laparoscopic procedures are usually faster (Table 1). These techniques include EAWR for benign tumors and SI-ESD with LLND and clean-NET for malignant gastric tumors (Figs. 1 and 2).

### Cleaner and oncologically safer procedure (less spillage)

Methods for removing benign tumors include LAER, EAWR, and SI-IGR. For the removal of malignant tumors, ESD with LLND, SI-ESD with LLND, NEWS, and clean-NET can be implemented without spillage (Table 1, Figs. 1 and 2).

### Proper procedure for EG Jx tumors

ESD at a tumor located in the EG Jx area is difficult because endoscopic manipulation is more difficult in this area than in the gastric low body. The techniques for benign tumor removal in the EG Jx include EATR, LIGS, and SI-IGR (Table 1). For malignant tumors, LAEFR is possible if the EG Jx is not invaded by EGC.

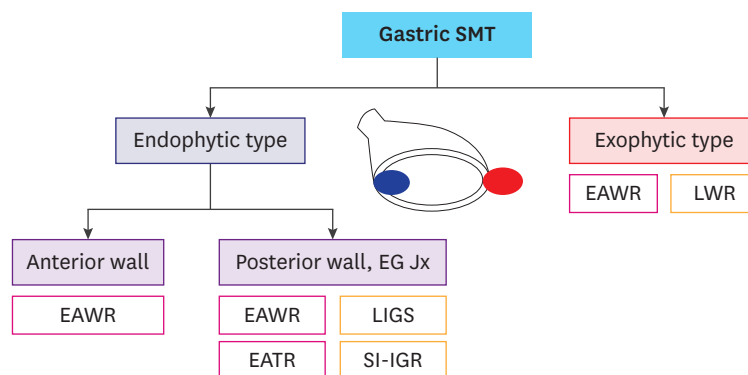
### Proposed algorithms for the LECS procedure without endoscopic skill for gastric SMTs

We proposed algorithms for the LECS procedure for gastric SMTs using the protruding type (Fig. 3). In the case of exophytic gastric SMTs, the laparoscopic wedge or EAWR can be performed without major complications. However, the problem is that the protruding type is not as visible as the endophytic type. In this case, endoscopy-assisted wedge resection

Table 1. Comparison of LECS procedures by 10 questions

Question	LAER/ESD with LLND	LECS	EAWR	EATR	LIGS	SI-IGR/SI-ESD LLND	LAEFR	NEWS	Clean-NET
Concept?	ESD+LA	ESD+LR	EA+LR	EA+LR	EA+LR	EA+LR	EFTR+LA	EFTR+LR	EA+LR
Procedure time?	Long	Moderate	Short	Moderate	Long	Moderate	Long	Long	Short
Applicable tumor location?	Any location	Any location	Mid-high body	Mid-high body PW	Mid-high body PW	Mid-high body PW	Any location	Any location	Any location
Applicability for EG Jx tumor?	+	+	-	+	+	+	+	-	-
Applicability for pyloric tumor?	+	+	-	+	+	-	+	-	-
Spillage risk?	No	Yes	No	Yes	Yes	Minimum	Yes	No	No
Suture requirement?	Yes	Yes	Yes	Yes	Yes	Yes	Yes	Yes	Yes
Possibility of staple only?	No	Sometimes	Yes	No	No	No	No		
Possible for beginner surgeon?	Yes	Yes	Yes	Possible	No	Possible	No	Yes	Possible
Professional endoscopic skill required?	Yes	Yes	No	No	No	No	Yes	Yes	No

LECS = laparoscopic endoscopic cooperative surgery; LAER = laparoscopy-assisted endoscopic resection; ESD = endoscopic submucosal dissection; LLND = laparoscopic lymph node dissection; EAWR = endoscope-assisted laparoscopic wedge resection; EATR = endoscope-assisted laparoscopic transgastric surgery; LIGS = laparoscopic intragastric surgery; SI-IGR = single-incision intragastric resection; SI-ESD = single-incision endoscopic submucosa dissection; LAEFR = laparoscopy-assisted endoscopic full-thickness resection; NEWS = non-exposed endoscopic wall-inversion surgery; Clean-NET = clean no-exposure technique; LA = laparoscopic assistance; LR = laparoscopic resection; EA = endoscopic assistance; EFTR = endoscopic full-thickness resection; EG Jx = esophagogastric junction; PW = posterior wall; + = positive; - = negative.



**Fig. 3.** Proposed algorithm for the LECS procedure for gastric SMTs according to the protruding type. LECS = laparoscopic endoscopic cooperative surgery; SMT = submucosal tumor; EAWR = endoscope-assisted laparoscopic wedge resection; LWR = laparoscopic wedge resection; EATR = endoscope-assisted laparoscopic transgastric resection; LIGS = laparoscopic intragastric surgery; SI-IGR = single-incision intragastric resection; EG Jx = esophagogastric junction.

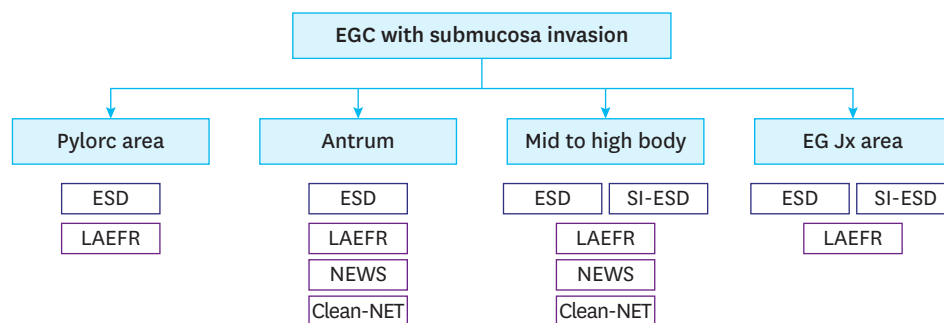
is relatively easy to perform on the anterior wall side, but not on the posterior wall side or near the upper body, especially in the EG Jx. Therefore, if EAWR is difficult to implement, surgeons can try EATR, LIGS, or SI-IGR.

**Proposed algorithms for the LECS procedure for EGC**

We proposed an algorithm for the LECS procedure for EGC according to the tumor location (Fig. 4). The ESD procedure can be adapted for all areas of the stomach, and SI-ESD can be performed in the mid to high body and EG Jx areas. In full-thickness gastric resection, LAEFR can be adapted for the whole stomach, but it cannot be applied to the pyloric and EG Jx areas by NEWS and clean-NET. Additional sentinel node biopsy or LLND is recommended for all procedures.

**DISCUSSION**

The presence of numerous reported procedures proves that there are no definite procedures. For example, there was much interest on NOTES several years ago [9,48], but the interest of surgeons has shifted to single-port laparoscopy due to the slow development of instruments and limitations of technology. Considering cosmetics with few wounds, reduced or single-



**Fig. 4.** Proposed algorithm for the LECS procedure for EGC according to tumor location. LECS = laparoscopic endoscopic cooperative surgery; EGC = early gastric cancer; ESD = endoscopic submucosal dissection; LAEFR = laparoscopy-assisted endoscopic full-thickness resection; NEWS = non-exposed endoscopic wall-inversion surgery; Clean-NET = clean no-exposure technique; SI-ESD = single-incision endoscopic submucosa dissection; EG Jx = esophagogastric junction.

port robotic surgery seems to be preferred compared to NOTES or LECS, which take more time and effort [49-51].

Before starting the LECS procedure, it is necessary for beginners in LECS to become familiar with the procedure by participating in programs such as animal laboratories where the technique is used frequently rather than immediately applying the immature technique to patients [34-36,48]. Before the implementation of a new procedure, an internal medicine endoscopist should be consulted to clarify the simulation of the method, and if necessary, experience through visits to other hospitals is required. It is especially important to check for stricture and leakage with an intraoperative endoscope after the procedure. If a passage disturbance is suspected by endoscopy, conversion to conventional gastrectomy is necessary [40,52]. It is also necessary to first remove benign tumors and then, after accumulating experience, the challenge to remove malignant gastric tumors can be attempted. Additionally, the method of removing EGC tumors with the LECS procedure is still in the clinical study stage, and its oncological safety has not been verified [2,14]. Therefore, it is necessary to inform patients with EGC about the feasibility of LECS and its safety. The authors hope that this review will contribute to the understanding and selection of LECS techniques for individual patients on a case-by-case basis.

In conclusion, surgeons need to select the LECS procedure according to tumor type, tumor location, their own experience, and the situation of the institution while also considering the advantages and disadvantages of each procedure.

## REFERENCES

1. Hiki N, Yamamoto Y, Fukunaga T, Yamaguchi T, Nunobe S, Tokunaga M, et al. Laparoscopic and endoscopic cooperative surgery for gastrointestinal stromal tumor dissection. *Surg Endosc* 2008;22:1729-1735.  
[PUBMED](#) | [CROSSREF](#)
2. Ntourakis D, Mavrogenis G. Cooperative laparoscopic endoscopic and hybrid laparoscopic surgery for upper gastrointestinal tumors: current status. *World J Gastroenterol* 2015;21:12482-12497.  
[PUBMED](#) | [CROSSREF](#)
3. Abe N, Takeuchi H, Yanagida O, Masaki T, Mori T, Sugiyama M, et al. Endoscopic full-thickness resection with laparoscopic assistance as hybrid NOTES for gastric submucosal tumor. *Surg Endosc* 2009;23:1908-1913.  
[PUBMED](#) | [CROSSREF](#)
4. Goto O, Takeuchi H, Kitagawa Y, Yahagi N. Endoscopic submucosal dissection (ESD) and related techniques as precursors of "New Notes" resection methods for gastric neoplasms. *Gastrointest Endosc Clin N Am* 2016;26:313-322.  
[PUBMED](#) | [CROSSREF](#)
5. Caron PH, Martins MI, Bertevello PL. Preliminary analysis of hybrid laparoscopic procedure for resection of gastric submucosal tumors. *Rev Col Bras Cir* 2016;43:129-135.  
[PUBMED](#) | [CROSSREF](#)
6. Tan Y, Tan L, Lu J, Huo J, Liu D. Endoscopic resection of gastric gastrointestinal stromal tumors. *Transl Gastroenterol Hepatol* 2017;2:115.  
[PUBMED](#) | [CROSSREF](#)
7. Kim CG. Endoscopic full-thickness resection combined with laparoscopic surgery. *Clin Endosc* 2018;51:33-36.  
[PUBMED](#) | [CROSSREF](#)
8. Goto O, Takeuchi H, Kitagawa Y, Yahagi N. Endoscopic submucosal dissection (ESD) and related techniques as precursors of "New Notes" resection methods for gastric neoplasms. *Gastrointest Endosc Clin N Am* 2016;26:313-322.  
[PUBMED](#) | [CROSSREF](#)
9. Kim HH, Uedo N. Hybrid NOTES: combined laparo-endoscopic full-thickness resection techniques. *Gastrointest Endosc Clin N Am* 2016;26:335-373.  
[PUBMED](#) | [CROSSREF](#)



10. Inoue H, Ikeda H, Hosoya T, Yoshida A, Onimaru M, Suzuki M, et al. Endoscopic mucosal resection, endoscopic submucosal dissection, and beyond: full-layer resection for gastric cancer with nonexposure technique (CLEAN-NET). *Surg Oncol Clin N Am* 2012;21:129-140.  
[PUBMED](#) | [CROSSREF](#)
11. Abe N, Takeuchi H, Ooki A, Nagao G, Masaki T, Mori T, et al. Recent developments in gastric endoscopic submucosal dissection: towards the era of endoscopic resection of layers deeper than the submucosa. *Dig Endosc* 2013;25 Suppl 1:64-70.  
[PUBMED](#) | [CROSSREF](#)
12. Kato M, Nakajima K, Nishida T, Yamasaki M, Nishida T, Tsutsui S, et al. Local resection by combined laparoendoscopic surgery for duodenal gastrointestinal stromal tumor. *Diagn Ther Endosc* 2011;2011:645609.  
[PUBMED](#) | [CROSSREF](#)
13. Qiu WQ, Zhuang J, Wang M, Liu H, Shen ZY, Xue HB, et al. Minimally invasive treatment of laparoscopic and endoscopic cooperative surgery for patients with gastric gastrointestinal stromal tumors. *J Dig Dis* 2013;14:469-473.  
[PUBMED](#) | [CROSSREF](#)
14. Matsuda T, Hiki N, Nunobe S, Aikou S, Hirasawa T, Yamamoto Y, et al. Feasibility of laparoscopic and endoscopic cooperative surgery for gastric submucosal tumors (with video). *Gastrointest Endosc* 2016;84:47-52.  
[PUBMED](#) | [CROSSREF](#)
15. Hiki N, Nunobe S, Matsuda T, Hirasawa T, Yamamoto Y, Yamaguchi T. Laparoscopic endoscopic cooperative surgery. *Dig Endosc* 2015;27:197-204.  
[PUBMED](#) | [CROSSREF](#)
16. Novitsky YW, Kercher KW, Sing RF, Heniford BT. Long-term outcomes of laparoscopic resection of gastric gastrointestinal stromal tumors. *Ann Surg* 2006;243:738-745.  
[PUBMED](#) | [CROSSREF](#)
17. Ye X, Yu J, Kang W, Ma Z, Xue Z. Short- and long-term outcomes of endoscope-assisted laparoscopic wedge resection for gastric submucosal tumors adjacent to esophagogastric junction. *J Gastrointest Surg* 2018;22:402-413.  
[PUBMED](#) | [CROSSREF](#)
18. Huang JL, Zheng ZH, Wei HB, Chen TF, Liu JP, Huang Y, et al. Endoscopy-assisted laparoscopic resections for gastric gastrointestinal stromal tumors: a retrospective study. *J Laparoendosc Adv Surg Tech A* 2017;27:110-114.  
[PUBMED](#) | [CROSSREF](#)
19. Wilhelm D, von Delius S, Burian M, Schneider A, Frimberger E, Meining A, et al. Simultaneous use of laparoscopy and endoscopy for minimally invasive resection of gastric subepithelial masses - analysis of 93 interventions. *World J Surg* 2008;32:1021-1028.  
[PUBMED](#) | [CROSSREF](#)
20. Basso N, Rosato P, De Leo A, Picconi T, Trentino P, Fantini A, et al. Laparoscopic treatment of gastric stromal tumors. *Surg Endosc* 2000;14:524-526.  
[PUBMED](#) | [CROSSREF](#)
21. DE-Quadros LG, Kaiser-Junior RL, Campos JM, Felix VN, Flamini-Junior M, Vecchi M, et al. Laparoendoscopic transgastric resection of subepithelial juxtacardiac tumors. *Arq Bras Cir Dig* 2017;30:143-146.  
[PUBMED](#) | [CROSSREF](#)
22. Ma JJ, Hu WG, Zang L, Yan XW, Lu AG, Wang ML, et al. Laparoscopic gastric resection approaches for gastrointestinal stromal tumors of stomach. *Surg Laparosc Endosc Percutan Tech* 2011;21:101-105.  
[PUBMED](#) | [CROSSREF](#)
23. Mahajan NN, Singh Nagpal SJ, Wong Kee Song LM, Blackmon SH. Laparoendoscopic transgastric resection of prepyloric gastrointestinal stromal tumor. *Innovations (Phila)* 2019;14:66-68.  
[PUBMED](#) | [CROSSREF](#)
24. Tagaya N, Mikami H, Kogure H, Kubota K, Hosoya Y, Nagai H. Laparoscopic intragastric stapled resection of gastric submucosal tumors located near the esophagogastric junction. *Surg Endosc* 2002;16:177-179.  
[PUBMED](#) | [CROSSREF](#)
25. Privette A, McCahill L, Borrazzo E, Single RM, Zubarik R. Laparoscopic approaches to resection of suspected gastric gastrointestinal stromal tumors based on tumor location. *Surg Endosc* 2008;22:487-494.  
[PUBMED](#) | [CROSSREF](#)
26. Lamm SH, Steinemann DC, Linke GR, Eucker D, Simon T, Zerz A, et al. Total inverse transgastric resection with transoral specimen removal. *Surg Endosc* 2015;29:3363-3366.  
[PUBMED](#) | [CROSSREF](#)

27. Na JU, Lee SI, Noh SM. The single incision laparoscopic intragastric wedge resection of gastric submucosal tumor. *J Gastric Cancer* 2011;11:225-229.  
[PUBMED](#) | [CROSSREF](#)
28. Choi CI, Lee SH, Hwang SH, Kim DH, Jeon TY, Kim DH, et al. Single-incision intragastric resection for upper and mid gastric submucosal tumors: a case-series study. *Ann Surg Treat Res* 2014;87:304-310.  
[PUBMED](#) | [CROSSREF](#)
29. Abe N, Mori T, Takeuchi H, Yoshida T, Ohki A, Ueki H, et al. Laparoscopic lymph node dissection after endoscopic submucosal dissection: a novel and minimally invasive approach to treating early-stage gastric cancer. *Am J Surg* 2005;190:496-503.  
[PUBMED](#) | [CROSSREF](#)
30. Li H, Zhao LL, Zhang XC, Liu DX, Wang GY, Huo ZB, et al. Combination of endoscopic submucosal dissection and laparoscopic sentinel lymph node dissection in early mucinous gastric cancer: Role of lymph node metastasis. *World J Clin Cases* 2020;8:3474-3482.  
[PUBMED](#) | [CROSSREF](#)
31. Bok GH, Kim YJ, Jin SY, Chun CG, Lee TH, Kim HG, et al. Endoscopic submucosal dissection with sentinel node navigation surgery for early gastric cancer. *Endoscopy* 2012;44:953-956.  
[PUBMED](#) | [CROSSREF](#)
32. Eom BW, Yoon HM, Min JS, Cho I, Park JH, Jung MR, et al. Prospective multicenter feasibility study of laparoscopic sentinel basin dissection after endoscopic submucosal dissection for early gastric cancer: SENORITA 2 trial protocol. *J Gastric Cancer* 2019;19:157-164.  
[PUBMED](#) | [CROSSREF](#)
33. An JY, Min JS, Hur H, Lee YJ, Cho GS, Park YK, et al. Laparoscopic sentinel node navigation surgery versus laparoscopic gastrectomy with lymph node dissection for early gastric cancer: short-term outcomes of a multicentre randomized controlled trial (SENORITA). *Br J Surg* 2020;107:1429-1439.  
[PUBMED](#) | [CROSSREF](#)
34. Park JY, Kim YW, Ryu KW, Nam BH, Lee YJ, Jeong SH, et al. Assessment of laparoscopic stomach preserving surgery with sentinel basin dissection versus standard gastrectomy with lymphadenectomy in early gastric cancer-A multicenter randomized phase III clinical trial (SENORITA trial) protocol. *BMC Cancer* 2016;16:340.  
[PUBMED](#) | [CROSSREF](#)
35. Jeong SH, Lee YJ, Yoo MW, Park ST, Choi SK, Hong SC, et al. Comparison of hybrid natural orifice transluminal endoscopic surgery and single-port laparoscopic surgery for sentinel node basin dissection in a porcine model. *J Laparoendosc Adv Surg Tech A* 2012;22:132-138.  
[PUBMED](#) | [CROSSREF](#)
36. Jeong SH, Park JH, Yoo MW, Choi SK, Hong SC, Jung EJ, et al. Feasibility of the trans-umbilical route compared with the trans-oral route in gastric upper body endoscopic submucosal dissection: a porcine model. *Surg Endosc* 2014;28:515-523.  
[PUBMED](#) | [CROSSREF](#)
37. Jeong SH, Min JS, Park JH, Hong SC, Jung EJ, Ju YT, et al. Safety and location analysis of transumbilical endoscopic submucosal dissection with single-basin lymph node dissection in the upper gastric body: a porcine model. *Surg Endosc* 2020;34:590-597.  
[PUBMED](#) | [CROSSREF](#)
38. Lim SG, Hur H, Han SU, Lee KM, Kang JK, Shin SJ, et al. Laparoscopy-assisted endoscopic full-thickness resection for gastric subepithelial tumors originated from the muscularis propria layer: a pilot study with literature review. *Scand J Gastroenterol* 2017;52:257-263.  
[PUBMED](#) | [CROSSREF](#)
39. Mahawongkajit P, Chanswangphuvana P. Laparoscopy-assisted endoscopic full-thickness resection of upper gastrointestinal subepithelial tumors: a single-center early experience. *Mol Clin Oncol* 2020;12:461-467.  
[PUBMED](#) | [CROSSREF](#)
40. Kim CG. Endoscopic full-thickness resection combined with laparoscopic surgery. *Clin Endosc* 2018;51:33-36.  
[PUBMED](#) | [CROSSREF](#)
41. Nunobe S, Hiki N, Gotoda T, Murao T, Haruma K, Matsumoto H, et al. Successful application of laparoscopic and endoscopic cooperative surgery (LECS) for a lateral-spreading mucosal gastric cancer. *Gastric Cancer* 2012;15:338-342.  
[PUBMED](#) | [CROSSREF](#)
42. Cho WY, Kim YJ, Cho JY, Bok GH, Jin SY, Lee TH, et al. Hybrid natural orifice transluminal endoscopic surgery: endoscopic full-thickness resection of early gastric cancer and laparoscopic regional lymph node dissection-14 human cases. *Endoscopy* 2011;43:134-139.  
[PUBMED](#) | [CROSSREF](#)

43. Mitsui T, Goto O, Shimizu N, Hatao F, Wada I, Niimi K, et al. Novel technique for full-thickness resection of gastric malignancy: feasibility of nonexposed endoscopic wall-inversion surgery (news) in porcine models. *Surg Laparosc Endosc Percutan Tech* 2013;23:e217-e221.  
[PUBMED](#) | [CROSSREF](#)
44. Eom BW, Kim CG, Kook MC, Yoon HM, Ryu KW, Kim YW, et al. Non-exposure simple suturing endoscopic full-thickness resection with sentinel basin dissection in patients with early gastric cancer: the SENORITA 3 pilot study. *J Gastric Cancer* 2020;20:245-255.  
[PUBMED](#) | [CROSSREF](#)
45. Goto O, Mitsui T, Fujishiro M, Wada I, Shimizu N, Seto Y, et al. New method of endoscopic full-thickness resection: a pilot study of non-exposed endoscopic wall-inversion surgery in an ex vivo porcine model. *Gastric Cancer* 2011;14:183-187.  
[PUBMED](#) | [CROSSREF](#)
46. Goto O, Takeuchi H, Kawakubo H, Matsuda S, Kato F, Sasaki M, et al. Feasibility of non-exposed endoscopic wall-inversion surgery with sentinel node basin dissection as a new surgical method for early gastric cancer: a porcine survival study. *Gastric Cancer* 2015;18:440-445.  
[PUBMED](#) | [CROSSREF](#)
47. Mahawongkajit P, Techagumpuch A, Suthiwartnarueput W. Non-exposed endoscopic wall-inversion surgery for a gastrointestinal stromal tumor of the stomach: a case report. *Oncol Lett* 2017;14:4746-4750.  
[PUBMED](#) | [CROSSREF](#)
48. Kanehira E, Kanehira AK, Tanida T, Takahashi K, Obana Y, Sasaki K. Clean-NET: a modified laparoendoscopic wedge resection of the stomach to minimize the sacrifice of innocent gastric wall. *Surg Endosc* 2020;34:290-297.  
[PUBMED](#) | [CROSSREF](#)
49. Kato M, Uraoka T, Isobe Y, Abe K, Hirata T, Takada Y, et al. A case of gastric adenocarcinoma of fundic gland type resected by combination of laparoscopic and endoscopic approaches to neoplasia with non-exposure technique (clean-NET). *Clin J Gastroenterol* 2015;8:393-399.  
[PUBMED](#) | [CROSSREF](#)
50. Kalloo AN, Singh VK, Jagannath SB, Niiyama H, Hill SL, Vaughn CA, et al. Flexible transgastric peritoneoscopy: a novel approach to diagnostic and therapeutic interventions in the peritoneal cavity. *Gastrointest Endosc* 2004;60:114-117.  
[PUBMED](#) | [CROSSREF](#)
51. Seo WJ, Son T, Roh CK, Cho M, Kim HI, Hyung WJ. Reduced-port totally robotic distal subtotal gastrectomy with lymph node dissection for gastric cancer: a modified technique using Single-Site® and two additional ports. *Surg Endosc* 2018;32:3713-3719.  
[PUBMED](#) | [CROSSREF](#)
52. Song JH, Son T, Lee S, Choi S, Cho M, Kim YM, et al. D2 lymph node dissections during reduced-port robotic distal subtotal gastrectomy and conventional laparoscopic surgery performed by a single surgeon in a high-volume center: a propensity score-matched analysis. *J Gastric Cancer* 2020;20:431-441.  
[PUBMED](#) | [CROSSREF](#)
53. Seo WJ, Son T, Shin H, Choi S, Roh CK, Cho M, et al. Reduced-port totally robotic distal subtotal gastrectomy for gastric cancer: 100 consecutive cases in comparison with conventional robotic and laparoscopic distal subtotal gastrectomy. *Sci Rep* 2020;10:16015.  
[PUBMED](#) | [CROSSREF](#)
54. Park JH, Jeong SH, Lee YJ, Kim TH, Kim JM, Kim DH, et al. Safety and efficacy of post-anastomotic intraoperative endoscopy to avoid early anastomotic complications during gastrectomy for gastric cancer. *Surg Endosc* 2020;34:5312-5319.  
[PUBMED](#) | [CROSSREF](#)