

## Bone changes in the mandibular incisors after orthodontic correction of dental crowding without extraction: A cone-beam computed tomographic evaluation

Claudia Scigliano Valerio<sup>1,\*</sup>, Cláudia Assunção e Alves Cardoso<sup>2</sup>, Eustáquio Afonso Araújo<sup>3,4</sup>, Elton Gonçalves Zenóbio<sup>5</sup>, Flávio Ricardo Manzi<sup>2</sup>

<sup>1</sup>Department of Orthodontics, Faculdade Arnaldo, Belo Horizonte, Brazil

<sup>2</sup>Department of Oral Radiology, Pontifical Catholic University of Minas Gerais, Belo Horizonte, Brazil

<sup>3</sup>Department of Orthodontics, Saint Louis University, St. Louis, MO, USA

<sup>4</sup>Ciências Médicas Postgraduate Program, Belo Horizonte, Brazil

<sup>5</sup>Department of Dentistry, Pontifícia Universidade Católica de Minas Gerais, Belo Horizonte, MG, Brazil

### ABSTRACT

**Purpose:** This study aimed to evaluate changes of the alveolar bone and interdental bone septum of the mandibular incisors through cone-beam computed tomography (CBCT) after orthodontic treatment of mandibular dental crowding without dental extraction.

**Materials and Methods:** The sample consisted of 64 CBCT images (32 pre-treatment and 32 post-treatment) from 32 adult patients with class I malocclusion and an average age of  $23.0 \pm 3.9$  years. The width and height of the alveolar bone and interdental septum, the distance between the cemento-enamel junction (CEJ) and the facial and lingual bone crests, and the inclination of the mandibular incisors were measured.

**Results:** The distance between the CEJ and the marginal bone crest on the facial side increased significantly ( $P < 0.05$ ). An increased distance between the CEJ and the bone crest on the facial and lingual sides showed a correlation with the irregularity index ( $P < 0.05$ ); however, no significant association was observed with increasing mandibular incisor inclination ( $P > 0.05$ ). The change in the distance between the CEJ and the marginal bone crest on the facial side was correlated significantly with bone septum height ( $P < 0.05$ ).

**Conclusion:** Bone dehiscence developed during the treatment of crowding without extraction only on the incisors' facial side. Increasing proclination of the mandibular incisor was not correlated with bone dehiscence. The degree of dental crowding assessed through the irregularity index was associated with the risk of developing bone dehiscence. The interdental septum reflected facial marginal bone loss in the mandibular incisors. (*Imaging Sci Dent* 2021; 51: 155-65)

**KEY WORDS:** Tooth Movement Techniques; Alveolar Bone Loss; Cone-Beam Computed Tomography

### Introduction

Dental crowding represents the most prevalent type of malocclusion in the world.<sup>1</sup> The third National Health and Nutrition Examination Survey, conducted in the United States between 1988 and 1994, showed that the adult population presented a high prevalence (45%) of significant to

severe dental irregularities.<sup>2</sup> In addition, dental crowding represents one of the main complaints about orthodontic treatment, as it affects aesthetic self-perception and individuals' quality of life.<sup>3,4</sup>

Mandibular dental crowding may be treated orthodontically without extraction by expanding the dental arch, molar distalization, and interdental enamel reduction, or by dental extraction. Facial-lingual tooth movement may occur in any of these approaches, and this movement has side effects, such as the development of fenestration, bone dehiscence, and gingival recession, illustrated in studies that reported these phenomena to be 5.8%-11.5% more frequent in the ortho-

This project was supported by the Foundation of Research Support for the State of Minas Gerais (FAPEMIG), and CAPES Foundation (Finance Code 001).  
Received September 21, 2020; Revised December 16, 2020; Accepted January 12, 2021  
\*Correspondence to : Prof. Claudia Scigliano Valerio  
Department of Orthodontics, School of Dentistry, Faculdade Arnaldo, Rua Vitorino Marçola, 360, CEP: 30310-360, Belo Horizonte, Minas Gerais, Brazil  
Tel) 55-31-3524-5204, E-mail) csvortodontia@live.com

dontic-treated group.<sup>5-7</sup> These side effects were tested by some authors in experimental studies performed in animals and in observational studies conducted in human beings; nevertheless, the results are controversial. In animal experiments, some authors verified that the increase in the mandibular incisors' facial inclination induced by orthodontic appliances resulted in facial alveolar bone loss, producing dehiscence and/or fenestration and gingival recession;<sup>8-10</sup> however, another experimental study with monkeys did not find the same results.<sup>11</sup> In observational studies in human beings, some authors detected an association between changes in the facial inclination of the mandibular incisor obtained with orthodontic appliances, and the development of bone dehiscence and gingival recession;<sup>7,12-14</sup> however, other authors did not detect such an association and, therefore, did not consider sagittal tooth movement a risk factor.<sup>5,15-17</sup>

Periapical, bitewing, or panoramic radiographs cannot show the facial-lingual aspect of the periodontium due to overlapping images on conventional radiographs.<sup>18-20</sup> Cone-beam computed tomography (CBCT) overcomes this diagnostic deficiency by enabling dentists to evaluate support structures for the dental elements in the lingual and facial regions without overlapping structures and within the 3 spatial planes.<sup>18,21</sup> Few studies have evaluated the development of alveolar defects (i.e., dehiscence and bone fenestration) resulting from orthodontic movement using computed tomography.<sup>14,22-25</sup> Most of these studies evaluated the consequences of rapid maxilla expansion over the facial alveolar bone of superior premolars and molars, effects that had only previously been presented in the literature in dental casts and 2-dimensional radiographs.<sup>22,24,25</sup> Finally, only a few studies have evaluated changes in alveolar bone thickness in the incisor region in patients treated orthodontically,<sup>14,23,26</sup> and no study has evaluated the interdental bone septum.

Therefore, the purpose of this study was to evaluate changes in the thickness and height of the alveolar bone and the interdental bone septum in the mandibular incisor region, using CBCT, after the orthodontic treatment of dental crowding without tooth extraction.

## Materials and Methods

This study was conducted after receiving approval from the Ethics and Research Committee (protocol number: 30803614.3.0000.5137) and obtaining informed consent from the patients who participated in the study. This study was designed as a retrospective cohort study. The CBCT images were taken between 2009 and 2017.

This study consisted of 32 patients between 18 and 29

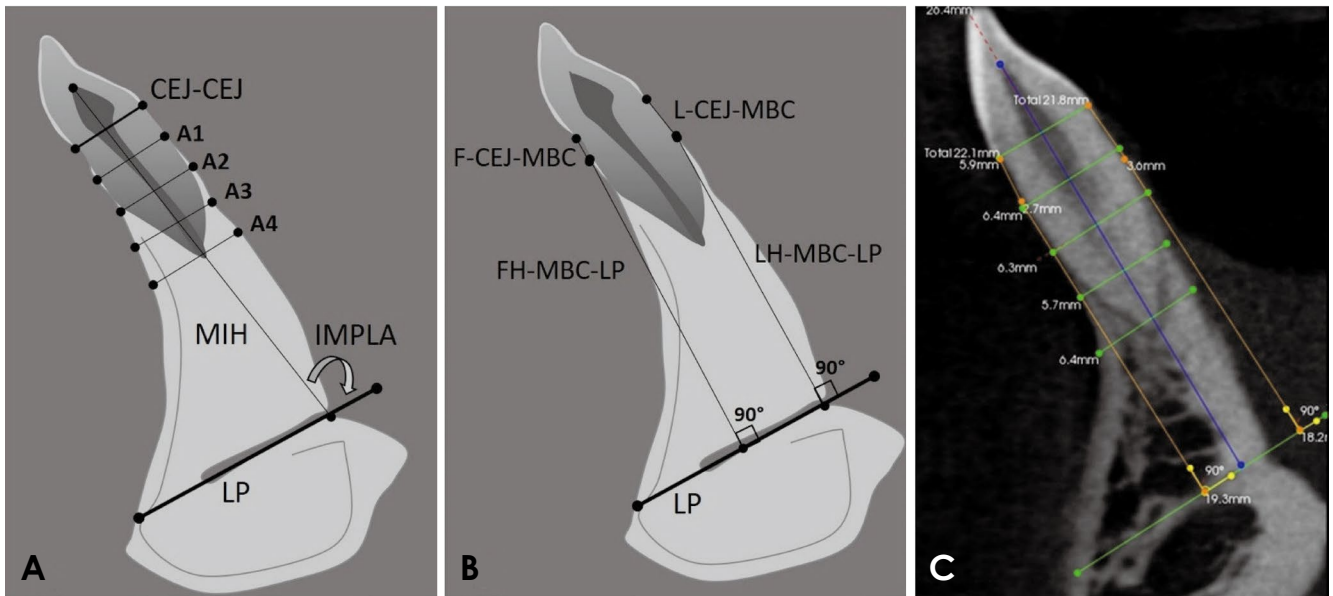
years of age (average:  $23.0 \pm 3.9$  years of age), with anterior dental crowding in the mandibular arcade and class I malocclusion, who needed orthodontic treatment without extraction. Patients under the age of 17; patients who had gingival recession, periodontal disease, a bone or soft tissue lesion in the mandibular incisor region, absence of mandibular incisors, high insertion of the lower labial frenulum and/or tongue frenulum; smokers; patients who were using alcohol or prescription drugs that affected bone metabolism; and patients who did not have pre-treatment and post-treatment CBCT images were excluded.

All patients were treated with fixed metal orthodontic appliances with a Roth prescription (Abzil, 3M Oral Care, São José do Rio Preto, Brazil), with a slot measuring  $0.022 \times 0.028$  inches and continuous archwires (Morelli, Sorocaba, Brazil). Leveling and alignment were performed with round nickel-titanium wire (0.012 inches, 0.014 inches, and 0.016 inches), round stainless-steel wire (0.016 inches and 0.018 inches), and rectangular stainless-steel wire ( $0.016 \times 0.022$  inches and  $0.018 \times 0.025$  inches). The finishing archwires consisted of a rectangular stainless-steel wire ( $0.019 \times 0.025$  inches). Interdental enamel reduction was performed on the anterior teeth to solve dental crowding in all patients. The average treatment time was  $17.4 \pm 3.5$  months.

The 32 CBCT images obtained before orthodontic treatment (T1) were compared with 32 CBCT images obtained 3 to 6 months after the end of orthodontic treatment (T2). All images were obtained using the same Kodak 9000 3D CBCT device (East Kodak Company, Rochester, NY, USA) at the following settings: 74 kV, 10 mA, and an exposure time of 10.8 seconds. The thickness of the isotropic voxel, and therefore of the CBCT images, was  $76 \mu\text{m}$ . The field of view (FOV) used was  $5 \text{ cm} \times 3.75 \text{ cm}$ . A total of 64 CBCT images were evaluated.

Linear and angular measurements of the CBCT images were obtained by CS 3D imaging software (Kodak Dental Systems, Rochester, NY, USA). Measurements were obtained using a 0.076-mm slice. First, CBCT scans (axial reconstructions) were used to evaluate dental crowding through Little's irregularity index.<sup>27</sup> To obtain the irregularity index, the displacements of the contact points of the mandibular anterior teeth were measured using the distance-measuring property of the Kodak software. The alveolar bone and interdental septum measurements were obtained in parasagittal reconstructions that passed through either the center of the mesiodistal width of the root or the center of the interdental bone septum. Therefore, all measurements were performed in the facial-lingual direction.

The measurements used in this study used the lingual canal



**Fig. 1.** Graphical illustration. A. Measurement of the distance between the pulp chamber ceiling and the lingual plane (MIH), the IMPLA angle, and the alveolar bone thicknesses A1, A2, A3, and A4. B. Measurement of the distance between the cementoenamel junction (CEJ) and the facial (F-CEJ-MBC) and lingual (L-CEJ-MBC) marginal bone crests, and of the facial (FH-MBC-LP) and lingual (LH-MBC-LP) bone plate height. C. Parasagittal slice showing the actual measurements. Lingual plane (LP).

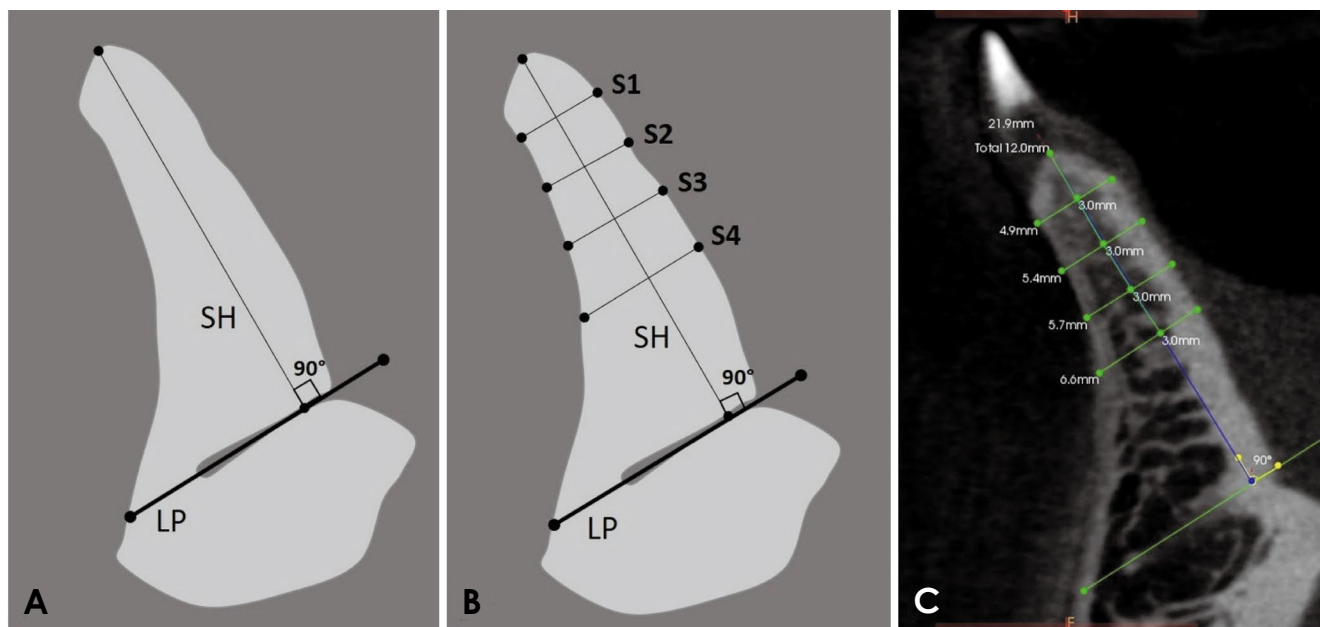
located in the midline region of the mandible area as a reference, according to the findings of Valerio et al.<sup>28</sup> The following measurements were obtained: the mandibular incisor inclination; the vertical position of the mandibular incisor; the facial and lingual bone plate height; the distance between the cementoenamel junction (CEJ) and bone crest on the facial and lingual sides; and the alveolar bone thickness in the dental region located at 3, 6, 9, and 12 mm below the line that connected the lingual and facial CEJ (Fig. 1). Likewise, the height of the mesial and distal interdental septum and the width of the mesial and distal interdental septum located at 3, 6, 9, and 12 mm below the bone crest were obtained (Fig. 2). The variables used in this study and their definitions are provided in Table 1.

First, a line was drawn on the lingual canal after localization of the lingual foramen. This line, beginning in the lingual foramen and extending in the direction of the facial limit of the symphysis, was named the lingual plane (LP).<sup>28</sup> Mandibular incisor inclination was evaluated through the angle between the mandibular incisor's long axis and the LP (IMPLA angle) (Fig. 1A). To register the distance between the pulp chamber ceiling and the LP, the mandibular incisor's long dental axis was extended, starting from the pulp chamber ceiling towards the LP (MIH) (Fig. 1A). Measurements of the thickness of the dental bone ridge (A1, A2, A3, and A4) were obtained from the intersection between the incisor's long axis and the line that connected the facial CEJ

and the lingual CEJ (CEJ-CEJ line), at points located at 3, 6, 9, and 12 mm below the CEJ-CEJ line (Fig. 1A). The facial and lingual bone plate height was recorded by tracing a perpendicular line from the LP up to the facial and lingual marginal bone crest (MBC). Thus, the facial bone plate height (FH-MBC-LP) and the lingual bone plate height (LH-MBC-LP) were obtained (Fig. 1B). Subsequently, the distances between the lingual CEJ and the lingual marginal bone crest (L-CEJ-MBC), as well as between the facial CEJ and the facial marginal bone crest (F-CEJ-MBC), were measured (Figs. 1B and C).

The CBCT images at the midline region of the interdental space were selected to measure the interdental bone septum height (SH). Starting at the bone crest, a line was traced perpendicularly to the LP, and the interdental SH was obtained (Fig. 2A). Subsequently, 4 points were marked on the SH to obtain the interdental septum thickness, namely, points located at 3, 6, 9, and 12 mm below the bone crest. Subsequently, parallel lines to the LP plane were traced, passing through the 4 points mentioned above, which extended from the facial side to the lingual side, to measure the thicknesses S1, S2, S3, and S4 (Figs. 2B and C). Both the height and the thickness of the mesial and distal interdental bone septum were evaluated.

Two observers (1 orthodontist and 1 oral radiologist) were calibrated. All measurements were taken twice, with an interval of 2 weeks between each measurement.



**Fig. 2.** Graphical illustration of the sagittal sectional view at the interdental septum. A. Measurement of the interdental septum height (SH). B. Measurement of interdental septum thicknesses S1, S2, S3, and S4, located at 3, 6, 9, and 12 mm below the bone crest, respectively. C. Parasagittal slice shows the actual measurements of the interdental septum.

**Table 1.** Description of variables

Variable	Description
Irregularity index	The summed displacement of the anatomic contact points of mandibular anterior teeth
<b>Alveolar bone and mandibular incisors</b>	
A1	Facial lingual thickness of the alveolar bone 3 mm below the CEJ line
A2	Facial lingual thickness of the alveolar bone 6 mm below the CEJ line
A3	Facial lingual thickness of the alveolar bone 9 mm below the CEJ line
A4	Facial lingual thickness of the alveolar bone 12 mm below the CEJ line
FH-MBC-LP	Facial height of the alveolar ridge from the facial marginal bone crest to the lingual plane
LH-MBC-LP	Lingual height of the alveolar ridge from the lingual marginal bone crest to the lingual plane
F-CEJ-MBC	Distance from the facial CEJ to the facial marginal bone crest
L-CEJ-MBC	Distance from the lingual CEJ to the lingual marginal bone crest
MIH	Pulp chamber ceiling of the mandibular incisor to the lingual plane
IMPLA	Mandibular incisor to lingual plane angle
<b>Mesial and distal interdental septum</b>	
SH_M	Interdental septum height (mesial side of mandibular incisor)
S1_M	Alveolar ridge thickness of the interdental septum 3 mm below the bone crest (mesial side of mandibular incisor)
S2_M	Alveolar ridge thickness of the interdental septum 6 mm below the bone crest (mesial side of mandibular incisor)
S3_M	Alveolar ridge thickness of the interdental septum 9 mm below the bone crest (mesial side of mandibular incisor)
S4_M	Alveolar ridge thickness of the interdental septum 12 mm below the bone crest (mesial side of mandibular incisor)
SH_D	Interdental septum height (distal side of the mandibular incisor)
S1_D	Alveolar ridge thickness of the interdental septum 3 mm below the bone crest (distal side of mandibular incisor)
S2_D	Alveolar ridge thickness of the interdental septum 6 mm below the bone crest (distal side of mandibular incisor)
S3_D	Alveolar ridge thickness of the interdental septum 9 mm below the bone crest (distal side of mandibular incisor)
S4_D	Alveolar ridge thickness of the interdental septum 12 mm below the bone crest (distal side of mandibular incisor)

CEJ: cementoamel junction

**Statistical analysis**

The intra-class correlation coefficient was used to determine intra- and inter-examiner agreement.<sup>29</sup>

The Kolmogorov-Smirnov normality test revealed normal distributions for the following variables: L-CEJ-MBC, FH-MBC-LP, LH-MBC-LP, A1, A2, MIH, SH\_M, SH\_D, S2\_D, S3\_D, and S3\_M. A non-normal distribution was observed for F-CEJ-MBC, A3, A4, IMPLA, S1\_D, S4\_D, S1\_M, S2\_M, and S4\_M. Thus, the paired Student t-test and the Wilcoxon test were used to evaluate the differences between the measures obtained at T1 and T2, based on the normality standard. The random error was calculated using Dahlberg’s formula.<sup>30</sup>

Pearson correlation coefficients were used to determine the correlations between the variables, and were interpreted as proposed by Evans.<sup>31</sup> Therefore, an *r* value between 0.00 and 0.19 was interpreted as “very weak,” an *r* value between 0.20 and 0.39 was interpreted as “weak,” an *r* value between 0.40 and 0.59 was interpreted as “moderate,” an *r* value between 0.60 and 0.79 was interpreted as “strong”, and an *r* value between 0.80 and 1.00 was interpreted as “very

strong.”

For all tests, the significance level was defined at 5% ( $P < 0.05$ ). Statistical analyses were performed with SPSS (version 21; IBM, Armonk, NY, USA).

**Results**

Intra- and inter-examiner agreement was excellent for the alveolar bone and interdental septum measurements (0.92 and 0.86, and 0.94 and 0.87, respectively).

The random error varied from 0.07 to 0.31 mm for linear measurements, and was 1.58° for measurements of the IMPLA angle (Table 2).

The Student t-test revealed statistically significant changes in A2, S2\_D, S3\_D, and S3\_M. The Wilcoxon test revealed statistically significant changes in F-CEJ-MBC, IMPLA, and S2\_M (Table 2).

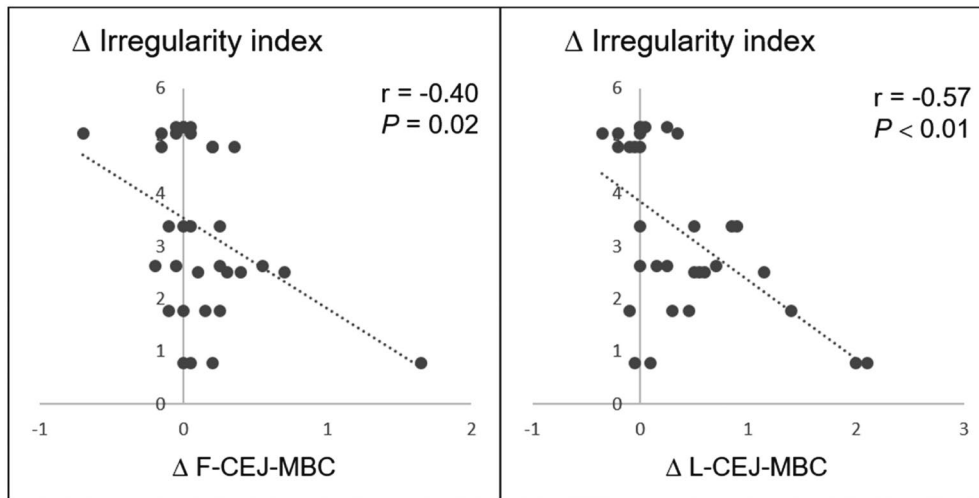
**Pearson correlations**

The irregularity index was correlated moderately and negatively with F-CEJ-MBC and L-CEJ-MBC (Table 3, Fig. 3).

**Table 2.** Descriptive statistics for the variables at the pre-treatment time (T1), post-treatment time (T2), differences between T1 and T2, error of the method (Dahlberg), the paired Student t-test, and the Wilcoxon test

Variable	T1		T2		ΔT2-T1		Dahlberg	<i>t</i>
	Mean	SD	Mean	SD	Mean	SD		
Irregularity index	3.30	1.59	0	0	-3.30	1.59	0.07	11.75 <sup>aa*</sup>
F-CEJ-MBC	1.96	0.57	2.09	0.59	0.13	0.37	0.15	-2.26 <sup>bb*</sup>
L-CEJ-MBC	2.24	0.79	2.63	0.87	0.39	0.61	0.16	1.38 <sup>a</sup>
FH-MBC-LP	20.28	2.43	20.13	2.20	-0.15	0.80	0.28	-1.08 <sup>a</sup>
LH-MBC-LP	19.83	2.38	19.79	2.37	-0.04	0.94	0.31	-0.14 <sup>a</sup>
A1	6.93	0.45	6.85	0.38	-0.08	0.25	0.17	-1.77 <sup>a</sup>
A2	6.86	0.64	6.63	0.54	-0.23	0.31	0.14	-3.50 <sup>aa*</sup>
A3	6.90	1.05	6.77	1.00	-0.13	0.54	0.11	-1.12 <sup>b</sup>
A4	7.50	1.70	7.44	1.58	-0.06	0.62	0.15	-0.12 <sup>b</sup>
MIH	26.35	2.01	26.60	2.01	0.25	0.70	0.20	0.37 <sup>a</sup>
IMPLA	91.45	7.19	95.47	6.86	4.02	4.60	1.58	-3.57 <sup>bb*</sup>
SH_D	22.30	2.40	22.36	2.37	0.06	0.97	0.24	0.46 <sup>a</sup>
S1_D	6.71	0.50	6.55	0.49	-0.16	0.41	0.14	-1.58 <sup>b</sup>
S2_D	6.72	0.69	6.47	0.75	-0.25	0.45	0.16	-2.84 <sup>aa*</sup>
S3_D	6.87	1.10	6.67	1.13	-0.20	0.55	0.15	-2.07 <sup>aa*</sup>
S4_D	7.26	1.53	7.08	1.48	-0.18	0.59	0.13	-1.71 <sup>b</sup>
SH_M	22.80	2.51	22.86	2.47	0.06	0.78	0.26	0.57 <sup>a</sup>
S1_M	6.08	0.67	5.92	0.58	-0.16	0.43	0.15	-1.02 <sup>b</sup>
S2_M	5.91	0.80	5.67	0.62	-0.24	0.43	0.14	-2.40 <sup>bb*</sup>
S3_M	6.31	1.10	6.08	1.02	-0.23	0.52	0.12	-2.19 <sup>aa*</sup>
S4_M	7.02	1.50	6.89	1.46	-0.13	0.48	0.14	-1.24 <sup>b</sup>

<sup>a</sup>: Paired Student t-test; <sup>b</sup>: Wilcoxon test; \*:  $P < 0.05$



**Fig. 3.** Scatter plots show a moderate correlation between the irregularity index and F-CEJ-MBC and L-CEJ-MBC. This indicates that the higher the irregularity index, the greater the trend of marginal bone loss on the mandibular incisor’s lingual and facial sides.

**Table 3.** Correlations of interdental septum, alveolar bone, and mandibular incisor changes with changes in the distance from the facial and lingual cemento enamel junction to the marginal bone crest

	Δ F-CEJ-MBC	Δ L-CEJ-MBC
	<i>r</i>	<i>r</i>
Δ Irregularity index	-0.40*	-0.57**
Δ SH_D	0.30	0.30
Δ SH_M	0.38*	0.42*
Δ S2_M	-0.13	-0.35*
Δ S3_M	-0.37*	-0.42*
Δ A3	-0.36*	-0.36*
Δ A4	-0.20	-0.38*
Δ MIH	0.14	0.25
Δ IMPLA	0.19	-0.01

\*: Correlation is significant at the 0.05 level (2-tailed), \*\*: Correlation is significant at the 0.01 level (2-tailed)

Changes in F-CEJ-MBC and L-CEJ-MBC were significantly correlated with the mesial bone septum height (SH\_M); however, the same was not true for the interdental height of the distal bone septum (SH\_D) (Table 3 and Fig. 4). F-CEJ-MBC and L-CEJ-MBC were also significantly correlated with the facial-lingual thicknesses of the alveolar bone located 9 mm below the CEJ-CEJ line (A3 variable), and with the thicknesses of the mesial interdental septum located 9 mm below the bone crest (S3\_M variable). There was no significant association between changes in the MIH or IMPLA angle and increases in L-CEJ-MBC or F-CEJ-MBC.

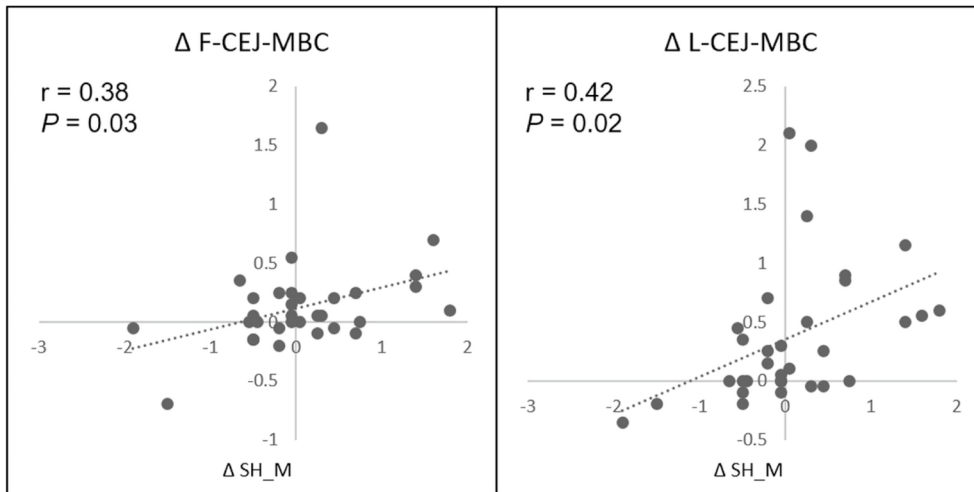
Regarding changes in FH-MBC-LP and LH-MBC-LP between the T1 and T2 time points, no correlation was detected

**Table 4.** Correlations of interdental septum (height and thickness) changes, alveolar bone thickness, and mandibular incisor changes with changes in the facial and lingual height of the alveolar ridge

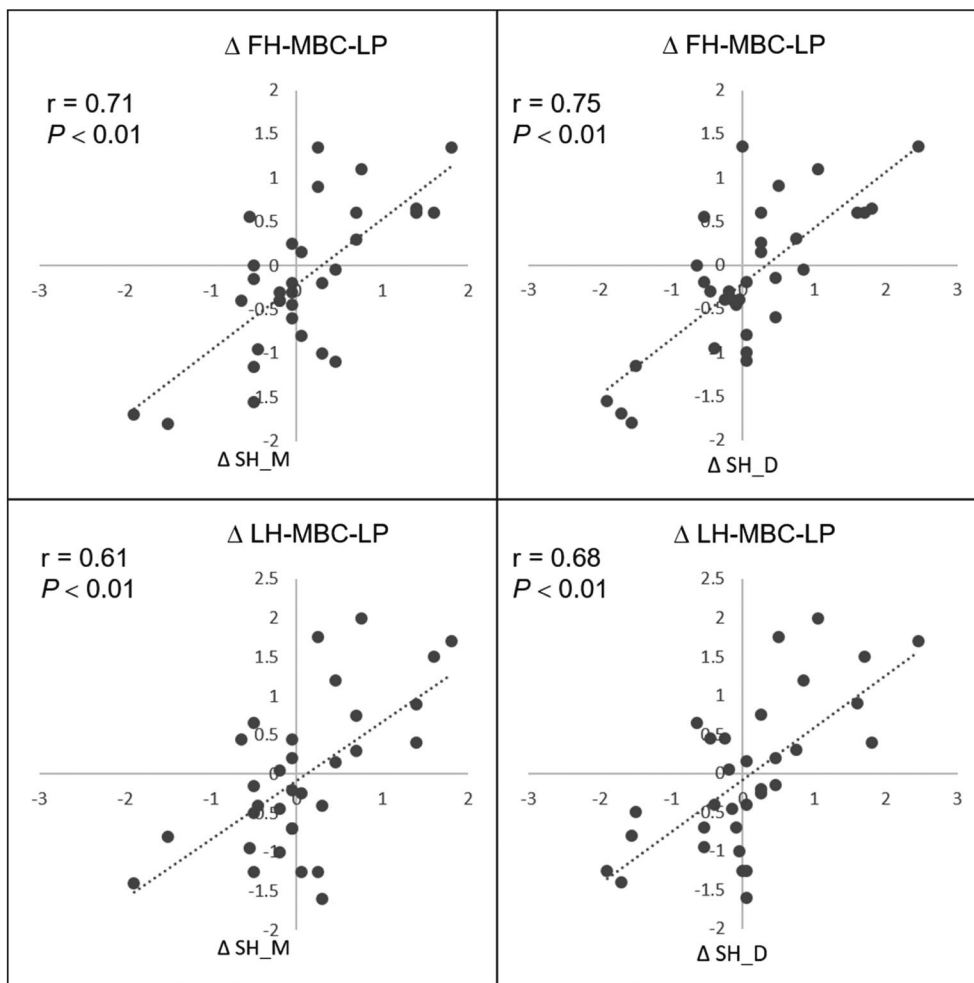
	Δ FH-MBC-LP	Δ LH-MBC-LP
	<i>r</i>	<i>r</i>
Δ Irregularity index	-0.42*	0.19
Δ SH_D	0.75**	0.68**
Δ SH_M	0.71**	0.61**
Δ S1_D	-0.54**	-0.35*
Δ S2_D	-0.47**	-0.39*
Δ S3_D	-0.69**	-0.52
Δ S4_D	-0.67**	-0.60**
Δ S1_M	-0.45*	-0.50**
Δ S2_M	-0.54**	-0.45*
Δ S3_M	-0.73**	-0.62**
Δ S4_M	-0.66**	-0.68**
Δ A1	-0.43*	-0.47**
Δ A2	-0.33	-0.36
Δ A3	-0.61**	-0.50**
Δ A4	-0.73**	-0.55**
Δ MIH	-0.78**	-0.72**
Δ IMPLA	-0.49**	0.16

\*: Correlation is significant at the 0.05 level (2-tailed), \*\*: Correlation is significant at the 0.01 level (2-tailed)

between the irregularity index and changes in FH-MBC-LP or LH-MBC-LP (Table 4). There was a significant and strong correlation with changes in bone septum height on both the mesial side (SH\_M) and the distal side (SH\_D) (Fig. 5). Changes in FH-MBC-LP and LH-MBC-LP demonstrated



**Fig. 4.** Scatter plots show a positive and weak correlation between the mesial interdental septum (SH\_M) with the distance between CEJ and the facial marginal bone crest (F-CEJ-MBC), and a positive and moderate correlation with the distance between the CEJ and the lingual marginal bone crest (L-CEJ-MBC).



**Fig. 5.** Scatter plot showing a positive and strong correlation between lingual and facial bone plate height (LH-MBC-LP and FH-MBC-LP) and the mesial (SH\_M) and distal (SH\_D) interdental septum height.

**Table 5.** Correlations of changes in the interdental septum and alveolar bone variables with changes in the vertical (MIH) and angular position (IMPLA) of the mandibular incisors

	Δ MIH	Δ IMPLA
	<i>r</i>	<i>r</i>
Δ SH_D	0.73**	-0.07
Δ S1_D	-0.32	0.19
Δ S2_D	-0.41*	0.15
Δ S3_D	-0.62**	0.22
Δ S4_D	-0.67**	0.09
Δ SH_M	0.69**	-0.06
Δ S1_M	-0.36*	-0.77
Δ S2_M	-0.42*	0.12
Δ S3_M	-0.75**	0.06
Δ S4_M	-0.77**	-0.10
Δ FH-MBC-LP	0.78**	-0.49**
Δ LH-MBC-LP	0.72**	0.16

\*: Correlation is significant at the 0.05 level (2-tailed), \*\*: Correlation is significant at the 0.01 level (2-tailed)

a moderate and significant correlation with changes in bone septum thickness measurements on both the mesial and distal sides (S1, S2, S3, and S4). The changes that occurred in FH-MBC-LP and LH-MBC-LP showed statistically significant negative correlations with changes in the facial-lingual thickness of the alveolar bone (A1, A2, A3, and A4). There was also a strong and negative correlation with the vertical position of the mandibular incisor (MIH variable), both for FH-MBC-LP and for LH-MBC-LP. The facial bone plate (FH-MBC-LP) was the only variable that showed a moderate and negative statistically significant correlation with the IMPLA angle (Table 4).

Regarding the changes from T1 to T2 in the mandibular incisor’s vertical (MIH) and angular dental positioning (IMPLA), there were significant correlations between MIH and facial-lingual height and the thickness of the mesial and distal interdental septa. The only variable significantly associated with changes in the IMPLA angle was FH-MBC-LP, which demonstrated a negative correlation; that is, an increase in the IMPLA angle was correlated with a decrease in FH-MBC-LP (Table 5).

### Discussion

The purpose of this study was to evaluate, using CBCT, changes in the height and thickness of the alveolar bone and the interdental septum in the mandibular incisor region in class I adult patients with dental crowding who were treated with fixed orthodontic appliances without dental ex-

traction. Some studies have evaluated the changes in the alveolar bone thickness in the incisor area in patients treated orthodontically with CBCT.<sup>14,23,26</sup> However, to date, no study has evaluated the interdental septum together with an analysis of the dental region.

Studies that evaluated the effect of the voxel size (0.125-0.30 mm) in measuring craniofacial structures considered differences in thickness measures obtained in the mandible to be insignificant in images obtained by equipment operating with different voxels.<sup>32-34</sup> The present study used CBCT equipment with a 0.076-mm voxel size, which, compared to previous studies<sup>14,23,26,35</sup> can provide a better spatial resolution.<sup>34,36</sup> In association with this fact, a smaller FOV was also used; therefore, the 2 parameters considered to be important for obtaining good spatial resolution, FOV and voxel size,<sup>34</sup> were optimized in this study. The images were analyzed and measured from CBCT slices with a 0.076-mm thickness in order to detect the smallest possible changes in terms of potential bone loss or gain in the alveolar bone.

Previous studies measured the facial and lingual thicknesses of the bone plates adjacent to the facial and lingual surface of the incisor root in 3 regions, namely at the level of the MBC, the midline level of the root, and the dental apex.<sup>14,23,26,35</sup> Nevertheless, the alveolar bone plate thickness has reduced dimensions, especially in the marginal crest region; this limitation compromises accuracy, making it impossible to detect changes of smaller than 0.5 mm.<sup>37-39</sup> Thus, small changes may not be appropriately quantified, in addition to being within the random error margin. Therefore, in this study, the total width of the alveolar bone was measured in the facial-lingual direction for a more precise evaluation of bone alterations. As a result, regarding the dental bone ridge width, a significant reduction was noted in A2 - that is, in the region located 6 mm below the CEJ-CEJ line (Table 2). No changes in A1, A3, or A4 were observed, indicating possible fenestration in this region.

The distance between the CEJ and the marginal bone crest on the facial side (F-CEJ-MBC) underwent a positive change; that is, there was a significant increase in this variable at T2 (Table 2), indicating vertical bone loss or dehiscence in this region. The distance between the CEJ and the marginal bone crest on the lingual surface (L-CEJ-MBC) did not increase significantly, unlike the results of other studies conducted with CBCT.<sup>14,40</sup> One study evaluated bone loss on the facial and lingual sides of anterior teeth in patients treated orthodontically with premolar extraction and identified an average bone loss of 5.7 mm on the lingual surface of mandibular central incisors.<sup>40</sup> Another study<sup>14</sup> obtained a statistically significant bone loss of 1.12 mm on the lingual



surface of the mandibular incisor in patients treated orthodontically without dental extraction.<sup>14</sup> Our study found no significant bone loss of 0.39 mm on the lingual surface. Some factors may have contributed to findings that diverged from ours, such as orthodontic appliances, as other studies used the MBT pre-adjusted appliance or self-ligating brackets, and treatment without dental extraction.

Although L-CEJ-MBC did not significantly change, L-CEJ-MBC and F-CEJ-MBC showed moderate correlations with the irregularity index, illustrating that the greater the degree of dental crowding, the greater the trend of vertical bone loss after orthodontic treatment without dental extraction. This information may help the orthodontist choose a proper treatment plan, especially in patients who show signs of gingival recession.

The increase in mandibular incisor inclination towards the facial side has been reported in the literature as a cause or risk factor for facial bone dehiscence. Experimental studies performed on monkeys, in which the mandibular incisor was projected towards the facial side with an extension between 3 mm and 6 mm, showed bone loss and gingival recession in the facial region.<sup>8,9</sup> However, another study stated that the final inclination of the mandibular incisor is more important than the projection of this tooth and considered an inclination of greater than 96° to be a risk factor.<sup>14</sup> A more recent study evaluated the inclination of mandibular incisors after orthodontic treatment without extraction and obtained an average increase of 2.40° in this angle.<sup>14</sup> However, these authors found no correlation between the increase in this inclination and vertical bone loss. The present study obtained an average increase of 4.02° in the facial inclination of the incisors, but this increase was not statistically significantly correlated with the increase in the distance between the facial bone crest and the CEJ, a variable used to identify bone dehiscence. Nonetheless, this variable was correlated with a reduction in the height of the facial bone plate (Tables 3 and 4). Future studies should evaluate the safety limit at which the mandibular incisor may be projected towards the facial side or retroinclined without causing marginal bone loss.

This study focused on evaluating the interdental bone septum and evaluating the alveolar bone to identify variables that could contribute to detecting bone loss resulting from orthodontic forces. For this reason, the choice was made to analyze the interdental septum in the mesial and in the distal sides of the mandibular incisors separately, as the direction of orthodontic forces may have different effects on each side of the tooth. An interesting finding was the correlation between the interdental septum height and the marginal bone loss on both the lingual and facial sides, possibly because

the remodeling process during orthodontic treatment occurs on all sides around the teeth, including the interdental septum, and not only on the facial and lingual sides (Table 3). The results also showed moderate to strong significant correlations between the height of the facial and lingual bone plate and the height and thickness of the interdental septum on the incisor's mesial and distal sides (Table 4). Future studies may define monitoring criteria for the marginal bone loss of incisors by evaluating the interdental septum.

Not much is known about the effects of the vertical change of the incisor after orthodontic movement on the periodontium; however, this aspect may be important in evaluating vertical bone loss.<sup>41</sup> A previous study reported a 5-mm extrusion in the projected incisors that developed dehiscence.<sup>8</sup> In the current study, the MIH measurement was designed to evaluate whether the incisors' extrusion or intrusion would cause any changes in thickness and height to the bone ridge and the interdental septum, as well as in F-CEJ-MBC and L-CEJ-MBC. However, the MIH measurement does not merely represent a vertical position change, but rather the vertical and sagittal movement of the incisors. Although the results showed a moderate to strong association between the increase in the MIH variable and reduced thickness in the interdental septum, further studies will be needed to obtain a tooth measurement representing a purely vertical position change.

In conclusion, significant marginal bone loss was only observed on the incisors' facial side, indicating dehiscence after the orthodontic treatment of mandibular incisor crowding without tooth extraction. The degree of dental crowding, assessed through the irregularity index, was associated with the risk of bone dehiscence in the incisors when orthodontic treatment was performed without dental extraction. The interdental SH was correlated with marginal vertical bone loss on both the lingual and facial sides. Therefore, interdental septum measurements may be used to monitor marginal bone loss during orthodontic treatment.

## References

1. Buschang PH, Shulman JD. Incisor crowding in untreated persons 15-50 years of age: United States, 1988-1994. *Angle Orthod* 2003; 73: 502-8.
2. Burt VL, Harris T. The third National Health and Nutrition Examination Survey: contributing data on aging and health. *Gerontologist* 1994; 34: 486-90.
3. Claudino D, Traebert J. Malocclusion, dental aesthetic self-perception and quality of life in a 18 to 21 year-old population: a cross section study. *BMC Oral Health* 2013; 13: 3.
4. Zhang M, McGrath C, Hägg U. The impact of malocclusion and its treatment on quality of life: a literature review. *Int J Paediatr*

- Dent 2006; 16: 381-7.
5. Morris JW, Campbell PM, Tadlock LP, Boley J, Buschang PH. Prevalence of gingival recession after orthodontic tooth movements. *Am J Orthod Dentofacial Orthop* 2017; 151: 851-9.
  6. Slutzkey S, Levin L. Gingival recession in young adults: occurrence, severity, and relationship to past orthodontic treatment and oral piercing. *Am J Orthod Dentofacial Orthop* 2008; 134: 652-6.
  7. Renkema AM, Fudalej PS, Renkema AA, Abbas F, Bronkhorst E, Katsaros C. Gingival labial recessions in orthodontically treated and untreated individuals: a case - control study. *J Clin Periodontol* 2013; 40: 631-7.
  8. Batenhorst KF, Bowers GM, Williams JE Jr. Tissue changes resulting from facial tipping and extrusion of incisors in monkeys. *J Periodontol* 1974; 45: 660-8.
  9. Steiner GG, Pearson JK, Ainamo J. Changes of the marginal periodontium as a result of labial tooth movement in monkeys. *J Periodontol* 1981; 52: 314-20.
  10. Karring T, Nyman S, Thilander B, Magnusson I. Bone regeneration in orthodontically produced alveolar bone dehiscences. *J Periodontal Res* 1982; 17: 309-15.
  11. Wingard CE, Bowers GM. The effects of facial bone from facial tipping of incisors in monkeys. *J Periodontol* 1976; 47: 450-4.
  12. Artun J, Krogstad O. Periodontal status of mandibular incisors following excessive proclination. A study in adults with surgically treated mandibular prognathism. *Am J Orthod Dentofacial Orthop* 1987; 91: 225-32.
  13. Yared KF, Zenobio EG, Pacheco W. Periodontal status of mandibular central incisors after orthodontic proclination in adults. *Am J Orthod Dentofacial Orthop* 2006; 130: 6.e1-8.
  14. Garlock DT, Buschang PH, Araujo EA, Behrents RG, Kim KB. Evaluation of marginal alveolar bone in the anterior mandible with pretreatment and posttreatment computed tomography in nonextraction patients. *Am J Orthod Dentofacial Orthop* 2016; 149: 192-201.
  15. Ruf S, Hansen K, Pancherz H. Does orthodontic proclination of lower incisors in children and adolescents cause gingival recession? *Am J Orthod Dentofacial Orthop* 1998; 114: 100-6.
  16. Djeu G, Hayes C, Zawaideh S. Correlation between mandibular central incisor proclination and gingival recession during fixed appliance therapy. *Angle Orthod* 2002; 72: 238-45.
  17. Allais D, Melsen B. Does labial movement of lower incisors influence the level of the gingival margin? A case-control study of adult orthodontic patients. *Eur J Orthod* 2003; 25: 343-52.
  18. Fuhrmann R a, Bücken A, Diedrich PR. Assessment of alveolar bone loss with high resolution computed tomography. *J Periodontal Res* 1995; 30: 258-63.
  19. Garib DG, Henriques JF, Janson G, de Freitas MR, Fernandes AY. Periodontal effects of rapid maxillary expansion with tooth-tissue-borne and tooth-borne expanders: a computed tomography evaluation. *Am J Orthod Dentofacial Orthop* 2006; 129: 749-58.
  20. Evangelista K, Vasconcelos Kde F, Bumann A, Hirsch E, Nitka M, Silva MA. Dehiscence and fenestration in patients with Class I and Class II Division 1 malocclusion assessed with cone-beam computed tomography. *Am J Orthod Dentofacial Orthop* 2010; 138: 133.e1-7.
  21. Mengel R, Candir M, Shiratori K, Flores-de-Jacoby L. Digital volume tomography in the diagnosis of periodontal defects: an in vitro study on native pig and human mandibles. *J Periodontol* 2005; 76: 665-73.
  22. Baysal A, Uysal T, Veli I, Ozer T, Karadede I, Hekimoglu S. Evaluation of alveolar bone loss following rapid maxillary expansion using cone-beam computed tomography. *Korean J Orthod* 2013; 43: 83-95.
  23. Picanço PR, Valarelli FP, Caçado RH, de Freitas KM, Picanço GV. Comparison of the changes of alveolar bone thickness in maxillary incisor area in extraction and non-extraction cases: computerized tomography evaluation. *Dental Press J Orthod* 2013; 18: 91-8.
  24. Rungcharassaeng K, Caruso JM, Kan JY, Kim J, Taylor G. Factors affecting buccal bone changes of maxillary posterior teeth after rapid maxillary expansion. *Am J Orthod Dentofacial Orthop* 2007; 132: 428.e1-8.
  25. Garib DG, Menezes MH, Silva Filho OG, Santos PBD. Immediate periodontal bone plate changes induced by rapid maxillary expansion in the early mixed dentition: CT findings. *Dental Press J Orthod* 2014; 19: 36-43.
  26. Sarikaya S, Haydar B, Çiğer S, Ariyürek M. Changes in alveolar bone thickness due to retraction of anterior teeth. *Am J Orthod Dentofacial Orthop* 2002; 122: 15-26.
  27. Little RM. The irregularity index: a quantitative score of mandibular anterior alignment. *Am J Orthod* 1975; 68: 554-63.
  28. Valerio CS, E Alves CA, Manzi FR. Reproducibility of cone-beam computed tomographic measurements of bone plates and the interdental septum in the anterior mandible. *Imaging Sci Dent* 2019; 49: 9-17.
  29. Shrout PE, Fleiss JL. Intraclass correlations: uses in assessing rater reliability. *Psychol Bull* 1979; 86: 420-8.
  30. Galvão MC, Sato JR, Coelho EC. Dahlberg formula - a novel approach for its evaluation. *Dental Press J Orthod* 2012; 17: 115-24.
  31. Evans JD. *Straightforward statistics for the behavioral sciences*. Brooks: Cole Pub Co; 1995.
  32. Hekmatian E, Jafari-Pozve N, Khorrami L. The effect of voxel size on the measurement of mandibular thickness in cone-beam computed tomography. *Dent Res J (Isfahan)* 2014; 11: 544-8.
  33. Moshfeghi M, Tavakoli MA, Hosseini ET, Hosseini AT, Hosseini IT. Analysis of linear measurement accuracy obtained by cone beam computed tomography (CBCT-NewTom VG). *Dent Res J (Isfahan)* 2012; 9 (Suppl 1): S57-62.
  34. Patcas R, Müller L, Ullrich O, Peltomäki T. Accuracy of cone-beam computed tomography at different resolutions assessed on the bony covering of the mandibular anterior teeth. *Am J Orthod Dentofacial Orthop* 2012; 141: 41-50.
  35. Nayak Krishna US, Shetty A, Girija MP, Nayak R. Changes in alveolar bone thickness due to retraction of anterior teeth during orthodontic treatment: a cephalometric and computed tomography comparative study. *Indian J Dent Res* 2013; 24: 736-41.
  36. Molen AD. Considerations in the use of cone-beam computed tomography for buccal bone measurements. *Am J Orthod Dentofacial Orthop* 2010; 137(4 Suppl): S130-5.
  37. Behnia H, Motamedian SR, Kiani MT, Morad G, Khojasteh A. Accuracy and reliability of cone beam computed tomographic measurements of the bone labial and palatal to the maxillary anterior teeth. *Int J Oral Maxillofac Implants* 2015; 30: 1249-55.

38. Fuhrmann RA, Wehrbein H, Langen HJ, Diedrich PR. Assessment of the dentate alveolar process with high resolution computed tomography. *Dentomaxillofac Radiol* 1995; 24: 50-4.
39. Leung CC, Palomo L, Griffith R, Hans MG. Accuracy and reliability of cone-beam computed tomography for measuring alveolar bone height and detecting bony dehiscences and fenestrations. *Am J Orthod Dentofacial Orthop* 2010; 137(4 Suppl): S109-19.
40. Lund H, Gröndahl K, Gröndahl HG. Cone beam computed tomography evaluations of marginal alveolar bone before and after orthodontic treatment combined with premolar extractions. *Eur J Oral Sci* 2012; 120: 201-11.
41. Hong SY, Shin JW, Hong C, Chan V, Baik UB, Kim YH, et al. Alveolar bone remodeling during maxillary incisor intrusion and retraction. *Prog Orthod* 2019; 20: 47.