



Unusual Presentation of a Testicular Lymphoma Mimicking a Missed Testicular Torsion: A Case Report

계류 고환염전으로 오인된 드문 형태의 고환 림프종:
증례 보고

Mi Jin Kim, MD , Young Hwan Lee, MD* , Youe Ree Kim, MD

Department of Radiology, Wonkwang University College of Medicine, Wonkwang University Hospital, Iksan, Korea

Testicular lymphoma is an uncommon testicular tumor that usually presents as a painless mass. It usually shows hypervascularity on color Doppler ultrasound (US) and a mild enhancement on enhanced CT or MRI. We present an unusual case of a testicular lymphoma mimicking a missed testicular torsion in a 67-year-old male patient with right scrotal swelling and intermittent pain for 2 months. Color Doppler US demonstrated the absence of vascularity in the enlarged right testis, and the initial diagnosis was a missed testicular torsion. CT demonstrated a poorly enhancing mass rather than a missed testicular torsion with enhanced small nodular foci at the periphery. The final pathological diagnosis was testicular lymphoma.

Index terms Testicular Neoplasms; Lymphoma, Non-Hodgkin; Testis; Spermatic Cord Torsion; Ultrasonography

INTRODUCTION

Testicular lymphoma accounts for less than 10% of testicular neoplasms. Generally, it is characterized by “hyper-vascularity” on color Doppler ultrasound (US) (1). Here, we report a case of unusual presentation of testicular lymphoma with avascularity on US, mimicking missed testicular torsion. We also reviewed previous reported cases of testicular lymphoma and their imaging findings.

Received September 17, 2020
Revised December 15, 2020
Accepted February 1, 2021

***Corresponding author**

Young Hwan Lee, MD
Department of Radiology,
Wonkwang University
College of Medicine,
Wonkwang University Hospital,
895 Muwang-ro, Iksan 54538,
Korea.

Tel 82-63-859-1920

Fax 82-63-851-4749

E-mail yjyh@wonkwang.ac.kr

This is an Open Access article distributed under the terms of the Creative Commons Attribution Non-Commercial License (<https://creativecommons.org/licenses/by-nc/4.0>) which permits unrestricted non-commercial use, distribution, and reproduction in any medium, provided the original work is properly cited.

ORCID iDs

Mi Jin Kim

[https://
orcid.org/0000-0001-5568-0187](https://orcid.org/0000-0001-5568-0187)

Young Hwan Lee

[https://
orcid.org/0000-0001-5893-6571](https://orcid.org/0000-0001-5893-6571)

Youe Ree Kim

[https://
orcid.org/0000-0001-5615-9721](https://orcid.org/0000-0001-5615-9721)

CASE REPORT

A 67-year-old male visited our hospital with a complaint of right scrotal swelling with mild intermittent pain and tenderness for two months. On physical examination, his right testis showed slight enlargement compared to the left testis. The overlying skin was normal in the right scrotum. The patient had mild tenderness at the right testis. Hematological examination showed that C-reactive protein level was high (139.21 mg/L, normal range: less than 10 mg/L). His white blood cell level was normal, close to the upper limit ($9.94 \times 10^3/\mu\text{L}$, normal range: 4.5 to $11.0 \times 10^3/\mu\text{L}$).

Scrotal US showed no remarkable findings at the left testis. However, the right testis showed enlargement with heterogeneous hypoechoic echogenicity. A small amount of hydrocele was also detected (Fig. 1A). Color Doppler US demonstrated the absence of blood flow at the right intra-testicular tissue, with only blood flow being detected at the para-testicular tissue. No definite torsion knot was seen (Fig. 1B). Considering the patient's clinical information and sonographic findings, missed testicular torsion was suspected. Subsequent ab-

Fig. 1. A 67-year-old male with testicular lymphoma mimicking missed testicular torsion.

A. Longitudinal US image shows diffuse heterogeneous echogenicity of the right testis with a mild hydrocele in the right scrotal sac.

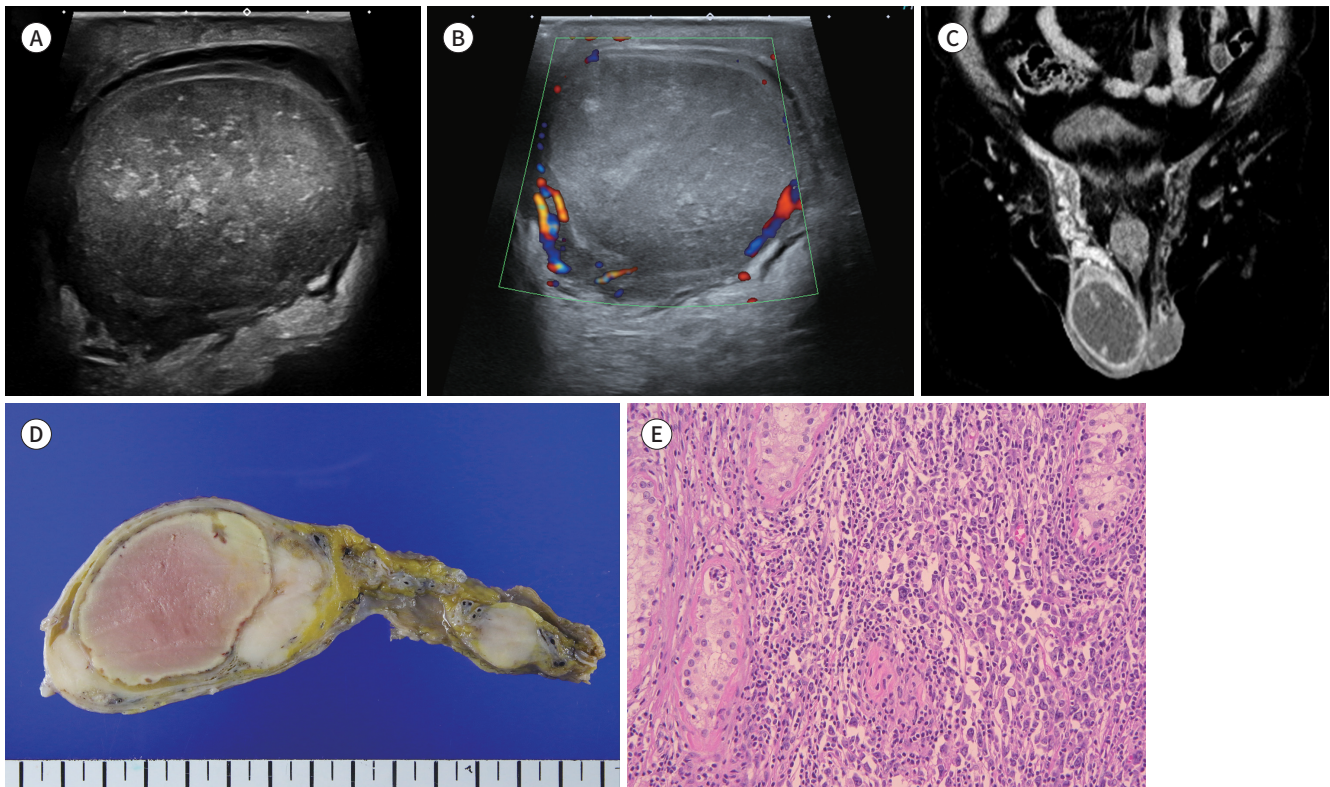
B. Color Doppler US image shows no color flow signal at the intratesticular tissue, and blood flow is detected at the paratesticular tissue.

C. Coronal enhanced-CT image shows a 6.1 × 4.3-cm sized well-defined poorly enhancing mass in the right testis with peripherally enhancing nodular solid portions. The right spermatic cord and right gonadal vein are also thickened.

D. The gross specimen shows a diffusely enlarged testis with hemorrhagic ischemia and necrosis.

E. Photomicrograph (hematoxylin and eosin, × 400) shows lymphocyte aggregation and invasion of the seminiferous tubules (not shown).

US = ultrasound



domen-pelvis CT imaging revealed an about 6.1 × 4.3-cm sized well-defined poorly enhancing soft tissue density mass at the right testis. Some enhancing nodular solid portions were noted at the peripheral portion of the mass. The right spermatic cord was also thickened and the right gonadal vein was enlarged. It was considered as a poorly enhancing testicular mass with infarction rather than torsion. There was no definite evidence of enlarged lymph nodes or distant metastatic lesions (Fig. 1C). Orchiectomy was performed. Operative findings revealed that there was no evidence of testicular torsion. The gross findings showed a yellowish mass with hemorrhage (Fig. 1D).

Hematoxylin and eosin staining images revealed aggregation of lymphocytes (Fig. 1E). Immunohistochemistry showed positive results for CD20 and MUM-1. The pathologic diagnosis was confirmed to be diffuse large B-cell lymphoma with extensive hemorrhagic infarction. Neck CT, chest CT, and PET/CT were performed to identify metastasis. There were no distant metastatic lesions. The patient was treated with chemotherapy following the operation.

DISCUSSION

Primary testicular lymphoma accounts for 1%–9% of all testicular tumors and 1% of all non-Hodgkin lymphoma. It is the most common testicular tumor for men over 60-year-old. The most common symptom is painless testicular swelling or enlargement. It tends to show bilaterality. B symptoms such as fever, weight loss, and night sweat are uncommon differently from other types of lymphoma. The most common histologic type of testicular lymphoma is diffuse large B cell lymphoma (2). Testicular lymphoma has a relatively rapid disease progression. It often infiltrates to epididymis, spermatic cord, and retroperitoneal lymph nodes. In advanced stage, it has a tendency to show extranodal metastasis such as the central nervous system, skin, Waldeyer's ring, and lung (1). For its diagnosis and treatment, orchiectomy is performed predominantly (3).

Generally, testicular lymphoma appears to be diffuse or show focal hypo-echogenicity on scrotal US. On color Doppler imaging, its lesions show hyper-vascularity (4). According to a previous study, when eight pathologic proven testicular lymphoma or leukemia patients were reviewed, all lesions depicted hyper-vascularity at color Doppler imaging (5). It has been suggested that if hyper-vascularity is seen on scrotal color Doppler US in patients who complain painless scrotal swelling, testicular lymphoma/leukemia should be considered as a differential diagnosis (5). Another study has analyzed color Doppler US findings of 43 patients diagnosed with testicular lymphoma and found that most (38 of 43, 88%) lesions are hypervascular (4).

CT can be used to assess tumor staging. It can also be used to determine distant or lymph node metastasis. It allows us to sensitively detect retroperitoneal, para-aortic lymph nodes and solid organ metastasis. Calcification and hemorrhage are unusual (2). PET/CT can also be performed for initial staging and evaluating treatment response (6). MRI is useful to characterize testicular tumor properly with high sensitivity and specificity. Most of testicular lymphomas show low signal intensity than normal testis tissue in both T1 and T2-weighted images. The tumor homogeneously shows less enhancement than normal testicular tissue, usually. It also demonstrates moderate-to-marked diffusion restriction (2, 7).

Testicular torsion develops every year about 0.8% of boys under the age of 20 years in the United States. When color Doppler US demonstrates the absence of intra- testicular flow in a male who has testicular pain, testicular torsion is highly likely to be the diagnosis. It has been reported that color Doppler US has a sensitivity of about 80% to 100% and a specificity of 97% to 100% in adults (8).

In our case, patient complained about scrotal swelling with mild discomfort for two months. The initial diagnosis was missed testicular torsion due to the absence of vascularity on color Doppler US. However, CT findings suggested testicular mass rather than torsion. The gross pathology demonstrated extensive hemorrhagic necrosis. Hemorrhage is rare findings for testicular lymphoma (2). However, tumor necrosis is one of characteristics of cancer. It is developed by prolonged hypoxia within rapidly growing cancer surpassing vascular supply (9). Hemorrhagic necrosis in the present case might be due to rapid growth of the tumor. It made the tumor show hypovascularity on color Doppler US image. However, CT image showed a small enhancing portion at the peripheral portion of the testicular tumor. The central portion of the tumor demonstrated necrosis earlier while the peripheral portion of the tumor was preserved. A previous study has reported a case of testicular lymphoma in an 86-year-old male with complaint of three weeks of testicular pain and right scrotal swelling. That patient's diagnosis was considered as testicular torsion without additional sonographic examination (10). The surgeon proceeded with immediate exploration. Histopathological examination of the testicular mass was reported as diffuse large B cell lymphoma with evidence of recurrent torsion and focal subacute testicular ischemia and necrosis (10).

In conclusion, when an enlarged testis demonstrates decreased vascularity on color Doppler US in elderly patients, both testicular torsion and lymphoma should be considered for differential diagnosis. Additional imaging such as CT and MRI would be helpful for correct diagnosis.

Author Contributions

Conceptualization, L.Y.H., K.Y.R.; data curation, all authors; formal analysis, K.M.J., K.Y.R.; funding acquisition, K.Y.R.; investigation, K.M.J., K.Y.R.; methodology, K.Y.R., K.M.J.; project administration, L.Y.H.; resources, K.M.J.; software, K.Y.R., K.M.J.; supervision, L.Y.H.; validation, K.Y.R.; visualization, K.M.J., L.Y.H.; writing—original draft, K.M.J.; and writing—review & editing, L.Y.H., K.Y.R.

Conflicts of Interest

The authors have no potential conflicts of interest to disclose.

Funding

This paper was supported by Wonkwang University in 2020.

REFERENCES

1. Shahab N, Doll DC. Testicular lymphoma. *Semin Oncol* 1999;26:259-269
2. Sabale A, Prahlanan A, Kalidos K, Koshy SM, Ramachandran K. Unusual continuous intra-abdominal spread of primary testicular lymphoma along the spermatic cord and gonadal vessels: report of 2 cases. *Radiol Case Rep* 2015;10:76-80
3. Hasselblom S, Ridell B, Wedel H, Norrby K, Sender Baum M, Ekman T. Testicular lymphoma—a retrospective, population-based, clinical and immunohistochemical study. *Acta Oncol* 2004;43:758-765
4. Bertolotto M, Derchi LE, Secil M, Dogra V, Sidhu PS, Clements R, et al. Grayscale and color Doppler features

- of testicular lymphoma. *J Ultrasound Med* 2015;34:1139-1145
5. Mazzu D, Jeffrey RB Jr, Ralls PW. Lymphoma and leukemia involving the testicles: findings on gray-scale and color Doppler sonography. *AJR Am J Roentgenol* 1995;164:645-647
 6. Okuyucu K, İnce S, Alagöz E, Ataş E, Arslan N. Utility of FDG PET/CT in the management of primary testicular lymphoma. *Mol Imaging Radionucl Ther* 2018;27:61-65
 7. Cassidy FH, Ishioka KM, McMahon CJ, Chu P, Sakamoto K, Lee KS, et al. MR imaging of scrotal tumors and pseudotumors. *Radiographics* 2010;30:665-683
 8. Liang T, Metcalfe P, Sevcik W, Noga M. Retrospective review of diagnosis and treatment in children presenting to the pediatric department with acute scrotum. *AJR Am J Roentgenol* 2013;200:W444-W449
 9. Song MK, Chung JS, Shin DY, Lim SN, Lee GW, Choi JC, et al. Tumor necrosis could reflect advanced disease status in patients with diffuse large B cell lymphoma treated with R-CHOP therapy. *Ann Hematol* 2017; 96:17-23
 10. Ackermann T, Kuang R, Tsan C. Unusual presentation of testicular torsion in an elderly man. *ANZ J Surg* 2016;86:837-838

계류 고환염전으로 오인된 드문 형태의 고환 림프종: 증례 보고

김미진 · 이영환* · 김유리

고환 림프종은 무통성 종괴를 주소로 내원하는 드문 고환 종양이다. 일반적으로 고환 림프종은 칼라 도플러 초음파에서 고혈관성을 보이며, 컴퓨터단층촬영이나 자기공명영상에서 조영증강을 보인다. 저자들은 우측 고환 종대를 주소로 내원한 67세 환자에서 초음파 검사상 크기가 커진 고환 내 혈류가 보이지 않아 계류염전으로 진단하였으나, 전산화단층촬영에서는 주변부에 일부 조영증강을 보이는 종괴로 관찰되었고, 수술 이후 림프종이 진단된 증례를 경험하여 보고하고자 한다.

원광대학교 의과대학 원광대학교병원 영상의학과