









Mediastinal Lymph Node Metastasis from Head and Neck Cancer: Predictive Factors and Imaging Features

두경부암의 종격동 림프절 전이: 예측인자 및 영상 소견

Il Kwon Ko, MD¹ , Dae Young Yoon, MD^{1*} , Sora Baek, MD¹ ,
Ji Hyun Hong, MD¹ , Eun Joo Yun, MD¹ , In Jae Lee, MD² 

¹Department of Radiology, Kangdong Seong-Sim Hospital, Hallym University College of Medicine, Seoul, Korea

²Department of Radiology, Hallym University Sacred Heart Hospital, Hallym University College of Medicine, Anyang, Korea

Purpose To assess the predictive factors and describe the imaging features of mediastinal lymph node (MLN) metastases in patients with head and neck cancer.

Materials and Methods We compared the clinical features and disease characteristics (sex, age, site of primary tumor, histologic type, history of prior treatments, TNM stages, and metastasis in cervical LNs) of patients with head and neck cancers between the MLN metastasis and no MLN metastasis groups. We also evaluated the chest CT (distribution and maximum dimension of the largest LN) and PET/CT (maximum standardized uptake value) features of MLN metastases based on the MLN classification.

Results Of the 470 patients with head and neck cancer, 55 (11.7%) had MLN metastasis, involving 150 mediastinal stations. Hypopharynx cancer, recurrent tumor, T4 stage, N2/N3 stages, and M1 stage were found to be significant predicting factors for MLN metastasis. The most common location of MLN metastasis was ipsilateral station 2 (upper paratracheal LNs, 36.4%), followed by ipsilateral station 11 (interlobar LNs, 27.3%) and ipsilateral station 10 (hilar LNs, 25.5%).

Conclusion Metastasis to MLNs should be considered in patients with head and neck cancer, especially in cases that are associated with a hypopharyngeal cancer, recurrent tumor, and high TNM stages.

Index terms Head and Neck Neoplasms; Mediastinum; Lymphatic Metastasis; Positron Emission Tomography Computed Tomography; Computed tomography, X-Ray

Received December 15, 2020

Revised January 24, 2021

Accepted January 26, 2021

*Corresponding author

Dae Young Yoon, MD
Department of Radiology,
Kangdong Seong-Sim Hospital,
Hallym University
College of Medicine,
150 Seongan-ro, Gangdong-gu,
Seoul 05355, Korea.







Tel 82-2-2224-2312

Fax 82-2-2224-2481

E-mail evee0914@chollian.net

This is an Open Access article distributed under the terms of the Creative Commons Attribution Non-Commercial License (<https://creativecommons.org/licenses/by-nc/4.0>) which permits unrestricted non-commercial use, distribution, and reproduction in any medium, provided the original work is properly cited.

ORCID iDs

Il Kwon Ko 
<https://orcid.org/0000-0002-4592-4544>
Dae Young Yoon 
<https://orcid.org/0000-0003-1522-0236>
Sora Baek 
<https://orcid.org/0000-0001-6536-2385>
Ji Hyun Hong 
<https://orcid.org/0000-0003-1039-654X>
Eun Joo Yun 
<https://orcid.org/0000-0001-9310-4340>
In Jae Lee 
<https://orcid.org/0000-0001-9775-5677>

INTRODUCTION

Tumor metastasis to lymph nodes (LNs) is one of the most important prognostic factors for patients with head and neck cancers (1). Head and neck cancers usually spread to regional LNs in the neck. However, although uncommon, they may metastasize to extra-cervical LNs, such as mediastinal LNs (MLNs) (2-5). Metastasis to MLNs may significantly affect treatment planning and have profound impact on the prognosis of the head and neck cancer (6-8). The drainage pathway of neck and mediastinal lymphatic system is divided into superficial or deep and it has ipsilateral or contralateral pathways. Therefore, the distribution of MLN metastasis is also important in the treatment of metastatic disease (9).

There have been only a limited number of studies on the incidence of MLN metastases from head and neck (2-5). To our knowledge, however, no previous studies reported the predictive factors and imaging features of MLN metastasis from head and neck cancer.

Therefore, this study was aimed to assess the predicting factors, and to describe the imaging features of MLN metastases in patients with head and neck cancer.

MATERIALS AND METHODS

PATIENTS

This study was approved by the Institutional Review Board. The requirement to obtain written informed consent from each patient was waived because of the retrospective nature of the study.

We retrospectively reviewed the medical records and imaging results of 829 patients with head and neck cancer, who underwent curative surgical resection in a tertiary head and neck cancer center, between January 2015 and December 2018. Of these, adequate pathological T- or N-staging was not available for 25 patients, and PET/CT was not performed for evaluation of distant metastasis for 334 patients. These patients were excluded from the study. Therefore, a total of 470 patients were finally selected for the study, including 329 men, and 141 women; their ages ranged from 21 to 91 years, with a mean of 58.9 ± 13.0 years.

MLN metastasis was diagnosed with mediastinal dissection/LN biopsy ($n = 11$) or CT imaging features ($n = 44$). MLNs were considered to be metastatic based on imaging findings, if they met at least two of the following criteria: 1) the short-axis diameter ≥ 10 mm or central necrosis, irrespective of its nodal size in contrast-enhanced chest CT (10); 2) maximum standardized uptake (SUV_{max}) ≥ 6.0 in PET/CT (11); 3) $\geq 30\%$ increased in the maximal diameter in following-up chest CT; and 4) $\geq 30\%$ reduction in the maximal diameter after radiotherapy/chemotherapy in following-up chest CT.

IMAGING STUDIES

In accordance with our institutional guidelines, all 470 patients underwent head and neck CT, and torso PET/CT. Additional chest CT scans were performed in 218 patients with suspected MLN metastasis, based on PET/CT findings.

All head and neck CT scans were carried out with a 256-row multidetector CT scanner (Brilliance iCT, Philips Medical Systems, Best, the Netherlands). The technical parameters were

as follows: pitch, 0.61; gantry rotation time, 50 ms; collimation, 6.4×0.625 mm; 120 kVp; 200 mAs; and matrix, 512×512 . The scanning range was from the level of the maxillary sinus to the tracheal bifurcation (mean coverage, 250 mm). Image acquisition was started 90 seconds after administration of intravenous injection of 100 mL of lomeprol 350 mg/mL (lomeron 350, Bracco, Milan, Italy). Axial, coronal, and sagittal images were reconstructed with contiguous slices of 3-mm thickness.

All PET/CT scans were acquired on a combined whole-body PET/CT system (Discovery STE; GE Medical Systems, Milwaukee, WI, USA). The protocol of PET was as follows: minimum fasting time, 6 hours; acceptable blood glucose level, 150 mg/dL; 370–555 MBq (10–15 mCi); ^{18}F -fluorodeoxyglucose (FDG); uptake period, 60 ± 10 min; and intrinsic spatial resolution, 5.1 mm. Non-contrast-enhanced CT was obtained with following parameters: detector configuration, 16×0.625 mm; table speed, 17.5 mm/rot, 120 kVp; 50–170 mAs; slice thickness, 3.75 mm; and image interval, 3.27 mm. The attenuation-corrected PET and CT images were reconstructed using iterative reconstruction algorithm in the axial and coronal planes, with slice thickness of 3.3–3.9 mm.

All chest CT scans were carried out with a 256-row multidetector CT scanner (Brilliance iCT, Philips Medical Systems). The technical parameters were as follows: pitch, 0.92; gantry rotation time, 500 ms; collimation, 6.4×0.625 mm; 120 kVp; 150–200 mAs; and matrix, 512×512 . The scanning range was from the level of apex of lung, to the upper pole of kidney. Image acquisition was started 50 seconds after administration of intravenous injection of 100 mL of Iobitridol 350 mg/mL (Xenetix 350, Guerbet, Villepinte, France). Axial, coronal, and sagittal images were reconstructed, with contiguous slices of 3-mm thickness.

All image interpretations were performed by reviewers who were blinded to the clinical information, the final diagnosis, and the results of the other imaging examinations.

ANALYSIS

For each patient, we retrieved the following data: sex, age at the time of diagnosis, site of primary tumor, histologic type of tumor, history of prior treatments for malignancy (primary tumor or recurrent tumor after treatment), pT, pN, and pM (or cM) status based on the 8th edition of American Joint Committee on Cancer staging system, location of metastatic cervical LNs, and location of MLNs with metastatic involvement (12).

Cervical LNs were classified based on imaging-based nodal classification (13). MLNs were classified based on the International Association for the Study of Lung Cancer Lymph Node Map (14). However, when using these two LN classifications, the levels IV, V, VI, and VII of the cervical LN, and the station I and II regions of the MLN overlap (from the caudal portion of the innominate vein to the cricoid cartilage). For the purpose of the study, the boundary between cervical LNs and MLNs was defined as the upper margin of the manubrium, and bilateral clavicles. The upper border of station I in the MLNs is formed by the lower margin of the cricoid cartilage, the lower border is formed by the upper margin of the manubrium, and the lateral border is formed by the bilateral clavicles. The area includes parts of levels IV, V, and VI of the cervical LN. Therefore, we classified this region (station I of MLN) as cervical LN levels IV, V, and VI. Meanwhile, the upper border of level VII of the cervical LNs is formed by the upper margin of the manubrium, the lower border is formed by the upper margin of

the innominate vein, and the lateral border is formed by the medial margin of the bilateral common carotid artery. We classified this region (level VII of the cervical LN) as station II of MLN.

In our study, all cervical LN and MLN metastases were interpreted on level-by-level and station-by-station bases, respectively. For example, if at least 1 node was confirmed as metastatic node in a given nodal level or station, this level or station was considered to be positive, regardless of the number and size of metastatic nodes. All LN groups were recorded as ipsilateral or contralateral to the primary head and neck cancer because laterality of LN metastasis may affect the prognosis in patient (9).

We also evaluated the chest CT for distribution of MLN metastasis, and for the maximum dimension of the largest LN in each involved station and PET/CT for the highest value of SUV_{max} of LN in each involved station.

We analyzed the association between clinicopathologic features of head and neck cancer, and MLN metastasis. Statistical analysis was performed using the paired Student *t* test for continuous variables and chi-square or Fisher's exact test for categorical variables. A *p*-value of < 0.05 was considered to indicate statistical significance. All statistical analyses were performed using SPSS version 21.0 (IBM Corp., Armonk, NY, USA).

RESULTS

Among 470 patients with head and neck cancer, 55 (11.7%) had MLN metastasis at the time of diagnosis. Table 1 outlines the clinical features and disease characteristics of patients with and without MLN metastasis. Hypopharyngeal cancer ($p = 0.0031$), recurrent tumor ($p = 0.0001$), T4 stage ($p < 0.0001$), N2/N3 stages ($p = 0.0001$), M1 stage ($p < 0.0001$), cervical LN involvements of Level I ($p = 0.0107$), Level II ($p = 0.0128$), III ($p < 0.0001$), IV ($p < 0.0001$), and VI ($p = 0.0211$) were statistically significant predicting factors of MLN metastasis. There was no significant difference in sex, age, histologic type of tumor, and cervical LN involvements of level V and miscellaneous locations between the two groups.

Table 2 shows the distribution and incidence of MLN metastasis in each mediastinal region. Head and neck cancer metastasized to 101 ipsilateral and 49 contralateral MLN stations. The highest incidence of metastasis was observed in ipsilateral station 2 (upper paratracheal LNs, $n = 20$, 36.4%), followed by ipsilateral station 11 (interlobar LNs, $n = 15$, 27.3%), ipsilateral station 10 (hilar LNs, $n = 14$, 25.5%), ipsilateral station 4 (lower paratracheal LNs), and contralateral station 10 (hilar LNs, $n = 13$, 23.5% each). Maximum dimension and SUV_{max} of ipsilateral metastatic MLNs were significantly higher than those of contralateral metastatic MLNs (Table 3).

Figs. 1, 2 show representative cases of MLN metastasis from head and neck cancer.

DISCUSSION

MLN metastasis was thought to be an uncommon event in patients with head and neck cancer. The reported incidence rates of MLN metastasis in head and neck cancer have been variable. The variation in the reported incidence of MLN metastasis depends on the site,

Table 1. Association of Clinopathological Factors with MLN Metastasis in Head and Neck Cancers

Clinical Features	MLN Metastasis (n = 55, %)	No MLN Metastasis (n = 415, %)	p-Value
Sex			0.7542
Male	37 (11.2)	292 (88.8)	
Female	18 (12.8)	123 (87.2)	
Age (years)			0.0310
Mean \pm standard deviation	62.5 \pm 10.4	58.4 \pm 13.3	
Site of primary tumor			
Nasal cavity and paranasal sinus	1 (3.4)	28 (96.6)	0.2588
Tonsil	4 (7.4)	50 (92.6)	0.4130
Larynx	8 (7.8)	95 (92.2)	0.2177
Tongue and oral cavity	8 (10.5)	68 (89.5)	0.8781
Salivary gland	4 (11.1)	32 (88.9)	0.8383
Thyroid	14 (12.7)	96 (87.3)	0.8315
Nasopharynx and oropharynx	6 (22.2)	21 (77.8)	0.1489
Hypopharynx*	10 (28.6)	25 (71.4)	0.0031
Histologic type			0.1002
Squamous cell carcinoma	39 (13.9)	242 (86.1)	
Others	16 (8.5)	173 (91.5)	
Previous treatment			0.0001
Primary tumor	40 (9.5)	380 (90.5)	
Recurrent tumor after treatment	15 (30.0)	35 (70.0)	
T stage			
T1 [†]	2 (1.6)	122 (98.4)	0.0002
T2	11 (8.1)	125 (91.9)	0.2694
T3	15 (13.4)	97 (86.6)	0.6388
T4*	27 (27.6)	71 (72.4)	<0.0001
N stage			
N0 [†]	13 (5.3)	230 (94.7)	<0.0001
N1	15 (14.4)	89 (85.6)	0.4206
N2 and N3*	27 (22.0)	96 (78.0)	0.0001
M stage*			<0.0001
M0	40 (9.0)	403 (91.0)	
M1	15 (55.6)	12 (44.4)	
Metastasis in cervical lymph node [‡]			
Level I*	11 (24.4)	34 (75.6)	0.0107
Level II*	31 (16.5)	157 (83.5)	0.0128
Level III*	31 (22.3)	108 (77.7)	<0.0001
Level IV*	42 (37.2)	71 (62.8)	<0.0001
Level V	8 (23.5)	26 (76.5)	0.0511
Level VI*	10 (23.8)	32 (76.1)	0.0211
Miscellaneous locations	2 (10.5)	17 (89.5)	0.8403

TNM stage was based on the 8th edition of the American Joint Committee on Cancer head and neck cancer staging classification (16). Cervical lymph node classification was based on imaging-based nodal classification (17).

*Significantly higher than negative ones.

[†] Significantly lower than negative ones.

[‡] Percentages do not sum up 100% because some patients had metastatic involvement of more than one cervical area.

MLN = mediastinal lymph node

Table 2. Distribution of MLN Metastases in 55 Patients with Malignant Head and Neck Cancer

Location	Ipsilateral LN with Head and Neck Tumor (n = 101, %)	Contralateral LN with Head and Neck Tumor (n = 49, %)	Total (n = 150, %)
Station 2: upper paratracheal LNs	20 (36.4)	8 (14.5)	28 (50.9)
Station 3: prevascular, retrotracheal LNs	9 (16.4)	2 (3.6)	11 (20.0)
Station 4: lower paratracheal LNs	13 (23.6)	7 (12.7)	20 (36.4)
Station 5: subaortic LNs	4 (7.3)	1 (1.8)	5 (9.1)
Station 6: paraaortic LNs	1 (1.8)	4 (7.3)	5 (9.1)
Station 7: subcarinal LNs	9 (16.4)	1 (1.8)	10 (18.2)
Station 8: paraoesophageal LNs	2 (3.6)	2 (3.6)	4 (7.3)
Station 9: pulmonary ligament LNs	-	-	-
Station 10: hilar LNs	14 (25.5)	13 (23.6)	27 (49.1)
Station 11: interlobar LNs	15 (27.3)	9 (16.4)	24 (43.7)
Station 12: lobar LNs	-	-	-
Station 13: segmental LNs	-	-	-
Station 14: subsegmental LNs	-	-	-

MLN classification was based on the International Association for the Study of Lung Cancer LN Map (18). Percentages do not sum up to 100% because some patients had metastatic involvement of more than one cervical area.

LN = lymph node, MLN = mediastinal LN

Table 3. CT and PET/CT Features of Mediastinal LN Metastasis in Patients with Malignant Head and Neck Cancer

Imaging Features	Ipsilateral LN with Head and Neck Tumor (n = 101)	Contralateral LN with Head and Neck Tumor (n = 49)	p-Value
Maximum dimension (mm) of LN on CT			< 0.0001
Mean \pm standard deviation	17.5 \pm 7.6	13.3 \pm 4.0	
Range	7-51	7-26	
The highest value of SUV _{max} on PET/CT			< 0.0001
Mean \pm standard deviation	6.3 \pm 3.6	4.6 \pm 1.9	
Range	2.0-16.3	2.1-9.2	

Measurements were performed on station-by-station basis.

LN = lymph node, SUV_{max} = maximum standardized uptake value

stage and phenotype of the primary head and neck cancer, and on screening methods used for evaluation of metastasis (15).

In 1987, Kotwall et al. (2) reported an autopsy series of 832 patients with squamous cell carcinoma of the head and neck, and reported 15.6% incidence of MLN metastasis. In 1977, Merino et al. (3) evaluated 5019 patients with squamous cell carcinoma of the upper respiratory and digestive tracts, and reported a 2.9% incidence rate of MLN metastasis. In 2000, de Bree et al. (4) evaluated 101 patients with advanced-stage or recurrent head and neck squamous cell carcinoma using chest CT, and reported that 4.0% of patients had MLN metastasis. In 2017, Duprez et al. (5) evaluated 1022 patients with whole stage squamous cell carcinoma of the oral cavity, larynx, oropharynx, and hypopharynx, and reported an incidence of MLN

Fig. 1. A 55-year-old male with squamous cell carcinoma of the hypopharynx.

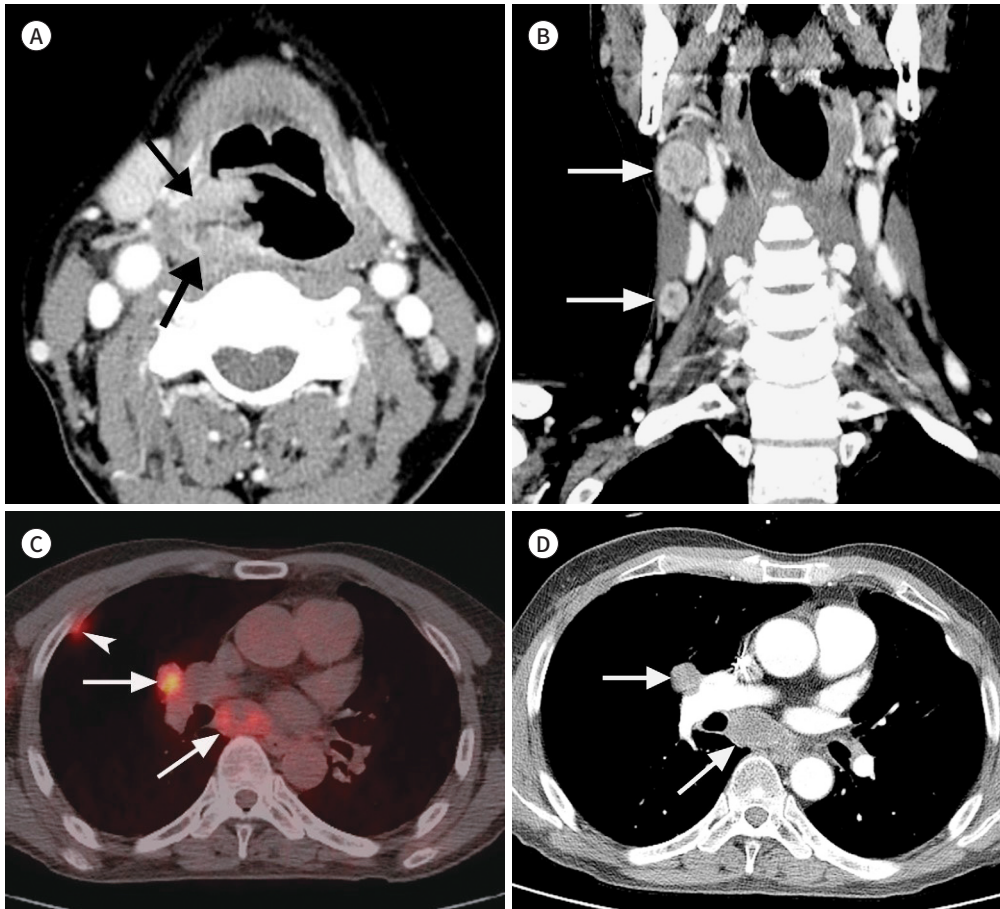
A. Contrast-enhanced axial neck CT shows an ill-defined mass in the right pyriform sinus (arrows).

B. Contrast-enhanced coronal neck CT shows multiple metastatic LNs (arrows) in the right levels II and IV. Partial pharyngectomy and neck dissection confirmed the hypopharyngeal squamous cell carcinoma and metastatic cervical LNs.

C. Axial PET/CT image obtained 3 days after neck CT shows fluorodeoxyglucose uptakes in the mediastinal LNs (arrows) in ipsilateral stations 7 and 10. Note a small uptake (arrowhead) in the subpleural portion of the right lung, suggesting pleural metastasis.

D. Contrast-enhanced axial chest CT shows enlarged necrotic LNs (arrows) in ipsilateral stations 7 and 10. Bronchoscopic biopsy confirmed metastatic squamous cell carcinoma.

LN = lymph node



metastasis of 1.1%. Our study involved the use of PET/CT for screening, and showed a MLN metastasis rate of 11.7% in all patients with head and neck cancer, which is markedly higher than those of clinical studies and slightly lower than that of autopsy studies.

Neck lymphatics can be divided into the superficial and deep lymphatic pathways. The deep lymphatic pathways receive lymphatic drainage from all the LNs of head and neck, whether directly or indirectly through the superficial lymphatic pathway (16). Lymphatic drainage of head and neck cancer is mainly in the deep lymphatic pathways, especially levels II, III, and IV (17-19). The deep lymphatic pathways merge into the right or left jugular lymphatic trunk and are drained into each subclavian vein via the thoracic duct and the right lymphatic duct (16). The efferent upper jugular communicating pathway crosses the midline,

Fig. 2. A 66-year-old male with papillary thyroid cancer.

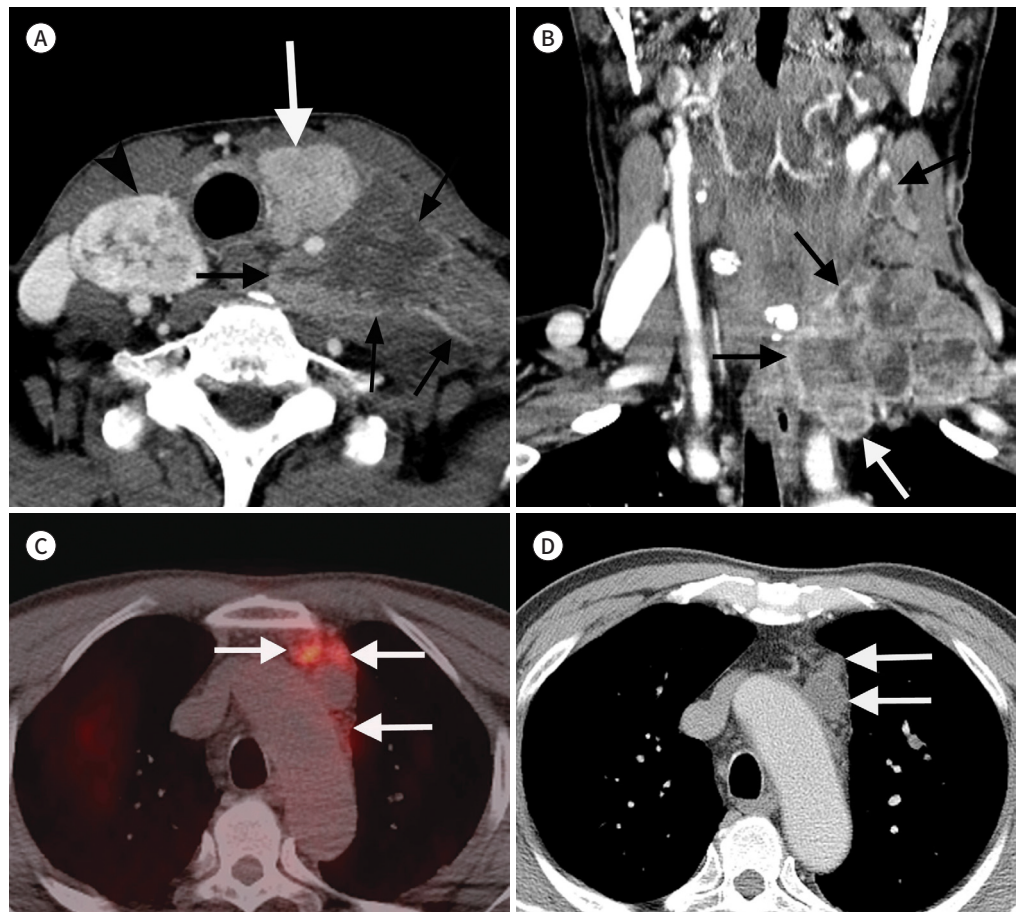
A. Contrast-enhanced axial neck CT shows ill-defined mass in the left thyroid lobe (white arrow), and multiple metastatic LNs (black arrows) in the left levels IV, V, and VI. In addition, note a well-defined mass (arrow-head) in the right thyroid lobe, which was confirmed as a follicular adenoma.

B. Contrast-enhanced coronal neck CT shows multiple conglomerated necrotic metastatic LNs (arrows) in the left lower neck and upper mediastinum. Total thyroidectomy and neck dissection confirmed papillary thyroid cancer and metastatic cervical LNs.

C. Axial PET/CT image obtained 5 days after neck CT shows fluorodeoxyglucose uptake in the mediastinal LNs (arrows) in ipsilateral station 3.

D. Contrast-enhanced axial chest CT shows enlarged necrotic LNs in ipsilateral station 3 (arrows). Mediastinal LN dissection confirmed the metastatic papillary thyroid carcinoma.

LN = lymph node



and drains into the contralateral LNs (20).

Therefore, the pattern of metastasis from head and neck cancer to MLNs is different from the recognized and usual drainage pathways in the neck. The possible explanation for MLN metastasis from head and neck cancer is the retrograde dissemination, caused by the blockage of normal routes of lymphatic drainage due to extensive cervical LN metastasis, or by fibrosis following surgery or radiation therapy. In particular, blockage or fibrosis of the jugular subclavian junction or the surrounding lymphatic system may lead to tumor spread along alternative routes to MLNs (6).

Our study demonstrated that hypopharyngeal cancer, recurrent tumor, T4 stage, N2/N3 stages, M1 stage, and cervical LN involvements of Levels I, II, III, IV, and VI, were statistically

significant predicting factors for MLN metastasis in patients with head and neck cancer. These predicting factors for MLN metastasis are similar to those for distant metastasis from head and neck cancer in previous studies (2, 3, 15, 21-23).

Considering anatomical proximity and the lymphatic drainage system, hypopharyngeal cancers are at risk of harboring MLN metastasis. Other locations of the primary tumor had no significant impact on the presence of MLN metastasis. In addition, disruption of lymphatic pathways due to previous surgery or radiotherapy may result in MLN metastasis along alternative routes, in the presence of recurrent tumors. Both surgery and radiotherapy have been shown to alter normal patterns of cervical lymph flow markedly (24).

In our series, the presence of MLN metastasis was significantly more prevalent in patients with advanced TNM stages. The incidence of MLN metastasis was extremely low in T1 & N0 stages. Results of the present study showed that cervical LN metastasis plays crucial role in MLN metastasis. However, the influence of the location of cervical LN metastasis on the probability of developing MLN metastasis is not clear. Although our data showed the highest rate of MLN metastasis in cases of cervical level IV LN involvement (37.2%), the metastatic involvement of most cervical LN levels were significant predictable factors for MLN metastasis.

In the present study, MLNs in 150 stations of 55 patients with head and neck cancer were found to be metastatic. Head and neck cancer frequently metastasized to the upper zone (stations 2, 3, and 4; 39.3%), and hilar and interlobar zone (stations 10 and 11; 34.0%), while the lower zone (stations 8 and 9; 2.7%) and peripheral zone (stations 12, 13, and 14; 0%) were less likely to be involved. These results can be explained by the distribution of MLN and close anatomical relationship with cervical LNs. In addition, almost one-third of MLN metastases were found in the contralateral mediastinum, which indicates the communicating pathways that cross the midline in the neck and mediastinum. Although our study showed that CT and PET/CT features of MLN metastasis were non-specific, maximum dimension on CT and the highest value of SUV_{max} of ipsilateral MLN metastasis were significantly greater than those of contralateral MLN metastasis. Therefore, it was inferred that head and neck cancer initially metastasize to ipsilateral MLNs, and then to contralateral MLNs.

A variety of screening techniques are employed in routine practice for evaluation of MLN or lung metastasis, in patients with head and neck cancer. Plain chest radiography is relatively cost-effective and is the most commonly performed test for patients with malignancies. If there is a high likelihood of thoracic metastasis, a CT scan of the chest may be more informative than plain chest radiography alone. Nowadays, FDG-PET/CT has generally been considered a useful diagnostic tool for detecting regional and distant metastases (25). In addition, a PET/CT scan would be more useful in head and neck cancers for identifying distant metastasis, especially extrathoracic, as compared to CT of the chest (26, 27). In contrast, PET/CT has also been reported to have low sensitivity for the detection of LN metastasis (28). FDG-PET may fail to detect metastases with low metabolic activity. The usefulness of PET/CT is also limited in non-tumorous hypermetabolic conditions, such as inflammation, which can lead to false positive uptake (29). It is assumed that routine PET/CT scanning for distant metastasis evaluation for head and neck cancer is not justified, and PET/CT is most effective in cases with a higher risk of distant metastasis, for evaluation of distant metastasis, for example, hypopharynx cancer, recurrent tumor, and advanced TNM stages.

There were several limitations to our study. First, this was a retrospective and single center study; therefore, selection bias could exist. Second, pathological confirmation of MLN metastasis was not acquired in all cases, and the data was analyzed on station-by-station basis, instead of node-by-node basis. Third, our series included only those patients who underwent PET/CT, so that we could target a more advanced group of patients. Preoperative mediastinal evaluations by PET/CT should not be performed in small non-advanced head and neck cancers because these tumors are associated with a relatively low risk of nodal metastasis.

In conclusion, Although MLN metastasis from head and neck cancer is uncommon, the knowledge of the predictive factors and distribution of MLNs metastasis is important in the accurate diagnosis and proper management of patients with head and neck cancer. Metastasis to MLNs should be considered in patients with head and neck cancer, especially in cases that are associated with hypopharyngeal cancer, recurrent tumor, and high TNM stages.

Author Contributions

Conceptualization, K.I.K.; data curation, B.S.; formal analysis, H.H.J.; investigation, Y.E.J.; methodology, L.I.J.; project administration, B.S.; resources, H.J.H.; software, Y.E.J.; supervision, Y.D.Y.; validation, K.I.K.; visualization, L.I.J.; writing—original draft, K.I.K.; and writing—review & editing, Y.D.Y.

Conflicts of Interest

The authors have no potential conflicts of interest to disclose.

Funding

None

REFERENCES

1. Layland MK, Sessions DG, Lenox J. The influence of lymph node metastasis in the treatment of squamous cell carcinoma of the oral cavity, oropharynx, larynx, and hypopharynx: N0 versus N+. *Laryngoscope* 2005;115:629-639
2. Kotwall C, Sako K, Razack MS, Rao U, Bakamjian V, Shedd DP. Metastatic patterns in squamous cell cancer of the head and neck. *Am J Surg* 1987;154:439-442
3. Merino OR, Lindberg RD, Fletcher GH. An analysis of distant metastases from squamous cell carcinoma of the upper respiratory and digestive tracts. *Cancer* 1977;40:145-151
4. de Bree R, Deurloo EE, Snow GB, Leemans CR. Screening for distant metastases in patients with head and neck cancer. *Laryngoscope* 2000;110:397-401
5. Duprez F, Berwouts D, De Neve W, Bonte K, Boterberg T, Deron P, et al. Distant metastases in head and neck cancer. *Head Neck* 2017;39:1733-1743
6. Ng SH, Chang JT, Chan SC, Ko SF, Wang HM, Liao CT, et al. Nodal metastases of nasopharyngeal carcinoma: patterns of disease on MRI and FDG PET. *Eur J Nucl Med Mol Imaging* 2004;31:1073-1080
7. Joo YH, Sun DI, Cho KJ, Cho JH, Kim MS. The impact of paratracheal lymph node metastasis in squamous cell carcinoma of the hypopharynx. *Eur Arch Otorhinolaryngol* 2010;267:945-950
8. Zhang TT, Qu N, Hu JQ, Shi RL, Wen D, Sun GH, et al. Mediastinal lymph node metastases in thyroid cancer: characteristics, predictive factors, and prognosis. *Int J Endocrinol* 2017;2017:1868165
9. Tankéré F, Camproux A, Barry B, Guedon C, Depondt J, Gehanno P. Prognostic value of lymph node involvement in oral cancers: a study of 137 cases. *Laryngoscope* 2000;110:2061-2065
10. Toloza EM, Harpole L, McCrory DC. Noninvasive staging of non-small cell lung cancer: a review of the current evidence. *Chest* 2001;123:137S-146S
11. Kumar A, Dutta R, Kannan U, Kumar R, Khilnani GC, Gupta SD. Evaluation of mediastinal lymph nodes using F-FDG PET-CT scan and its histopathologic correlation. *Ann Thorac Med* 2011;6:11-16
12. Huang SH, O'Sullivan B. Overview of the 8th edition TNM classification for head and neck cancer. *Curr Treat*

Options Oncol 2017;18:40

13. Som PM, Curtin HD, Mancuso AA. Imaging-based nodal classification for evaluation of neck metastatic adenopathy. *AJR Am J Roentgenol* 2000;174:837-844
14. El-Sherief AH, Lau CT, Wu CC, Drake RL, Abbott GF, Rice TW. International association for the study of lung cancer (IASLC) lymph node map: radiologic review with CT illustration. *Radiographics* 2014;34:1680-1691
15. Ferlito A, Shaha AR, Silver CE, Rinaldo A, Mondin V. Incidence and sites of distant metastases from head and neck cancer. *ORL J Otorhinolaryngol Relat Spec* 2001;63:202-207
16. Lengelé B, Hamoir M, Scalliet P, Grégoire V. Anatomical bases for the radiological delineation of lymph node areas. Major collecting trunks, head and neck. *Radiother Oncol* 2007;85:146-155
17. Iyer NG, Shaha AR, Ferlito A, Thomas Robbins K, Medina JE, Silver CE, et al. Delphian node metastasis in head and neck cancers--oracle or myth? *J Surg Oncol* 2010;102:354-358
18. Teymoortash A, Werner JA. Current advances in diagnosis and surgical treatment of lymph node metastasis in head and neck cancer. *GMS Curr Top Otorhinolaryngol Head Neck Surg* 2012;11:Doc04
19. Ossoff RH, Sisson GA. Lymphatics of the floor of the mouth and neck: anatomical studies related to contralateral drainage pathways. *Laryngoscope* 1981;91:1847-1850
20. Kowalski LP. Noncervical lymph node metastasis from head and neck cancer. *ORL J Otorhinolaryngol Relat Spec* 2001;63:252-255
21. Troell RJ, Terris DJ. Detection of metastases from head and neck cancers. *Laryngoscope* 1995;105:247-250
22. Alvi A, Johnson JT. Development of distant metastasis after treatment of advanced-stage head and neck cancer. *Head Neck* 1997;19:500-505
23. Liu JC, Bhayani M, Kuchta K, Galloway T, Fundakowski C. Patterns of distant metastasis in head and neck cancer at presentation: implications for initial evaluation. *Oral Oncol* 2019;88:131-136
24. Fisch UP. Cervical lymph flow in man following radiation and surgery. *Trans Am Acad Ophthalmol Otolaryngol* 1965;69:846-868
25. Rohren EM, Turkington TG, Coleman RE. Clinical applications of PET in oncology. *Radiology* 2004;231:305-332
26. Krabbe CA, Pruim J, van der Laan BF, Rödiger LA, Roodenburg JL. FDG-PET and detection of distant metastases and simultaneous tumors in head and neck squamous cell carcinoma: a comparison with chest radiography and chest CT. *Oral Oncol* 2009;45:234-240
27. Rohde M, Nielsen AL, Johansen J, Sørensen JA, Nguyen N, Diaz A, et al. Head-to-head comparison of chest x-ray/head and neck MRI, chest CT/head and neck MRI, and 18F-FDG PET/CT for detection of distant metastases and synchronous cancer in oral, pharyngeal, and laryngeal cancer. *J Nucl Med* 2017;58:1919-1924
28. Kim SK, Kang KW, Lee JS, Kim HK, Chang HJ, Choi JY, et al. Assessment of lymph node metastases using 18F-FDG PET in patients with advanced gastric cancer. *Eur J Nucl Med Mol Imaging* 2006;33:148-155
29. Tsunoda Y, Ito M, Fujii H, Kuwano H, Saito N. Preoperative diagnosis of lymph node metastases of colorectal cancer by FDG-PET/CT. *Jpn J Clin Oncol* 2008;38:347-353

두경부암의 종격동 림프절 전이: 예측인자 및 영상 소견

고일권¹ · 윤대영^{1*} · 백소라¹ · 홍지현¹ · 윤은주¹ · 이인재²

목적 본 연구의 목적은 두경부암의 종격동 림프절 전이의 예측인자와 영상 소견을 알아보고자 함이다.

대상과 방법 이 연구에서 저자들은 두경부암 환자 중에서 종격동 림프절 전이그룹과 비전이 그룹 사이의 임상 소견 및 질병의 특성(성별, 연령, 원발성 종양 부위, 조직학적 유형, 악성종양에 대한 이전 치료이력, T, N- 및 M- 단계, 경부 림프절 전이) 들을 비교하였다. 또한 저자들은 전이그룹에서 종격동 림프절 분류에 따라 림프절 전이의 흉부 전산화단층촬영(전이분포와 림프절 최대직경) 및 양전자방출단층촬영/전산화단층촬영(최대 표준섭취계수)의 소견을 평가하였다.

결과 두경부암 환자 470명 중 55명(11.7%)에서 150개의 종격동 station을 포함하는 종격동 림프절 전이가 발견되었다. 하인두암, 재발한 종양, T4, N2/N3, 및 M1 단계는 종격동 림프절 전이의 의미 있는 예측인자로 평가되었다. 종격동 림프절 전이의 가장 흔한 위치는 일측 station 2 (상부기관주위 림프절, 36.4%), 일측 station 11 (엽간 림프절, 27.3%), 일측 station 10 (폐문 림프절, 25.5%) 순이었다.

결론 하인두암, 재발성 종양 및 높은 TNM 단계인 경우, 두경부암의 종격동 림프절 전이 가능성을 고려하여야 한다.

¹한림대학교 의과대학 강동성심병원 영상의학과,

²한림대학교 의과대학 한림대학교성심병원 영상의학과