



# Angiographic Findings of an Isolated Meandering Pulmonary Vein: A Case Report

## 단독 사행 폐정맥의 혈관 조영술 소견: 증례 보고

Ji Su Ko, MD , Lyo Min Kwon, MD\* , Han Myun Kim, MD ,  
Ji Young Woo, MD , Yoo Na Kim, MD , Jung Won Moon, MD

Department of Radiology, Hallym University Kangnam Sacred Heart Hospital, Seoul, Korea

A meandering pulmonary vein (MPV) is a rare pulmonary vascular anomaly characterized by an abnormal course of the pulmonary vein draining into the left atrium. We report the case of a 55-year-old female who was diagnosed with a right MPV on pulmonary angiography. Enhanced chest CT revealed a vascular structure with an abnormal course that drained into the right superior pulmonary vein in the right upper lobe, which resembled a pulmonary arteriovenous malformation (AVM). Pulmonary angiography performed to discriminate between an MPV and pulmonary AVM showed no feeding artery, normal parenchymal staining, and drainage to the left atrium via the culprit vessel. Thus, the patient was diagnosed with MPV. When an MPV is difficult to differentiate from other vascular anomalies on enhanced chest CT, pulmonary angiography can be helpful. By recognizing the angiographic findings of an MPV, unnecessary treatment can be prevented.

**Index terms** Pulmonary Veins; Congenital Abnormalities; Angiography;  
Arteriovenous Malformation; Scimitar Syndrome

## INTRODUCTION

A meandering pulmonary vein (MPV) is a very rare pulmonary vascular anomaly (1). It is characterized by a meandering path with the pulmonary vein draining into the left atrium, and can be confused with scimitar syndrome and pulmonary arteriovenous malformation (AVM) (1-3). MPV is a rare disease with 20 case reports, and few reports on angiography findings have been reported (3, 4). Herein, we report a case of MPV, focusing on its angiographic findings, which was confused with pulmonary AVM on contrast-enhanced chest CT in a healthy asymptomatic patient.

Received September 30, 2020  
Revised November 4, 2020  
Accepted November 7, 2020

\*Corresponding author  
Lyo Min Kwon, MD  
Department of Radiology,  
Hallym University  
Kangnam Sacred Heart Hospital,  
1 Singil-ro, Yeongdeungpo-gu,  
Seoul 07441, Korea.

Tel 82-2-829-5241  
Fax 82-2-829-5155  
E-mail lisa516@hanmail.net

This is an Open Access article distributed under the terms of the Creative Commons Attribution Non-Commercial License (<https://creativecommons.org/licenses/by-nc/4.0>) which permits unrestricted non-commercial use, distribution, and reproduction in any medium, provided the original work is properly cited.

### ORCID iDs

Ji Su Ko   
<https://orcid.org/0000-0001-6589-2431>  
Lyo Min Kwon   
<https://orcid.org/0000-0001-5611-2480>  
Han Myun Kim   
<https://orcid.org/0000-0003-4594-8527>  
Ji Young Woo   
<https://orcid.org/0000-0002-6200-0159>  
Yoo Na Kim   
<https://orcid.org/0000-0003-2580-418X>  
Jung Won Moon   
<https://orcid.org/0000-0002-7444-0709>

## CASE REPORT

A 55-year-old healthy female with no relevant medical history visited our hospital for abnormal chest radiographic finding during a medical check-up. The posterior-anterior chest radiography showed a nodular opacity in the right upper lung zone (Fig. 1A). She had no respiratory symptoms and showed no abnormal findings on physical examination. Transcutaneous oxygen saturation was in the normal range. For further evaluation, a contrast-enhanced chest CT was performed. The nodular opacity observed on chest radiography was a vascular structure in the right upper lobe (RUL) with an abnormal course, which drained into the left atrium (Fig. 1B, C). The vascular structure was not clearly connected to the pulmonary artery, but it was difficult to rule out the possibility of a pulmonary AVM. There was no hypoplasia of the lung and no anomaly was seen in the heart and bronchus. Therefore, angiography and elective embolization were requested.

Pulmonary angiography via the right femoral vein was performed under local anesthesia using a 6-Fr guiding sheath (Flexor Ansel Guiding sheath, Cook Medical, Bloomington, IN, USA). The sheath was placed in the main pulmonary trunk and a right pulmonary angiography was performed with a 5-Fr angiographic catheter (Davis, A&A Medical Device, Seongnam, Korea). On pulmonary angiography, a vascular structure having a meandering path and draining in the left atrium was observed in the RUL, but there was no feeding artery and no early drainage (Fig. 1D). Selective angiographies using a 2-Fr microcatheter (Progreat, Terumo, Tokyo, Japan) at RUL segmental arteries showed a normal venous drainage into the right superior pulmonary vein through the aberrant anomalous vein after parenchymal staining (Fig. 1E). An isolated MPV was diagnosed based on the absence of an arterial communication. It was not an AVM, but one of the normal variations. There was no intraprocedural complication and the patient was discharged without further treatment.

## DISCUSSION

MPV was first reported by Kozuka and Nosaki in 1968 (5). The term 'MPV' was first used by Goodman et al. (6) in the presence of scimitar sign to define the abnormal splitting of the right pulmonary vein into the left atrium.

MPV is a rare pulmonary venous anomaly, also referred to as pseudo-scimitar syndrome or scimitar variant. It has been sometimes confused with the classical scimitar syndrome and pulmonary AVM (2, 3). It is important to distinguish MPV from other vascular anomalies to determine whether to treat or not.

Scimitar syndrome has three main characteristic findings: the right pulmonary vein draining into the inferior vena cava, a systemic arterial supply of the lung, and hypoplasia of the right lung. Meanwhile, an isolated MPV drains into the left atrium and there is no systemic arterial supply and hypoplasia of the lung (1, 7). Pulmonary AVM is another differential diagnosis which presents as an abnormal communication between the pulmonary artery and vein without a capillary bed, contrary to an MPV which has a normal lung capillary bed (2). The presence of feeding arteries and the location of the pulmonary venous drainage are important in discriminating between MPV and other diseases (1, 2). Diagnostic findings of iso-

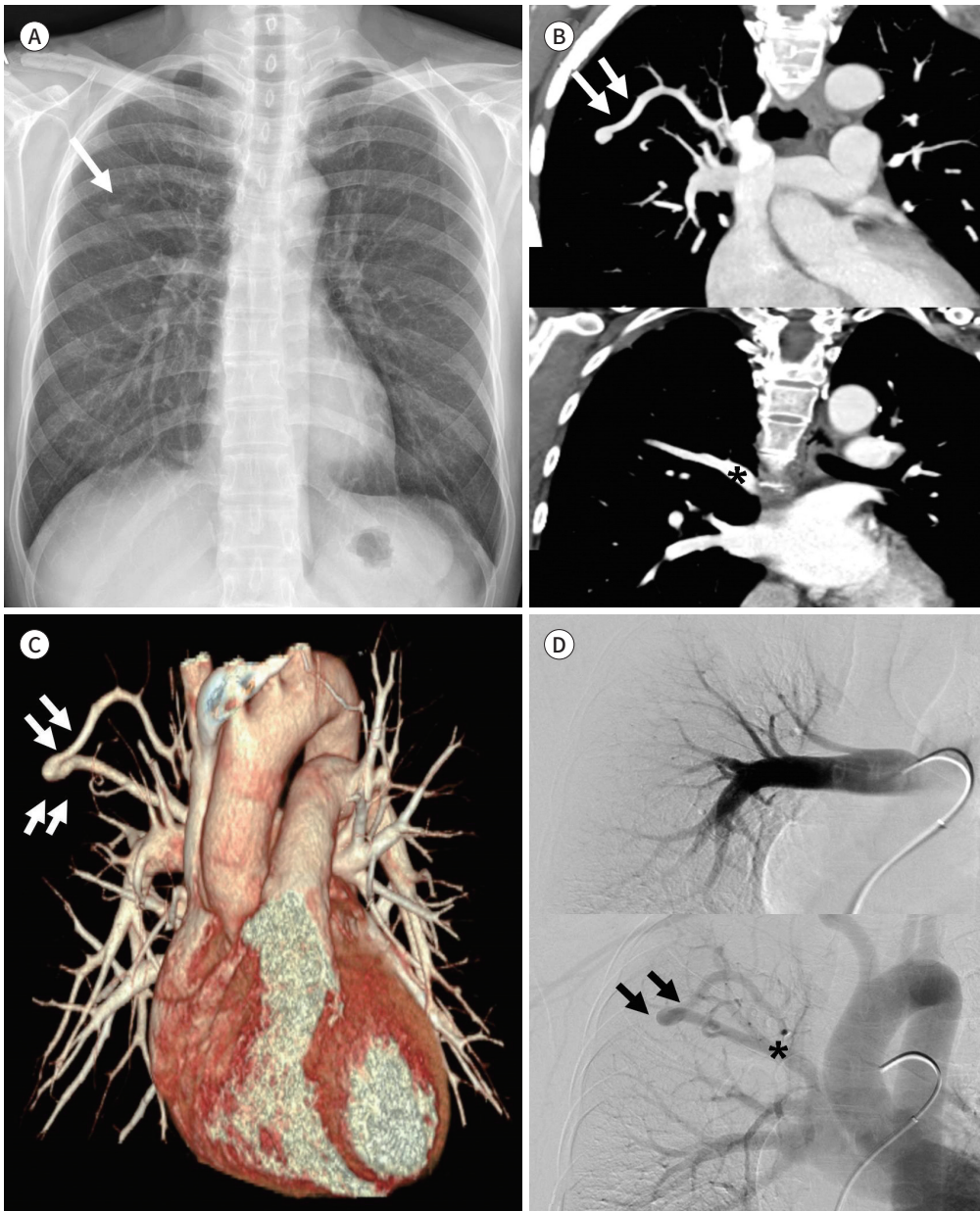
**Fig. 1.** A 55-year-old female with a meandering pulmonary vein.

**A.** Chest radiograph shows a nodular opacity (arrow) in the right upper lung zone with a normal cardiac silhouette.

**B.** Contrast-enhanced chest CT coronal images (upper) show a tortuous vascular structure in the right upper lobe (arrows) emptying into the left atrium via the right superior pulmonary vein (asterisk) (lower).

**C.** A three-dimensional reformatted volume-rendered image shows the aberrant anomalous vein (arrows) with a tortuous course draining into the left atrium.

**D.** Pulmonary angiography shows normal arterial vessels without evidence of a feeding artery (upper) and the tortuous vein (arrows) draining into the right superior pulmonary vein (asterisk) (lower).

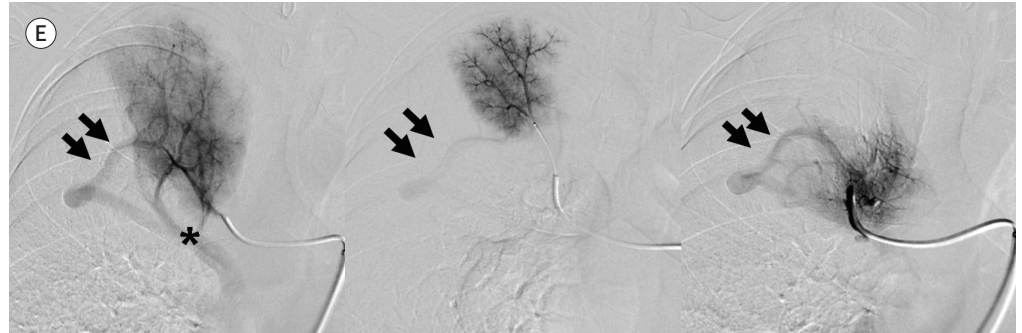

lated MPV, scimitar syndrome, and pulmonary AVM are summarized in Table 1.

With the advance in technology, multidetector CT (MDCT), MR angiography, and reformatted images are main diagnostic methods because they can well demonstrate the vascular structure (3). However, it may be difficult to discriminate between an MPV and pulmonary

**Fig. 1.** A 55-year-old female with a meandering pulmonary vein.

**E.** Pulmonary selective arteriography in several segmental arteries show normal parenchymal staining and normal venous drainage into the right superior pulmonary vein (asterisk) through the tortuous vein (arrows) in the right upper lobe.

**Table 1.** Diagnostic Findings of Isolated MPV, Scimitar Syndrome, and Pulmonary AVM

	Isolated MPV	Scimitar Syndrome	Pulmonary AVM
Clinical features	Asymptomatic	Asymptomatic or pulmonary infection/dyspnea	Asymptomatic or dyspnea
Arterial structure	No systemic arterial supply	Systemic arterial supply to the lung	Nidus with feeding artery
Venous drainage	Left atrium	Inferior vena cava	Left atrium
Associated anomaly	-	Congenital heart disease, hypoplasia of the right lung	Hereditary hemorrhagic telangiectasia

AVM = arteriovenous malformation, MPV = meandering pulmonary vein

AVM with a MDCT only like in this case; pulmonary angiography can therefore be helpful. Pulmonary angiography shows the diagnostic findings of an MPV: the absence of feeding arteries and an abnormal arteriovenous communication, with an aberrant pulmonary vein draining into the left atrium after staining the normal lung capillary bed.

MPV drains to the left atrium, so if there is no accompanying vascular anomaly, it is usually detected incidentally without symptoms (3). Associated vascular anomalies should be checked because surgical treatment may be required (7). In some cases, MPV drains in the inferior vena cava, resulting in asymptomatic left-to-right shunt requiring a surgical ligation between the MPV and the inferior vena cava (8, 9). The reported associated anomalies include ipsilateral absence of the middle bronchus and interlobar fissures, and right pulmonary hypoplasia (2). In the case described by Goodman et al. (6), dextrocardia and hypoplasia of the right main pulmonary artery was noted. Focal systemic arterial blood supply from the abdominal aorta or celiac trunk in the right lower lobe was also reported to be an associated anomaly (1, 4, 7). Lung resection has been required in patients with bronchiectasis or chronic parenchymal lung disease secondary to the abnormal arterial supply to the right lower lobe (10).

We reported the angiographic findings of an isolated right-sided MPV without associated vascular anomalies. By recognizing the angiographic findings of an MPV, unnecessary treatment, such as embolization or surgery can be prevented.

#### Author Contributions

Conceptualization, K.L.M., K.H.M.; data curation, K.J.S., W.J.Y.; investigation, K.J.S.; methodology,

W.J.Y., K.Y.N., M.J.W.; project administration, K.L.M., K.H.M.; resources, K.J.S., K.L.M.; supervision, K.L.M.; visualization, K.L.M., K.H.M.; writing—original draft, K.J.S., K.L.M.; and writing—review & editing, K.L.M., K.Y.N., M.J.W.

### Conflicts of Interest

The authors have no potential conflicts of interest to disclose.

### Funding

None

## REFERENCES

1. Lee M, Jeon KN, Park MJ, Bae K. Meandering pulmonary veins: two case reports. *Medicine (Baltimore)* 2020;99:e19815
2. Sneha Harish C, Dixit R, Agarwal A, Garg A. Meandering pulmonary vein: a case report. *J Radiol Case Rep* 2020;14:7-13
3. Aygun MS, Çalık M, Çalık SG. Meandering pulmonary vein: very rare incidental finding. *Eurasian J Pulmonol* 2018;20:43-45
4. Al-Naami GH, Abu-Sulaiman RM. A familial variant of the Scimitar syndrome with a meandering pulmonary vein. *Cardiol Young* 2006;16:308-309
5. Kozuka T, Nosaki T. A pulmonary vein anomaly: unusual connection and tortuosity of the right lower lobe vein. *Br J Radiol* 1968;41:232-234
6. Goodman LR, Jamshidi A, Hipona FA. Meandering right pulmonary vein simulating the Scimitar syndrome. *Chest* 1972;62:510-512
7. Tortoriello TA, Vick GW 3rd, Chung T, Bezold LI, Vincent JA. Meandering right pulmonary vein to the left atrium and inferior vena cava: the first case with associated anomalies. *Tex Heart Inst J* 2002;29:319-323
8. Gazzaniga AB, Matloff JM, Harken DE. Anomalous right pulmonary venous drainage into the inferior vena cava and left atrium. *J Thorac Cardiovasc Surg* 1969;57:251-254
9. Takeda S, Imachi T, Arimitsu K, Minami M, Hayakawa M. Two cases of scimitar variant. *Chest* 1994;105:292-293
10. Sanger PW, Taylor FH, Robicsek F. The "scimitar syndrome." Diagnosis and treatment. *Arch Surg* 1963; 86:580-587

## 단독 사행 폐정맥의 혈관 조영술 소견: 증례 보고

고지수 · 권려민\* · 김한면 · 우지영 · 김유나 · 문정원

사행 폐정맥(meandering pulmonary vein)은 드물게 보이는 폐 혈관 이상으로, 사행성 주행을 보이는 폐정맥이 좌심방으로 배출되는 것을 특징으로 하는 질환이다. 우리는 조영증강 흉부 전산화단층촬영 및 폐 혈관 조영술 후 우측 사행 폐정맥으로 진단된 55세 여성 환자를 보고하고자 한다. 조영증강 흉부 전산화단층촬영상 우상폐정맥으로 배출되는 구불구불한 사행성 경로를 보이는 혈관구조물이 우상엽에 있었고, 폐 동정맥 기형이 의심되었다. 진단 및 치료를 위해 폐혈관 조영술이 시행되었고, 폐혈관 조영술에서 먹이 동맥(feeding artery)은 보이지 않았고, 환자는 우측 사행 폐정맥으로 진단되었다. 조영증강 흉부 전산화단층촬영에서 사행 폐정맥과 다른 혈관 기형의 감별이 어려운 경우, 폐혈관 조영술 소견이 진단에 도움이 되며, 추가로 시행할 수 있는 진단도구가 되겠다. 사행 폐정맥의 혈관 조영 소견을 인식함으로써 불필요한 치료가 시행되는 것을 예방할 수 있다.

한림대학교 강남성심병원 영상의학과