



Extrahepatic Bile Duct Duplication with Intraductal Papillary Neoplasm: A Case Report

이중 담관 기형과 동반된 담관 관내 유두종 : 증례 보고

Gayoung Jeon, MD , Juwan Choi, MD*

Department of Radiology, Daegu Fatima Hospital, Daegu, Korea

Extrahepatic duct duplication is an extremely rare congenital anomaly. Hilar cholangiocarcinoma with extrahepatic bile duct duplication was reported; however, intraductal papillary neoplasm of the bile duct (IPNB) with extrahepatic bile duct duplication has not been reported to the best of our knowledge. We report a rare case of IPNB with extrahepatic bile duct duplication of a 64-year-old female. The patient underwent extended right hepatectomy, and the results of a subsequent histopathological examination were consistent with an IPNB with extrahepatic bile duct duplication. We report this rare case with radiologic imaging findings and a brief review of the current literature.

Index terms Bile Ducts, Extrahepatic; Bile Duct Disease; Bile Duct Neoplasms; Extrahepatic Biliary System

INTRODUCTION

Extrahepatic duct duplication is an extremely rare congenital anomaly with only 24 cases reported until 1986 (1). The types of duplication were classified into five categories. Type V is characterized by single drainage of two extrahepatic bile ducts categorized as subtype Va and Vb, according to the number of communication channels between duplicated ducts (Fig. 1A) (2).

Choledocholithiasis and anomalous union of the pancreaticobiliary duct are well-known complications of the extrahepatic duct duplication, including pancreatitis, cholangitis, and cholecystitis (3).

We report a case of extrahepatic duct duplication complicated by an intraductal papillary neoplasm of the bile duct (IPNB) with imaging findings of multidetector CT (MDCT) and MR cholangiopancreatography (MRCP), which was finally confirmed in the patho-

Received June 5, 2020
Revised August 3, 2020
Accepted November 12, 2020

*Corresponding author
Juwan Choi, MD
Department of Radiology,
Daegu Fatima Hospital,
99 Ayang-ro, Dong-gu,
Daegu 41199, Korea.

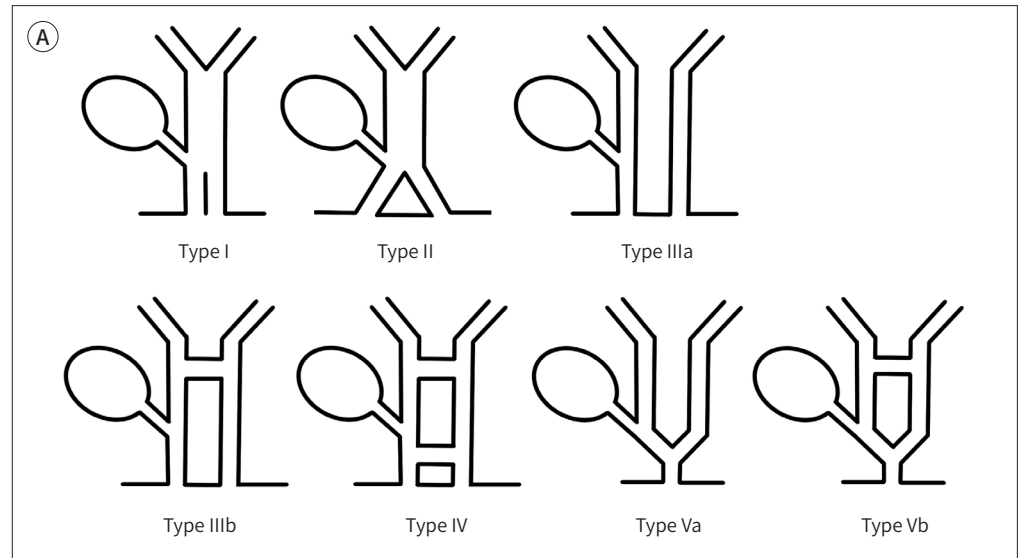
Tel 82-53-940-7161
E-mail wanmann@naver.com

This is an Open Access article distributed under the terms of the Creative Commons Attribution Non-Commercial License (<https://creativecommons.org/licenses/by-nc/4.0>) which permits unrestricted non-commercial use, distribution, and reproduction in any medium, provided the original work is properly cited.

ORCID iDs

Gayoung Jeon
<https://orcid.org/0000-0002-4276-8152>
Juwan Choi
<https://orcid.org/0000-0003-3837-9047>

Fig. 1. A 64-year-old female with extrahepatic bile duct duplication combined intraductal papillary neoplasm. **A.** Saito et al. (4) made a modified classification and Choi et al. (2) proposed the fifth configuration type. Type Va includes single drainage without any communication between two extrahepatic bile ducts, while Type Vb includes single drainage with one or more communication channels.



logic evaluation after surgery.

CASE REPORT

A 64-year-old female was admitted to our hospital with right upper abdominal pain and dyspepsia for several days. On physical examination, tenderness was found in the right upper abdominal area. She was admitted with right upper abdominal pain 10 years previously. CT showed distal common bile duct (CBD) stones with combined obstructive cholangitis and cholecystitis (Fig. 1B). She underwent endoscopic retrograde cholangiopancreatography (ERCP), and delayed cholecystectomy was performed. Laboratory tests at this admission revealed an elevated erythrocyte sedimentation rate (43 mm/h), alkaline phosphatase (128 IU/L), gamma glutamyl transferase (191 IU/L), low-density lipoprotein (134 mg/dL), and triacylglycerol (257 mg/dL). CT scan showed markedly dilated intra- and extra-bile ducts without a distal obstructing cause. Two extrahepatic bile ducts were connected at the hepatic hilum and were joined together at the distal CBD. Anomalous pancreaticobiliary ductal union was not identified. CT scan also revealed a single intra-biliary lesion extending from the right main intrahepatic duct to the right side of the duplicated extrahepatic duct. This lesion was thought to be an intra-/extrahepatic duct stone due to a previous history of CBD stone; however, it showed improvement in the arterial and portal phase of enhanced CT scan (Fig. 1C).

MRCP was also performed. In T2-weighted images, an intra-biliary lesion with papillary projection was detected and showed intermediate signal intensity. In diffusion-weighted image ($b = 800$), it showed diffusion restriction (Fig. 1D). A three-dimensional maximum intensity projection (3D MIP) image showed diffused dilatation of the intrahepatic and extrahepatic bile ducts, and extrahepatic duct duplication with proximal communication. The duplicated

Fig. 1. A 64-year-old female with extrahepatic bile duct duplication combined intraductal papillary neoplasm.
B. Contrast-enhanced abdominal CT scan performed 10 years ago. Axial CT images sequentially show extrahepatic duct duplication. Cystic duct (black arrows), right side of duplicated bile ducts (white arrows), and left side of duplicated bile ducts (white arrowheads) are seen. A single distal common bile duct is noted (black arrowhead).
C. Multiphase contrast-enhanced abdominal CT scan at present (pre-contrast, arterial phase, portal phase, and delayed phase images in clockwise order). Axial images show extrahepatic bile duct duplication (white arrows). Intrahepatic bile duct dilatation and an intraductal mass like lesion (black arrows) with enhancement in the arterial phase is seen.

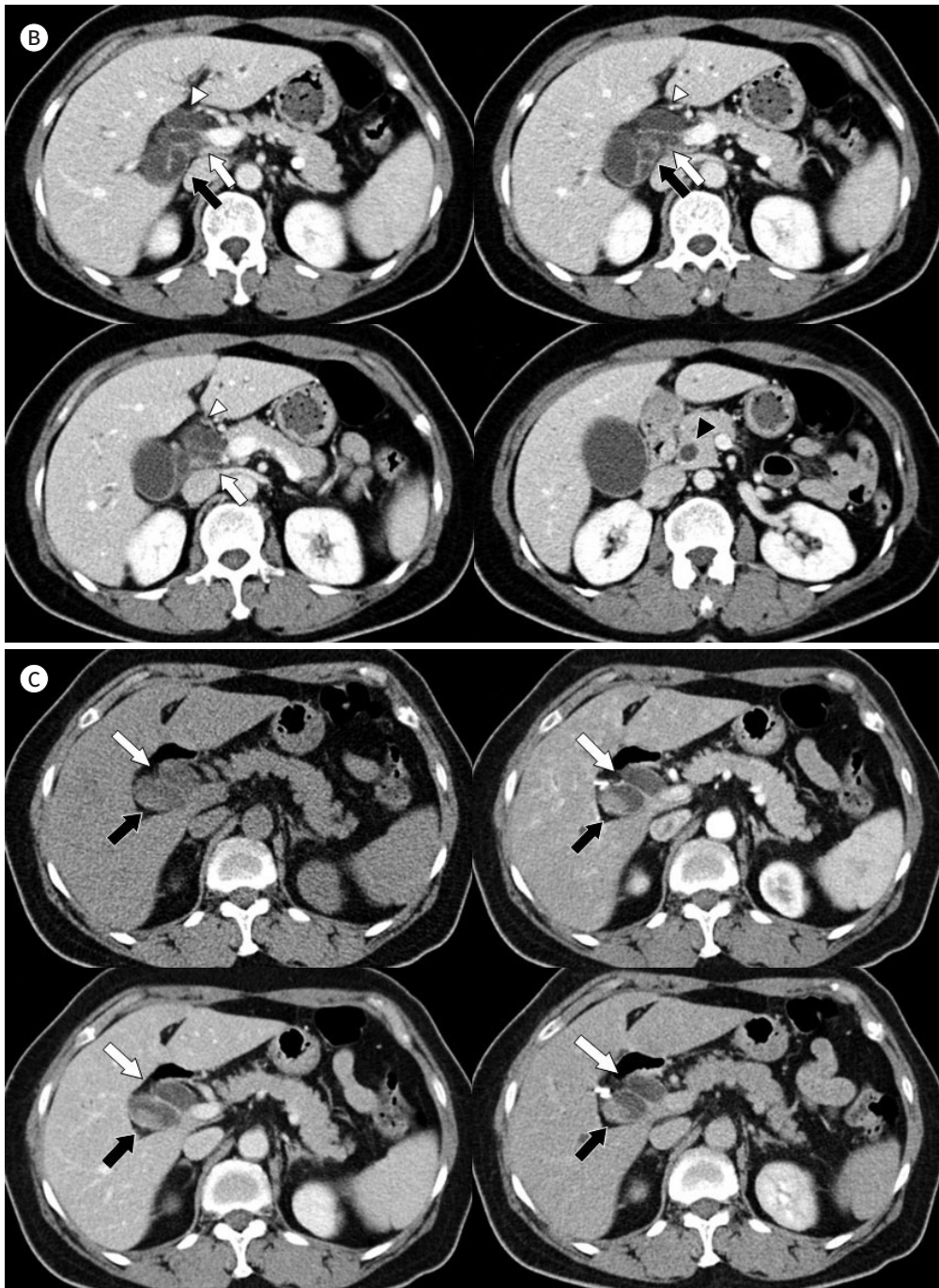


Fig. 1. A 64-year-old female with extrahepatic bile duct duplication combined intraductal papillary neoplasm.
D. Sequential T2 weighted axial images (upper left, upper right, lower left) show a mass with papillary projection which is intermediate signal intensity and extended from right main intrahepatic duct (arrowheads) to the right side of the duplicated extrahepatic ducts (thin arrows). Proximal communication of the extrahepatic bile duct duplication is seen (thick arrow). Axial diffusion-weighted image (b = 800, lower right) shows the diffusion restriction of the intraductal papillary neoplasm of the bile duct (arrows).
E. MR cholangiopancreatography. The three-dimensional maximum intensity projection image shows diffuse biliary tree dilatation, including intrahepatic and extrahepatic bile duct, and the duplication of the extrahepatic bile duct (white arrows) with proximal communication (arrowhead). The duplicated ducts join into a single common bile duct (black arrow). The cystic stump is seen in the right side of the duplicated extrahepatic bile duct (black arrowhead). These findings are seen clearer than in a multidetector CT image because the duplicated extrahepatic ducts are aligned obliquely and vertically.

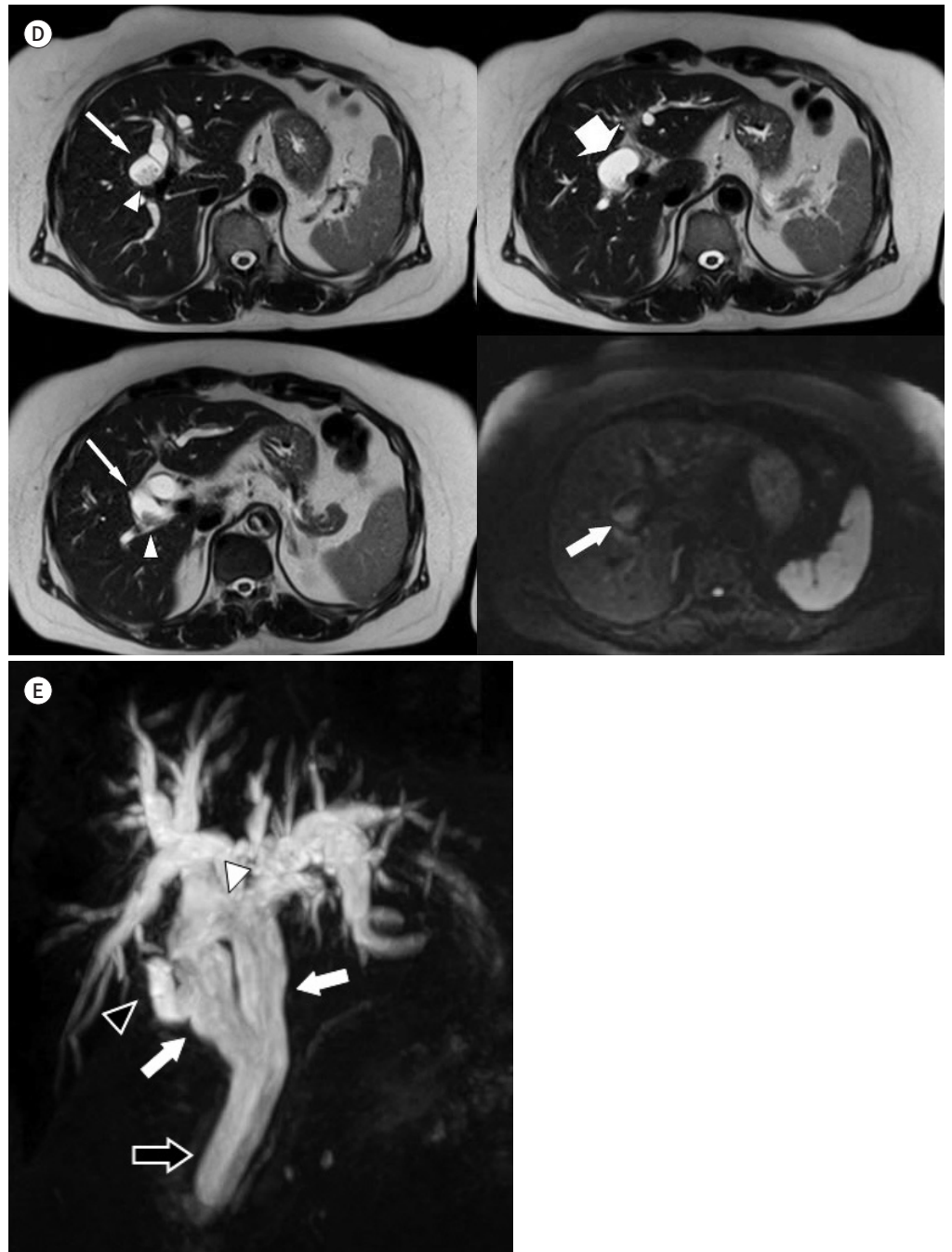
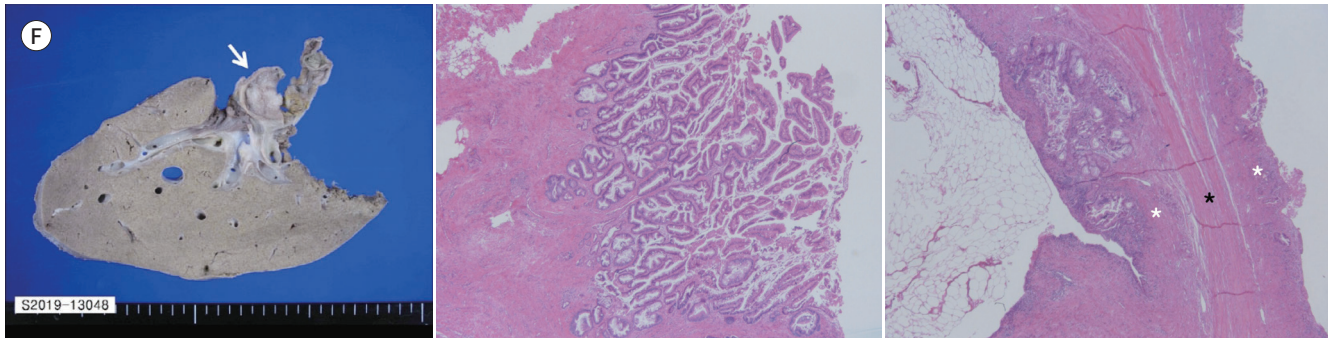


Fig. 1. A 64-year-old female with extrahepatic bile duct duplication combined intraductal papillary neoplasm.

F. Pathologic examination. The gross specimen photograph shows a 17 mm × 13 mm mass filling the bile duct (left, arrow). Photomicrography (hematoxylin and eosin staining, × 20, middle) shows papillary projections of the intraductal papillary neoplasm of the bile duct. Photomicrography (hematoxylin and eosin staining, × 20, right) shows the muscle layer of the common bile duct (black star) and mucosal layer (white stars) are lying on both sides of the muscle. It implies extrahepatic duct duplication.



ducts finally joined together into a single CBD. The cystic duct stump was seen on the right side of the duplicated extrahepatic bile duct (Fig. 1E).

ERCP was performed to decompress the dilated biliary tree and to obtain a specimen for histopathologic examination. Many mucinous products were drained. The cytology of bile was obtained from endoscopic nasobiliary drainage showed chronic inflammation. To distinguish from cholangiocarcinoma, percutaneous transhepatic biliary drainage and cholangioscopic biopsy were performed, but only atypical cells were obtained.

Although it was not diagnosed as IPNB in the pathologic study progressed by specimen obtained before the operation, it was strongly suspected as an IPNB in the MRCP study. Resection was decided because IPNB is a pre-invasive biliary neoplasm considered to be a precursor of cholangiocarcinoma. The extended right hepatectomy, radical bile duct resection, duplicated EDH with Roux-en-Y hepaticojejunostomy, and jejunojejunostomy were performed. Approximately a 17 mm × 13 mm IPNB with low to intermediate grade dysplasia was found, and there was no evidence of pathologically invasive carcinoma (Fig. 1F). The surgery was successfully done, but the patient expired after 6 days due to hepatic failure.

DISCUSSION

Extrahepatic duct duplication is an extremely rare congenital anomaly reported in only 24 cases until 1986 (1).

Choi et al. (2) suggested the mechanism of this anomaly as a developmental failure for the double biliary system to regress.

Saito et al. (4) suggested a modified classification of double CBD, which was based on Ebert's morphologic grouping from type I to IV. Choi et al. (2) suggested an additional classification named "type V" for the extrahepatic duct duplication. This type of variation deficit characterizes the single drainage of two extrahepatic bile ducts. If there were no communication between the two extrahepatic ducts with single drainage, it would be classified as type Va; if there were one or more communication between two extrahepatic ducts with single drainage, it would be classified as type Vb (Fig. 1). The patient in this case was classified as type Vb.

Yamashita et al. (3) reported a case of double CBDs and reviewed the concomitant conditions that occurred in 47 reported cases in Japan. The most common concomitant condition was pancreaticobiliary malformation, followed by choledocholithiasis and cancer. Only three types of cancer, such as the gallbladder, ampulla of Vater, and gastric, were included in that report. After that, Choi et al. (2) reported a case of a type Va extrahepatic bile duct duplication with hilar cholangiocarcinoma; however, IPNB has not been reported as a concomitant condition the extrahepatic duct duplication.

In our case, the patient had previously presented with choledocholithiasis, which is combined with acute cholecystitis. In this presentation, IPNB was newly found with unknown etiology, but associations with hepatolithiasis and Clonorchis suggest it may cause chronic biliary inflammation (5). From this point of view, IPNB should also be considered as one of the concomitant conditions of the extrahepatic duct duplication.

Kim et al. (6) suggested that MDCT with MIP technique is more helpful in making a preoperative diagnosis than MRCP to demonstrate detailed anatomical information such as communication channels or a stone-filled duct. However, MRCP with 3D MIP reformat is also helpful in making a differential diagnosis. In the case of choledocholithiasis, a stone could be seen as a high density intraductal lesion in a non-contrast CT image when it was radiopaque. In addition, a radiolucent stone needs to be evaluated by an MRCP study to identify signal voids (7).

IPNB and cholangiocarcinoma were the diseases that should be distinguished when an intraductal lesion was seen. IPNB, which is defined as a prominent papillary proliferation of the dysplastic epithelium, is one of the precursors of cholangiocarcinoma. CT scan shows dilated intra-/extrahepatic bile ducts with mural nodularity, discrete intraluminal papillary, or fungating mass. If there is papillary projection or soft tissue mass within the dilated ducts, it would appear hypointense on T1-weighted image with an arterial phase enhancement in the T1 dynamic image. In T2-weighted images, it is seen as intermediate to hyperintense (5, 8).

In conclusion, we report a type Vb case of the extraepatic bile duct duplication with IPNB, which has not been reported. In this case, MDCT and MRCP were helpful in making a preoperative and differential diagnosis.

Author Contributions

Conceptualization, all authors; investigation, all authors; supervision, C.J.; visualization, all authors; writing—original draft, J.G.; and writing—review & editing, all authors.

Conflicts of Interest

The authors have no potential conflicts of interest to disclose.

Funding

None

REFERENCES

1. Teilum D. Double common bile duct. Case report and review. *Endoscopy* 1986;18:159-161
2. Choi E, Byun JH, Park BJ, Lee MG. Duplication of the extrahepatic bile duct with anomalous union of the pancreaticobiliary ductal system revealed by MR cholangiopancreatography. *Br J Radiol* 2007;80:e150-e154
3. Yamashita K, Oka Y, Urakami A, Iwamoto S, Tsunoda T, Eto T. Double common bile duct: a case report and

a review of the Japanese literature. *Surgery* 2002;131:676-681

4. Saito N, Nakano A, Arase M, Hiraoka T. A case of duplication of the common bile duct with anomaly of the intrahepatic bile duct. *Nihon Geka Gakkai Zasshi* 1988;89:1296-1301
5. Federle MP, Raman SP. *Diagnostic imaging: gastrointestinal*. 3rd ed. Philadelphia, PA: Elsevier Health Sciences 2015:966-969
6. Kim SW, Park DH, Shin HC, Kim IY, Park SH, Jung EJ, et al. Duplication of the extrahepatic bile duct in association with choledocholithiasis as depicted by MDCT. *Korean J Radiol* 2008;9:550-554
7. You MW, Jung YY, Shin JY. Role of magnetic resonance cholangiopancreatography in evaluation of choledocholithiasis in patients with suspected cholecystitis. *J Korean Soc Radiol* 2018;78:147-156
8. Chatterjee A, Lopes Vendrami C, Nikolaidis P, Mittal PK, Bandy AJ, Menias CO, et al. Miller FH. Uncommon intraluminal tumors of the gallbladder and biliary tract: spectrum of imaging appearances. *Radiographics* 2019;39:388-412

이중 담관 기형과 동반된 담관 관내 유두종 : 증례 보고

전가영 · 최주완*

이중 담관 기형은 매우 드문 선천 기형의 한 종류이다. 이중 담관 기형과 동반한 담관암의 증례가 보고된 적이 있으나 담관암의 전 침습적 병변인 관내 유두종이 이중 담관 기형과 함께 동반한 증례는 보고된 적이 없다. 우리는 64세 여성에게서 발견된 이중 담관 기형과 동반된 관내 유두종을 보고하고자 한다. 환자는 간 우엽 절제술을 시행하였으며 병리 결과에서 관내 유두종, 이중 담관 기형으로 진단되었다. 이에 대한 증례를 간단한 문헌 고찰과 함께 보고한다.

대구파티마병원 영상의학과