



# Multiple Primary Malignant Neoplasms: A Case Report of Breast Mucinous Carcinoma and Extramammary Diffuse Large B-Cell Lymphoma in a Male Patient

다발성 원발성 악성종양: 남성 환자에서 유방의 점액성 선암과 유방외 미만성 거대 B세포 림프종이 병발한 증례 보고

Su Young Kim, MD , Ji Young Lee, MD\* 

Department of Radiology, Inje University, Ilsan Paik Hospital, Goyang, Korea

Multiple primary malignant neoplasms refer to two or more malignancies in an individual that are not related. We report a case of a 78-year-old male with concurrent breast mucinous carcinoma and extramammary lymphoma. The patient initially presented with palpable masses in the left breast and the right groin, which were pathologically confirmed after a surgical biopsy as breast mucinous carcinoma and diffuse large B-cell lymphoma, respectively. He underwent whole-body 18-fluorine deoxyglucose PET/CT before surgery, and an enhancing nodular lesion in the left lingual tonsil was found incidentally. It was later confirmed as a diffuse large B-cell lymphoma, a pathology of the same type as the right inguinal mass. Unspecified lymphadenopathies in breast cancer patients may easily be considered as metastatic lesions. However, this case suggests that lymphomas should be included in the differential diagnoses to avoid misdiagnosis and treatment delay, especially in older adult patients.

**Index terms** Male Breast Cancer; Diffuse Large-Cell Lymphoma; Multiple Primary Neoplasms; Ultrasonography; Magnetic Resonance Imaging

Received June 11, 2020  
Revised July 27, 2020  
Accepted August 27, 2020

\*Corresponding author  
Ji Young Lee, MD  
Department of Radiology,  
Inje University, Ilsan Paik Hospital,  
170 Juhwa-ro, Ilsanseo-gu,  
Goyang 10380, Korea.

Tel 82-31-910-7394  
Fax 82-31-910-7369  
E-mail drleeji@paik.ac.kr

This is an Open Access article distributed under the terms of the Creative Commons Attribution Non-Commercial License (<https://creativecommons.org/licenses/by-nc/4.0>) which permits unrestricted non-commercial use, distribution, and reproduction in any medium, provided the original work is properly cited.

#### ORCID iDs

Su Young Kim   
<https://orcid.org/0000-0002-1824-0008>  
Ji Young Lee   
<https://orcid.org/0000-0002-6099-601X>

## INTRODUCTION

Multiple primary malignant neoplasms (MPMNs) refer to two or more malignancies in an individual without any relationship between the tumors. The widely used diagnostic criteria for MPMNs were originally described by Warren and Gates (1) and these suggest that each tumor must be malignant, each tumor must be distinct, and the probability of one being a metastasis of the other must be excluded. Few cases have been reported regarding simultaneous occurrence of breast cancer and other malignancies in male patients. The most common type of malignancy among male breast cancer patients is invasive ductal carcinoma, while mucinous carcinoma is extremely rare (2). Sordi et al. (3) reported the first synchronous case of invasive ductal carcinoma and axillary lymphoma in a 39-year-old male, and the existing reports describe several similar cases in female. However, no concurrent cases of second primary malignancies associated with male breast cancers other than invasive ductal carcinoma have been documented in the literature so far. Herein, we report a case of mucinous breast carcinoma and extramammary lymphoma that occurred simultaneously in a male patient. To the best of our knowledge, this combination in a male patient has never been previously reported in the literature.

## CASE REPORT

A 78-year-old male visited our hospital with two palpable masses in different areas. He had observed one lump under the left nipple a year ago but did not undergo any medical examination. He observed the other lump in the right groin area a month ago. A detailed medical history revealed negative results regarding primary comorbidities, drug history, and family history of cancer. Physical examination revealed a hard, fixed mass approximately 4 cm in size in the left retroareolar area and a hard mass approximately 3 cm in size in the right inguinal area. Laboratory studies including complete blood count, C-reactive protein, erythrocyte sedimentation rate, carcinoembryonic antigen, and cancer antigen 15-3 revealed no abnormalities.

Ultrasound (US) was performed for the palpable lesions. It revealed a 3.5-cm sized mass with heterogeneous echogenicity in the left breast and a 2.7-cm sized enlarged lymph node with loss of central fatty hilum and increased vascularities in the right inguinal region (Fig. 1A). At the request of the attending physician, US-guided gun biopsy was performed for the inguinal lesion. The pathological report suggested unspecified hematologic malignancy.

Subsequently, contrast-enhanced CT of the chest, abdomen, and pelvis was performed. Chest CT revealed a 3.5 cm × 2.1 cm relatively lobulated contoured mass with heterogeneous enhancement, which was directly abutting the pectoralis muscle. A few enlarged lymph nodes were also observed in the left axilla. CT of the abdomen and pelvis showed a 2.7 cm × 2.4 cm circumscribed oval homogeneously enhanced soft tissue mass and several small non-specific lymph nodes in the right inguinal area. There was no evidence of any abnormality in the solid organs nor abnormal lymphadenopathy in the abdominopelvic cavity (Fig. 1B).

An excisional biopsy confirmed diffuse large B-cell lymphoma in the right inguinal area, and at the same time, an incisional biopsy of the left breast mass confirmed mucinous carcinoma (Fig. 1C). For a more detailed evaluation of the left breast lesion, dynamic contrast-en-

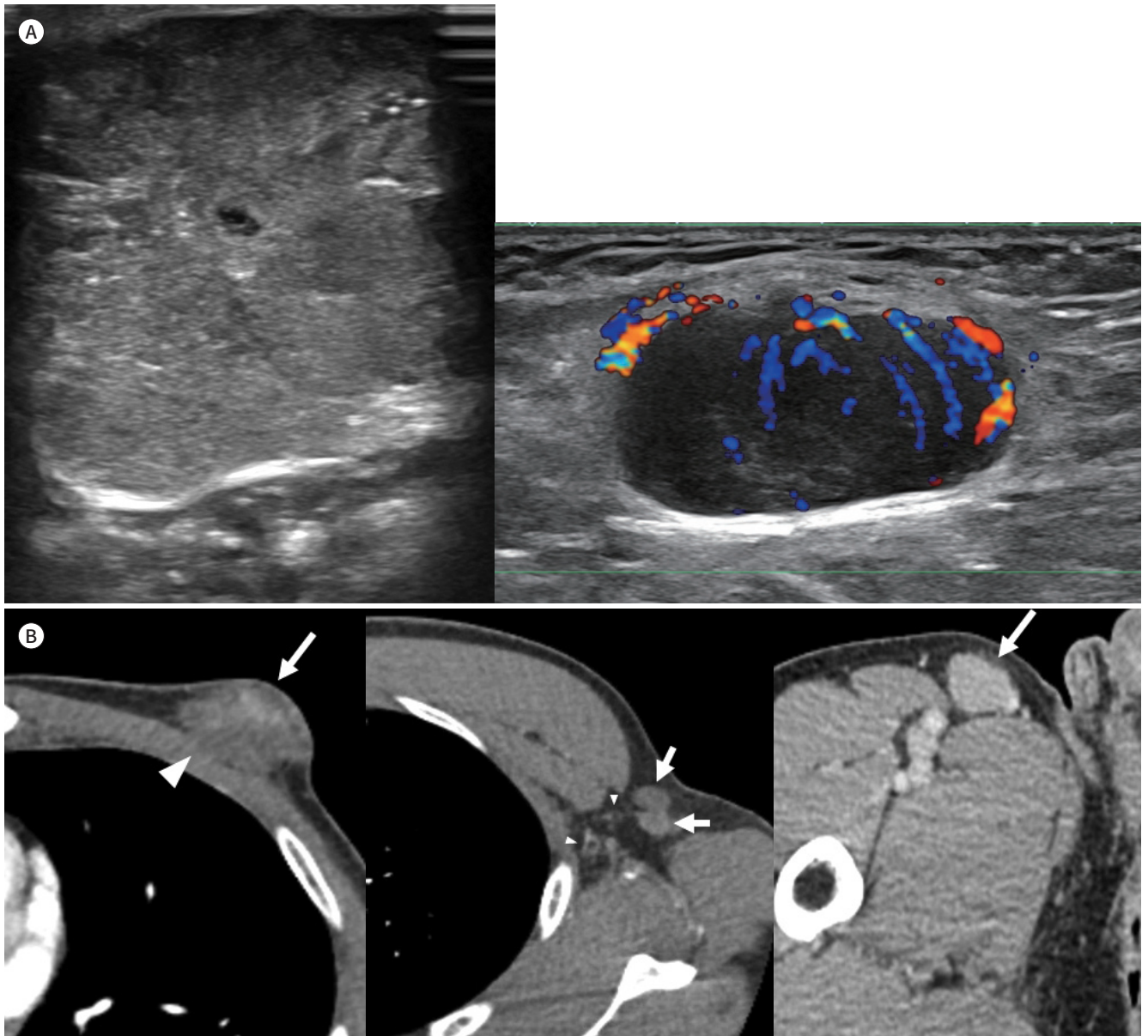
hanced breast MRI was performed. The mass showed high signal intensity on fat-saturated T2-weighted images, low signal intensity on fat-saturated T1-weighted images and showed heterogeneous enhancement with delayed washout pattern in kinetic analysis (Fig. 1D).

For metastasis workup, the patient underwent a whole-body 18-fluorine deoxyglucose PET/

**Fig. 1.** A 78-year-old male with mucinous carcinoma of the left breast and diffuse large B-cell lymphomas of the right inguinal lymph node and the left lingual tonsil.

**A.** Grayscale ultrasonography image shows a 3.5-cm mass with heterogeneous echogenicity in the left breast (left). Doppler ultrasonography image shows a 2.7-cm enlarged lymph node with loss of central hilar fat and increased central and peripheral vascularity in the right inguinal region (right).

**B.** Contrast-enhanced CT images of the lesions in the left breast and the right inguinal area. An ill-defined heterogeneously enhancing mass (arrow, left) directly abutting the left pectoralis muscle (arrowhead, left) is seen in the left breast. Two enlarged lymph nodes with relatively homogeneous enhancement and loss of central hilar fat (arrows, middle) and nonspecific small lymph nodes with normal central hilar fat (arrowheads, middle) are also observed. A well-defined soft-tissue density mass (arrow, right) with relatively homogeneous enhancement is seen in the right inguinal area.



CT (<sup>18</sup>F-FDG PET/CT). High uptake of <sup>18</sup>F-FDG was noted within the known lesions in the left breast [maximum standardized uptake value (SUV<sub>max</sub>) = 4.9] and the right inguinal area (SUV<sub>max</sub> = 4.2). An avid enhancing nodular lesion approximately 2 cm in length was noted incidentally at the left lingual tonsil (SUV<sub>max</sub> = 16.8, Fig. 1E).

The patient underwent modified radical left mastectomy with lymph node dissection for mucinous carcinoma. Additionally, left lingual tonsil excision was performed at the same time. Histopathology and immunochemistry confirmed Nottingham grade I mucinous breast carcinoma, estrogen and progesterone receptor positivity, and two axillary lymph nodes positive for metastasis. The excised left lingual tonsil lesion was confirmed as a diffuse large B-cell lymphoma, the same pathology as that of the right inguinal mass.

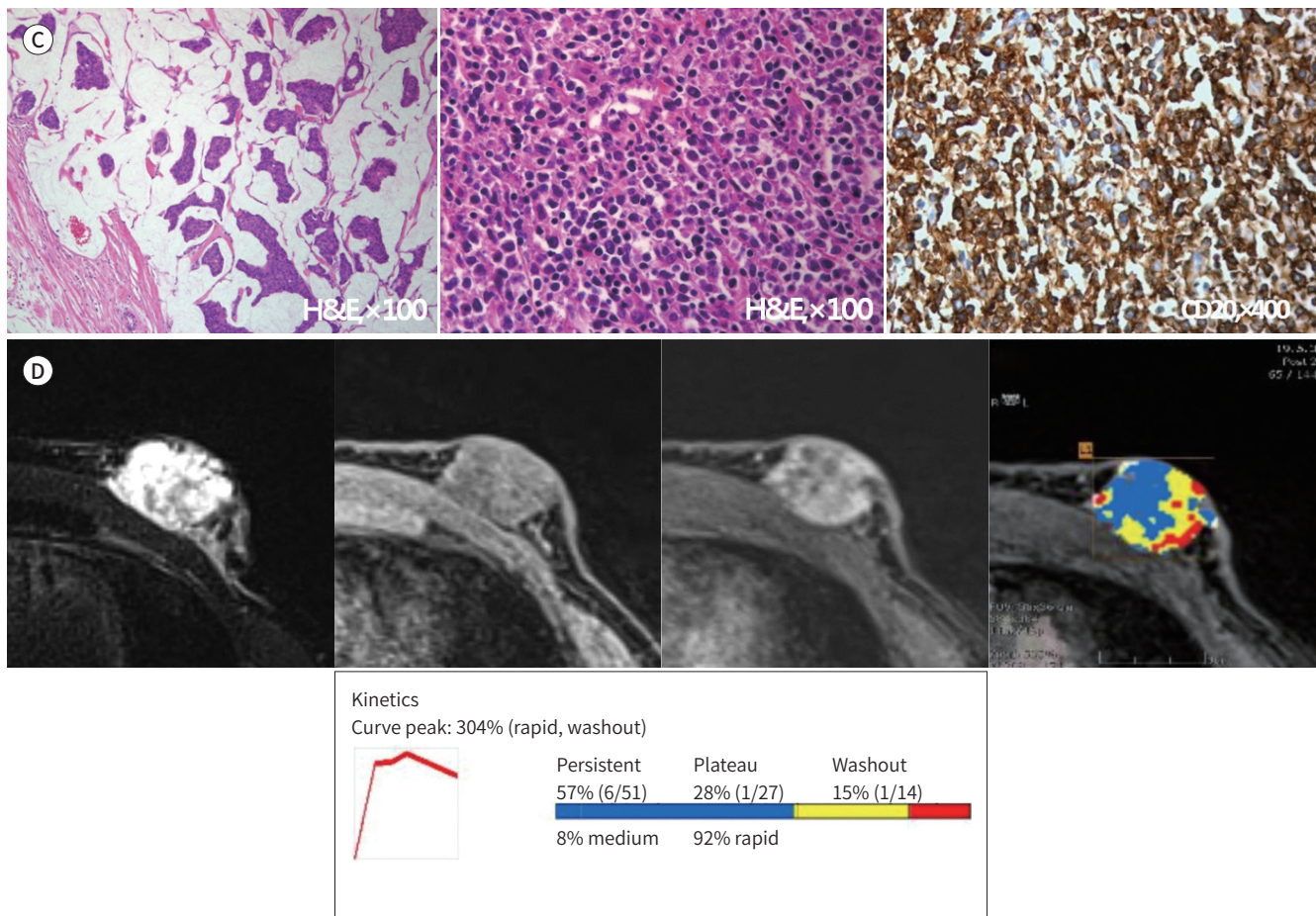
Finally, the patient was diagnosed with mucinous carcinoma of the left breast and diffuse large B-cell lymphoma of the right inguinal area and the left lingual tonsil. However, his de-

**Fig. 1.** A 78-year-old male with mucinous carcinoma of the left breast and diffuse large B-cell lymphomas of the right inguinal lymph node and the left lingual tonsil.

**C.** Histopathologic examination of the left breast mass shows carcinoma cell nests with plump mucinous stroma (left). Histopathologic examination of the right inguinal area mass shows large to medium-sized neoplastic cells with diffuse lymphoid proliferation (middle), strongly stained with CD20 immunostaining (right).

**D.** Axial MRI images of the left breast demonstrate a lobulated mass with high signal intensity on fat-saturated T2-weighted images (1st), low signal intensity on fat-saturated T1-weight sequence (2nd), and heterogeneous enhancement after contrast agent administration (3rd). The kinetic curve graph shows rapid early enhancement and a persistent enhancing-type curve (4, 5th).

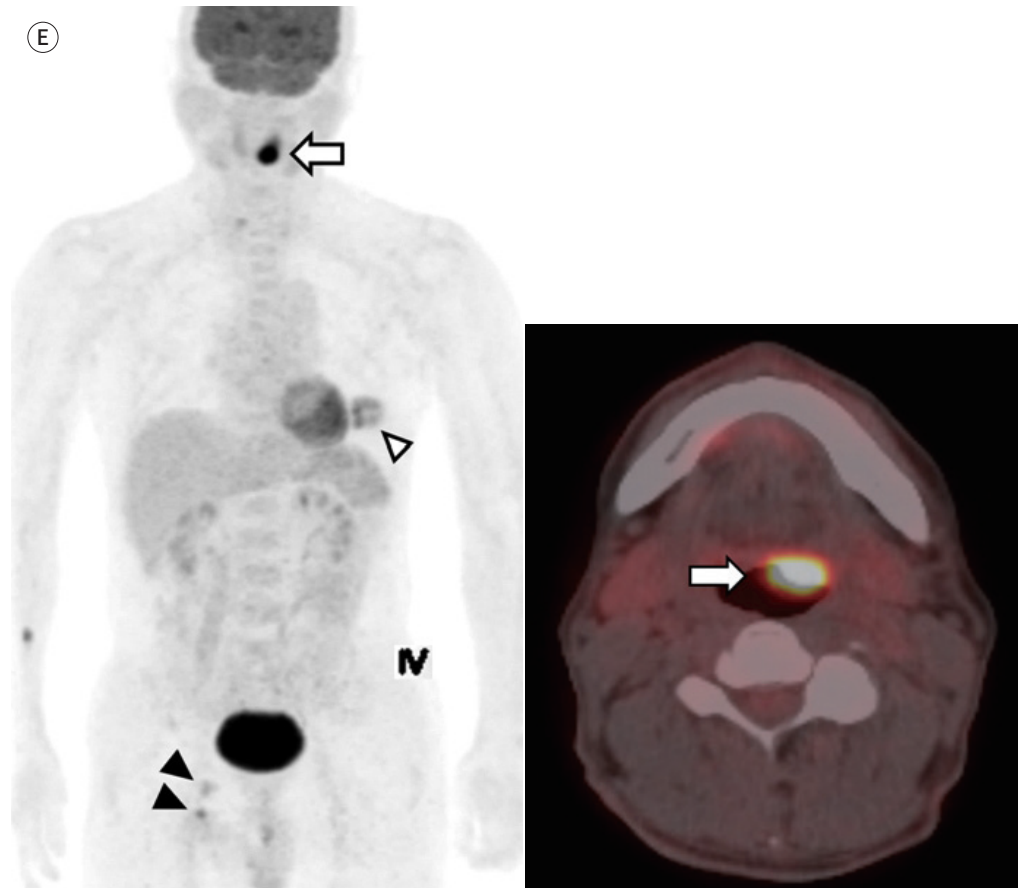
H&E = hematoxylin and eosin



**Fig. 1.** A 78-year-old male with mucinous carcinoma of the left breast and diffuse large B-cell lymphomas of the right inguinal lymph node and the left lingual tonsil.

**E.** PET/CT maximal intensity projection image shows the left breast lesion (arrowhead, left,  $SUV_{max} = 4.9$ ), the right inguinal lesions (black arrowheads, left,  $SUV_{max} = 4.2$ ), and the incidentally noted left lingual tonsil lesion (arrow, left,  $SUV_{max} = 16.8$ ). Axial  $^{18}F$ -FDG PET/CT shows focal FDG uptake in the left lingual tonsil (arrow, right).

$^{18}F$ -FDG = 18-fluorine deoxyglucose,  $SUV_{max}$  = maximum standardized uptake value



tailed history revealed no family history of cancer or environmental exposure to risk factors. A chromosome study showed a normal karyotype and genetic testing revealed negative results for BRCA1 and BRCA2 gene mutations. Subsequently, the patient underwent hormonal therapy with tamoxifen and chemotherapy with the R-CHOP protocol (cyclophosphamide, doxorubicin, vincristine, and prednisone; given every 21 days for 6 cycles) in combination. After eight months from the operation, follow-up CT of the abdomen and pelvis revealed decrease in size of the right small inguinal lymph nodes. And another three months later, follow-up studies including chest and abdominopelvic CT and breast US showed no signs of recurrence.

## DISCUSSION

The incidence of MPMNs is increasing annually due to developments in diagnostic technology and increased survival and life expectancy of cancer patients. The reported incidence of MPMNs ranges from 0.7% to 11.7%, according to the literature review (4). The patient in

the present report was simultaneously diagnosed with two categories of malignancies, fulfilling the criteria of MPMNs according to the definition by Warren and Gates (1). MPMNs might be synchronous or metachronous depending on the time of diagnosis. A second primary tumor that developed six or more months after the diagnosis of the first primary tumor is generally termed as metachronous, and a tumor that developed within six months is termed synchronous (4). Synchronous MPMNs are rare occurrences, and certain associated factors such as intrinsic, extrinsic, genetic, and therapeutic factors have been suggested. However, much of the causal relationship between these malignancies is not yet clear (4). Our patient did not have any predisposing factors such as genetic factors, a family history of cancer, BRCA gene mutations, or environmental exposure to risk factors.

Among MPMNs, concurrence of breast cancer and lymphoma is a rare condition that can result in a high rate of misdiagnosis in clinical practice as well as delay in proper management. Several reports regarding the combination of breast cancer and lymphoma have been published. The majority of the cases reported lymphomas developed in contiguity with breast cancer in the same breast, the contralateral breast, or the axillary lymph nodes (3, 5). Only Michalinos et al. (6) reported the follicular lymphoma involving an inguinal lymph node and the contralateral breast in a female patient. The male patient in the present report was diagnosed with lymphoma of the lingual tonsil and inguinal lymph nodes. Hence, the present case is different from the previously reported cases. As these regions of lymphoma involvement were distant from the breast cancer, they could easily be considered as distant metastasis at first.

Several reports have shown that breast cancer and lymphoma have an increased risk of occurrence following the occurrence of the other. Hemminki et al. (7) showed that male patients diagnosed with primary breast cancer had a 63% increased risk of developing lymphohematopoietic malignancy compared with males in the general population and that the increased risk of non-Hodgkin's lymphoma was 46% among these malignancies. It is also known that breast cancer patients who underwent radiotherapy and chemotherapy had an increased incidence of non-Hodgkin's lymphoma (6). A few common genetic factors such as ataxia telangiectasia mutated gene and mouse mammary tumor virus are suggested as pathophysiological connections (6), but these are possible causes of simultaneously occurred lymphoma and ductal breast carcinoma; not lymphoma and mucinous carcinoma.

Mucinous carcinoma of the male breast is an extremely rare histologic type of mammary neoplasm with very few studies conducted to date (2). There are two possibilities for the concurrence of mucinous breast carcinoma and diffuse large B-cell lymphoma, namely a simple coincidence and an unestablished causal relationship between these malignancies. A common epidemiological factor can be considered in the simultaneous occurrence of these malignancies, as both mucinous carcinoma and diffuse large B-cell lymphoma tend to occur in older age groups (2, 8). Moreover, as lymphoma is a hematological malignancy affecting the lymphatic system, an immunosuppressed state caused by abnormal lymphocytes can be associated with an increased risk of developing other types of primary malignancies including breast cancer (5).

Differentiating between lymph node involvement in lymphoma and metastatic lymph nodes only using the imaging findings is not easy, especially in small-sized nodes. However, lymph node involvement in lymphoma is described as a lesion with uniform density and mild ho-

mogeneous enhancement (9), which is consistent with the present case. Besides, intranodal necrosis is a comparatively reliable criterion for metastatic lymph nodes. However, it can be rare and not visible in smaller lymph nodes (10). In the present case, the axillary lymph node did not show any non-enhancing portion, suggesting necrosis. Histopathologic diagnosis of lymphoma can be done with fine needle aspiration cytology or core biopsy, but it may be insufficient for an accurate diagnosis and may require postoperative histologic examination.

In conclusion, simultaneous occurrence of breast mucinous carcinoma and extramammary lymphoma is extremely rare. Therefore, unspecified lymphadenopathies can easily be considered metastatic lesions of breast cancer in such cases. However, lymphoma should be included in differential diagnoses to avoid misdiagnosis or proper management delay in clinical practice, especially in elderly patients.

#### Author Contributions

Conceptualization, L.J.Y.; data curation, K.S.Y.; formal analysis, all authors; funding acquisition, L.J.Y.; investigation, all authors; methodology, L.J.Y.; project administration, all authors; resources, all authors; software, all authors; supervision, L.J.Y.; validation, all authors; visualization, K.S.Y.; writing—original draft, K.S.Y.; and writing—review & editing, L.J.Y.

#### Conflicts of Interest

The authors have no potential conflicts of interest to disclose.

#### Funding

None

#### REFERENCES

- Warren S, Gates O. Multiple primary malignant tumors: a survey of the literature and statistical study. *Am J Cancer* 1932;16:1358-1414
- Ishida M, Umeda T, Kawai Y, Mori T, Kubota Y, Abe H, et al. Mucinous carcinoma occurring in the male breast. *Oncol Lett* 2014;7:378-380
- Sordi E, Cagossi K, Lazzaretti MG, Gusolfino D, Artioli F, Santacroce G, et al. Rare case of male breast cancer and axillary lymphoma in the same patient: an unique case report. *Case Rep Med* 2011;2011:940803
- De Luca A, Frusone F, Vergine M, Cocchiara R, La Torre G, Ballesio L, et al. Breast cancer and multiple primary malignant tumors: case report and review of the literature. *In Vivo* 2019;33:1313-1324
- Zhong J, Di L, Zheng W. Synchronous breast cancer and breast lymphoma: two case reports and literature review. *Chin J Cancer Res* 2014;26:355-359
- Michalinos A, Vassilakopoulos T, Levidou G, Korkolopoulou P, Kontos M. Multifocal bilateral breast cancer and breast follicular lymphoma: a simple coincidence? *J Breast Cancer* 2015;18:296-300
- Hemminki K, Scélo G, Boffetta P, Mellemkjaer L, Tracey E, Andersen A, et al. Second primary malignancies in patients with male breast cancer. *Br J Cancer* 2005;92:1288-1292
- Smith A, Howell D, Patmore R, Jack A, Roman E. Incidence of haematological malignancy by sub-type: a report from the Haematological Malignancy Research Network. *Br J Cancer* 2011;105:1684-1692
- Yu RS, Zhang WM, Liu YQ. CT diagnosis of 52 patients with lymphoma in abdominal lymph nodes. *World J Gastroenterol* 2006;12:7869-7873
- Van den Brekel MW. Lymph node metastases: CT and MRI. *Eur J Radiol* 2000;33:230-238

## 다발성 원발성 악성종양: 남성 환자에서 유방의 점액성 선암과 유방외 미만성 거대 B세포 림프종이 병발한 증례 보고

김수영 · 이지영\*

다발성 원발성 악성 종양은 한 환자에서 2개 이상의 원발성 악성 종양이 각각 독립적으로 발생하는 경우를 말한다. 저자들은 78세 남자 환자에서 동시에 발생한 유방의 점액성 선암과 유방외 림프종의 증례를 경험하여 보고하고자 한다. 환자는 2개의 만저지는 덩이를 주소로 내원하여 외과적 생검을 통해 좌측 유방의 점액성 선암과 우측 서혜부의 미만성 거대 B세포 림프종을 확진하였다. 이후 수술 전 시행한 PET/CT에서 좌측 허파도의 우연종이 발견되었고, 절제 생검을 통해 미만성 거대 B세포 림프종을 확진하였다. 유방암 환자에서 불특정한 림프절 비대가 발견되는 경우 전이성 병변으로 간주되기 쉬우나, 이 증례의 환자와 같이 고령의 환자군에서는 림프종을 감별 진단으로 함께 고려함으로써 오진 및 치료 지연을 방지할 수 있을 것이다.

인제대학교 일산백병원 영상의학과