









Primary Central Nervous System Involvement in Peripheral T-Cell Lymphoma: A Case Report

원발성 중추신경계 말초 T 세포성 림프종: 증례 보고

Seung Hee Byun, MD¹ , Da Mi Kim, MD^{1*} , In Ho Lee, MD¹ ,
Chang June Song, MD¹ , Kyung Hwan Kim, MD² , Song Yi Choi, MD³ 

¹Department of Radiology, Chungnam National University Hospital, Daejeon, Korea
Departments of ²Neurosurgery, ³Pathology, Chungnam National University College of Medicine, Daejeon, Korea

Primary central nervous system T-cell lymphoma (PCNSTL) is an extremely rare type of brain tumor. There are only few reports on the imaging findings of patients with PCNSTL. Herein, we report the imaging findings of a patient with peripheral T-cell lymphoma-not otherwise specified that presented with numerous small nodular and patchy strongly enhancing lesions on MRI.

Index terms Primary Central Nervous System Neoplasms; Lymphoma; T-cell; Brain; Magnetic Resonance Imaging

INTRODUCTION

Primary central nervous system lymphoma (PCNSL) is rare disease accounting for 1–5% of all brain tumors and 1% of all non-Hodgkin lymphoma (1). It is confined to the brain, meninges, spinal cord, or eye without extra central nervous system (CNS) or lymph node manifestations at the time of initial presentation (2). As the CNS lacks lymphatic drainage and lymphoid tissue, CNS involvement of lymphoma is highly selective neurotropism (3).

Primary central nervous system T-cell lymphoma (PCNSTL) is an extremely rare condition of T-cell origin, and the prevalence of this subtype among patients with PCNSL in the largest PCNSL cohort in the International Extranodal Lymphoma Study Group was only 2% (4). Notably, although peripheral T-cell lymphoma (PTCL)-not otherwise specified (NOS) is the most prevalent type of PCNSTL based on few retrospective stud-

Received January 16, 2020
Revised April 16, 2020
Accepted May 7, 2020







*Corresponding author

Da Mi Kim, MD
Department of Radiology,
Chungnam National University
Hospital, 282 Munhwa-ro,
Jung-gu, Daejeon 35015, Korea.

Tel 82-42-220-8108
Fax 82-42-253-0061
E-mail damirad@hanmail.net

This is an Open Access article distributed under the terms of the Creative Commons Attribution Non-Commercial License (<https://creativecommons.org/licenses/by-nc/4.0>) which permits unrestricted non-commercial use, distribution, and reproduction in any medium, provided the original work is properly cited.

ORCID iDs

Seung Hee Byun 
<https://orcid.org/0000-0002-8140-9400>
Da Mi Kim 
<https://orcid.org/0000-0001-9202-0276>
In Ho Lee 
<https://orcid.org/0000-0003-0659-1721>
Chang June Song 
<https://orcid.org/0000-0002-6683-445X>
Kyung Hwan Kim 
<https://orcid.org/0000-0003-1244-6969>
Song Yi Choi 
<https://orcid.org/0000-0002-8496-5613>

ies (5), little has been reported about the imaging findings of PTCL (5).

Herein, we report a case of primary CNS involvement in PTCL-not otherwise specified (NOS) in a 59-year-old man with MR imaging findings.

CASE REPORT

A 59-year-old man had a sudden visual loss, headache, memory loss, and disorganized speech for two weeks, without systemic B symptoms. He had no abnormal past medical history, including infectious, rheumatologic, and immunosuppressed conditions.

On brain MR imaging, T2-weighted images showed numerous small nodular or heterogeneous patchy iso to slightly low signal intensity lesions in bilateral cerebellum, brainstem, cerebral hemispheres, and deep gray matter. The lesions showed low to iso signal intensity on the T1-weighted image, with strong homogeneous contrast enhancement. There was no leptomeningeal enhancement. Diffusion-weighted imaging (DWI) (b-value = 1000 s/mm²) showed high signal intensity, with restricted diffusion on apparent diffusion coefficient (ADC) map. Susceptibility-weighted image showed no microbleeds. The lesions were not well distinguished from severe vasogenic edema on brain CT (Fig. 1A).

Cerebrospinal fluid (CSF) analysis was notable for < 5 red blood cells (normal range < 10); glucose 48 mg/dL (normal range 40–70 mg/dL); protein 93 mg/dL (normal range 15–45 mg/dL); and 55 white blood cells (normal range < 5).

A stereotactic biopsy from the left temporo-occipital lobe was performed twice. Pathological diagnosis revealed PTCL-NOS. Immunohistochemical stains were performed using antibodies to CD3, CD20, CD5, CD15, CD30, S-100, and Ki-67. Tumor cells showed positive expression of CD3 (T-cell marker) and negative expression of CD20 (B-cell marker), CD15, CD30 (Reed-Sternberg cells marker), CD5, and S-100 (Fig. 1B). The expression of Ki-67 protein (cell proliferating marker) was 10%. The molecular pathological evaluation for the Epstein-Barr virus (EBV) showed negative results. These findings indicate that tumor cells were of T-cells in origin. Additional imaging included enhanced CT scans of the chest, abdomen and pelvis as well as PET/CT showed no remarkable abnormality. Also, bone marrow biopsy was performed for staging and no definite lymphoma involvement was noted. The final diagnosis was PTCL-NOS in the brain.

The patient was treated with induction chemotherapy consisting of methotrexate, procarbazine, and vincristine. After 2 cycles, follow-up MR imaging showed a partial response (Fig. 1C). However, after 5 cycles, follow-up MR imaging showed tumor progression and new appearance of lymphoma involvement in bilateral cerebral hemispheres, deep gray matter, and midbrain (Fig. 1D).

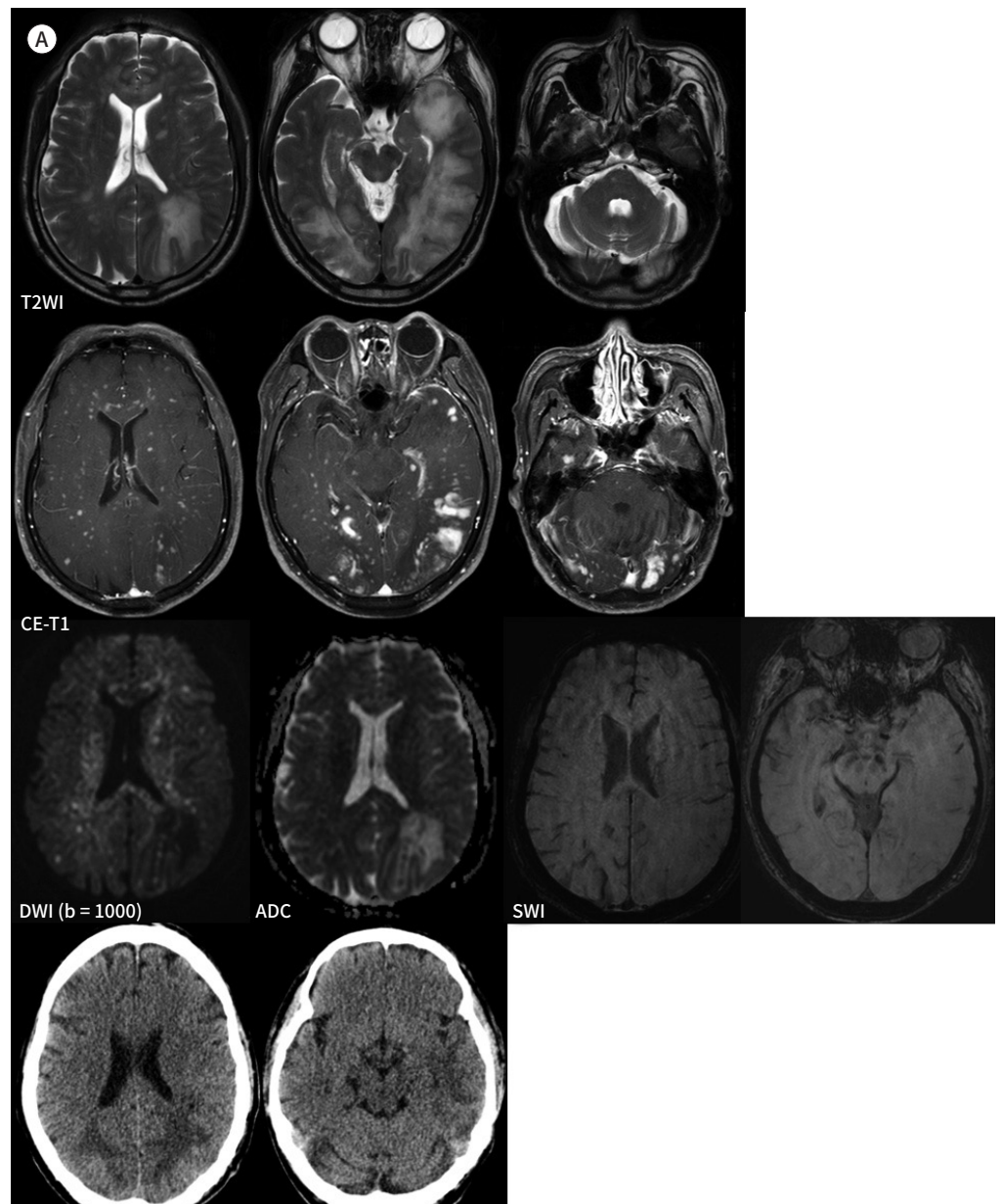
DISCUSSION

CNS involvement of lymphoma is classified into 2 subtypes: secondary CNS lymphoma and PCNSL (1). PCNSL is a rare tumor but incidence rates are increasing among immunocompetent patients (5). While the most common histologic subtype of PCNSL is diffuse large B-cell lymphoma, others including Burkitt lymphoma, MALT lymphoma, follicular lympho-

ma, and, less commonly, T-cell lymphomas can present with the intracranial disease (6). PTCL is a subtype of T-cell lymphoma and heterogeneous group of lymphoproliferative disorder, PTCL-NOS accounts for about more than one third (30–50%) of all PTCL (6). Until date,

Fig.1. A 59-year-old man with PTCL-NOS in the brain.

A. On initial brain MR imaging, axial T2WIs show small nodular or heterogeneous patchy iso to slightly low signal intensity lesions in the bilateral cerebellum, brainstem, cerebral hemispheres, and deep gray matter. Axial CE T1-weighted axial images show numerous variable-sized, nodular, or homogeneous patchy strong contrast enhancement, without leptomeningeal enhancement (two top rows). DWI shows high signal intensity, with restricted diffusion on the ADC map, corresponding to cytotoxic edema. SWI images show no microbleeds. The lesions are not well distinguished from severe vasogenic edema on brain CT (bottom row). ADC = apparent diffusion coefficient, CE = contrast-enhanced, DWI = diffusion-weighted imaging, PTCL-NOS = peripheral T-cell lymphoma-not otherwise specified, SWI = susceptibility-weighted image, T2WI = T2-weighted image



incidence of PTCL-NOS in CNS is not clear due to the rarity of the disease (4). Most of the PTCL-NOS have a poor response towards chemotherapy and poor prognosis (6).

Because PCNSL has characteristic of due to high cellularity and high nuclear/cytoplasm ratio, they generally show hypo- or isointense on T2-weighted imaging and restricted diffusion in lesions on DWI and ADC map (1). In our case, the tumor showed typically hyperintensity on DWI and restricted diffusion. However, on T2-weighted image, tumor and edema were not differentiated clearly, due to severe perilesional vasogenic edema. Also, these lesions showed no tumoral hemorrhage or calcification. The lesions presented diffuse homogeneous nodular and patchy enhancement without leptomeningeal enhancement. These imaging findings were mimics of disseminated CNS infection, such as viral, bacterial, fungal,

Fig.1. A 59-year-old male with PTCL-NOS in the brain.

B. On histopathological examination, diffuse perivascular and parenchymal infiltration of atypical lymphocytes are demonstrated (hematoxylin and eosin, $\times 100$). These tumor cells show immunoreactivity for CD3 ($\times 100$).

C. After 2 cycles of chemotherapy, follow-up axial T2-weighted images, and axial contrast-enhanced T1-weighted MR images show partial response.

D. After 5 cycles of chemotherapy, follow-up axial T2-weighted images, and axial contrast-enhanced T1-weighted MR images show tumor progression and new appearance of lymphoma involvement in the bilateral cerebral hemispheres and deep gray matter.

PTCL-NOS = peripheral T-cell lymphoma-not otherwise specified

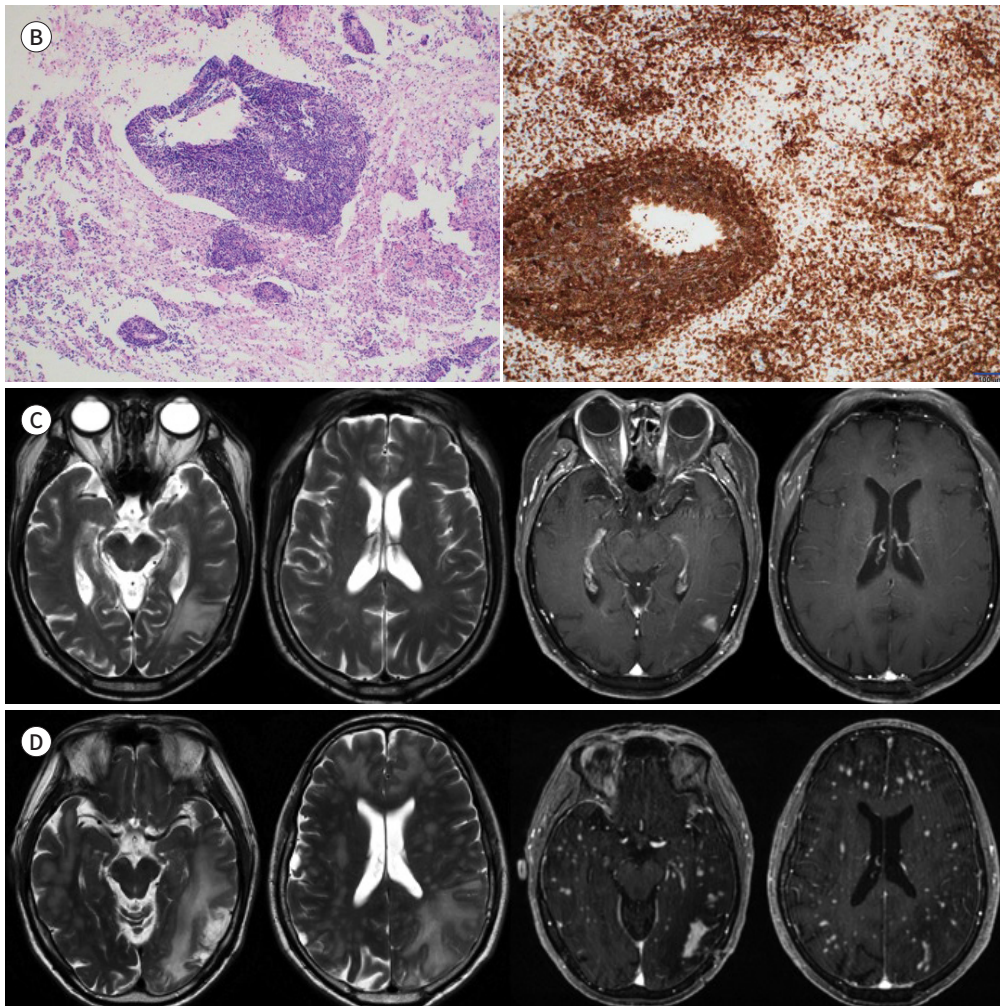


Table 1. Review of the Previously Reported Cases of PTCL-NOS

References	No. of Patients	MRI Findings		Pathologic Findings	
		Lesion		Perivascular Infiltration	Tumoral Necrosis
Menon et al. (2)	15	Solitary	8 (53.3)	10 (66.7)	11 (73.3)
		Multiple	7 (46.7)		
Choi et al. (10)	7	Solitary	7 (100)	6 (85.7)	6 (85.7)

Data are *n* (%) values.

PTCL-NOS = peripheral T-cell lymphoma-not otherwise specified

mycobacterial, parasitic, and metastasis (1, 7). However, all the infectious diseases are usually related to conditions of immunosuppression, and usually present with meningitis or meningoencephalitis. Diagnosis of meningitis is based on clinical symptoms and laboratory findings such as CSF analysis. In general, infectious granulomas tend to present imaging findings of variable enhancement (no enhancement to the ring and nodular enhancement) and abscess formation, which is usually larger. Furthermore, they manifest different appearances corresponding to varying stages (7). Unlike typical infectious granuloma, our case showed homogeneous enhancement in all the lesions.

In our case, based on MR imaging findings of lesions of restricted diffusion and vividly homogeneous enhancement, primary B-cell lymphoma of all the PCNSL may be considered. However, the perilesional vasogenic edema is not prominent in primary B-cell lymphoma, regardless of tumor size (1).

Meanwhile, of all PCNSL, intravascular lymphoma and lymphomatoid granulomatosis of the CNS may have similar radiological features; pathological findings are needed to distinguish these diseases (8). Intravascular lymphoma is a subtype of extranodal diffuse large B-cell lymphoma and lymphomatoid granulomatosis is a lymphoproliferative disorder, in which tumorous B cells transform after infection with the EBV (9). In our case, based on the expression of the T-cell specific marker and negative results of molecular analysis for the EBV, two diseases can be ruled out. Due to rarity of PCTL-NOS in CNS, detailed morphologic features, molecular genetics, and immunophenotypes were not available (6, 8).

To the best of our knowledge, there have been a few reports of primary CNS involvement of PTCL-NOS in the brain, focused on clinical and pathologic findings. The MRI findings of all reported primary PTCL-NOS in brain are shown in Table 1. As we listed in Table 1, tumor can be divided into solitary mass and multiple lesions according to multiplicity. Menon et al. (2) reported 53.3% solitary mass of 15 cases and Choi et al. (10) reported 100% solitary mass of 7 cases. Also, microscopically, they reported necrosis and perivascular infiltration of tumor cells were frequently observed, but, there was no detailed mention whether these findings are included or not in imaging finding. On pathologic examination, according to Menon et al. (2), most of the PTCL in CNS showed prominent perivascular infiltration, with expansion of tumor cells into the Virchow-Robin space. Choi et al. (10) mentioned that the T-cells in PTCL were dispersed without forming a histological solid mass. In our case, the MRI features may correlate with underlying aforementioned studies' mentioned pathology.

In summary, we present a rare case of PTCL-NOS in brain. Due to the rarity of this tumor, making a correct diagnosis of PTCL in brain may be difficult. However, MR imaging findings

of numerous variable-sized, homogeneously strong enhancing lesions with restricted diffusion in brain should alert a radiologist to consider PTCL-NOS.

Author Contributions

Conceptualization, K.D.M.; data curation, B.S.H.; formal analysis, K.D.M, B.S.H.; funding acquisition, K.D.M.; investigation, K.D.M.; methodology, K.D.M.; project administration, B.S.H., K.D.M.; resources, B.S.H., K.D.M.; software, B.S.H., K.D.M.; supervision, K.D.M.; validation, B.S.H., K.D.M.; visualization, all authors; writing—original draft, B.S.H.; and writing—review & editing, K.D.M.

Conflicts of Interest

The authors have no potential conflicts of interest to disclose.

REFERENCES

1. Haldorsen IS, Espeland A, Larsson EM. Central nervous system lymphoma: characteristic findings on traditional and advanced imaging. *AJNR Am J Neuroradiol* 2011;32:984-992
2. Menon MP, Nicolae A, Meeker H, Raffeld M, Xi L, Jegalian AG, et al. Primary CNS T-cell lymphomas: a clinical, morphologic, immunophenotypic, and molecular analysis. *Am J Surg Pathol* 2015;39:1719-1729
3. Fraser E, Gruenberg K, Rubenstein JL. New approaches in primary central nervous system lymphoma. *Chin Clin Oncol* 2015;4:11
4. Chihara D, Oki Y. Central nervous system involvement in peripheral T cell lymphoma. *Curr Hematol Malign Rep* 2018;13:1-6
5. Löw S, Han CH, Batchelor TT. Primary central nervous system lymphoma. *Ther Adv Neurol Disord* 2018;11:1756286418793562
6. Lone W, Alkhiniji A, Manikkam Umakanthan J, Iqbal J. Molecular insights into pathogenesis of peripheral T cell lymphoma: a review. *Curr Hematol Malign Rep* 2018;13:318-328
7. Department of Radiology, Seoul National University College of Medicine. *Neuroradiology*. 2nd ed. Seoul: Ilchokak 2011
8. Giannini C, Dogan A, Salomão DR. CNS lymphoma: a practical diagnostic approach. *J Neuropathol Exp Neurol* 2014;73:478-494
9. Quinones E, Potes LI, Silva N, Lobato-Polo J. Lymphomatoid granulomatosis of the brain: a case report. *Surg Neurol Int* 2016;7:S612-S616
10. Choi JS, Nam DH, Ko YH, Seo JW, Choi YL, Suh YL, et al. Primary central nervous system lymphoma in Korea: comparison of B- and T-cell lymphomas. *Am J Surg Pathol* 2003;27:919-928

원발성 중추신경계 말초 T 세포성 림프종: 증례 보고

변승희¹ · 김다미^{1*} · 이인호¹ · 송창준¹ · 김경환² · 최송이³

원발성 중추신경계 T 세포 임파종은 모든 뇌종양 중에서 매우 드물게 발생하는 뇌종양이다. 그렇기 때문에 지금까지 보고된 영상의학적인 소견은 매우 드물다. 저자들은 자기공명영상에서 다수의 작은 결절 및 반점형으로 조영증강되는 병변으로 보였던 뇌실질에 발생한 원발성 기타 상세불명의 말초 T 세포 림프종을 경험하였기에 영상의학적인 소견을 중점으로 하여 보고하고자 한다.

¹충남대학교병원 영상의학과
충남대학교 의과대학 ²신경외과교실, ³병리과교실