



Carotid duplex ultrasound: interpretations and clinical applications

Hye-Yeon Choi

Department of Neurology, Kyung Hee University Hospital at Gangdong, Kyung Hee University School of Medicine, Seoul, Korea

Received: August 27, 2021

Revised: October 9, 2021

Accepted: October 9, 2021

Correspondence to

Hye-Yeon Choi

Department of Neurology, Kyung Hee University Hospital at Gangdong, 892 Dongnam-ro, Gangdong-gu, Seoul 05278, Korea

Tel: +82-2-440-6269

Fax: +82-2-440-7243

E-mail: hyechoi@gmail.com

ORCID

Hye-Yeon Choi

<https://orcid.org/0000-0001-6291-3153>

Carotid duplex ultrasound is commonly used to diagnose various carotid artery diseases due to it being noninvasive and easy to perform. Carotid atherosclerosis is a major indicator for the need to perform carotid duplex ultrasound, which can determine the degree of stenosis, plaque characteristics, and intima-media thickness. It can also be used to screen and follow-up after carotid revascularization. Here we discuss the standard techniques, interpretations, and clinical indicators for carotid duplex ultrasounds.

Key words: Ultrasonography; Carotid artery; Duplex Doppler ultrasonography; Carotid artery diseases

INTRODUCTION

Ultrasonography is noninvasive, safe, and can be used to examine the morphology and functionality of the human body. Furthermore, it can be performed relatively quickly and repeated at a low cost. Carotid duplex ultrasound can be used to determine the presence and shape of atherosclerotic plaques. Since it is a relatively inexpensive and safe noninvasive examination method, it is widely used to diagnose and monitor carotid artery disease. However, despite its ease of access, inexperienced examiners may find the procedure difficult to perform. The purpose of this review is to present the standard method of carotid duplex ultrasound, and to interpret its findings and clinical applications.

HOW TO EXPLORE

Position

The examiner can observe the carotid artery from either an overhead or a lateral sitting position.¹ In the overhead position, the examiner sits behind the head of the patient be-

side the end of the bed and uses both hands in the test. This position provides an expanded sonic window with a clear view of the carotid artery and allows many ultrasound probing positions. However, the examiner should be familiar with the practice of using both hands. A lateral sitting position is used for most ultrasonography examinations. The examiner generally uses their right hand to evaluate both carotid arteries. This position makes it easy to control the ultrasound probe. However, obtaining right-posterior projections is difficult. The optimal position for tilting the head of the patient is approximately 45° away from the relevant artery. Tilting the face too far from the test site can distort the anatomy or compress blood vessels, especially veins. The neck of the patient should be relaxed and the chin should be slightly raised. Placing a pillow induces a poor evaluation window for the carotid artery and therefore normally should not be used.

Ultrasound device settings

The standard equipment used in this technique includes a high-resolution grayscale B-mode system, with linear ultrasound transducers operating at > 7 MHz.² Optimal image quality can be obtained when appropriate depths of focus (e.g., 30-40 mm) and optimal frame rates (25 Hz) are ap-

plied.^{3,4} Log gain compensation (dynamic range) is recommended to be around 60 dB.² Gain settings are adjusted to achieve symmetrical brightness on the near and far walls or in the midfield to avoid intraluminal artifacts.⁴

EXAMINATION PROCEDURE

The arterial wall should be assessed longitudinally, exactly perpendicular to the ultrasound projection. Both walls should be distinctly visualized to accurately measure the diameter. The diameter should be measured during diastole using automatic cine-loop detection or by measuring the minimum diameter during the cardiac cycle.³ A lateral probe position is recommended as it provides the best midfield resolution. Imaging of the carotid bifurcation is essential for serial imaging. Longitudinal and cross-sectional views of the carotid tree are required to examine focal atherosclerosis. Color flow Doppler imaging helps to identify hypoechogenic boundaries.

An adequate acoustic angle is important in obtaining an accurate color Doppler image. The ultrasound beam should be perpendicular to the skin, with a linear probe generating a grayscale image. However, to accurately record velocity

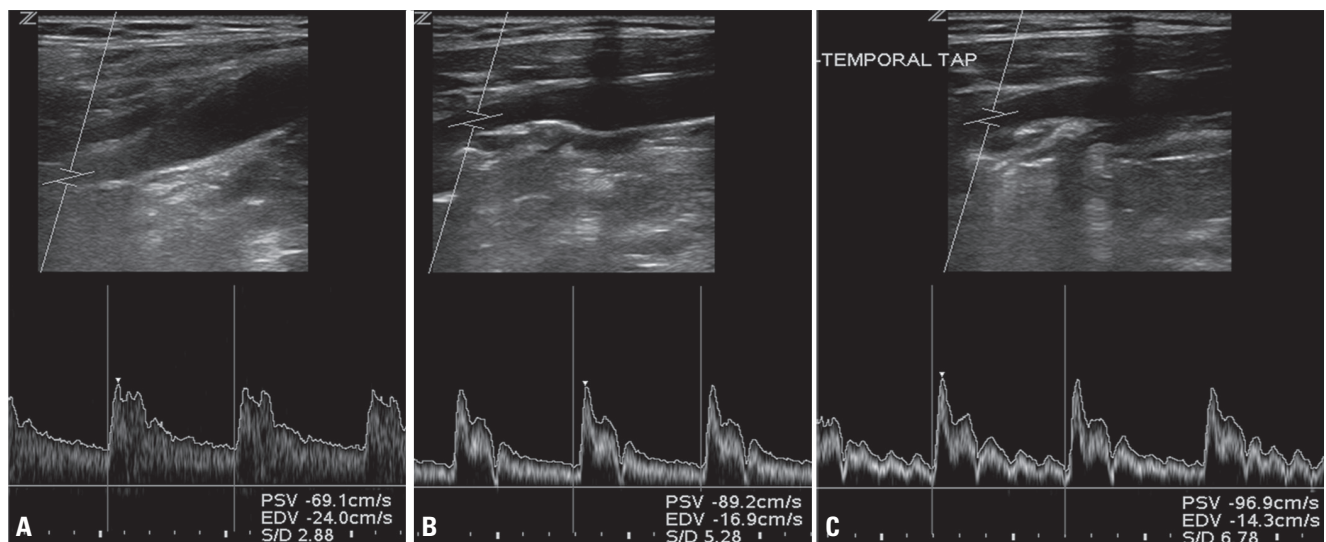


Fig. 1. Examination of internal carotid artery (ICA) and external carotid artery (ECA). (A) Low-resistance waveform of the ICA. The waveform had a blunter systolic peak and greater diastolic flow for the ICA than for the ECA. (B) High-resistance waveform of the ECA. Sharp rise in flow velocity during systole, rapid decline toward baseline, and diminished diastolic flow. (C) ECA after temporal tapping. Repeated tapping of the superficial temporal artery caused waveform oscillation (small deflection) in the ECA spectrum.

using color Doppler ultrasonography, the angle must be between 30° and 60°.¹ In most patients, the probe surface runs parallel to the common carotid artery (CCA) in its usual position, which allows scanning of the carotid artery without applying pressure. Pushing the head- or foot-side edge creates an angle between the probe surface and the vessel, which can achieve the optimal Doppler angle. This is called the heel-and-toe technique, and is a method for steering probes.¹ Pulse-wave Doppler is needed to precisely measure flow velocity, and uses a small sample volume from the vessel center to assess the velocity at that segment. The peak velocity is measured to detect significant stenosis. Angle correction is crucial for measuring the actual flow velocity, which should be performed along the flow direction instead of the vessel wall.⁵ The flow direction is generally the same as the vessel direction, but it can differ from the vessel direction when eccentric atherosclerotic plaques are present.

HOW TO DISTINGUISH BETWEEN ARTERIES

Carotid arteries

First, in the cross-sectional view, trace the carotid artery from the proximal CCA to the distal internal carotid artery (ICA) and then the external carotid artery (ECA), or vice versa. Then, observe the shape of the carotid artery in the longitudinal view. The CCA divides into the ICA and ECA. The ICA has a larger diameter, is located deeper than the ECA, and is directed toward the mastoid process. In contrast, the ECA is located superficially and is directed toward the face. The proximal ICA does not have branches, while the ECA does. The Doppler spectrums of the ICA indicated lower resistance patterns (Fig. 1). The velocity difference between the systolic and diastolic phases of the blood is smaller in the ICA than in the ECA. Another method for differentiating the ECA from the ICA involves placing the fingertips on the ipsilateral temporal artery when obtaining the ECA Doppler spectrums, which generates a serration-like artifact. This temporal artery tapping-induced artifact is generally not observed in the normal ICA Doppler spectrum. This so-called temporal tapping is a useful method for differentiating between the ICA and ECA (Fig. 1). However, waveform oscillations induced by temporal tapping can be found beyond the ECA in the CCA

and ICA, especially in diseased ICAs.⁶

Vertebral arteries

Vertebral artery is a branch of the subclavian artery, and the V2 segment can be detected using carotid duplex ultrasound. The probe is placed parallel to the carotid artery and then moved posterolaterally to the neck. The vertebral artery can be distinguished by its acoustic shadow caused by the transverse processes (Fig. 2). The vertebral artery can be easily observed when the examinee pushes their shoulder down. Percussion of the C1 atlas may help differentiate between the vertebral artery, the thyrocervical artery, and the CCA.³

EXAMINATION FINDINGS

The examination report should include the intima-media thickness (IMT), presence of plaques and their characteristics, flow velocities of each segment, diameter of each segment, and presence of stenosis and other vascular abnormalities. Furthermore, other abnormalities arising in the neck area, such as thyroid disease, should be noted and reported when they are observed.

Intima-media thickness

The vascular wall consists of the intima, media, and adventitia. The IMT is observed in the longitudinal B-mode view of the CCA as two bright lines: the first line adjacent to the lumen is the intima, and the outside second line is the adven-

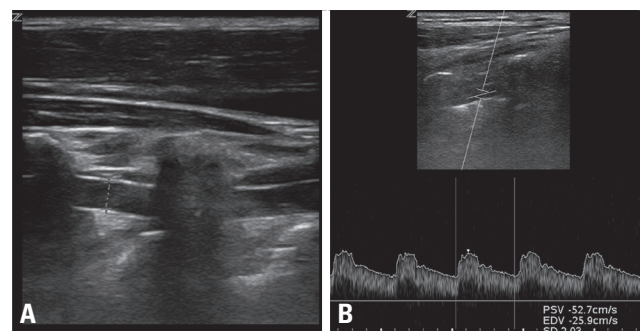


Fig. 2. Examination of vertebral artery. (A) Vertebral artery visualized between shadows from cervical transverse processes. (B) Typical vertebral artery waveform had a low resistance with continuous forward flow during diastole.

tia. The dark area between the two lines is the media, and the thickness from the interface between the lumen and the inner membrane to that between the media and the adventitia is the IMT (Fig. 3). It can be more clearly observed in the far than in the near wall. CCA IMT should be measured at the far wall without focal lesions over a 10-mm segment located approximately 5 mm proximal to the carotid bulb.^{2,4} Automatic or semiautomatic measurements are recommended, since manual measurements take longer and their values can vary between examinees. The average or maximum thickness is used in clinical practice.

Normal IMT values depend on age, sex, and race. They can also differ according to the type of measurement method used. Although normal IMT values among Koreans have been reported, large-scale studies are needed to predict cardio-cerebrovascular disease risk. Some studies have identified the normal IMT values in the Korean population. Two studies included healthy people who had no previous vascular diseases or other risk factors.^{7,8} One study used an average IMT value,⁷ and found mean IMTs in the overall population of 0.6 mm and 0.53 mm in males and females, respectively. The age was 56 ± 8 years (mean \pm standard deviation) and 54 ± 8 years for males and females, respectively, and IMT increased with age. Another study used the mean maximum IMT value measured on the bilateral CCA.⁸ That study compared IMT according to the presence of metabolic syndrome. IMTs were larger in patients with metabolic syndrome (0.77 mm in males and 0.75 mm in females) than in the healthy population (0.76 mm and 0.71 mm, respectively). The difference in IMT between these two studies might be attributable to the older population included in the latter study (age of 62.1 ± 7.7

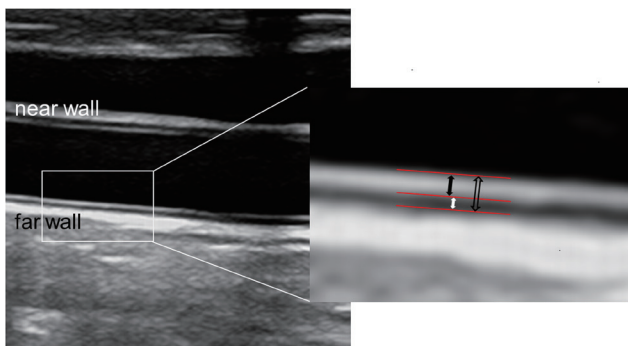


Fig. 3. Intima-media thickness (IMT). Bidirectional arrows indicate intima (black), media (white), and IMT (outlined).

years in males and 61.0 ± 7.9 years in females).

Plaque

A plaque is defined as a focal structure protruding into the arterial lumen by at least 0.5 mm or 50% of the surrounding IMT, or having an IMT of > 1.5 mm.² The maximum thickness should be measured at two different insonation angles in the longitudinal and cross-sectional views.

The size, morphology, and characteristics of plaques should be described, including echogenicity and intraplaque hemorrhage presence, neovascularization, ulceration, or its mobile portions. Plaque echogenicity can be described as echogenic, isoechoic, echolucent, or heterogeneous. The echogenicity of the intima-media complex is a criterion that determines an isoechoic plaque. The plaque surface can be described as smooth, irregular, or ulcerated.

Blood flow measurement

Blood flow velocity and endovascular diameter can be measured using two methods: 1) quantitative measurement using spectral Doppler ultrasound and 2) color M-mode ultrasound.³ The first method involves measuring the angle-corrected time-averaged mean flow velocity and inner diameter of blood vessels using B-mode images. The second is also called color velocity imaging quantification. When the intravessel luminal diameter or systolic velocity is at its maximum, the flow rate and inner diameter are measured simultaneously from a still image. Artifacts such as overlapping or color bleeding should be avoided when performing measurements in color M-mode imaging. In previous studies, the spectral Doppler method has been reported to show faster blood flow than the color M method, which could be attributed to the larger inner diameter measured by the spectral Doppler method. The following data should be included: peak systolic velocity and end-diastolic velocity for all vessel segments, Doppler spectral waveform morphologies from the CCA, ICA, and ECA, flow direction, and the peak systolic velocity in the vertebral arteries.

Internal carotid artery

To measure the blood flow rate and inner diameter of the ICA, the point where the blood vessel extends straight should be selected at least 1.5-2 cm above the ICA bifurcation, after the head is turned to the opposite side by $25-45^\circ$.³

Vertebral artery

The vertebral artery is normally measured between the C4 and C5 transverse processes when the head is turned approximately 10° to the side opposite to that being examined.³

CLINICAL APPLICATIONS

Symptomatic carotid stenosis

Symptomatic carotid stenosis refers to atherosclerotic stenosis of the ICA, which induces ischemia symptoms. Ischemic events associated with carotid artery disease include ocular symptoms such as amaurosis fugax of the ipsilateral eye, central or branch retinal artery occlusion, ischemic optic neuropathy, cerebral infarction, and transient ischemic attack (TIA).

Diagnosis

The consensus criteria suggested by the Society of Radiologists in Ultrasound are widely used to evaluate the degree of carotid artery stenosis (Table 1).⁹ These criteria suggest that carotid artery stenosis can be diagnosed as < 50%, 50-69%, ≥ 70%, or complete occlusion based on the maximum systolic ICA blood velocity combined with a comprehensive examination which determines atherosclerotic plaque presence, end-diastolic velocity, and the maximum systolic blood velocity ratio between the ICA and CCA. However, the specificity of carotid stenosis varies between reports. Therefore, to determine whether an operation or a procedure should be performed, magnetic resonance angiography

or CT angiography or a subsequent examination of the carotid ultrasound by another examiner is recommended to minimize the probability of performing unnecessary procedures.^{10,11}

Predicting potential revascularization complications

Carotid duplex ultrasound can be used to predict complications that can occur during revascularization procedures such as carotid endarterectomy (CEA) or carotid artery angioplasty and stenting (CAS). Carotid ultrasound can provide important information for carotid artery stenting in determining the mechanical characteristics of an atherosclerotic plaque, such as its surface (smooth or irregular) and structure (homogeneous, nonhomogeneous, intraplaque hemorrhage, or calcification).^{12,13} However, carotid duplex sonography does not sufficiently assess the risk of surgical treatment for screening purposes because of a lack of standardized data.¹⁴ Another limitation is that it cannot be used to evaluate cerebral perfusions, intracranial collateral circulation, or other vascular abnormalities such as aneurysms.

Follow-up after revascularization

There are several reports of the restenosis incidence ranging from 5% to 22% and from 2.7% to 33% after CEA and CAS, respectively.¹⁵ After carotid revascularization, the blood flow velocity is observed to be greater than normal using carotid ultrasound, and so caution is needed when interpreting the observations.¹⁴ Appropriate criteria for interpreting carotid duplex sonography findings after carotid revascularization have not yet been established, and so it is necessary to establish and regularly verify laboratory standards.

Table 1. Parameters used in carotid duplex ultrasound to estimate the degree of carotid artery stenosis

Degree of stenosis ^a (%)	Primary parameter		Additional parameter	
	ICA PSV (cm/s)	Plaque estimate (%)	ICA/CCA PSV ratio	ICA EDV (cm/s)
Normal	< 125	None	< 2.0	< 40
< 50	< 125	< 50	< 2.0	< 40
50-69	125-230	≥ 50	2.0-4.0	40-100
≥ 70	> 230	≥ 50	> 4.0	> 100
Near occlusion	High, low, or undetectable	Visible	Variable	Variable
Total occlusion	Undetectable	Visible, no detectable lumen	Not applicable	Not applicable

ICA, internal carotid artery; PSV, peak systolic velocity; CCA, common carotid artery; EDV, end-diastolic velocity.

^aStenosis (%) is based on conventional angiography.

Follow-up after carotid endarterectomy

CEA results in the blood vessels at the endarterectomy site becoming considerably wider, but the distal ones remain narrow, leading to higher measured blood flow velocities. This finding occurs particularly when artificial blood vessels are used in the stricture area during surgery. Reintervention consideration is suggested in postcarotid endarterectomies at 70-99% asymptomatic restenosis.¹⁰ There is no consensus on follow-up examinations using carotid ultrasound after CEA. Restenosis is known to occur less in cases of patch angioplasty than in those of primary closure.¹⁶ Therefore, a carotid ultrasonography follow-up is recommended for primary closure after 1 month, 6 months, and then annually.¹⁷ For patch angioplasty, further regular follow-ups are not required if findings are normal at the 6-month follow-up.¹⁸ The Society for Vascular Surgery in the United States recommend carotid duplex ultrasound at baseline and every 6 months for 2 years, and annually thereafter until it stabilizes (i.e., until no restenosis is observed in two consecutive annual scans).¹⁹

Follow-up after carotid angioplasty and stenting

In-stent restenosis after carotid artery stent placement is more common than restenosis after CEA. Restenosis occurrence should therefore be monitored. However, the degree of stenosis may be overestimated because of changes in blood flow and vascular compliance caused by the stent.¹⁹ In carotid artery stenting, since the degree of carotid artery stiffness increases due to the stent, the blood flow velocity through this area could increase. To reduce this, velocity thresholds need to be modified for follow-up observations of intrastent restenosis in the carotid artery (Table 2).²⁰⁻²² To monitor for intrastent restenosis, it is suggested to perform carotid ultrasonography within 30 days of the procedure, then every 6 months for 2 years, and annually thereafter.^{10,23} In contrast to the relatively high restenosis incidence, the risk of stroke is minimal. It is therefore recommended that asymptomatic restenosis should be treated medically at > 70% after CAS.¹⁵

Asymptomatic carotid stenosis

Asymptomatic carotid artery stenosis refers to stenosis that is accidentally revealed in a test and has not induced any neurological symptoms. It can be diagnosed if a patient has

not experienced cerebral or transient ischemia symptoms in the area supplied by the stenotic carotid artery or has experienced cerebral ischemia symptoms for more than 6 months.²⁴ The degree of stenosis and plaque characteristics can be used to estimate future ischemia risk. A study that assessed the future stroke risk in asymptomatic carotid stenosis estimated that the annual stroke risks was 1-2% in cases of 50-79% stenosis, 2-4% in cases of 80-89% stenosis, and 4-6% in cases of 90-99% stenosis.²⁵ Typically 20-25% of patients with asymptomatic carotid artery stenosis have been reported as showing progression in their degree of stenosis during follow-up examinations.^{26,27} TIA or ischemic stroke risk has been reported to increase by approximately threefold when the degree of asymptomatic carotid artery stenosis progresses to $\geq 80\%$ compared with cases without progression.²⁶ As characteristics of atherosclerotic plaques, echolucent or hypoechoic plaques are associated with plaque instability,²⁸ whereas echogenic or hyperechoic plaques are associated with plaque stability and are mostly observed in patients who have had asymptomatic carotid artery stenosis for a long period.²⁵ A study involving an asymptomatic population found that hypoechoic plaques were significantly associated with ipsilateral stroke risk after adjusting for other factors including stenosis, grayscale median, presence of discrete white areas with no acoustic shadowing to indicate neovascularization, plaque area, and contralateral TIA or stroke history.²⁹ Carotid ultrasound

Table 2. Suggested criteria for diagnosing in-stent restenosis after carotid artery stenting

	Stenosis ^a (%)	PSV (cm/s)	EDV (cm/s)	ICA/CCA ratio
Lal et al. ²²	0-19	< 150		< 2.15
	20-49	150-219		
	50-79	220-339		≥ 2.7
	80-99	≥ 340		≥ 4.15
AbuRahma et al. ²¹	30-49	> 154	> 42	> 1.533
	50-79	> 224	> 88	> 3.439
	80-99	> 325	> 119	> 4.533
Zhou et al. ²⁰	> 70	≥ 350		≥ 4.75

PSV, peak systolic velocity; EDV, end-diastolic velocity; ICA, internal carotid artery; CCA, common carotid artery.

^aStenosis (%) is based on conventional angiography.

screening for detecting asymptomatic carotid artery stenosis is generally not recommended.³⁰ However, when coronary artery disease, peripheral artery disease, or ≥ 2 risk factors for atherosclerosis are present, screening for carotid artery stenosis may be considered.¹⁷

Prediction of cardiovascular disease risk

Assessing carotid IMT and carotid atherosclerotic plaque measurements may be useful for predicting cardiovascular disease risk. The following patient characteristics can lead to consideration of carotid ultrasonography for evaluating the cardiovascular disease risk: early cardiovascular disease

Table 3. Carotid artery ultrasonography may be performed or considered in the following cases

Carotid artery ultrasonography may be performed or considered in the following cases

1. Initial assessment

- 1.1. If a lesion is suspected in the carotid or vertebral artery.
 - 1.1.1. When a new neurological symptom appears that is presumed to be associated with anterior circulation or an existing symptom that worsens.
 - 1.1.2. When a new neurological symptom appears that is presumed to be associated with posterior circulation or an existing symptom that worsens.
 - 1.1.3. When subclavian steal syndrome is suspected due to symptoms such as dizziness, headache, and visual field disturbances that occur when the arm is exercised excessively.
 - 1.1.4. When diagnosing spontaneous carotid artery dissections in patients with pulsatile lesions on the neck.
 - 1.1.5. If the Hollenhorst plaque is observed in a retinal examination.
 - 1.1.6. When carotid bruit is heard and a carotid artery examination has not been performed previously.
- 1.2. If a carotid or vertebral artery abnormality has been previously diagnosed, but revascularization has not been performed.
- 1.3. Screening may be considered for patients aged ≥ 65 years who are scheduled to undergo a coronary artery bypass graft surgery or in patients with left main coronary stenosis, peripheral artery stenosis, smoking, a history of stroke or transient ischemic attack, or carotid bruit.
- 1.4. In asymptomatic patients with no evidence of atherosclerosis, screening may be considered when two or more of the following risk factors are present: hypertension, hyperlipidemia, smoking, atherosclerosis in an immediate family member aged < 60 years, or a family history of cerebral infarction.
- 1.5. To assess the cardiovascular disease risk of the following patients: 1) an individual with moderate cardiovascular risk, 2) an immediate family member with early cardiovascular disease, 3) a patient aged < 60 years with one definite risk factor, and 4) a female aged < 60 years with two or more risk factors.

2. Follow-up assessment

- 2.1. Patients with previously diagnosed carotid artery stenosis, but who had not undergone revascularization.
 - 2.1.1. In patients with 70-99% stenosis of the carotid artery, follow-up examinations should be performed every 6 months.
 - 2.1.2. Annual follow-ups should be performed on patients with 50-69% stenosis of the carotid artery.
- 2.2. Patients with previously diagnosed carotid or vertebral artery stenosis who had undergone revascularization.
 - 2.2.1. When new neurological symptoms develop or existing symptoms worsen.
 - 2.2.2. Carotid ultrasound should be performed within 30 days of carotid artery stenting, then every 6 months for 2 years, and annually thereafter.
 - 2.2.3. If primary suturing is performed during a carotid endarterectomy, follow-up examinations are recommended at 1 month, 6 months, and then annually. In patch angioplasty cases, regular follow-ups are not recommended if findings at a 6-month follow-up are normal.
 - 2.2.4. If an abnormality is evident at the follow-up examination, the need to perform repeated revascularization should be evaluated by performing follow-up examinations every 6 months.
 - 2.2.5. If it is determined that further treatments are no longer required, follow-up examinations can be terminated.
- 2.3. Follow-up examinations should not be performed when the findings from previous carotid ultrasonography evaluations were normal.
- 2.4. A follow-up examination should not be performed within 1 year when an atherosclerotic plaque, but not stenosis, is present.
- 2.5. The evidence for performing follow-up examinations at intervals of at least 1 year is insufficient in cases with less than 50% stenosis of the carotid artery.

in immediate family members, aged < 60 years with at least one definite risk factor, and females aged < 60 years with two or more risk factors.⁴ However, carotid ultrasonography is not recommended when the patient has a diagnosed atherosclerotic disease, when the test results would not affect the treatment, or when the purpose is simply to identify worsening or improvement. The need for regular follow-up examinations is also contentious. A relationship between the progression (increase) of the carotid IMT over time and the risk of cardiovascular disease in a general population has not yet been established.³¹ It is also unclear whether treating increased carotid IMT or carotid atherosclerosis improves the cardiovascular disease prognoses.

Dissection

Cervical artery dissection is accompanied by various intravascular and extravascular changes, because blood vessels narrow after endovascular injury. The occurrence of an intimal tear results in the formation of an intramural hematoma between the intima and media. Intramural hematomas cause varying degrees of stenosis and occlusion. Duplex sonography can reveal hypoechoic thickening of the blood vessel wall. Its other findings include irregular stenosis, dissection flap, double lumen, pseudoaneurysm, or gradually narrowed vessel with distal obstruction.^{32,33} However, the ultrasonographic findings of carotid artery dissections are mostly nonspecific stenosis or obstruction, and they rarely reveal characteristic intimal detachment, double lumen, or pseudoaneurysm.³⁴

Carotid web

The carotid web is a thin membrane-like shape attached to the blood vessel wall that forms as the intima thickens and the media thins.³⁵ Although conventional digital subtraction angiography is the gold standard for diagnosing a carotid web, ultrasound can also be helpful, especially in young patients with cryptogenic stroke.^{36,37} Because current sonographic findings are mostly nonspecific, consideration and awareness of the condition are necessary. Several sonographic features relate to the carotid web, including mild bulbous outgrowth, hypochoic masses with a linear band extending into the lumen, focally arising artifacts with elevated peak systolic velocity, irregular echogenic plaque causing stenosis, and thin strands protruding into the lumen.³⁸

Subclavian steal syndrome

The Doppler ultrasound effect can be used to assess blood flow reflux in the vertebral artery. An alternating flow pattern or prominent midsystolic deceleration is observed unless a complete blood flow reversal occurs.^{39,40} Hyperemia tests using a blood pressure cuff can induce blood flow reversal and diagnose the hidden steal phenomenon.³⁹

SUGGESTIONS

Based on the discussed findings, we now present a summary of standard guidelines for performing carotid ultrasound in clinical practice (Table 3). These suggestions are based on an article published in *Journal of Neurosonology and Neuroimaging*:¹⁴ 1) Both the carotid and vertebral arteries should be examined, and B-mode and Doppler velocity measurements should be performed. 2) The necessity of carotid ultrasound is determined by the clinical symptoms, medical history, and other test results of a patient. Carotid ultrasound is not recommended for screening individuals with no related symptoms, medical history, or disease.

Conflicts of Interest

The authors declare no conflicts of interest relevant to this article.

REFERENCES

1. Lee W. General principles of carotid Doppler ultrasonography. *Ultrasonography* 2014;33:11-17.
2. Touboul PJ, Hennerici MG, Meairs S, Adams H, Amarenco P, Bornstein N, et al. Mannheim carotid intima-media thickness and plaque consensus (2004-2006-2011). An update on behalf of the advisory board of the 3rd, 4th and 5th watching the risk symposia, at the 13th, 15th and 20th European Stroke Conferences, Mannheim, Germany, 2004, Brussels, Belgium, 2006, and Hamburg, Germany, 2011. *Cerebrovasc Dis* 2012;34:290-296.
3. Lee SJ, Yu S, Hong JM, Ahn SH, Jeong SK, Lee JY, et al. Extracranial carotid duplex ultrasonography. Part I-basic principles and standard examination for carotid and vertebral arteries, and jugular veins. *J Neurosonol Neuroimag* 2018;10:47-60.
4. Stein JH, Korcarz CE, Hurst RT, Lonn E, Kendall CB, Mohler ER, et

- al. Use of carotid ultrasound to identify subclinical vascular disease and evaluate cardiovascular disease risk: a consensus statement from the American Society of Echocardiography Carotid Intima-Media Thickness Task Force. Endorsed by the Society for Vascular Medicine. *J Am Soc Echocardiogr* 2008;21:93-111; quiz 189-190.
5. Polak JF, Alessi-Chinetti JM, Kremkau FW. Doppler velocity estimates of internal carotid artery stenosis: angle correction parallel to the color Doppler Lumen versus parallel to the artery wall. *J Ultrasound Med* 2019;38:3211-3218.
 6. Kliewer MA, Freed KS, Hertzberg BS, Paulson EK, DeLong DM, Black BL, et al. Temporal artery tap: usefulness and limitations in carotid sonography. *Radiology* 1996;201:481-484.
 7. Youn YJ, Lee NS, Kim JY, Lee JW, Sung JK, Ahn SG, et al. Normative values and correlates of mean common carotid intima-media thickness in the Korean rural middle-aged population: the Atherosclerosis Risk of Rural Areas in Korea General Population (ARIRANG) study. *J Korean Med Sci* 2011;26:365-371.
 8. Lee YH, Shin MH, Kweon SS, Nam HS, Park KS, Choi JS, et al. Normative and mean carotid intima-media thickness values according to metabolic syndrome in Koreans: the Namwon study. *Atherosclerosis* 2014;234:230-236.
 9. Grant EG, Benson CB, Moneta GL, Alexandrov AV, Baker JD, Bluth EI, et al. Carotid artery stenosis: gray-scale and Doppler US diagnosis--society of radiologists in ultrasound consensus conference. *Radiology* 2003;229:340-346.
 10. Naylor AR, Ricco JB, de Borst GJ, Debus S, de Haro J, Halliday A, et al. Editor's choice - management of atherosclerotic carotid and vertebral artery disease: 2017 Clinical Practice Guidelines of the European Society for Vascular Surgery (ESVS). *Eur J Vasc Endovasc Surg* 2018;55:3-81.
 11. Jahromi AS, Cinà CS, Liu Y, Clase CM. Sensitivity and specificity of color duplex ultrasound measurement in the estimation of internal carotid artery stenosis: a systematic review and meta-analysis. *J Vasc Surg* 2005;41:962-972.
 12. Stojanov D, Ilic M, Bosnjakovic P, Zivkovic M, Jolic S, Vukasinovic N, et al. New ischemic brain lesions on diffusion-weighted MRI after carotid artery stenting with filter protection: frequency and relationship with plaque morphology. *AJNR Am J Neuroradiol* 2012;33:708-714.
 13. Madycki G, Staszkiwicz W, Gabrusiewicz A. Carotid plaque texture analysis can predict the incidence of silent brain infarcts among patients undergoing carotid endarterectomy. *Eur J Vasc Endovasc Surg* 2006;31:373-380.
 14. Lee JY, Choi HY, Lee SI, Hwang YH, Cho AH, Seo WK, et al. Extracranial carotid duplex ultrasonography. Part II-clinical utility of carotid duplex ultrasound. *J Neurosonol Neuroimag* 2018;10:61-79.
 15. Stilo F, Montelione N, Calandrelli R, Distefano M, Spinelli F, Di Lazzaro V, et al. The management of carotid restenosis: a comprehensive review. *Ann Transl Med* 2020;8:1272.
 16. Bond R, Rerkasem K, Naylor AR, Aburahma AF, Rothwell PM. Systematic review of randomized controlled trials of patch angioplasty versus primary closure and different types of patch materials during carotid endarterectomy. *J Vasc Surg* 2004;40:1126-1135.
 17. Brott TG, Halperin JL, Abbara S, Bacharach JM, Barr JD, Bush RL, et al. 2011 ASA/ACCF/AHA/AANN/AANS/ACR/ASNR/CNS/SAIP/SCAI/SIR/SNIS/SVM/SVS guideline on the management of patients with extracranial carotid and vertebral artery disease: executive summary. *Circulation* 2011;124:489-532.
 18. Aburahma AF. Duplex criteria for determining $\geq 50\%$ and $\geq 80\%$ internal carotid artery stenosis following carotid endarterectomy with patch angioplasty. *Vascular* 2011;19:15-20.
 19. Zierler RE, Jordan WD, Lal BK, Mussa F, Leers S, Fulton J, et al. The Society for Vascular Surgery practice guidelines on follow-up after vascular surgery arterial procedures. *J Vasc Surg* 2018;68:256-284.
 20. Zhou W, Felkai DD, Evans M, McCoy SA, Lin PH, Kougiaris P, et al. Ultrasound criteria for severe in-stent restenosis following carotid artery stenting. *J Vasc Surg* 2008;47:74-80.
 21. AbuRahma AF, Abu-Halimah S, Bensenhaver J, Dean LS, Keiffer T, Emmett M, et al. Optimal carotid duplex velocity criteria for defining the severity of carotid in-stent restenosis. *J Vasc Surg* 2008;48:589-594.
 22. Lal BK, Hobson RW 2nd, Tofghi B, Kapadia I, Cuadra S, Jamil Z. Duplex ultrasound velocity criteria for the stented carotid artery. *J Vasc Surg* 2008;47:63-73.
 23. Bandyk DF. Follow-up after carotid endarterectomy and stenting: What to look for and why. *Semin Vasc Surg* 2020;33:47-53.
 24. den Hartog AG, Achterberg S, Moll FL, Kappelle LJ, Visseren FL, van der Graaf Y, et al. Asymptomatic carotid artery stenosis and the risk of ischemic stroke according to subtype in patients with clinical manifest arterial disease. *Stroke* 2013;44:1002-1007.
 25. Icolaidis AN, Kakkos SK, Griffin M, Sabetai M, Dhanjil S, Tegos T, et al. Severity of asymptomatic carotid stenosis and risk of ipsilateral hemispheric ischaemic events: results from the ACSRS study. *Eur J Vasc Endovasc Surg* 2005;30:275-284.

26. Lewis RF, Abrahamowicz M, Côté R, Battista RN. Predictive power of duplex ultrasonography in asymptomatic carotid disease. *Ann Intern Med* 1997;127:13-20.
27. Cheng TW, Pointer KE, Gopal M, Farber A, Jones DW, Eberhardt RT, et al. Natural history of non-operative management in asymptomatic patients with 70%-80% internal carotid artery stenosis by duplex criteria. *Eur J Vasc Endovasc Surg* 2020;60:339-346.
28. Brinjikji W, Rabinstein AA, Lanzino G, Murad MH, Williamson EE, DeMarco JK, et al. Ultrasound characteristics of symptomatic carotid plaques: a systematic review and meta-analysis. *Cerebrovasc Dis* 2015;40:165-174.
29. Kakkos SK, Griffin MB, Nicolaidis AN, Kyriacou E, Sabetai MM, Tegos T, et al. The size of juxtaluminal hypoechoic area in ultrasound images of asymptomatic carotid plaques predicts the occurrence of stroke. *J Vasc Surg* 2013;57:609-618.e1; discussion 617-8.
30. US Preventive Services Task Force, Krist AH, Davidson KW, Mangione CM, Barry MJ, Cabana M, et al. Screening for asymptomatic carotid artery stenosis: US preventive services task force recommendation statement. *JAMA* 2021;325:476-481.
31. Lorenz MW, Polak JF, Kavousi M, Mathiesen EB, Völzke H, Tuomainen TP, et al. Carotid intima-media thickness progression to predict cardiovascular events in the general population (the PROG-IMT collaborative project): a meta-analysis of individual participant data. *Lancet* 2012;379:2053-2062.
32. Sturzenegger M, Mattle HP, Rivoir A, Baumgartner RW. Ultrasound findings in carotid artery dissection: analysis of 43 patients. *Neurology* 1995;45:691-698.
33. Yang L, Ran H. Extracranial vertebral artery dissection: findings and advantages of ultrasonography. *Medicine (Baltimore)* 2018;97:e0067.
34. Benninger DH, Baumgartner RW. Ultrasound diagnosis of cervical artery dissection. *Front Neurol Neurosci* 2006;21:70-84.
35. Bennani H, Alami B, Hajjar C, Quenum L, Haloua M, Boubbou M, et al. Symptomatic carotid web: about a rare ultrasound finding. *J Med Vasc* 2020;45:284-287.
36. Nezu T, Hosomi N. Usefulness of carotid ultrasonography for risk stratification of cerebral and cardiovascular disease. *J Atheroscler Thromb* 2020;27:1023-1035.
37. Park HK, Hong KS. Carotid web: under-recognized etiology for ischemic stroke. *J Neurosonol Neuroimag* 2018;10:100-105.
38. Kwon JA, Gwak DS, Shim DH, Kim YW, Hwang YH. Cryptogenic stroke caused by a carotid web with a superimposed thrombosis: serial neurosonologic findings. *J Neurosonol Neuroimag* 2019;11:158-161.
39. Kliwer MA, Hertzberg BS, Kim DH, Bowie JD, Courneya DL, Carroll BA. Vertebral artery Doppler waveform changes indicating subclavian steal physiology. *AJR Am J Roentgenol* 2000;174:815-819.
40. Lee JY. Duplex ultrasonography in vertebrobasilar system. *Journal of Neurosonology* 2009;1:14-18.