



# Relationship between rotational disc displacement of the temporomandibular joint and the dentoskeletal morphology

So-Hyun Park<sup>a</sup>   
Won-Jeong Han<sup>b</sup>  
Dong-Hwa Chung<sup>c</sup>  
Jung-Sub An<sup>d</sup>  
Sug-Joon Ahn<sup>e</sup> 

<sup>a</sup>Department of Orthodontics, Dankook University Jukjeon Dental Hospital, Yongin, Korea

<sup>b</sup>Department of Oral and Maxillofacial Radiology, College of Dentistry, Dankook University, Cheonan, Korea

<sup>c</sup>Department of Orthodontics, College of Dentistry, Dankook University, Cheonan, Korea

<sup>d</sup>Department of Orthodontics, Seoul National University Dental Hospital, Seoul, Korea

<sup>e</sup>Dental Research Institute and Department of Orthodontics, School of Dentistry, Seoul National University, Seoul, Korea

**Objective:** The purpose of this study was to evaluate the relationship between rotational disk displacement (DD) of the temporomandibular joint (TMJ) and the dentoskeletal morphology. **Methods:** Women aged > 17 years were included in this study. Each subject had a primary complaint of malocclusion and underwent routine cephalometric examinations. They were divided into five groups according to the findings on sagittal and coronal magnetic resonance images of their TMJs: bilateral normal disk position, bilateral anterior DD with reduction (ADDR), bilateral rotational DD with reduction (RDDR), bilateral anterior DD without reduction (ADDNR), and bilateral rotational DD without reduction (RDDNR). Twenty-three cephalometric variables were analyzed, and the Kruskal–Wallis test was used to evaluate differences in the dentoskeletal morphology among the five groups. **Results:** Patients with TMJ DD exhibited a hyperdivergent pattern with a retrognathic mandible, unlike those with a normal disk position. These specific skeletal characteristics were more severe in patients exhibiting DD without reduction than in those with reduction, regardless of the presence of rotational DD. Rotational DD significantly influenced horizontal and vertical skeletal patterns only in the stage of DD with reduction, and the mandible exhibited a more backward position and rotation in patients with RDDR than in those with ADDR. However, there were no significant dentoskeletal differences between ADDNR and RDDNR. **Conclusions:** The results of this study suggest that rotational DD of TMJ plays an important role in the dentoskeletal morphology, particularly in patients showing DD with reduction. [Korean J Orthod 2021;51(2):105–114]

**Key words:** Temporomandibular joint, Cephalometrics, Classification, Disk displacement

Received November 25, 2019; Revised March 17, 2020; Accepted March 25, 2020.

**Corresponding author:** Sug-Joon Ahn.

Professor, Dental Research Institute and Department of Orthodontics, School of Dentistry, Seoul National University, 101, Daehak-ro, Jongno-gu, Seoul 03080, Korea.

Tel +82-2-2072-2671 e-mail titoo@snu.ac.kr

So-Hyun Park and Won-Jeong Han contributed equally to this work.

**How to cite this article:** Park SH, Han WJ, Chung DH, An JS, Ahn SJ. Relationship between rotational disc displacement of the temporomandibular joint and the dentoskeletal morphology. Korean J Orthod 2021;51:105–114.

© 2021 The Korean Association of Orthodontists.

This is an Open Access article distributed under the terms of the Creative Commons Attribution Non-Commercial License (<http://creativecommons.org/licenses/by-nc/4.0>) which permits unrestricted non-commercial use, distribution, and reproduction in any medium, provided the original work is properly cited.

## INTRODUCTION

Disk displacement (DD) of the temporomandibular joint (TMJ) refers to an alteration in the normal position of the articular disk, related to the mandibular condyle and the articular eminence of the temporal bone.<sup>1</sup> Magnetic resonance imaging (MRI) is considered the gold standard for determining the TMJ disk position,<sup>2</sup> and the reported prevalence of TMJ DD diagnosed by MRI is approximately 30% and 82% in asymptomatic and symptomatic patients, respectively.<sup>3</sup> All forms of TMJ DD are more prevalent in female than in male individuals.<sup>4</sup>

Generally, TMJ DD is divided into anterior DD with reduction and anterior DD without reduction because of their higher prevalence. However, medial or lateral DD is also frequent<sup>5</sup> and commonly accompanied by anterior DD; this condition is termed rotational DD and classified into anteromedial and anterolateral rotational DD.<sup>3</sup>

TMJ DD has been of great interest to orthodontists because of its significant influence on the dentoskeletal morphology. Previous studies have demonstrated that the dentoskeletal morphology of patients with TMJ DD is associated with decreased posterior facial and ramus heights, backward rotation of the ramus and mandible, and increased overjet.<sup>6,7</sup> However, most studies have analyzed the relationships between TMJ DD and the dentoskeletal morphology without considering rotational DD. Although anterior DD is frequently associated with rotational DD, the prevalence of which is 9.7–35%,<sup>8,9</sup> relationships between rotational DD and dentoskeletal variables remain unclear. The aim of this study was to determine these relationships by using routine lateral cephalograms and TMJ MRI.

## MATERIALS AND METHODS

The sample for this retrospective study consisted of women aged > 17 years who visited the Department of Orthodontics at Seoul National University Dental Hospital between June 1995 and November 2016. Each subject had a primary complaint of malocclusion, and routine lateral cephalograms were acquired using the Asahi CX-90SP II (Asahi Roentgen, Kyoto, Japan). The inclusion criteria were as follows: 1) absence of any systemic disease, 2) no history of orthodontic or TMJ treatment, 3) no history of trauma involving the TMJ or juvenile rheumatoid arthritis, and 4) requirement of bilateral TMJ MRI because of potential TMJ problems. Girls aged < 17 years were not included to avoid growth-related size differences. The Institutional Review Board of the Seoul National University Dental Hospital approved the research protocol (CRI11040). Informed consent was waived.

Irrespective of the TMJ status, all patients consented

to take a bilateral high-resolution MRI in the sagittal (opened and closed) and coronal (closed) planes for evaluation of the TMJ. TMJ MRI was performed using the Signa Horizon (1.5 T; GE Healthcare, Waukesha, WI, USA) with a unilateral 3-inch surface receiver coil (GE Healthcare). T1-weighted (repetition time [TR]/echo time [TE], 600/12 ms) and proton-density (TR/TE, 4,000/14 ms) pulse sequences were obtained in the sagittal plane, with a 3-mm slice thickness, a 10-cm field of view, two excitations, and an image matrix of 254 × 192 pixels.

Three experienced investigators interpreted the images. Any disagreement was settled by discussion and consensus. Subsequently, the TMJ disk position on the sagittal and coronal views was divided into five categories according to the criteria described below.<sup>6,10,11</sup>

### Normal disk position (group 1)

The intermediate zone of the disk was interposed between the condylar head and the posterior slope of the articular eminence on the sagittal closed mouth images. On the coronal closed mouth images, the disk was located centrally on the condylar head including the medial and lateral poles of the condyle, without skewness from side to side (Figure 1A). When the jaw opened, the disk remained interposed between the osseous components and moved anteriorly in a synchronized fashion without medial or lateral displacement on the sagittal (from medial to lateral) open mouth images.

### Anterior DD with reduction (ADDR; group 2)

The posterior band of the disk was anterior to the posterior slope of the articular eminence and the condylar head on all sagittal closed mouth images, although the disk was recaptured and the disk–condyle relationship appeared normal upon mouth opening. The disk was located centrally on the condylar head on the coronal (from anterior to posterior, Figure 1A) closed mouth and sagittal (from medial to lateral) open mouth images.

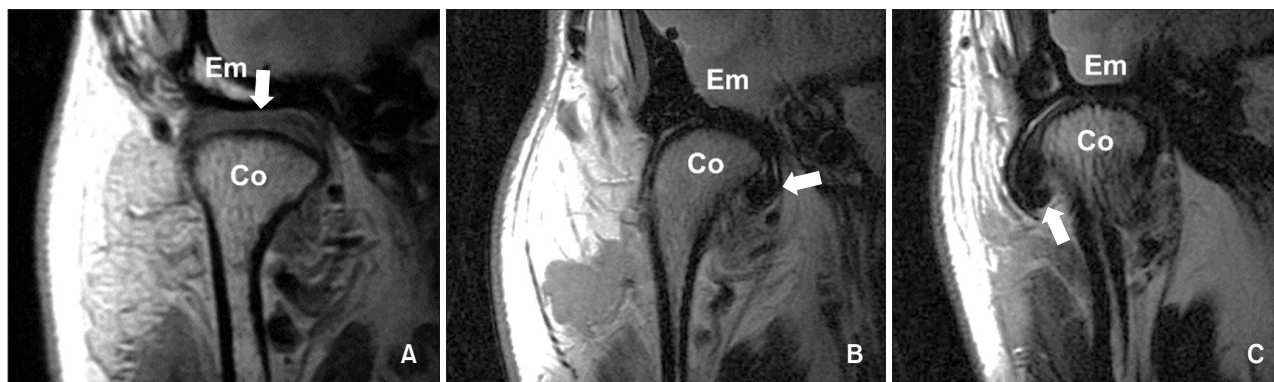
### Rotational DD with reduction (RDDR; group 3)

#### *Anteromedial RDDR*

In the closed mouth position, the disk was displaced both anteriorly and medially relative to the condyle (Figure 1B), although it was recaptured and located centrally on the condylar head upon mouth opening.

#### *Anterolateral RDDR*

In the closed mouth position, the disk was displaced both anteriorly and laterally relative to the condyle (Figure 1C), although it was recaptured and located centrally on the condylar head upon mouth opening.



**Figure 1.** Coronal images of the temporomandibular joint showing the disk (arrow) interposed between the condyle (Co) and articular eminence (Em) in the closed mouth position. **A**, Normal disk position. **B**, Medial disk displacement. **C**, Lateral disk displacement.

**Table 1.** Descriptive analysis of the sample size and age

Variable	Group 1 (n = 19)	Group 2 (n = 25)	Group 3 (n = 13)	Group 4 (n = 49)	Group 5 (n = 34)	p-value
Age (yr)	25.7 ± 9.4	28.9 ± 10.8	23.6 ± 5.3	24.0 ± 4.9	23.8 ± 4.8	0.3

Values are presented as mean ± standard deviation.

Group 1, patients with bilateral normal disk positions; Group 2, patients with bilateral anterior disk displacement with reduction; Group 3, patients with bilateral rotational disk displacement with reduction; Group 4, patients with bilateral anterior disk displacement without reduction; Group 5, patients with bilateral rotational disk displacement without reduction. The *p*-value was analyzed using the Kruskal-Wallis test at a significance level of *p* < 0.05.

#### *Anterior DD without reduction (ADDNR; group 4)*

In all sagittal sections, the posterior band of the disk was anterior to the posterior slope of the articular eminence and the condylar head in the closed mouth position, and the disk was not recaptured upon mouth opening. Although the disk was displaced, it remained central on the condylar head on coronal (from anterior to posterior, Figure 1A) closed mouth and sagittal (from medial to lateral) open mouth images.

#### **Rotational DD without reduction (RDDNR; group 5)**

##### *Anteromedial RDDNR*

In the closed mouth position, the disk was displaced both anteriorly and medially relative to the condyle (Figure 1B), and the disk was not recaptured upon mouth opening.

##### *Anterolateral RDDNR*

In the closed mouth position, the disk was displaced both anteriorly and laterally relative to the condyle (Figure 1C), and the disk was not recaptured upon mouth opening.

The disk positions were carefully evaluated according to the classification criteria. Ambiguous cases, such as those exhibiting partial DD or DD with partial reduction,

were excluded. The prevalence of TMJ symptoms in our sample has been described elsewhere.<sup>12</sup> Following classification, only patients with the same disk position in the left and right TMJs were included in consideration of the fact that skeletal characteristics associated with unilateral TMJ DD are obscured by averaging of the right and left landmarks used to determine their location on lateral cephalograms.<sup>13</sup>

We excluded cases involving pure medial or lateral DD without anterior DD because of the small sample size (only five). In addition, anteromedial and anterolateral rotational DDs were unified into rotational DD because of non-significant differences in dentoskeletal characteristics between patients with anteromedial DD and those with anterolateral DD (data not shown).

When power analysis was performed on the basis of a previous study,<sup>14</sup> at least 11 subjects per group were required in order to have sufficient power (80%) to identify statistically significant differences at the 5% level of significance. Finally, 140 patients were selected and classified into the five groups (Tables 1 and 2).

A single investigator traced all the cephalograms, and the tracings were registered in a digitizer interfaced with a desktop computer (V-ceph 6.0; Osstem, Seoul, Korea). Seventeen landmarks were digitized on each radiograph, and 23 variables were calculated. These variables were

**Table 2.** Comparison of dentoskeletal variables

Variable	Group 1 (n = 19)	Group 2 (n = 25)	Group 3 (n = 13)	Group 4 (n = 49)	Group 5 (n = 34)	p-value
<b>Horizontal skeletal relationships</b>						
Sella-Nasion-A point angle (°)	82.0 ± 2.8	81.6 ± 3.2	82.5 ± 3.6	81.5 ± 3.3	81.8 ± 3.0	0.742
Sella-Nasion-B point angle (°)	81.0 ± 4.0	76.6 ± 3.4	76.0 ± 3.4	73.7 ± 3.3	74.2 ± 4.1	< 0.001**
N-perpendicular to point A (mm)	1.7 ± 2.9	2.3 ± 3.3	2.7 ± 1.6	1.7 ± 3.4	2.0 ± 3.6	0.846
N-perpendicular to pogonion (mm)	1.2 ± 10.1	-6.1 ± 6.9	-9.9 ± 4.2	-14.6 ± 8.7	-14.0 ± 9.9	< 0.001**
A point-Nasion-B point angle (°)	1.0 ± 3.6	5.0 ± 2.7	6.6 ± 1.4	7.8 ± 2.6	7.6 ± 2.7	< 0.001**
<b>Vertical skeletal relationships</b>						
Frankfort horizontal plane to mandibular plane angle (°)	27.4 ± 5.4	29.4 ± 6.3	33.9 ± 5.7	35.3 ± 6.3	36.2 ± 7.4	< 0.001**
Maxillomandibular plane angle (°)	27.1 ± 5.8	28.9 ± 5.9	34.0 ± 4.8	34.4 ± 6.0	35.8 ± 6.6	< 0.001**
Anterior facial height (mm)	138.4 ± 5.9	138.2 ± 5.6	138.4 ± 6.0	137.3 ± 6.2	137.9 ± 6.9	0.649
Posterior facial height (mm)	89.4 ± 6.7	86.9 ± 6.3	83.0 ± 6.2	80.5 ± 6.0	80.6 ± 6.7	< 0.001**
Facial height ratio (%)	64.7 ± 4.9	63.0 ± 4.7	60.0 ± 5.0	58.7 ± 4.0	58.5 ± 5.2	< 0.001**
<b>Mandibular relationships</b>						
Ramus height (mm)	55.3 ± 5.5	51.5 ± 6.0	48.0 ± 4.9	46.5 ± 5.3	46.3 ± 5.4	< 0.001**
Ramus inclination (°)	94.4 ± 5.4	97.0 ± 5.2	98.3 ± 7.3	103.3 ± 5.8	101.0 ± 5.4	< 0.001**
Mandibular body length (mm)	82.0 ± 4.9	79.6 ± 4.5	78.1 ± 3.5	76.8 ± 5.6	75.9 ± 5.0	< 0.001**
Total mandibular body length (mm)	121.5 ± 7.0	116.2 ± 6.8	113.5 ± 3.7	109.2 ± 6.7	109.6 ± 5.8	< 0.001**
Mandibular body length ratio (%)	115.5 ± 7.4	111.8 ± 6.8	110.2 ± 6.7	108.2 ± 8.1	106.8 ± 7.7	0.002*
Gonial angle (°)	122.4 ± 7.1	122.7 ± 5.7	125.4 ± 7.5	122.0 ± 6.0	125.1 ± 6.4	0.178
<b>Dental relationships</b>						
Maxillary incisor to Sella-Nasion plane (°)	110.1 ± 6.9	105.9 ± 9.3	106.3 ± 4.5	105.5 ± 9.1	106.0 ± 9.0	0.350
Maxillary incisor to Frankfort horizontal plane angle (°)	119.5 ± 6.7	116.2 ± 8.6	116.1 ± 4.5	115.4 ± 8.5	115.8 ± 8.6	0.306
Mandibular incisor to Frankfort horizontal plane angle (°)	62.2 ± 11.7	54.7 ± 7.0	52.6 ± 6.2	46.9 ± 7.6	47.1 ± 7.1	< 0.001**
Mandibular incisor to mandibular plane angle (°)	90.4 ± 11.8	95.9 ± 6.9	93.5 ± 6.5	97.8 ± 6.8	96.8 ± 5.9	0.001*
Interincisal angle (°)	122.7 ± 11.8	118.5 ± 13.2	116.5 ± 8.5	111.5 ± 10.1	111.2 ± 11.0	0.006*
Overbite (mm)	0.3 ± 1.3	-0.2 ± 3.5	-1.1 ± 3.4	-1.4 ± 3.6	-1.2 ± 3.6	0.407
Overjet (mm)	0.8 ± 2.5	4.8 ± 2.2	5.5 ± 2.0	6.6 ± 2.4	5.9 ± 2.9	< 0.001**

Values are presented as mean ± standard deviation.

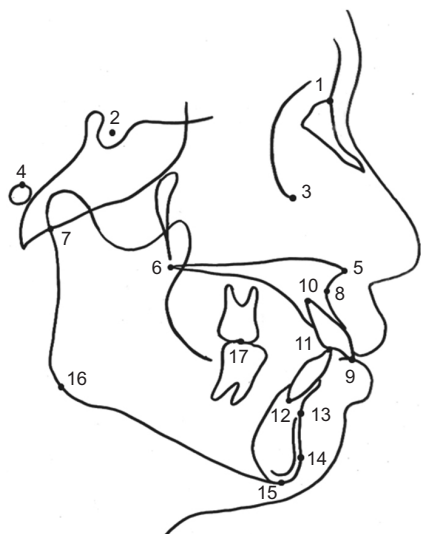
Group 1, patients with bilateral normal disk positions; Group 2, patients with bilateral anterior disk displacement with reduction; Group 3, patients with bilateral rotational disk displacement with reduction; Group 4, patients with bilateral anterior disk displacement without reduction; Group 5, patients with bilateral rotational disk displacement without reduction. The p-values were analyzed using the Kruskal–Wallis test at a significance level of  $p < 0.05$ .

\* $p < 0.05$ , \*\* $p < 0.001$ .

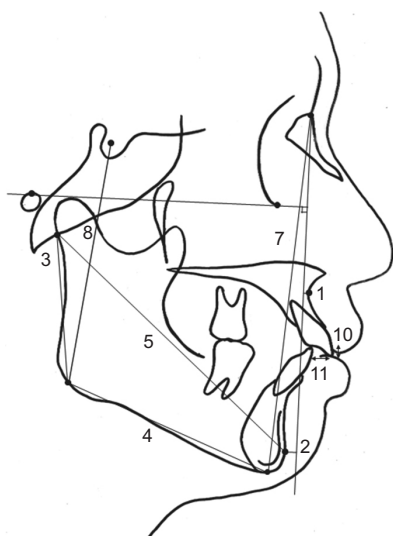
subdivided into four categories: horizontal skeletal, vertical skeletal, mandibular, and dental relationships (Table 2). The positions of all landmarks are shown in Figure 2, and their measurements are given in Figures 3 and 4.

To test the magnitude of the measurement error, we measured the lateral cephalograms of 15 randomly selected patients again after 2 weeks. According to Dahlberg’s formula,<sup>15</sup> the errors were 0.01 to 0.72 mm for

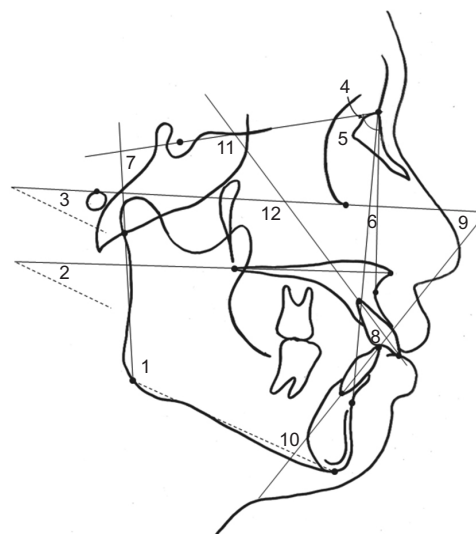
the linear measurements and 0.26° to 0.98° for the angular measurements. The Kruskal–Wallis test was used to analyze dentoskeletal differences among the five groups with respect to the TMJ DD status, while the Mann–Whitney *U* test with Bonferroni correction was used to analyze dentoskeletal differences between subset groups. A  $p$ -value of  $< 0.05$  was considered statistically significant.



**Figure 2.** Landmarks used for measurements in the study. 1, nasion; 2, sella; 3, orbitale; 4, porion; 5, anterior nasal spine; 6, posterior nasal spine; 7, articulare; 8, point A; 9, incisal end of maxillary incisor; 10, apex of maxillary incisor; 11, incisal end of mandibular incisor; 12, apex of mandibular incisor; 13, point B; 14, pogonion; 15, menton; 16, gonion; and 17, articulation of maxillary and mandibular molars.



**Figure 3.** Linear measurements obtained in the study. 1, N-perpendicular to point A; 2, N-perpendicular to pogonion; 3, ramus height; 4, mandibular body length; 5, total mandibular length; 6, mandibular body length ratio (mandibular body length/total mandibular length); 7, anterior facial height; 8, posterior facial height; 9, facial height ratio (posterior facial height/anterior facial height); 10, overbite; and 11, overjet.



**Figure 4.** Angular measurements obtained in the study. 1, gonial angle; 2, maxillomandibular plane angle; 3, Frankfort horizontal plane to mandibular plane angle (FMA); 4, sella-nasion-A point angle (SNA); 5, sella-nasion-B point angle (SNB); 6, A point-nasion-B point angle (ANB); 7, ramus inclination; 8, interincisal angle; 9, mandibular incisor to Frankfort horizontal plane angle (FMIA); 10, mandibular incisor to mandibular plane angle (IMPA); 11, maxillary incisor to sella-nasion plane angle; and 12, maxillary incisor to Frankfort horizontal plane angle.

## RESULTS

There were 19 women with a bilateral normal disk position (group 1), 25 with bilateral ADDR (group 2), 13 with bilateral RDDR (group 3), 49 with bilateral ADDNR (group 4), and 34 with bilateral RDDNR (group 5). The age range of patients was 17.0 to 57.8 years (mean,  $25.1 \pm 7.1$  years), and there were no significant differences in age distribution among the five groups (Table 1).

Tables 2 and 3 show that 16 cephalometric variables exhibited statistically significant differences among the five groups (Table 2), with significant differences mainly found between patients with a normal disk position (group 1) and those with TMJ DD (groups 2 to 5); between patients with ADDR (group 2) and those with RDDR, ADDNR, or RDDNR (groups 3, 4, or 5, respectively); and between patients with ADDR or RDDR (groups 2 or 3, respectively) and those with ADDNR or RDDNR (groups 4 or 5, respectively). There was no significant difference in dentoskeletal patterns between patients with ADDNR (group 4) and those with RDDNR (group 5; Table 3).

With regard to horizontal skeletal relationships, patients with TMJ DD (groups 2 to 5) showed a smaller Sella-Nasion-B point angle (SNB) and N-perpendicular

**Table 3.** Group comparisons of significant dentoskeletal variables

Dentoskeletal variable	Comparison of subset <sup>†</sup>
<b>Horizontal skeletal relationships</b>	
Sella-Nasion-B point angle (°)	(1 > 2, 3, 4, 5); (2, 3 > 4, 5)
N-perpendicular to pogonion (mm)	(1 > 2, 3, 4, 5); (2, 3 > 4, 5)
A point-Nasion-B point angle (°)	(1 < 2, 3, 4, 5); (2 < 3, 4, 5)
<b>Vertical skeletal relationships</b>	
Frankfort horizontal plane to mandibular plane angle (°)	(1 < 3, 4, 5); (2 < 3, 4, 5)
Maxillomandibular plane angle (°)	(1 < 3, 4, 5); (2 < 3, 4, 5)
Posterior facial height (mm)	(1 > 3, 4, 5); (2 > 4, 5)
Facial height ratio (%)	(1 > 3, 4, 5); (2 > 4, 5)
<b>Mandibular relationships</b>	
Ramus height (mm)	(1 > 3, 4, 5); (2 > 4, 5)
Ramus inclination (°)	(1 < 4, 5); (2, 3 < 4, 5)
Mandibular body length (mm)	(1 > 3, 4, 5); (2 > 4, 5)
Total mandibular body length (mm)	(1 > 2, 3, 4, 5); (2, 3 > 4, 5)
Mandibular body length ratio (%)	(1 > 3, 4, 5); (2 > 5)
<b>Dental relationships</b>	
Frankfort horizontal plane to mandibular incisor angle (°)	(1 > 2, 3, 4, 5); (2, 3 > 4, 5)
Interincisal angle (°)	(1 > 4, 5); (2 > 4, 5)
Mandibular incisor to mandibular plane angle (°)	(1 < 2, 4, 5)
Overjet (mm)	(1 < 2, 3, 4, 5); (2 < 4, 5)

1, bilateral normal disk position group; 2, bilateral anterior disk displacement with reduction group; 3, bilateral rotational disk displacement with reduction group; 4, bilateral anterior disk displacement without reduction group; 5, bilateral rotational disk displacement without reduction group.

<sup>†</sup>The Mann-Whitney *U* test with Bonferroni correction was performed to analyze dentoskeletal differences between subset groups.

to pogonion and a larger A point-Nasion-B point angle (ANB) than those with a normal disk position (group 1). However, N-perpendicular to point A and Sella-Nasion-A point angle (SNA) showed no significant difference between patients with TMJ DD and those with a normal disk position. In addition, the SNB and N-perpendicular to pogonion were significantly different between groups 2 or 3 (ADDR or RDDR, respectively) and groups 4 or 5 (ADDNR or RDDNR, respectively; ADDR, RDDR > ADDNR, RDDNR), while the ANB was significantly different between group 2 (ADDR) and groups 3, 4, or 5 (RDDR, ADDNR, or RDDNR, respectively; ADDR < RDDR, ADDNR, RDDNR; Tables 2 and 3).

Relative to the vertical skeletal relationships in patients with a normal disk position, the Frankfort horizontal plane to mandibular plane angle and the maxillomandibular plane angle increased while the posterior facial height and facial height ratio decreased in patients with TMJ DD (groups 2 to 5; Table 2). Differences were mainly observed between group 1 (normal disk position) and groups 3, 4, or 5 (RDDR, ADDNR, or RDDNR,

respectively) and between group 2 (ADDR) and groups 4 or 5 (ADDNR or RDDNR, respectively). However, there was no significant difference in the anterior facial height among the five groups (Table 3).

With regard to mandibular relationships, the ramus height, mandibular body length, and mandibular body length to anterior cranial base length ratio gradually decreased, although the ramus inclination increased, as TMJ DD progressed. However, the gonial angle was not significantly different among the five groups (Table 2). Differences were mainly observed between group 1 (normal disk position) and groups 3, 4, or 5 (RDDR, ADDNR, or RDDNR, respectively) and between groups 2 or 3 (ADDR or RDDR, respectively) and groups 4 or 5 (ADDNR or RDDNR, respectively; Table 3). However, there was no significant difference in the anterior facial height among groups.

With regard to dental variables, the mandibular incisors were more labially proclined relative to the cranial base and mandibular plane, the interincisal angle was smaller, and the overjet was larger in patients with TMJ

DD (groups 2 to 5) than in those with a normal disk position (group 1). The positions of the maxillary incisors and overbite were not significantly influenced by the TMJ DD status (Tables 2 and 3).

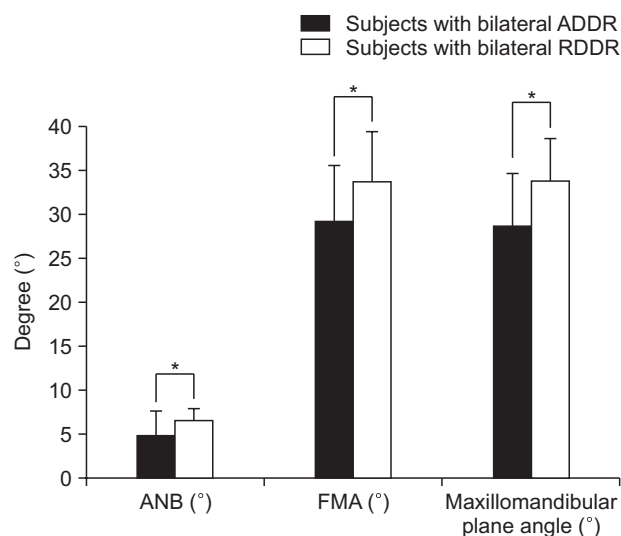
In order to evaluate the influence of rotational DD on the dentoskeletal morphology, we compared dentoskeletal variables between groups 2 (ADDR) and 3 (RDDR) and between groups 4 (ADDNR) and 5 (RDDNR). The ANB, Frankfort horizontal plane to mandibular plane angle, and maxillomandibular plane angle were significantly different between groups 2 and 3 (Figure 5). The results showed that patients with RDDR exhibited greater ANB, Frankfort horizontal plane to mandibular plane, and maxillomandibular plane angles than did those with ADDR (Tables 2 and 3, Figure 5). However, there were no significant differences in dentoskeletal variables between ADDNR and RDDNR (Tables 2 and 3).

The profilograms showed gradual profile changes, including a retrognathic mandible with a hyperdivergent pattern and increased overjet, as TMJ DD progressed. The most evident differences were seen between groups 1 and 2, while the least evident differences were seen between groups 4 and 5 (Figure 6).

### DISCUSSION

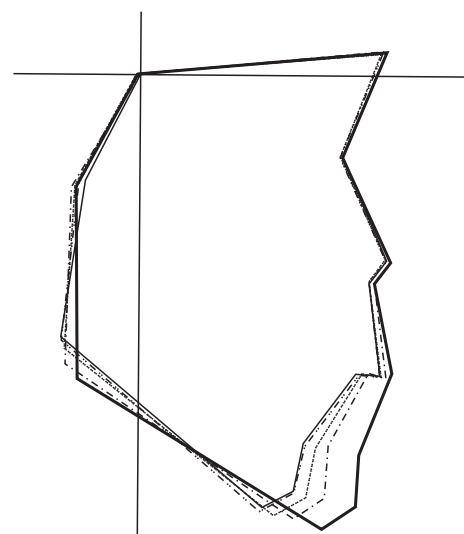
Although anterior displacement is the most common type of TMJ DD, arthrography and MRI studies have

shown that lateral and medial DDs are frequently accompanied by anterior DD.<sup>8,16</sup> A previous MRI study showed the type and prevalence of the disk position and displacement in 259 TMJs in female patients and symptom-free volunteers; anterior DD was most common (50.6%) and rotational DD was the second most common (49.8%), including anterolateral DD (41.7%) and anteromedial DD (8.1%).<sup>3</sup> In another MRI study of 545 TMJs with internal derangement, among rotational DD cases, 53% showed anterior DD with reduction and 34% showed anterior DD without reduction.<sup>17</sup> They determined that rotational DD was an important aspect of TMJ DD.<sup>16,17</sup> In the present study, 47 of 140 patients (33.6%) exhibited bilateral anteromedial or anterolateral rotational DD; there were 13 patients with RDDR (9.3%) and 34 with RDDNR (24.3%; Table 2). These results indicate that rotational DD should not be ignored when diagnosing TMJ DD. However, most studies have only investigated the relationships between anterior DD and altered facial morphological parameters, although TMJ DD occurs in both the sagittal and coronal directions. Until now, no study has investigated dentoskeletal differences with respect to rotational DD of the TMJ. The purpose of the present study was to analyze differences in dentoskeletal characteristics among patients with TMJ DD according to their coronal as well as sagittal disk positions. We found that the dentoskeletal characteristics



**Figure 5.** Dentoskeletal variables with significant differences between subjects with bilateral anterior disk displacement with reduction (ADDR) and those with bilateral rotational disk displacement with reduction (RDDR). ANB, A point-Nasion-B point angle; FMA, Frankfort horizontal plane to mandibular plane angle. Mann-Whitney *U* test; \**p* < 0.05.

- Bilateral normal disk position
- - - Bilateral anterior disk displacement with reduction
- ..... Bilateral rotational disk displacement with reduction
- - - Bilateral anterior disk displacement without reduction
- ..... Bilateral rotational disk displacement without reduction



**Figure 6.** Profilogram comparisons among five groups stratified according to the position of the temporomandibular joint disk on coronal and sagittal magnetic resonance images.

associated with TMJ DD were differently represented according to the coronal as well as sagittal relationships of the condyle–disk complex.

TMJ DD is related to skeletal Class II relationship with a hyperdivergent pattern,<sup>6,7,14,18</sup> and these features become more severe as the displacement progresses to a severe condition.<sup>7</sup> Similar to the results of previous studies focusing on the relationships between dentoskeletal variables and anterior DD without considering rotational DD,<sup>6,14</sup> the present study found dentoskeletal differences among patients with a normal disk position (group 1), ADDR (group 2), and ADDNR (group 4). Patients with TMJ DD had a decreased ramus height and backward rotation of the ramus compared to those with normal disk position. Moreover, the dentoskeletal features gradually became more severe as TMJ DD progressed from ADDR to ADDNR (Tables 2 and 3). These differences in dentoskeletal morphology associated with TMJ DD are thought to result from growth disturbance and/or osseous changes in the condylar head according to the progression of TMJ DD.<sup>19,20</sup> Although the cause-and-effect relationship is unclear, recent studies using MRI demonstrated a causal relationship between TMJ DD and skeletal deformity or disturbed growth.<sup>19,21</sup> The articular tissues of the TMJ have a remarkable adaptive capacity under normal circumstances. However, their capacity for excessive or sustained mechanical loads is not infinite.<sup>22</sup> As TMJ DD progresses, protective functions of the TMJ disk during functional jaw movements decreases, generating highly reactive molecular cascades associated with remodeling of the articular tissues in the affected condyle. If the mechanical or functional loads exceed the adaptive capacity of the TMJ, or if the affected subject is susceptible to maladaptive responses, regressive bony remodeling of the mandibular condyle commonly occurs as a consequence of TMJ DD.<sup>22</sup> An MRI study of growing facial skeletons reported that TMJ DD in children may either retard or arrest condylar growth, which results in decreased vertical dimensions in the proximal mandibular segments (condyle and condylar neck) and, eventually, mandibular deficiency or asymmetry.<sup>19</sup> This growth disturbance is caused by degenerative osseous erosion involving the proximal mandible, accentuating a retrognathic mandible with a hyperdivergent pattern. Degenerative osseous erosion is a frequent complication of TMJ DD and leads to regressive bony remodeling, and repetitive occurrences of degenerative osseous erosion (regional osteoporosis) and adaptive osseous remodeling (sclerosis and cortical thickening) tend to decrease the size of the condyle according to the progression of TMJ DD.<sup>20</sup> The decreased size of the condyle associated with TMJ DD causes backward rotation and posterior positioning of the mandible and is accompanied by changes in the mandibular shape, eventually resulting specific

dentoskeletal alterations. The cause-and-effect hypothesis is supported by several animal studies showing that experimentally induced DD can reduce the mandibular height and length through regressive condylar remodeling.<sup>23,24</sup>

In the present study, we compared dentoskeletal variables between patients with ADDR (group 2) and those with RDDR (group 3) and between patients with ADDNR (group 4) and those with RDDNR (group 5), in order to evaluate the relationship between rotational DD and the dentoskeletal morphology. The results indicated that patients with RDDR had a more retrognathic mandible with a hyperdivergent pattern (larger ANB, Frankfort horizontal plane to mandibular plane angle, and maxillomandibular plane angle) than those with ADDR (Table 3, Figure 5). The profilograms also showed significant differences in dentoskeletal patterns between ADDR and RDDR (Figure 6). However, we did not find significant differences between patients with ADDNR and those with RDDNR (Figure 6). These results indicate that rotational DD may significantly influence the dentoskeletal morphology only in patients having DD with reduction, with minimal influence in those having DD without reduction. These findings can be explained by the degree of DD in the presence of rotational DD. The functions of the disk include transmission of force, protection, and lubrication of the articulating surface in the TMJ.<sup>25</sup> When the shape and position of the disk changes, soft tissue inflammation occurs and osseous tissues are destroyed.<sup>26</sup> When there is no rotational DD, the disk is displaced only in the anterior direction. Whereas, when there is rotational DD, it is displaced in the anterolateral or anteromedial direction. This means that DD may be more complicated with a greater degree of displacement in RDDR than in ADDR. Therefore, more severe disk dysfunction is induced by RDDR than by ADDR and RDDR can influence condylar and mandibular morphologies more significantly than can ADDR. These findings are supported by a previous study showing that changes in condylar dimensions were greater in cases with anteromedial or anterolateral rotational DD than in those with pure anterior DD.<sup>27</sup>

On the other hand, rotational DD did not significantly affect the dentoskeletal morphology when it progressed to DD without reduction (Table 3). In DD without reduction, the disk is not recaptured during mouth opening or in the closed mouth position. Therefore, the disk cannot perform its original functions in the condyle–disk complex in both open and closed mouth positions. In addition, the disk shows a larger degree of displacement in DD without reduction than in DD with reduction, and this may induce more severe functional and morphological alterations in the condyle–disk complex, such as disk perforation and joint effusion.<sup>21</sup> Consequently,



more severe bony changes may occur in the condylar head in both ADDNR and RDDNR, and differences in the dentoskeletal morphology between ADDNR and RDDNR may not be statistically significant. This hypothesis is supported by the results of our study, which revealed significant differences in the SNB, N-perpendicular to pogonion, ramus inclination, total mandibular body length, and mandibular incisor to Frankfort horizontal plane angle between patients exhibiting DD without reduction (ADDNR or RDDNR) and those exhibiting DD with reduction (ADDR or RDDR; Tables 2 and 3). More severe hyperdivergent, retrognathic skeletal patterns were found in patients with ADDNR or RDDNR than in those with ADDR or RDDR (Table 2, Figure 6).

We included only women in this study because the number of male patients was limited, probably because TMJ DD shows a significant female predominance.<sup>28</sup> However, there may be no significant differences in dentoskeletal patterns between men and women with rotational DD, because dentoskeletal alterations associated with TMJ DD are not significantly different between the two sexes.<sup>29,30</sup>

This study has some limitations. First, we could not include patients with pure medial or lateral DD without anterior DD because of their limited number. Second, longitudinal samples were not included in this study. Longitudinal samples can provide information on the effects of progressive condylar resorption as well as cause-effect relationships between TMJ DD and the dentofacial morphology. Additional longitudinal studies with larger sample sizes should investigate specific dentoskeletal aspects associated with unilateral rotational and/or pure sideways DD of TMJ.

## CONCLUSION

TMJ DD was significantly associated with a hyperdivergent Class II morphology with a retrognathic mandible. This specific dentoskeletal morphology became more evident as DD progressed (with reduction to without reduction), regardless of the presence of rotational DD. Rotational DD significantly influenced the dentoskeletal morphology, specifically in the stage of DD with reduction, and subjects with RDDR showed a more retrognathic mandible with a hyperdivergent pattern than did those with ADDR. However, rotational DD had a minimal impact on the dentoskeletal morphology when it progressed from displacement with reduction to displacement without reduction, which is the terminal stage of TMJ DD. Within the study limitations, the results suggest that the coronal classification of TMJ DD should be carefully evaluated, particularly in orthodontic patients exhibiting DD with reduction.

## CONFLICTS OF INTEREST

No potential conflict of interest relevant to this article was reported.

## ACKNOWLEDGEMENTS

This work was supported by the Korea government Ministry of Trade, Industry and Energy (#10063356).

## REFERENCES

1. Ernberg M. The role of molecular pain biomarkers in temporomandibular joint internal derangement. *J Oral Rehabil* 2017;44:481-91.
2. Larheim TA. Role of magnetic resonance imaging in the clinical diagnosis of the temporomandibular joint. *Cells Tissues Organs* 2005;180:6-21.
3. Tasaki MM, Westesson PL, Isberg AM, Ren YF, Tallents RH. Classification and prevalence of temporomandibular joint disk displacement in patients and symptom-free volunteers. *Am J Orthod Dentofacial Orthop* 1996;109:249-62.
4. Talaat WM, Adel OI, Al Bayatti S. Prevalence of temporomandibular disorders discovered incidentally during routine dental examination using the Research Diagnostic Criteria for Temporomandibular Disorders. *Oral Surg Oral Med Oral Pathol Oral Radiol* 2018;125:250-9.
5. Tamimi D, Jalali E, Hatcher D. Temporomandibular joint imaging. *Radiol Clin North Am* 2018;56:157-75.
6. Ahn SJ, Kim TW, Nahm DS. Cephalometric keys to internal derangement of temporomandibular joint in women with Class II malocclusions. *Am J Orthod Dentofacial Orthop* 2004;126:485-94; discussion 494-5.
7. Nebbe B, Major PW, Prasad Ng. Female adolescent facial pattern associated with TMJ disk displacement and reduction in disk length: part I. *Am J Orthod Dentofacial Orthop* 1999;116:168-76.
8. Houry MB, Dolan E. Sideways dislocation of the temporomandibular joint meniscus: the edge sign. *AJNR Am J Neuroradiol* 1986;7:869-72.
9. Tasaki MM, Westesson PL. Temporomandibular joint: diagnostic accuracy with sagittal and coronal MR imaging. *Radiology* 1993;186:723-9.
10. Liedberg J, Westesson PL, Kurita K. Sideways and rotational displacement of the temporomandibular joint disk: diagnosis by arthrography and correlation to cryosectional morphology. *Oral Surg Oral Med Oral Pathol* 1990;69:757-63.
11. Aoyama S, Kino K, Amagasa T, Sakamoto I, Omura K, Honda E, et al. Clinical and magnetic resonance

- imaging study of unilateral sideways disc displacements of the temporomandibular joint. *J Med Dent Sci* 2002;49:89-94.
12. Jeon DM, Jung WS, Mah SJ, Kim TW, Ahn SJ. The effects of TMJ symptoms on skeletal morphology in orthodontic patients with TMJ disc displacement. *Acta Odontol Scand* 2014;72:776-82.
  13. Ahn SJ, Lee SP, Nahm DS. Relationship between temporomandibular joint internal derangement and facial asymmetry in women. *Am J Orthod Dentofacial Orthop* 2005;128:583-91.
  14. Ahn SJ, Baek SH, Kim TW, Nahm DS. Discrimination of internal derangement of temporomandibular joint by lateral cephalometric analysis. *Am J Orthod Dentofacial Orthop* 2006;130:331-9.
  15. Dahlberg G. *Statistical methods for medical and biological students*. London: G. Allen & Unwin Ltd; 1940. 232 p.
  16. Katzberg RW, Westesson PL, Tallents RH, Anderson R, Kurita K, Manzione JV Jr, et al. Temporomandibular joint: MR assessment of rotational and sideways disk displacements. *Radiology* 1988;169:741-8.
  17. Foucart JM, Carpentier P, Pajoni D, Marguelles-Bonnet R, Pharaboz C. MR of 732 TMJs: anterior, rotational, partial and sideways disc displacements. *Eur J Radiol* 1998;28:86-94.
  18. Brand JW, Nielson KJ, Tallents RH, Nanda RS, Currier GF, Owen WL. Lateral cephalometric analysis of skeletal patterns in patients with and without internal derangement of the temporomandibular joint. *Am J Orthod Dentofacial Orthop* 1995;107:121-8.
  19. Schellhas KP, Pollei SR, Wilkes CH. Pediatric internal derangements of the temporomandibular joint: effect on facial development. *Am J Orthod Dentofacial Orthop* 1993;104:51-9.
  20. Chang MS, Choi JH, Yang IH, An JS, Heo MS, Ahn SJ. Relationships between temporomandibular joint disk displacements and condylar volume. *Oral Surg Oral Med Oral Pathol Oral Radiol* 2018;125:192-8.
  21. Schellhas KP, Piper MA, Omlie MR. Facial skeleton remodeling due to temporomandibular joint degeneration: an imaging study of 100 patients. *AJNR Am J Neuroradiol* 1990;11:541-51.
  22. Milam SB. Pathogenesis of degenerative temporomandibular joint arthritides. *Odontology* 2005;93:7-15.
  23. Legrell PE, Reibel J, Nylander K, Hörstedt P, Isberg A. Temporomandibular joint condyle changes after surgically induced non-reducing disk displacement in rabbits: a macroscopic and microscopic study. *Acta Odontol Scand* 1999;57:290-300.
  24. Legrell PE, Isberg A. Mandibular length and midline asymmetry after experimentally induced temporomandibular joint disk displacement in rabbits. *Am J Orthod Dentofacial Orthop* 1999;115:247-53.
  25. Osborn JW. The disc of the human temporomandibular joint: design, function and failure. *J Oral Rehabil* 1985;12:279-93.
  26. Takahara N, Nakagawa S, Sumikura K, Kabasawa Y, Sakamoto I, Harada H. Association of temporomandibular joint pain according to magnetic resonance imaging findings in temporomandibular disorder patients. *J Oral Maxillofac Surg* 2017;75:1848-55.
  27. Torres MG, Crusoé-Rebello IM, Rosário M, Albuquerque MC, Campos PS. Morphometric features of the mandibular condyle and association with disk abnormalities. *Oral Surg Oral Med Oral Pathol Oral Radiol* 2016;121:566-72.
  28. Nebbe B, Major PW. Prevalence of TMJ disc displacement in a pre-orthodontic adolescent sample. *Angle Orthod* 2000;70:454-63.
  29. Kwon HB, Kim H, Jung WS, Kim TW, Ahn SJ. Gender differences in dentofacial characteristics of adult patients with temporomandibular disc displacement. *J Oral Maxillofac Surg* 2013;71:1178-86.
  30. Ikeda R, Ikeda K. Directional characteristics of incipient temporomandibular joint disc displacements: a magnetic resonance imaging study. *Am J Orthod Dentofacial Orthop* 2016;149:39-45.