

Original Article



Suspecting Intussusception and Recurrence Risk Stratification Using Clinical Data and Plain Abdominal Radiographs

Ye Rim Oh ,¹ Bo Kyung Je ,² Chaeyoun Oh ,³ Jae Hyung Cha ,⁴ and Jee Hyun Lee ⁵

¹Department of Pediatrics, Korea University Anam Hospital, Seoul, Korea

²Department of Radiology, Korea University Ansan Hospital, Ansan, Korea

³Department of Pediatric Surgery, Korea University Ansan Hospital, Ansan, Korea

⁴Medical Science Research Center, Korea University Ansan Hospital, Ansan, Korea

⁵Department of Pediatrics, Korea University Ansan Hospital, Ansan, Korea

OPEN ACCESS

Received: Jul 27, 2020

1st Revised: Sep 21, 2020

2nd Revised: Oct 5, 2020

Accepted: Oct 17, 2020

Correspondence to

Jee Hyun Lee

Department of Pediatrics, Korea University Ansan Hospital, 123 Jeokgeum-ro, Danwon-gu, Ansan 15355, Korea.

E-mail: izzihn@gmail.com

Copyright © 2021 by The Korean Society of Pediatric Gastroenterology, Hepatology and Nutrition

This is an open-access article distributed under the terms of the Creative Commons Attribution Non-Commercial License (<https://creativecommons.org/licenses/by-nc/4.0/>) which permits unrestricted non-commercial use, distribution, and reproduction in any medium, provided the original work is properly cited.

ORCID iDs

Ye Rim Oh

<https://orcid.org/0000-0001-6087-3119>

Bo Kyung Je

<https://orcid.org/0000-0001-8335-9980>

Chaeyoun Oh

<https://orcid.org/0000-0001-9734-0869>

Jae Hyung Cha

<https://orcid.org/0000-0003-3072-4846>

Jee Hyun Lee

<https://orcid.org/0000-0002-4318-2487>

Conflict of Interest

The authors have no financial conflicts of interest.

<https://pghn.org>

ABSTRACT

Purpose: Although ultrasonography is the gold standard of diagnosing intussusception, plain abdomen radiograph (AXR) is often used to make differential diagnosis for pediatric patients with abdominal pain. In intussusception patients, we aimed to analyze the AXR and clinical data to determine the characteristics of early AXR findings associated with diagnosis of intussusception and recurrence after reduction.

Methods: Between January 2011 and June 2018, 446 patients diagnosed with intussusception based on International Classification of Diseases-10 code of K56.1 were admitted. We retrospectively reviewed medical records of 398 patients who received air reduction; 51 of them have recurred after initial reduction. We evaluated six AXR features including absent ascending colon gas, absent transverse colon gas, target sign, meniscus sign, mass, and ileus. Clinical data and AXR features were compared between single episode and recurrence groups.

Results: Two groups did not show significant differences regarding clinical data. Mean time to recurrence from air reduction was 3.4±3.2 days. Absent ascending colon gas (63.9%) was the most common feature in intussusception, followed by mass (29.1%). All of six AXR features were observed more frequently in the recurrence group. Absent transverse colon gas was the most closely associated AXR finding for recurrence (odds ratio, 2.964; 95% confidence interval, 1.327–6.618; $p=0.008$).

Conclusion: In our study, absence of ascending colon gas was the most frequently seen AXR factor in intussusception patients. Extended and careful observation after reduction may be beneficial if such finding on AXR is found in intussusception patients.

Keywords: Intussusception; Recurrence; Abdominal radiographs; Pediatrics

INTRODUCTION

Intussusception is the second most common cause of acute abdominal emergency in children, second only to acute appendicitis [1]. It is defined as an invagination of one segment of intestine within another. It is one of the most common causes of intestinal

obstruction in early childhood [2]. Most cases of intussusception are idiopathic. About 10% of cases have a lead point [3]. Approximately 80–90% of children affected by intussusception are younger than 2 years old, although intussusception may occur at any age [4]. Nonetheless, it is often challenging for clinicians to diagnose intussusception based solely on history and physical examination. The “classic triad” (i.e., colicky abdominal pain, bloody stool, and palpable mass) is present in less than 40% of patients [2,3]. Most cases of intussusception show atypical symptoms and signs. Traditionally, radiographic finding with soft-tissue mass in right upper quadrant raises high suspicion of intussusception. Such mass is present in 25–60% of confirmed cases. However, sensitivity (36–90%) and specificity (45–90%) of abdomen radiograph (AXR) for detecting intussusception vary [5].

For definite diagnosis of intussusception, ultrasonography (USG) has emerged as the first-line modality over the last two decades [6]. USG is a favored method of choice since it is non-invasive, radiation-free, painless, fast, and relatively low in cost [5,7]. Additionally, it has high sensitivity and specificity for detection of intussusception (97.9% and 97.8%, respectively). Its high negative predictive value for excluding intussusception (99.7%) made it an ideal first-line diagnostic choice, that clinicians often rely on USG for diagnosing intussusception [8]. Nonetheless, AXR is often the initial imaging technique to make differential diagnosis for pediatric patients with abdominal pain, since it is easy to perform and relatively inexpensive. Therefore, in this paper, we aimed to analyze the AXR and clinical data to determine the characteristics of early AXR findings associated with the diagnosis of intussusception and recurrence after reduction.

MATERIALS AND METHODS

Patients

We reviewed 446 patients diagnosed with intussusception based on International Classification of Diseases-10 (ICD-10) classification code of K56.1 who presented to Korea University Ansan Hospital between January 2011 and June 2018.

The study excluded patients who were diagnosed with transient small bowel intussusception on USG and included only those who received air reduction. The patients were divided into two groups; those who received successful reduction without recurrence were assigned into a single episode group, while those with recurrence after initial reduction were assigned into a recurrence episode group (**Fig. 1**). Within the recurrence episode group, we have subcategorized the patients who have recurred after 14 days of initial treatment into relapsed group. When analyzing clinical data and AXR in recurrent intussusception patients, we have excluded the data of the relapsed group; we thought it was inappropriate to make the relapsed group's analysis using the data from time of first diagnosis. Ten patients had no AXR in our database. Thus, they were eliminated from the AXR analysis (**Fig. 1**).

Study design

We retrospectively evaluated patients according to their medical records obtained when they first came to hospital, including the following: (1) symptoms such as abdominal pain and/or irritability, bloody stool, vomiting, diarrhea, fever, and lethargy; (2) signs such as abdominal distension, abdominal tenderness, and abdominal mass; and (3) laboratory findings such as white blood cell (WBC) count, erythrocyte sedimentation rate (ESR), levels of C-reactive protein (CRP), and total carbon dioxide (tCO₂). At our institution, definite diagnosis was

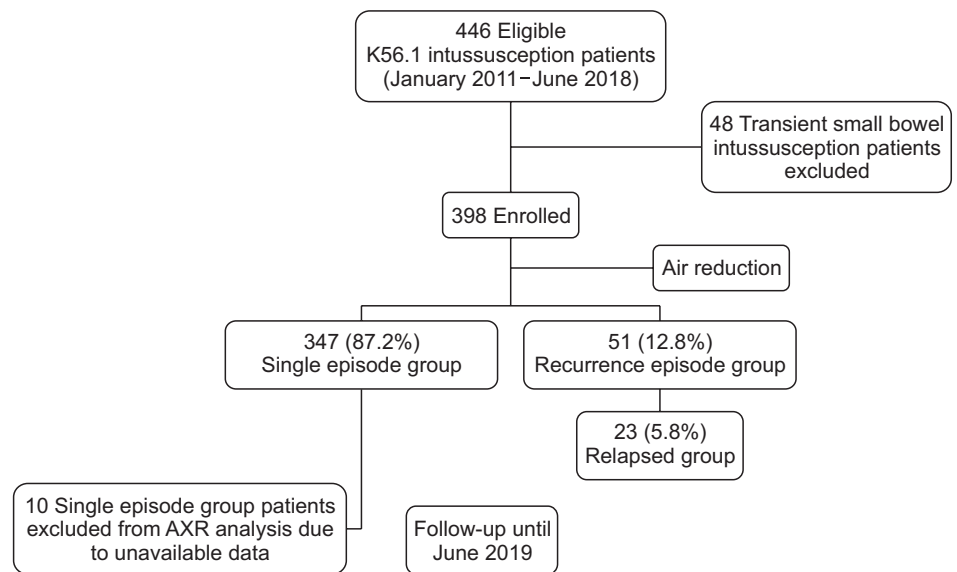


Fig. 1. Flowchart for the selection of patients. Recurrence episode group: patients who experienced recurrence after initial reduction. Relapsed group: patients who have recurred after 14 days of initial treatment. Relapsed group was included in the recurrence episode group but was excluded in recurrence analysis. AXR: abdomen radiograph.

made with USG. Abdominal computed tomography (CT) was additionally performed in seven cases when further evaluation was needed. Since there were no contraindications, air reduction was performed as initial treatment for all 398 cases. Informed consent was obtained from child's parents or guardians. Peripheral IV access was inserted before performing procedures. Dehydration was corrected if there were signs of volume deficit. Delayed treatment may lead to surgical emergency, and in case of possible complications or surgical reductions, a pediatric surgeon backup was available. For air reduction, a rectal tube was inserted and tight sealing was made to prevent leakage. Under fluoroscopy, a radiologist inflated balloon within the rectal ampulla. It was insufflated to a pressure of 60–100 mmHg to reduce intussusception [2,9,10].

Plain abdomen radiograph analysis

A pediatric radiologist reviewed 388 plain AXRs taken prior to USG imaging with masked information about patients' data and original AXR readings. If several AXR data were available, the initial AXR taken before first air reduction was used for data analysis. The radiologist evaluated AXR according to the following six factors: absent ascending colon gas, absent transverse colon gas, mass, small bowel obstruction, target sign, and meniscus sign. Authors of this study added the sum of patient's AXR's factors and determined whether patients had at least one of six AXR factors or not. We then compared the data of the two groups to analyze associations of initial AXR with recurrence.

Statistical analysis

Statistical analyses were performed using χ^2 test and Student's *t*-test to compare single episode and recurrence groups. In logistic regression analysis, a multivariate analysis was performed on a model including age and sex by selecting variables with *p*-value less than 0.05 through univariate analysis. IBM SPSS Statistics for Windows, Version 21.0 (IBM Co., Armonk, NY, USA) was used for all statistical analyses. Statistical significance was considered when *p*-value was less than 0.05.

Ethics

This study was approved by the Institutional Review Board of Korea University Ansan Hospital (No. K2018-1528).

RESULTS

Clinical characteristics of intussusception cases

Out of 446 patients with ICD-10 classification code of K56.1, 48 patients who were diagnosed with transient small bowel intussusception on USG were excluded. A total of 398 patients received air reduction and five of them received surgery. A total of 347 patients (87.2%) were classified into single episode group, where as 51 patients (12.8%) were classified as recurrence episode group. Of 398 patients, 5.8% (n=23) was subcategorized into the relapsed group (**Fig. 1**).

Mean age of eligible patients was 22.9±10.2 months, and 220 (55.3%) were males. The number of ileocecal type intussusception was 391 (98.2%). Abdominal pain and/or irritability and bloody stool were the most common symptoms (85.2% and 42.2% respectively). On physical examinations, 27.6% showed abdominal tenderness and 1.3% had palpable abdominal mass. On laboratory analyses, neither definite leukocytosis nor inflammatory marker elevation was seen. When analyzing AXR factors, absent ascending colon gas was the most common one (63.9%) in intussusception cases, followed by mass (29.1%), absent transverse colon gas (28.1%), and meniscus (20.9%). Small bowel obstruction (10.8%) and target sign (6.2%) were the least common AXR factors found in this study (**Table 1**).

Comparison between single episode and recurrence groups

The mean age of patients was 23.5±18.2 months for the single episode group and 18.8±15.6 months ($p=0.180$) for the recurrence group. Both groups showed a male predominance. The mean time to recurrence from air reduction was 3.4±3.2 days. There were no statistically significant differences in symptoms (abdominal pain and/or irritability, bloody stool, vomiting, diarrhea, fever, lethargy) between the two groups. There were no significant differences in physical examination or laboratory analysis (WBC count, ESR, CRP, tCO₂ levels) results between the two groups either. However, significant differences were found in absence of ascending colon gas ($p=0.010$), absence of transverse colon gas ($p=0.003$), target sign ($p=0.006$), sum of factors ($p=0.001$), and at least one positive finding of factors ($p=0.003$); these AXR findings were observed more commonly in the recurrence group (**Table 2**).

Analysis of abdomen radiograph factors in recurrent intussusceptions

On univariate analysis, absence of ascending colon gas (odds ratio [OR], 3.816; 95% confidence interval [CI], 1.295–11.246; $p=0.015$), absence of transverse colon gas (OR, 3.368; 95% CI, 1.541–7.361; $p=0.002$), target sign (OR, 4.092; 95% CI, 1.385–12.088; $p=0.011$), and meniscus sign (OR, 2.514; 95% CI, 1.106–5.714; $p=0.028$) were most closely associated AXR factors in recurrence after reduction. After adjusting for age and sex, multivariate analysis showed that absence of transverse colon gas was the most closely associated AXR factor for recurrence (OR, 2.964; 95% CI, 1.327–6.618; $p=0.008$) (**Table 3**).

Patients who received surgical reduction

Five patients received surgical reduction due to non-operative reduction failures or for diagnostic purposes (**Table 4**). Two patients were 4-month old infants. Both of them visited

Table 1. Baseline characteristics of intussusception patients

Variable	Total patients (n=398)
Sex (male)	220 (55.3)
Mean age (mo)	22.9±10.2
Types of intussusception on USG	
Ileocecal type	391 (98.2)
Small bowel	4 (1.8)
Symptoms	
Abdominal pain and/or irritability	245 (85.2)
Bloody stool	168 (42.2)
Vomiting	135 (33.9)
Diarrhea	132 (33.2)
Fever at diagnosis	73 (18.3)
Fever after reduction	8 (2.0)
Lethargy	68 (17.1)
Signs	
Abdominal distension	46 (11.6)
Abdominal tenderness	110 (27.6)
Abdominal mass	5 (1.3)
Laboratory findings at diagnosis	
WBC (count/ μ L)	11,130 (8,092–14,102)
ESR (mm/hr)	12.0 (5.0–25.0)
CRP (mg/dL)	0.39 (0.04–1.29)
tCO ₂ (mmol/L)	19.6 (17.8–21.0)
Abdominal X-ray findings	
Absent ascending colon gas	248 (63.9)
Absent transverse colon gas	109 (28.1)
Mass	113 (29.1)
Small bowel obstruction	42 (10.8)
Target sign	24 (6.2)
Meniscus	81 (20.9)

Values are presented as number (%), mean±standard deviation, or median (interquartile range).

USG: ultrasonography, WBC: white blood cell, ESR: erythrocyte sedimentation rate, CRP: C-reactive protein, tCO₂: total CO₂. Reference range: WBC (count/ μ L): 4.5–13.5×10³, ESR (mm/hr): 0–9, CRP (mg/dL): 0–0.5, tCO₂ (mmol/L): 23–29.

the hospital for common symptoms of intussusception (vomiting, abdominal pain and/or irritability, and bloody stool). One of them underwent subtotal colectomy and another received surgical ileocecal reduction. The duration between symptom onset and treatment was less than 24 hours for both. They both had severe swelling and necrotic change of intestines. They also experienced recurrence multiple times (patients 4 and 5). The resection specimens obtained by surgical removal and endoscopic polypectomy were lymphoid hyperplasia and jejunal polyps, respectively. One 59-month child who presented with isolated abdominal complaints was diagnosed with secondary intussusception due to Meckel's diverticulum on surgical pathology.

DISCUSSION

In this study, patient's symptoms, signs and physical examinations did not show significant differences between single episode and recurrence groups. Despite a small sample size, Champoux et al. [11] have reported presenting features or symptoms cannot predict recurrent intussusception. Similarly, our study showed that factors regarding symptoms, signs, and laboratory findings had no significant associations with recurrent intussusception. Single episode and recurrence groups did not show significant differences regarding these symptoms, signs, or laboratory findings. At our institution, 69.8% (n=278) of patients

Suspecting Intussusception and Recurrence Risk Stratification

Table 2. Comparison of single episode and recurrence groups

Variable	Single episode group (n=347)	Recurrence group (n=28)	p-value
Sex (male)	191 (55.0)	16 (57.1)	0.213
Mean age (mo)	23.5±18.2	18.8±15.6	0.180
Recurrence time (d)	-	3.4±3.2	
Remote relapse	-	8 (28.6)	
Types of intussusception on USG			<0.001
Ileocecal	346 (99.7)	25 (89.3)	
Small bowel	1 (0.3)	3 (10.7)	
Laboratory findings at diagnosis			
WBC (count/ μ L)	11,140 (8,072.5–14,087.5)	11,130 (8,570–13,450)	0.775
ESR (mm/hr)	12.1 (5.0–25.0)	8.0 (3.0–17.0)	0.084
CRP (mg/dL)	0.421 (0.092–1.41)	0.29 (0.07–0.667)	0.083
tCO ₂ (mmol/L)	19.5 (17.8–21.0)	19.7 (18.5–21.6)	0.361
Surgical treatment	3 (0.86)	2 (7.1)	
Abdominal X-ray findings			
Absent ascending colon gas	206 (59.4)	24 (85.7)	0.010
Absent transverse colon gas	86 (24.8)	15 (53.6)	0.003
Mass	89 (25.6)	12 (42.9)	0.062
Small bowel obstruction	35 (10.1)	3 (10.7)	0.956
Target sign	17 (4.9)	5 (18.9)	0.006
Meniscus sign	61 (17.6)	10 (35.7)	0.024
Sum of above six factors [†]	1.5±1.4	2.5±1.6	0.001
At least one positive finding of above factors [†]	222 (64.0)	26 (92.9)	0.003

Values are presented as number (%), mean±standard deviation, or median (interquartile range).

USG: ultrasonography, WBC: white blood cell, ESR: erythrocyte sedimentation rate, CRP: C-reactive protein, tCO₂: total CO₂.

*Each AXR finding was given a score of one and the sum was added. †Whether a patient has at least one of six abdomen radiograph factors was evaluated.

Table 3. Association between AXR finding and recurrence after initial reduction

Variable	Univariate			Multivariate		
	OR	95% CI	p-value	OR	95% CI	p-value
Sex (female)	0.613	0.281–1.333	0.217	0.612	0.290–1.507	0.325
Age (mo)	0.981	0.954–1.009	0.179	0.986	0.956–1.016	0.344
Absent ascending colon gas	3.816	1.295–11.246	0.015	2.004	0.584–6.982	0.269
Absent transverse colon gas	3.368	1.541–7.361	0.002	2.964	1.327–6.618	0.008
Mass	2.090	0.952–4.590	0.066			
Small bowel obstruction	1.035	0.297–30.606	0.956			
Target sign	4.092	1.385–12.088	0.011	2.932	0.951–9.036	0.061
Meniscus	2.514	1.106–5.714	0.028	1.751	0.388–7.899	0.466

Values are presented as median or number (%)

AXR: abdomen radiograph, OR: odds ratio, CI: confidence interval.

Table 4. Patients who received surgical reduction

Patient	Sex	Age (months of age)	Endoscopic and surgical treatment	Organic disease as lead points
1	Male	4	Subtotal colectomy	None
2	Male	59	Diverticulectomy and small bowel resection	Meckel's diverticulum
3	Female	4	Ileocecal resection	None
4	Female	19	Small bowel resection	Lymphoid hyperplasia
5	Female	23	Endoscopic polypectomy	Jejunal polyps

received therapeutic reduction within 48 hours from onset time. Patients from both groups might have shared similar progress before the treatment. Kim et al. [12] have retrospectively reviewed 479 children with intussusception who have visited a pediatric emergency department of a tertiary-care, university-affiliated hospital. Because their study defined recurrence within 48 hours of initial reduction, their patient groups shared similar progress to our study population. Similar to our study, Kim et al. [12] have reported that patients in recurrence and no recurrence groups have similar WBC counts and CRP levels.

However, AXR factors showed significant difference between single episode and recurrence groups; absent ascending colon gas, absent transverse colon gas, and target sign were more common in the recurrence group. Among the AXR factors, absent transverse colon gas from time of diagnosis was the most significantly associated AXR factor with recurrence after non-surgical reduction.

There is no disagreement that USG is the most useful method for diagnosing intussusception. In order to properly use AXR as a complementary tool rather than as a substitute for diagnosis or classification of recurrence risk groups, we need more information on radiographic characteristics of intussusception.

Abnormal gas pattern on AXR can help clinicians suspect certain pathology, and further imaging studies such as USG or CT can be used. Normally, gas is frequently seen throughout the whole gastrointestinal tract. Air is visible in the stomach with air fluid levels, but air in small bowel is less common and typically in less quantity. The large bowel, on the other hand, contains more gas than the small bowel, and it shows more variation in its distribution on AXR [13-15].

In our study, absence of ascending colon gas (63.9%) was the most frequently seen AXR factor in intussusception patients, followed by mass (29.1%), absence of transverse colon gas (28.1%), and meniscus (20.9%) (**Table 1**). Small bowel obstruction (10.8%) and target sign (6.2%) were the least common ones.

As intussusception occurs, intestinal edema aggravates over time, impairing gas movement from small intestine to large intestine, gradually resulting in absence of gas below intussusceptum. Absence of transverse colon gas was most significantly associated with recurrence of intussusception than the loss of gas in the ascending colon. We have assumed that prolonged time of intussusception could have resulted in gasless transverse colon, distal to intussusceptum, explaining the significant association of absence of transverse colon gas and recurrence. Progression of intussusception as it recurred may have worsened the paucity of gas in transverse colon. However, the association of absence of transverse colon gas on ileocolic intussusception with prolonged duration or longer segment of intussusception could not be confirmed in this study.

Recurrence rate of intussusception ranges from 5 to 11%. Recurrence rate as high as 21% following non-operative reductions has been reported. However, recurrence rates have been reported to be less than 4% following surgery [5,16].

Time interval before each recurrence varied greatly. We defined to subcategorize the recurrence groups by 14 days, considering that the most common cause of intussusception is swelling of lymph nodes around ileocecal valve, and the period until recovery of mesenteric lymphadenitis is usually about 2 weeks [17].

Pathologic lead points such as Meckel's diverticulum, juvenile polyps, and duplication cysts [3,16,18,19] may cause relapse of intussusception. Viral infections may also result in swollen Peyer patches, causing a separate episode of intussusception [20]. Severe inflammation of initial bowel edema may result in immediate recurrence. Incomplete reduction can also result in recurrence of intussusception. Once intussusception is diagnosed, a radiologist should perform pneumatic or saline reduction under guidance of fluoroscopy or USG if

there are no contraindications. At our institution, fluoroscopy-guided air reduction is routinely performed as a reduction method. Xie et al. [9] have reported that the success rate of USG-guided hydrostatic reduction is significantly higher than that of pneumatic reduction (96.77% vs. 83.87%) due to its consistent intra-colonic pressure when reducing intussusception. Others have reported that the success rate for USG-guided air reduction is 92–95% while that of USG-guided saline reduction is 70–90%, with air being a slightly more effective agent than fluid regardless of monitoring method [5]. USG-guided reduction does not result in pseudoreduction [21]. A radiologist can use real-time USG monitoring to reduce intussusceptum and inject normal saline or pressure until reduction of intussusceptum is verified on USG. Additionally, since USG-guided reduction method does not use radiation, repeated attempts can be tried with less concern to prevent incomplete reduction of intussusception at first trial [5]. Therefore, the choice of reduction method (fluoroscopy-guided air reduction) at our institution might have resulted in unsuccessful reductions, possibly resulting in recurrence.

Recently, Kim et al. [22] have evaluated diagnostic performances of artificial intelligence (AI) and a deep learning-based algorithm for detecting ileocolic intussusception using AXR. Our study was meaningful as a pilot study for developing AI deep learning algorithm, since it determined AXR's associations with recurrent intussusceptions after therapeutic reduction.

For diagnosing intussusception, high degree of clinical suspicion through initial clinical data and appropriate radiologic examination are needed. A definite diagnosis can be made by USG and CT. Contrast enema is both diagnostic and therapeutic. However, such invasive studies are not used as the first choice of diagnostic methods. Due to high sensitivity and specificity, USG has emerged as the initial imaging modality for diagnosis. Although the sensitivity and specificity of AXR can be improved by careful choice of view, it still does not reach anywhere near the same levels of accuracy as an USG examination [23].

Two studies have shown that 23–24% of patients with proven intussusception have completely normal AXR [24,25]. Clinicians should not rely on AXR to make or exclude diagnosis of intussusception or to predict recurrence. Although the limitations of diagnosing intussusception with AXR alone are clear, the possibility of its complementary use in the diagnosis process and predicting the risk of recurrence was found through our study.

This study has several limitations. It was limited to a single center with a relatively small sample size. In addition, it was a retrospective study, making it impossible to analyze long-term relapsed cases of intussusception.

In conclusion, our study showed that absence of ascending colon gas (63.9%) was the most frequently seen AXR finding in intussusception patients. Such finding on AXR in intussusception patients could be a clue for recurrent intussusception. Further studies with a large number of data are needed to predict intussusception's location on AXR. Although USG is the gold standard in diagnosis of intussusception, AXR certainly can be used as a complementary tool for diagnosis and recurrence monitoring.

REFERENCES

1. Huppertz HI, Soriano-Gabarró M, Grimpel E, Franco E, Mezner Z, Desselberger U, et al. Intussusception among young children in Europe. *Pediatr Infect Dis J* 2006;25(1 Suppl):S22-9.
[PUBMED](#) | [CROSSREF](#)
2. Waseem M, Rosenberg HK. Intussusception. *Pediatr Emerg Care* 2008;24:793-800.
[PUBMED](#) | [CROSSREF](#)
3. Ntoulia A, Tharakan SJ, Reid JR, Mahboubi S. Failed intussusception reduction in children: correlation between radiologic, surgical, and pathologic findings. *AJR Am J Roentgenol* 2016;207:424-33.
[PUBMED](#) | [CROSSREF](#)
4. Mandeville K, Chien M, Willyerd FA, Mandell G, Hostetler MA, Bulloch B. Intussusception: clinical presentations and imaging characteristics. *Pediatr Emerg Care* 2012;28:842-4.
[PUBMED](#) | [CROSSREF](#)
5. Magnuson DK. Intussusception in infants and children. In: Wyllie R, Hyams JS, Kay M, eds. *Pediatric gastrointestinal and liver disease*. 3rd ed. Philadelphia: Elsevier, 2006:711-21.
6. Edwards EA, Pigg N, Courtier J, Zapala MA, MacKenzie JD, Phelps AS. Intussusception: past, present and future. *Pediatr Radiol* 2017;47:1101-8.
[PUBMED](#) | [CROSSREF](#)
7. Ramsey KW, Halm BM. Diagnosis of intussusception using bedside ultrasound by a pediatric resident in the emergency department. *Hawaii J Med Public Health* 2014;73:58-60.
[PUBMED](#)
8. Hryhorczuk AL, Strouse PJ. Validation of US as a first-line diagnostic test for assessment of pediatric ileocolic intussusception. *Pediatr Radiol* 2009;39:1075-9.
[PUBMED](#) | [CROSSREF](#)
9. Xie X, Wu Y, Wang Q, Zhao Y, Chen G, Xiang B. A randomized trial of pneumatic reduction versus hydrostatic reduction for intussusception in pediatric patients. *J Pediatr Surg* 2018;53:1464-8.
[PUBMED](#) | [CROSSREF](#)
10. Beres AL, Baird R. An institutional analysis and systematic review with meta-analysis of pneumatic versus hydrostatic reduction for pediatric intussusception. *Surgery* 2013;154:328-34.
[PUBMED](#) | [CROSSREF](#)
11. Champoux AN, Del Beccaro MA, Nazar-Stewart V. Recurrent intussusception. Risks and features. *Arch Pediatr Adolesc Med* 1994;148:474-8.
[PUBMED](#) | [CROSSREF](#)
12. Kim JH, Lee JS, Ryu JM, Lim KS, Kim WY. Risk factors for recurrent intussusception after fluoroscopy-guided air enema. *Pediatr Emerg Care* 2018;34:484-7.
[PUBMED](#) | [CROSSREF](#)
13. Stoker J, van Randen A, Laméris W, Boermeester MA. Imaging patients with acute abdominal pain. *Radiology* 2009;253:31-46.
[PUBMED](#) | [CROSSREF](#)
14. Musson RE, Bickle I, Vijay RK. Gas patterns on plain abdominal radiographs: a pictorial review. *Postgrad Med J* 2011;87:274-87.
[PUBMED](#) | [CROSSREF](#)
15. Menashe SJ, Iyer RS, Parisi MT, Otto RK, Weinberger E, Stanescu AL. Pediatric abdominal radiographs: common and less common errors. *AJR Am J Roentgenol* 2017;209:417-29.
[PUBMED](#) | [CROSSREF](#)
16. Guo WL, Hu ZC, Tan YL, Sheng M, Wang J. Risk factors for recurrent intussusception in children: a retrospective cohort study. *BMJ Open* 2017;7:e018604.
[PUBMED](#) | [CROSSREF](#)
17. Helbling R, Conficconi E, Wyttenbach M, Benetti C, Simonetti GD, Bianchetti MG, et al. Acute nonspecific mesenteric lymphadenitis: more than "No Need for Surgery". *Biomed Res Int* 2017;2017:9784565.
[PUBMED](#) | [CROSSREF](#)
18. Navarro O, Daneman A. Intussusception. Part 3: diagnosis and management of those with an identifiable or predisposing cause and those that reduce spontaneously. *Pediatr Radiol* 2004;34:305-12; quiz 369.
[PUBMED](#) | [CROSSREF](#)
19. Blakelock RT, Beasley SW. The clinical implications of non-idiopathic intussusception. *Pediatr Surg Int* 1998;14:163-7.
[PUBMED](#) | [CROSSREF](#)

20. Lin SL, Kong MS, Houg DS. Decreasing early recurrence rate of acute intussusception by the use of dexamethasone. *Eur J Pediatr* 2000;159:551-2.
[PUBMED](#) | [CROSSREF](#)
21. Palder SB, Ein SH, Stringer DA, Alton D. Intussusception: barium or air? *J Pediatr Surg* 1991;26:271-4; discussion 274-5.
[PUBMED](#) | [CROSSREF](#)
22. Kim S, Yoon H, Lee MJ, Kim MJ, Han K, Yoon JK, et al. Performance of deep learning-based algorithm for detection of ileocolic intussusception on abdominal radiographs of young children. *Sci Rep* 2019;9:19420.
[PUBMED](#) | [CROSSREF](#)
23. Robson N, Beasley S. Role of plain abdominal radiography in the initial investigation of suspected intussusception. *J Paediatr Child Health* 2014;50:251-2.
[PUBMED](#) | [CROSSREF](#)
24. Hernandez JA, Swischuk LE, Angel CA. Validity of plain films in intussusception. *Emerg Radiol* 2004;10:323-6.
[PUBMED](#) | [CROSSREF](#)
25. Kodikara H, Lynch A, Morreau P, Vogel S. Ten-year review of intussusception at Starship Hospital: 1998-2007. *N Z Med J* 2010;123:32-40.
[PUBMED](#)