



Comparative efficiency of the preoperative pterygomandibular space injection of two doses of dexamethasone in mandibular third molar surgery

Pavita Wanithanon¹, Teeranut Chaiyasamut¹, Kadkao Vongsavan², Bishwa Prakash Bhattarai², Verasak Pairuchvej¹, Sirichai Kiattavorncharoen¹, Natthamet Wongsirichat²

¹Department of Oral and Maxillofacial Surgery, Faculty of Dentistry, Mahidol University, Bangkok, Thailand

²Walailak University International College of Dentistry, Bangkok, Thailand

Background: Impacted mandibular third molar removal is one of the most commonly performed oral surgical procedures. This procedure can lead to several postoperative complications, such as trismus, facial swelling, and pain, which occur as a result of the inflammatory responses to surgery. This study compared the efficiency of preoperative injections of 4 mg versus 8 mg dexamethasone into the pterygomandibular space to reduce postoperative sequelae.

Methods: This was a randomized, prospective, split-mouth, controlled study, including 52 mandibular third molar surgeries in 26 patients. Each patient was randomized to either the 4 mg or 8 mg dexamethasone injection group. Dexamethasone was injected into the pterygomandibular space after numbness from local anesthesia. Data were collected for trismus, facial swelling, visual analog scale (VAS) pain score, and the number of analgesics taken during the evaluation period. The level of significance was set at $P < 0.05$.

Results: Statistically significant differences in postoperative facial swelling ($P = 0.031$, diff = 1.4 mm) and pain ($P = 0.012$, diff = 0.020) were found between the 8 mg and 4 mg dexamethasone groups. However, there were no significant differences between the groups for trismus and the total number of analgesics consumed ($P > 0.05$).

Conclusion: Compared to the 4 mg preoperative dexamethasone injection, the 8 mg preoperative dexamethasone injection into the pterygomandibular space was more effective in reducing postoperative swelling and pain following the surgical removal of the impacted mandibular third molar. However, the difference in trismus could not be evaluated clinically. Therefore, the recommendation of administering the 4 mg dexamethasone preoperative injection is optimal in the third molar surgical procedure.

Keywords: Comparative Study; Dexamethasone; Mandible; Third molar; Pterygomandibular Space; Third molar; Visual Analog Scale.



This is an Open Access article distributed under the terms of the Creative Commons Attribution Non-Commercial License (<http://creativecommons.org/licenses/by-nc/4.0/>) which permits unrestricted non-commercial use, distribution, and reproduction in any medium, provided the original work is properly cited.



INTRODUCTION

1. Mechanism of dexamethasone

Surgical extraction of the mandibular third molar (MTM) is one of the most commonly performed oral

surgical procedures [1]. This procedure is often followed by swelling, pain, and trismus, which are elicited by the inflammatory response and may interfere with the daily activities of the patients [2,3]. Currently, the use of corticosteroids like dexamethasone with varying doses and techniques has been investigated in the surgical

Received: September 20, 2020 • Revised: December 3, 2020 • Accepted: December 22, 2020

Corresponding Author: Bishwa Prakash Bhattarai, Walailak University International College of Dentistry, 979/42-46 Phahonyothin Road 19th floor SM Tower Phaya Thai District Bangkok 10400, Thailand

Tel: +6622990935 E-mail: bishwa052@gmail.com

Copyright© 2021 Journal of Dental Anesthesia and Pain Medicine

removal of MTM and also in other maxillofacial surgeries to diminish the postoperative inflammation [4,5]. Dexamethasone is the most frequently and extensively used corticosteroid for this purpose [4,6]. It blocks the inflammatory cascade by inhibiting the enzyme phospholipase A2 with the downstream effect of decreasing the synthesis of inflammatory mediators such as prostaglandins and leukotrienes [4].

2. Corticosteroid administration

The use of corticosteroids in MTM surgery has been studied from various standpoints, such as the difference in preparations, dosing, routes, and delivery sites [7]. Corticosteroids can be administered orally (dexamethasone, methylprednisolone), intramuscularly (dexamethasone acetate), or both intramuscularly and intravenously (dexamethasone sodium phosphate, methylprednisolone acetate, and methylprednisolone sodium succinate) [8]. Regarding the reduction of postoperative inflammation after MTM surgery, submucosal, intravenous, intra-alveolar, intramuscular, and oral usages of dexamethasone have been reported [9,10]. However, very few studies have investigated the infusion of dexamethasone alone into the pterygomandibular space, the same site where the inferior alveolar nerve block (IANB) is delivered [11].

3. Inferior alveolar nerve block injection with dexamethasone administration

The IANB injection technique is routinely applied for the surgical extraction of the MTM. The IANB involves insertion of the needle into the pterygomandibular space. Therefore, many dentists have clinical experience and knowledge relating to the administration of chemical compounds into the pterygomandibular space, which makes this site and route for delivery of dexamethasone suitable [11,12]. Thus, this study aimed to evaluate the effectiveness of two different doses (4 and 8 mg) of dexamethasone injected preoperatively into the pterygomandibular space to reduce the post-surgical complications of MTM surgery.

4. Significance

Furthermore, the findings of this study could serve as the basis for accurate doses and administration techniques for the preoperative injection of dexamethasone in MTM surgery to decrease postoperative complications.

METHODS

1. Ethical approval

This clinical prospective, randomized, controlled, split-mouth study obtained ethical approval from the Human Research Ethics Committee of the Faculty of Dentistry/ Faculty of Pharmacy, Mahidol University, Institutional Review Board. (COA.No.MU-DT/PY-IRB 2019/031.2405).

2. Sample size calculation

The sample size of 30 patients was calculated based on the success rates of previous clinical studies (success rate 85.7%) [11]. Although the minimum required sample size for a 95% confidence interval (the level of significance for all statistical tests) was 26 patients, a sample size of 30 patients was enrolled to account for a possible 20% dropout rate. However, this study used only 26 patients with bilaterally symmetrical MTMs, which were surgically removed under local anesthesia (LA).

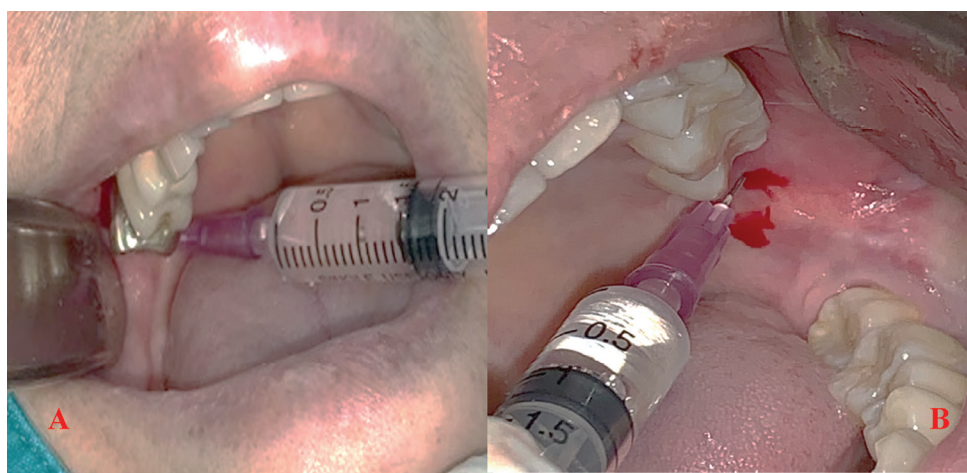
3. Eligibility criteria

The eligibility criteria for patient selection are shown in Table 1. Patients were recruited from the Oral and Maxillofacial Surgery clinic of the Faculty of Dentistry, Mahidol University, Thailand.

Eligible patients for this study were informed about the objectives and details of the study. Patients who agreed to participate signed the informed consent form. For each patient, the personal data, including name, sex, age, demographic profile, and current and previous medical and dental history were recorded.

Table 1. Eligibility criteria for patient selection

Inclusion criteria	Exclusion criteria
1. The patient is aged between 18 and 45 years.	1. Patients with systemic diseases such as hypertension, cardiovascular diseases, renal and/or liver failure, or other serious medical condition contraindicating the surgical removal of the impacted molar.
2. Symmetrically positioned impacted teeth on the panoramic radiographs of the patients.	2. Pregnant or lactating patient.
3. Healthy patients as determined by the medical history and clinical examination.	3. Patients allergic to local anesthetics.
4. Non-smoker and non-alcoholic patients.	4. Patients with facial deformities that may impede the intervention and evaluation.
5. The patient has at least a healthy lower first or second molar bilaterally (without caries or restoration)	5. Patients with swelling and/or infection around the MTMs.
6. Patients who were able to give their consent for the study.	6. Patients under medication that could affect their judgment on pain (NSAIDs, antidepressants,) within five days before surgery
7. Patients who could follow the instructions given by the investigators.	7. Inability to follow the instructions or cooperate during the study
Criteria for withdrawal	The withdrawal from the study at any time was entirely based on the patient's own decision. For this study, 1. One patient did not meet the set criteria, 2. One patient declined to provide the consent 3. Two patients were lost to follow-up.

**Fig. 1.** 4 mg and 8 mg dexamethasone injection into the pterygomandibular space A 8 mg in the right side and B 4 mg in the left side

4. Dexamethasone administration

With similar bilateral MTM, we randomly divided each side of the impaction into two equal groups by tossing to determine the code of the sequence of dexamethasone administration. Each patient was randomized to either the 4 mg or 8 mg dexamethasone injection groups (Fig. 1 A, B).

1. Group A: 4 mg of dexamethasone injection
2. Group B: 8 mg of dexamethasone injection.

Some patients received 4 mg dexamethasone on the

right side during the first appointment and 8 mg on the left side during the second appointment. However, some patients got 4 mg dexamethasone injected on 4 mg dexamethasone on the left side during the first appointment and 8 mg on the right side during the second appointment. Therefore, each patient was given two appointments for surgery with a three-to-four-week washout period. Dexamethasone was administered through the pterygomandibular space after the patient attained numbness via IANB.

5. Surgical procedure

A single surgeon performed all the operations using

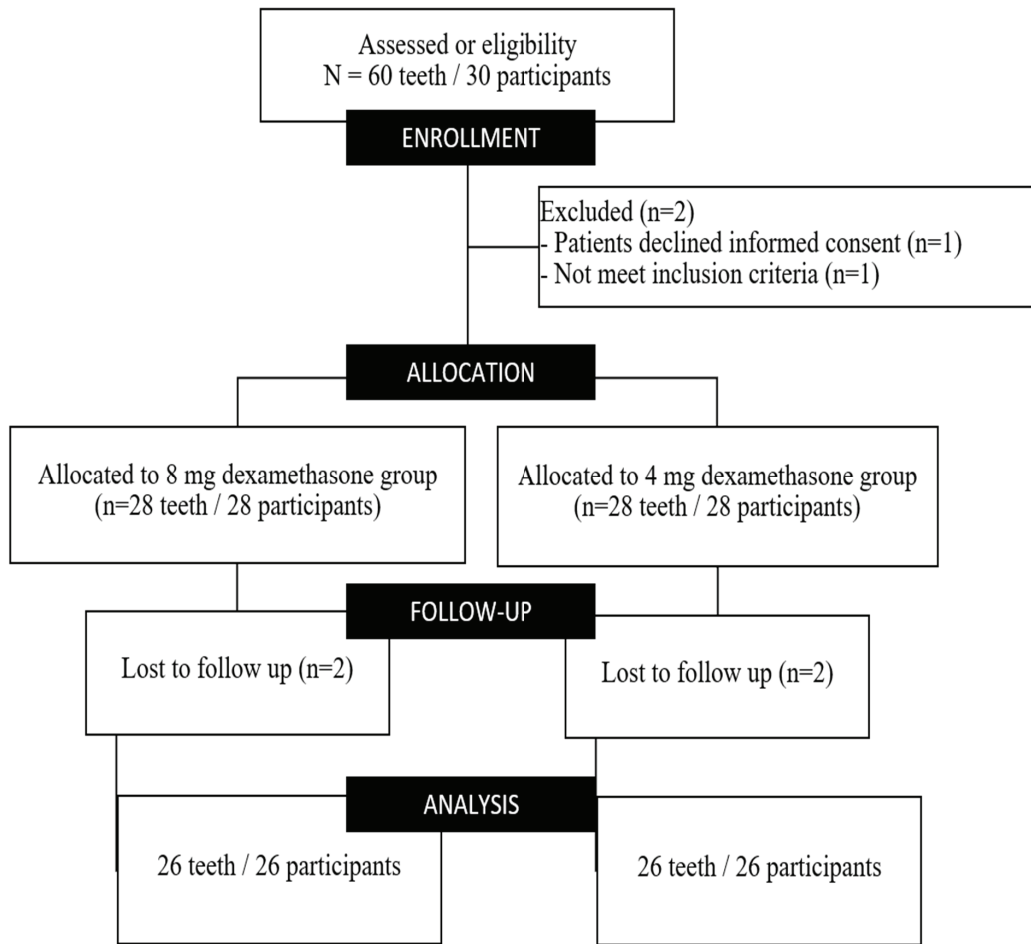


Fig. 2. The CONSORT diagram detailing patient recruitment and follow-up

the standard technique. Anesthesia was achieved using a cartridge of 1.7 ml of 4% articaine with 1:100,000 epinephrine through the IANB and 0.5 ml for the long buccal nerve block. Once the subjective sign of anesthesia was reported, dexamethasone was injected into the pterygomandibular space by another surgeon (the dose of dexamethasone in milligrams was determined by the randomly divided group).

The surgical zone was accessed by reflecting a triangular mucoperiosteal flap. The osteotomy procedure was performed with a round bur mounted on a slow-speed handpiece under uninterrupted saline irrigation. Tooth sectioning whenever required was accomplished, followed by tooth elevation by an elevator. After the complete tooth removal, the socket was toileted using saline with the total removal of follicles and damaged

tissue associated with the surgical area. After repositioning the flaps, interrupted silk sutures were used for approximation. This was followed by the application of a gauze pack in the surgical area. The details of every procedure (from the first incision to the final suture) were documented instantly after the surgery.

After the completion of each surgery, the patient received postoperative instructions. The patient was then recommended to take the analgesic tablet once their pain reached a moderate level. All patients received amoxicillin 500 mg orally every 8 h for 5 days and acetaminophen 500 mg orally in case of pain.

6. Postoperative measurements of facial swelling, trismus, and pain

Facial swelling and trismus were assessed before the

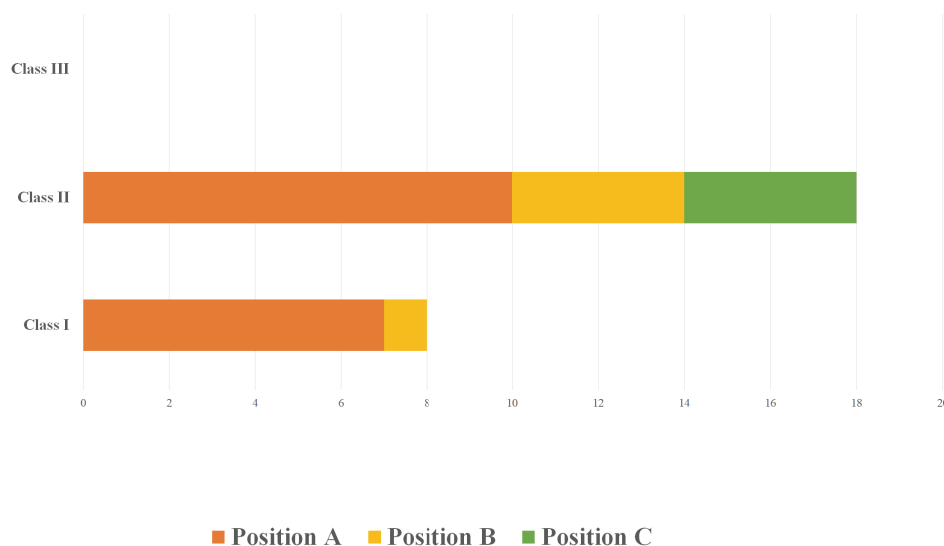


Fig. 3. Classification and Position of lower third molar impaction of the patients.

surgery (baseline) and on the 2nd and 7th postoperative day. A single thread was used to individually measure the corner of the eye angle of the mandible (A), the Tragus-Commissure of the mouth line (B), and the Tragus-Pogonion line (C) (mm) (Fig. 5). The evaluation of trismus was predictable by measuring the maximum inter-incisal distance (distance between the upper and lower incisal edge of the central incisors) using a Vernier caliper.

Post-surgical pain was assessed through the patients' recorded pain scores on a Visual Analog Scale (VAS) and the number of analgesic tablets consumed. The VAS pain score was noted on the day of surgery, and on the 1st to 3rd postoperative days.

7. Data analysis

The data were analyzed using Statistical Package for the Social Sciences (SPSS Version 18.0 for Windows, Chicago, IL, USA) with the level of significance set at $P < 0.05$.

Multivariate analysis was performed due to the split-mouth design and repeated outcome measurement with Bonferroni's adjustment for post hoc multiple comparisons. A paired t-test was used to compare the surgical time and the number of analgesic tablets taken between the use of 4 and 8 mg dexamethasone in the

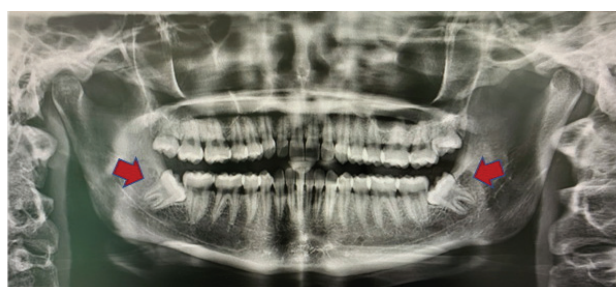

Fig. 4. Example of the bilateral mesioangular impacted third molar with Class II A

same patient.

RESULTS

1. General characteristics of the patients

Fig. 2 shows the flow diagram of the enrolment and follow-up of the patients. The study consisted of 26 patients, eight men (31%) and 18 women (69%) with a mean age of 22 years (range: 18 to 28 years).

2. Types of impacted mandibular third molars

The bilateral impacted MTMs in group A receiving 4 mg dexamethasone and group B receiving 8 mg dexamethasone were fourteen patients with horizontal angulation (54%), nine patients with mesial angulation

Table 2. Maximum inter-incisal measurements

Evaluation day	Mean ± SD (mm)		P-value
	8 mg Dexamethasone group	4 mg Dexamethasone group	
Pre-operation (baseline)	45.3 ± 5.1	45.4 ± 5.4	0.689
2 nd post-operateday	35.0 ± 9.7	34.6 ± 10.0	0.662
7 th post-operateday	42.5 ± 5.6	42.7 ± 6.8	0.828

Significant level P < 0.05

Table 3. Facial swelling measurements in three reference lines

Measurement	Mean ± SD (mm)		P-value	
	8 mg Dexamethasone group	4 mg Dexamethasone group		
Tr-Ch	Pre-operation (baseline)	111.5 ± 5.9	112.3 ± 7.1	0.136
	2 nd post-operateday	114.8 ± 5.5	115.5 ± 7.0	0.175
	7 th post-operateday	112.3 ± 5.8	112.9 ± 7.0	0.430
Tr-Pg	Pre-operation day (baseline)	136.6 ± 7.9	137.1 ± 7.9	0.267
	2 nd post-operateday	140.1 ± 7.0	141.5 ± 7.4	0.031*
	7 th post-operateday	137.6 ± 7.8	137.8 ± 7.9	0.652
Ex-Go	Pre-operation (baseline)	106.4 ± 7.3	107.8 ± 5.7	0.179
	2 nd post-operateday	108.7 ± 7.3	110.0 ± 6.3	0.162
	7 th post-operateday	107.3 ± 7.3	108.5 ± 6.1	0.168

Tr-Ch, tragus to the commissure of the mouth; Tr-Pg, tragus to the pogonion; Ex-Go, lateral canthus of the eye to the gonial angle of mandible. *Significant, P < 0.05

(35%), three patients with vertical angulation (11%), but there were no patients with distal angulation.

According to Pell and Gregory and Winter’s classification of MTM impaction of each group, ten were class IIA (39%), seven were class IA (27%), four were class IIB (15%), four were class IIC (15%), and one was class IB (4%), as illustrated in Fig. 3 and an illustration of the bilateral symmetrically positioned MTMs is shown in Fig. 4.

3. Operation times

The surgical time was recorded from the first incision to the last suture (min). The mean operation time was 22.46 ± 5.5 min for the 8 mg dexamethasone group and 22.32 ± 5.0 min for the 4 mg dexamethasone group. The operation time showed no significant difference between both groups (P = 0.789, P > 0.05). Surgical time showed similarity with that of the bilateral lower impacted third molar.

4. Adverse effects

In this study, there were no adverse events to any of

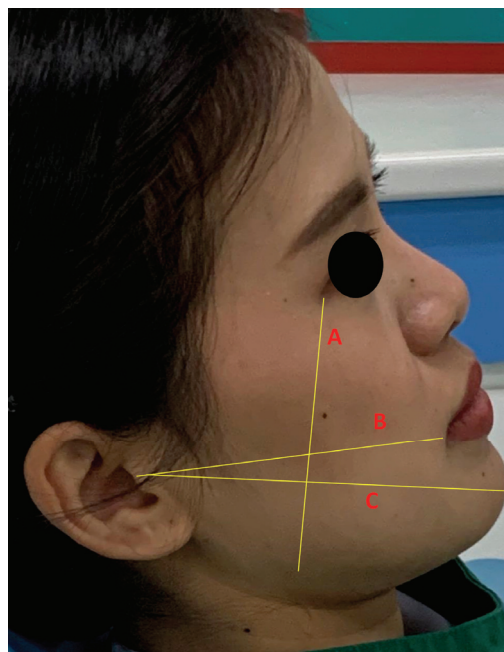


Fig. 5. Facial swelling measurement with the corner of the eye-angle of mandible (A), the tragus-commissure of mouth line (B) and the tragus-pogonion line (C) (mm)

the drugs or materials used. Postoperative infection, alveolar osteitis, and neural injuries of the inferior alveolar and lingual nerves were not observed in either

Table 4. Visual analog scale pain scores

Evaluation day	Mean \pm SD (mm)		P-value
	8 mg Dexamethasone group	4 mg Dexamethasone group	
Pre-operation (baseline)	34.6 \pm 25.4	42.7 \pm 25.4	0.186
1 st post-operateday	18.3 \pm 18.9	26.2 \pm 21.2	0.079
2 nd post-operateday	11.7 \pm 12.2	20.0 \pm 19.4	0.012*
3 rd post-operateday	6.7 \pm 10.1	13.5 \pm 14.5	0.020*

*Significant level $P < 0.05$

Table 5. Total number of analgesics taken

Study group	N	Mean \pm SD (tablets)	P-value
8 mg dexamethasone group	26	5.4 \pm 3.8	0.171
4 mg dexamethasone group	26	6.6 \pm 4.1	

groups throughout the study.

Measurements of trismus, which were examined by measuring the maximum inter-incisal distance, are shown in Table 2. However, no statistically significant difference was observed between the groups regarding the maximum mouth opening on any postoperative day ($P > 0.05$).

5. Measurement of facial swelling

Table 3 and Fig. 5 show the measurement of facial swelling in three lines (5 points of soft tissue landmarks: tragus, commissure of the mouth, pogonion, lateral canthus of the eye, and the gonial angle of the mandible). There were no significant differences in Tragus to the commissure of the mouth (Tr-Ch), Tragus to the Pogonion (Tr-Pg), and lateral canthus of the eye to the gonial angle of the mandible (Ex-Go) measurements between the groups ($P > 0.05$). Despite the overall result, on the 2nd postoperative day, a significant difference was observed on the Tragus-Pogonion line; the 4 mg dexamethasone group had significantly more swelling than the 8 mg dexamethasone group (diff = 1.4, $P = 0.031$).

6. Postoperative pain assessment

The evaluation of postoperative pain was measured in millimeters using a VAS pain score before surgery as the baseline and on the 2nd and 3rd postoperative days. The mean VAS pain scores of the 4 mg and 8 mg dexamethasone groups are shown in Table 4. Pain on the

2nd and 3rd postoperative days resulted in a significant difference between the 8 mg and 4 mg dexamethasone groups ($P = 0.012$ and, 0.020 respectively). Moreover, the 4 mg dexamethasone group had a significantly higher VAS pain score than the 8 mg dexamethasone group on the 2nd and 3rd post-surgical days (diff = 8.3, 6.8).

7. Number of analgesics

The number of analgesics taken was recorded between the operation day and the 7th postoperative day. Table 5 shows the total number of analgesics consumed in both groups. There was no significant difference between the groups ($P = 0.171$). However, the 8 mg dexamethasone group took fewer analgesics (1.2 tablets) when compared to the 4 mg dexamethasone group.

DISCUSSION

1. Symmetrical bilateral MTM impactions

The results showed no statistically significant difference in operation time between both groups ($P > 0.05$). Since the impacted MTM was symmetrically positioned on either side as confirmed by the panoramic radiographs, the MTM operations in this study had similar degrees of surgical difficulty.

2. Proper dosage of dexamethasone

Many previous studies on dexamethasone have

repeatedly proven that it lessens postoperative sequelae after MTM removal. Although dexamethasone has been regularly used, there is still no definite protocol for the proper dosage and route of administration [4,5,7,9,10].

3. Maximum mouth opening measurement

Our research showed no significant difference in the maximum inter-incisal opening between the 4 mg and 8 mg dexamethasone groups at any period ($P > 0.05$). The outcomes of the current study are analogous to those of Grossi et al. [13] and Chaudhary et al. [14], where both 4 mg and 8 mg dexamethasone administered preoperatively resulted in no significant difference in reducing trismus. In contrast to earlier findings, in 2008, Filho et al. reported that the consumption of 8 mg dexamethasone was more efficient in diminishing trismus than 4 mg dexamethasone [15].

4. Measurement of facial swelling

The evaluation of facial swelling in this study was performed as suggested by Schultze-Mosgau et al. [16] using three lines by marking five points on facial soft tissue landmarks, which is a simple and inexpensive technique. The results of the current study did not show significant differences in facial swelling in the three lines ($P > 0.05$) between the 4 mg and 8 mg dexamethasone groups. However, on the 2nd postoperative day on the Tragus-Pogonion line, an extra swelling of 1.4 mm was recorded in the 4 mg dexamethasone group. This difference in swelling when compared to the 8 mg dexamethasone group was statistically significant ($P = 0.031$). However, in the clinical setting, all cases displayed no difference in swelling under direct observation, and there were no complaints from the patients. Our finding is in agreement with the results of the study by Filho et al., in which similar doses of dexamethasone consumed orally before surgery were compared. They showed that 8 mg oral dexamethasone was more efficient in reducing facial swelling compared with 4 mg dexamethasone [15]. Conversely, some previous studies showed that 8 mg dexamethasone was

not significantly different from 4 mg dexamethasone in reducing postoperative facial swelling [13,14,16].

5. Pain measurement

Postoperative pain after MTM surgery is an expected complication. In this study, the VAS pain score and the total analgesic consumption were recorded to assess postoperative pain. The assessments made on the specified postoperative days showed a lower mean VAS pain score in the 8 mg dexamethasone group when compared to that of the 4 mg dexamethasone group. According to Jensen et al., the VAS score can be interpreted as pain intensity into 4 categories: 0–4 mm as no pain, 5–44 mm as mild pain, 45–74 mm as moderate pain, and 75–100 mm as severe pain [17,18]. The VAS pain score in both groups can be categorized as mild pain in this study. The significant difference found between the 2nd and 3rd postoperative days may not be clinically significant since it was in the same pain intensity category.

6. Analgesics taken by the patients

The total number of analgesics taken was recorded from the operation day until the 7th postoperative day. No statistical difference was noted between the 4 mg and 8 mg dexamethasone groups throughout the evaluation period. The difference in total analgesic consumption was higher in the 4 mg dexamethasone group than in the 8 mg dexamethasone group by 1.2 tablets. From both pain measurement results, the 8 mg dexamethasone injected through the pterygomandibular space was significantly more effective in reducing postoperative pain when compared with 4 mg dexamethasone. Our findings contradict those of previous studies, which found no significant differences between 4 mg and 8 mg dexamethasone in controlling postoperative pain.

7. Route of dexamethasone administration

A previous study by Latt et al. [11] suggested the pterygomandibular space as a route for the administration of dexamethasone. The pterygomandibular space offers

several advantages when chosen as the route of dexamethasone administration. Since IANB administration is commonly used in oral surgery by dentists, access to the pterygomandibular space is practical. Furthermore, the injection of dexamethasone is a pain-free procedure since the area is already anesthetized. Additionally, the pterygomandibular space has numerous blood supplies and loose areolar tissue that maximizes drug absorption [11,12].

Research has also shown that 4% dexamethasone is also an effective dose. A lower dose is also important to avoid adverse drug effects or drug side effects. In our opinion, the significant difference between facial swelling and VAS pain score in clinical research is based on statistical analysis, but the clinical consequences might not show the difference between both groups. Even if facial swelling was 1.4 mm alteration and the VAS pain score showed a difference in “mild pain” might be difficult to notice.

8. A limitation of this study

There are many limitations that may affect the results of the study. For example, the sample size calculation with few participants and the dose of the drug with a minor range used in the study (4 mg and 8 mg). The results of the current study are not significantly different from those of previous studies. Further controlled clinical studies on this topic are recommended as well as the measurement of the factors with the same duration. Moreover, an undeviating period for pain assessment and medication use is suggested to have a reliable base for comparison.

9. Conclusion

The current study showed that the preoperative 8 mg dexamethasone injection into the pterygomandibular space to reduce swelling and pain has a slightly higher effectiveness than the 4 mg dexamethasone injection. However, the effects on trismus and analgesic consumption were similar. Thus, we suggest that 8 mg dexamethasone is the ideal dosage for MTM operations.

The preoperative 4 mg dexamethasone injection into the pterygomandibular space was sufficient to reduce the postoperative complications of MTM surgery, with no greater effectiveness than the preoperative 8 mg dexamethasone injection.

AUTHOR ORCIDs

Pavita Wanithanont: <https://orcid.org/0000-0002-7990-2351>
Teeranut Chaiyasamut: <https://orcid.org/0000-0003-0487-5333>
Kadkao Vongsavan: <https://orcid.org/0000-0002-0537-2896>
Bishwa Prakash Bhattarai: <https://orcid.org/0000-0003-3359-9032>
Verasak Pairuchvej: <https://orcid.org/0000-0002-9566-2407>
 Sirichai Kiattavorncharoen: <https://orcid.org/0000-0001-6766-9188>
Natthamet Wongsirichat: <https://orcid.org/0000-0003-3005-2680>

AUTHOR CONTRIBUTIONS

Pavita Wanithanont: Conceptualization, Data curation, Formal analysis, Methodology, Writing - original draft
Teeranut Chaiyasamut: Conceptualization, Project administration, Software, Supervision, Visualization
Kadkao Vongsavan: Conceptualization, Supervision, Visualization
Bishwa Prakash Bhattarai: Resources, Software, Supervision, Writing - review & editing
Verasak Pairuchvej: Visualization, Writing - review & editing
Sirichai Kiattavorncharoen: Project administration, Supervision, Visualization
Natthamet Wongsirichat: Supervision, Writing - review & editing

ACKNOWLEDGMENTS: The authors would like to thank the staff, colleagues, and dental assistants, including co-workers in the Department of Oral and Maxillofacial Surgery, Faculty of Dentistry, Mahidol University, and Walailak University International College of Dentistry. Finally, the authors would like to thank Christian Estacio from Walailak University International College of Dentistry for editing and revising the language of this manuscript.

FUNDING AND SPONSORSHIP: This research received no sponsorship or external funding.

CONFLICTS OF INTEREST: The authors declare no conflicts of interest.

ETHICAL APPROVAL: This study was approved by the Faculty of dentistry/Faculty of Pharmacy, Mahidol

University, Institutional Review Board (MU-DT/PY-IRB) with study approval number “COA.No.MU-DT/PY-IRB 2019/031.2405.”

DECLARATION OF PATIENT CONSENT: The authors certify that they have obtained all appropriate patient consent forms. In the form, the patient(s) has/have given his/her/their consent for his/her/their images and other clinical information to be reported in the journal. The patients understand that their names and initials will not be published, and due efforts will be made to conceal their identity, but anonymity cannot be guaranteed.

CLINICAL TRIAL REGISTER: Not required in our faculty because the clinical research is monitored by the Committee in the Ethics of Research in Human Being of Dentistry and Pharmacy Mahidol University Institutional Review Board.

REFERENCES

1. Susarla SM, Blaeser BF, Magalnick D. Third molar surgery and associated complications. *Oral Maxillofac Surg Clin North Am* 2003; 15: 177-86.
2. Shepherd JP, Brickley M. Surgical removal of third molars. *BMJ* 1994; 309: 620-1.
3. Moraschini V, Hidalgo R, Porto Barboza Ed. Effect of submucosal injection of dexamethasone after third molar surgery: a meta-analysis of randomized controlled trials. *Int J Oral Maxillofac Surg* 2016; 45: 232-40.
4. Krishnan K, Kumar MPS. Role of corticosteroids in oral and maxillofacial surgery. *J Pharma Sci and Res* 2018; 10: 208-10.
5. Chegini S, Dhariwal DK. Review of evidence for the use of steroids in orthognathic surgery. *Br J Oral Maxillofac Surg* 2012; 50: 97-101.
6. Sanghavi J, Aditya A. Applications of corticosteroids in dentistry. *J Dent Allied Sci* 2015; 4: 19-24.
7. Ngeow WC, Lim D. Do corticosteroids still have a role in the management of third molar surgery. *Adv Ther* 2016; 33: 1105-39.
8. Alexander RE, Thronson RR. A review of perioperative corticosteroid use in dentoalveolar surgery. *Oral Surg Oral Med Oral Pathol Oral Radiol Endod* 2000; 90: 406-15.
9. Klongnoi B, Kaewpradub P, Boonsiriseth K, Wongsirichat N. Effect of single-dose preoperative intramuscular dexamethasone injection on lower impacted third molar surgery. *Int J Oral Maxillofac Surg* 2012; 41: 376-9.
10. Boonsiriseth K, Klongnoi B, Sirintawat N, Saengsinavin C, Wongsirichat N. Comparative study of the effect of dexamethasone injection and consumption in lower third molar surgery. *Int J Oral Maxillofac Surg* 2012; 41: 244-7.
11. Latt MM, Kiattavorncharoen S, Boonsiriseth K, Pairuchvej V, Wongsirichat N. The efficacy of dexamethasone injection on postoperative pain in lower third molar surgery. *J Dent Anesth Pain Med* 2016; 16: 95-102.
12. Khoury JN, Mihailidis S, Ghabriel M, Townsend G. Applied anatomy of the pterygomandibular space: improving the success of inferior alveolar nerve blocks. *Aust Dent J* 2011; 56: 112-21.
13. Grossi GB, Maiorana C, Garramone RA, Borgonovo A, Beretta M, Farronato D, et al. Effect of submucosal injection of dexamethasone on postoperative discomfort after third molar surgery: a prospective study. *J Oral Maxillofac Surg* 2007; 65: 2218-26.
14. Chaudary PD, Rastogi S, Gupta P, Niranjanaprasad Indra B, Thomas R, Choudhury R. Pre-emptive effect of dexamethasone injection and consumption on post-operative swelling, pain, and trismus after third molar surgery. A prospective, double-blind, and randomized study. *J Oral Biol Craniofac Res* 2015; 5: 21-7.
15. Laureano Filho JR, Maurette PE, Allais M, Cotinho M, Fernandes C. Clinical comparative study of the effectiveness of two dosages of dexamethasone to control postoperative swelling, trismus, and pain after the surgical extraction of mandibular impacted third molars. *Med Oral Patol Oral Cir Buccal* 2008; 13: E129-32.
16. Schultze-Mosgau S, Schmelzeisen R, Frolich JC, Schmele H. Use of ibuprofen and methylprednisolone for the prevention of pain and swelling after removal of impacted third molars. *J Oral Maxillofac Surg* 1995; 53: 2-7.
17. Vicentini CB, Ramacciato JC, Groppo FC, Teixeira RG, Motta RHL. Clinical evaluation of two dexamethasone

regimens in the extractions of impacted third molar-a randomized clinical trial. *Oral Maxillofac Surg* 2018; 22: 177-83.

18. Jensen MP, Chen C, Brugger AM. Interpretation of visual analog scale ratings and change scores: a reanalysis of two clinical trials of postoperative pain. *J Pain* 2003; 4: 407-14.