



Original Article

## Acupotomy for Scapulohumeral Periarthritis

Chang Qing Guo<sup>1,\*</sup>, Shi Ning Ma<sup>1</sup>, Xin Yi Fu<sup>1</sup>, Quan Gui Wang<sup>2</sup>, Mira Lee<sup>1</sup>

<sup>1</sup> School of Acupuncture-Moxibustion and Tuina, Beijing University of Chinese Medicine, Beijing, China  
<sup>2</sup> Department of Orthopedics, East Hospital, 00 Hospital of Beijing military region, Beijing, China



### ABSTRACT

#### Article history:

Submitted: April 09, 2020  
Revised: July 29, 2020  
Accepted: September 30, 2020

#### Keywords:

acupotomy, frozen shoulder,  
naproxen,  
randomized controlled trial

**Background:** Scapulohumeral periarthritis causes pain and stiffness, and limits movement but it is a treatable condition. This was a clinical study of acupotomy treatment for scapulohumeral periarthritis.

**Methods:** There were 80 patients randomly assigned to the traditional Chinese Medicine group (acupotomy) and the Western medicine group (naproxen), with 40 cases in each group. All patients had adjunct physiotherapy exercises for 14 days. Patients received acupotomy treatment 3 times for 14 days (Day 0, 7 and 14) or naproxen (0.22 g capsule; a non-steroidal anti-inflammatory drug) 3 times a day, for 14 days. The visual analogue scale (VAS) scores, range of motion (ROM) values, and the Melle scale, together with the therapeutic standard of diseases and syndromes in traditional Chinese Medicine were used for diagnosis and evaluation.

**Results:** There were significant differences in the VAS scores, ROM, Melle scores, cure rate and total effective rate in the group which took naproxen and the acupotomy group, before and after treatment ( $p < 0.01$ ). There were significant differences in the changes in VAS, ROM and Melle scores between the 2 groups ( $p < 0.01$ ), and the acupotomy group was better than the naproxen group.

**Conclusion:** Traditional Chinese Medicine and Western medicine can improve functional activity and reduce the level of pain experienced by patients suffering from scapulohumeral periarthritis. However, improvement of functional activity of the shoulder joint following acupotomy treatment was more obvious than the use of a non-steroidal anti-inflammatory drug, and the cure rate, and total effective rate of acupotomy was better.

<https://doi.org/10.13045/jar.2020.00080>  
pISSN 2586-288X eISSN 2586-2898

©2020 Korean Acupuncture & Moxibustion Medicine Society. This is an open access article under the CC BY-NC-ND license (<http://creativecommons.org/licenses/by-nc-nd/4.0/>).

### Introduction

Scapulohumeral periarthritis is a condition characterized by shoulder pain and limited range of movement, which mostly occurs in middle age (40-60 years), and the elderly. The incidence of scapulohumeral periarthritis in women is slightly higher than in men. With the aging of the population in society, the incidence of scapulohumeral periarthritis has significantly increased. It affects people's quality of life, so research into the treatment of scapulohumeral periarthritis has gained more attention. There are many treatments for scapulohumeral periarthritis. In this study the clinical application of acupotomy in the treatment of scapulohumeral periarthritis achieved good results in analgesia and remission of dysfunction.

### Materials and Methods

#### Demographic data

The 80 cases observed in this study were patients who visited the Department of Orthopedics in the General Hospital of Beijing Military Region, and the Department of Acupuncture and Moxibustion of the Outpatient Department of Traditional Chinese Medicine, Beijing University of Traditional Chinese Medicine (TCM) from December 2011 to December 2013.

There were 80 patients who met the inclusion criteria, and were randomly assigned to the TCM acupotomy group, or the Western medicine naproxen group using a random number table, with 40 patients in each group. There was 1 case of exclusion in the acupotomy group due to interrupted treatment caused by fear of the acupotomy procedure and therefore there were 39 cases in the

\*Corresponding author. Chang Qing Guo  
School of Acupuncture-Moxibustion and Tuina, Beijing University of Chinese Medicine, China  
E-mail: [guochangqing66@163.com](mailto:guochangqing66@163.com)

ORCID: Chang Qing Guo <https://orcid.org/0000-0003-0393-2674>, Shi Ning Shi <https://orcid.org/0000-0001-6811-1047>, Xin Yi Fu <https://orcid.org/0000-0002-8331-5002>, Quan Qui Wang <https://orcid.org/0000-0002-4978-7065>, Mira Lee <https://orcid.org/0000-0003-1805-3576>

©2020 Korean Acupuncture & Moxibustion Medicine Society. This is an open access article under the CC BY-NC-ND license (<http://creativecommons.org/licenses/by-nc-nd/4.0/>).

TCM group included in this study. One patient in the naproxen group was excluded due to long-term business trips during the treatment process and therefore there were 39 eligible cases in the Western medicine group.

Among the 80 patients, there were 32 cases of right shoulder involvement, 47 cases of left shoulder, and 1 case of double shoulder. There were 40 males and 40 females, with a male-to-female ratio of 1:1, including 19 males and 21 females with an average age of 56.25 years in the acupotomy TCM group, and 21 males and 19 females in the naproxen Western medicine group with an average age of 56.35 years (Table 1). Among the selected patients, only 1 patient had bilateral shoulder joint disease at the same time, and the rest were unilateral. The shortest course of disease was 0.5 months and the longest was 36 months.

The demographic data of the 2 groups were compared. The gender of the count data was tested by Chi-square test, and the age, condition and course of the measurement data were tested by rank sum test and there was no significant difference between groups ( $p > 0.05$ ).

There is no IRB system in China, so there is no IRB number for this study.

### Diagnostic criteria for scapulohumeral periarthritis

#### Diagnostic criteria of western medicine

Diagnosis of scapulohumeral periarthritis in the western medicine group was made by referring to the diagnostic criteria for scapulohumeral periarthritis formulated at “the second national academic seminar on scapulohumeral periarthritis”[1].

#### (1) Medical history

- ① Around 50 years old (women are slightly more prone to the condition than men).
- ② There is a history of shoulder injury or a history of local fixation, or a history of hemiplegia.
- ③ History of cold and humidity.

#### (2) Symptoms

- ① Slow onset, persistent pain, worse at night, affecting sleep.
- ② Dysfunction in lifting abduction and shoulder rotation restriction, of which the external rotation restriction is obvious (muscle spasm is dominant in the acute phase and joint spasm is dominant in the chronic phase).
- ③ Movements in daily life are limited including combing hair, dressing, putting on a belt, raising arms, and pulling hands out of pockets are all difficult movements.

#### (3) Clinical signs

- ① Extensive tenderness in the front of the shoulder, under the acromion, in the internodal groove, at the deltoid attachment, and in the upper corner of the scapula.
- ② Joint stiffness including external rotation, internal rotation, abduction, and lifting are restricted.
- ③ Muscle atrophy including the deltoid muscle and the supraspinatus and inferior muscles.

#### (4) X-ray inspection

- ① A scan of the front and back of the shoulder joint and the maximum lifting position, and the angle between the axis of the humeral shaft and the axis of the scapular ganglia which is less than 140°.
- ② Osteoporosis or cystic change of large humerus tuberosity or sclerosis of large tuberosity may be observed.

#### (5) Reference examination conditions (arthroscopy and shoulder arthrography).

### Diagnostic criteria of TCM

Diagnosis of scapulohumeral periarthritis in the TCM group was made by referring to the “TCM industry standard of the People’s Republic of China “Criteria of diagnosis and therapeutic effect of diseases and syndromes in TCM” (ZY/ T001.9-94) [2].

- (1) Chronic strain, muscle trauma and bone trauma, lack of qi and blood, complex feeling caused by wind, cold and dampness.
- (2) The prevalence age is about 50 years old (more women than men are affected), right shoulders are affected more than left shoulders, and patients mostly present in the chronic phase.
- (3) Pain around the shoulder joint, mainly felt at night, which is often induced by changes in the weather or fatigue, and dysfunction of the shoulder joint.
- (4) Shoulder muscle atrophy without obvious swelling presents as tenderness around the shoulder joint, unfavorable activity, and abduction function is obviously limited, and the phenomenon of the patient appearing to carry their shoulder occurs.
- (5) X-ray examination is mostly negative, and osteoporosis can be observed in patients with a long course of disease.

### Inclusion criteria

- (1) Meeting the diagnostic criteria of TCM /Western medicine.
- (2) Age ranges from 40 to 70 years.
- (3) Have not taken analgesics recently.
- (4) Be sane and have normal and stable vital signs.
- (5) Agree and voluntarily sign informed consent forms.
- (6) Patients who met the above diagnostic criteria and did not have other systemic diseases will participate in the clinical study.

### Exclusion criteria

- (1) Women who were pregnant, breast-feeding or preparing for pregnancy.
- (2) Acute shoulder joint injury, shoulder joint tuberculosis, tumor, apoplexy sequelae.
- (3) Patients with cardiovascular, cerebrovascular, lung, liver, kidney, hematopoietic system and other serious diseases, and mental diseases.

Table 1. Demographic Characteristics Between the 2 Groups.

Group	Cases	Gender		Age ( $\bar{x} \pm s, y$ )
		Men	Women	
TCM acupotomy group	40	19	21	56.25 $\pm$ 8.005
Western medicine naproxen group	40	21	19	56.35 $\pm$ 8.782

TCM, traditional Chinese medicine.

- (4) Obvious cervical spondylosis and shoulder fracture.
- (5) Shoulder pain caused by rheumatism and rheumatoid arthritis.
- (6) Skin damage at the operation site.
- (7) Excluding patients who were taking drugs or used other treatment methods after inclusion into the study.

### **Intervention methods**

#### TCM acupotomy therapy

The patient was placed in the sitting position and the upper limb of the affected side allowed to rest naturally, or the affected limb was placed on the lateral lying position. Four fixation points were taken in coracoid process, greater tuberosity of humerus, lesser tuberosity of humerus, and intertubercular groove. According to the patient's pain points, combined with the positions which limited shoulder joint function, and the pressure point, the cords, nodules at the fixed point, 1 to 2 treatment points such as the point in supraspinous fossa, the point in infraspinous fossa, and the point at the subscapular corner were chosen. Routine disinfection with iodine liquor or iodide, and spreading disposable towels, wearing sterile gloves, the use of a Hanzhang disposable sterile knife needle No. 4 0.8 mm × 50 mm (Beijing Excellence Huayou Medical Equipment Co., Ltd.) were used. In brief, the knife line was in parallel with the main nerves, blood vessels, and the knife rapidly pricked into the skin, vertical dredging, transverse stripping, making incisions and other treatment. When there was a sense of loosening, the knife needle was withdrawn. The treatment area was pressed for 3 minutes, and covered with a sterile dressing (in detail, ① with the coracoid process as the sign, the line of the knife needle edge is parallel to the short head of biceps brachii and colic brachialis muscle fiber, and the process of peeling off longitudinally, or inward and downward along the direction of pectoralis minor muscle fibers for longitudinal stripping begins. ② The acupotomy knife needle is inserted perpendicular to the surface of the skin at the lesser tuberosity of humerus to avoid the acupotomy knife needle causing a large amount of damage to the cephalic vein and axillary artery. ③ At the greater tubercle of humerus, the acupotomy knife needle edge was used to cut longitudinally along the supraspinatus muscle, infraspinatus muscle, and tendon fiber of the lesser round muscle to avoid shoveling the inner edge of the greater tubercle, and thus prevent injury to the long head muscle key of the biceps brachii. ④ At the point of the intertubercular groove, the knife needle was used to puncture longitudinally to the wall of the tendon sheath in the intertubercular groove, so that the acupotomy knife needle was along the tendon of long head of biceps brachii allowing movement longitudinally to cut open the tendon of the narrow section. It is not appropriate to perform the longitudinal operation of the deep part of the intertubercular groove, because it may damage the arteriae circumflexa humeri anterior). During treatment, the patient was instructed to move the shoulder joint in all directions. Treatment was given 3 times on the 1<sup>st</sup>, 7<sup>th</sup>, and 14<sup>th</sup> day.

#### Western medicine naproxen treatment

An oral naproxen natrium-bele capsule (0.22 g) was taken 3 times per day, for 14 days. Patients were instructed to move their shoulder in all directions during the 14-day treatment.

#### Adjuvant therapy

All patients were given adjuvant therapy, that is physiotherapy where patients were instructed to climb the wall with their fingers to the highest reachable point, 50 times a day, and bend over and move the shoulder in a pendulum motion for 100 movements, once a day.

### **Observation indicators**

#### Evaluation of shoulder joint pain using visual analogue scale scoring

Visual analogue scale (VAS) scoring was recorded once before and after treatment. In the VAS, a 10-cm-long ruler is marked with the 0 to 10 at both ends where 0 indicates pain free and 10 indicates the most intense pain.

#### Evaluation of shoulder range of motion

The change in range of motion (ROM) was measured by the goniometer and determined from before and after treatment ROM measurements.

- (1) Measuring forward and backward flexion of the shoulder joints was performed in a standing position, where the head, back and hip were against to the wall. The goniometer was placed on the back of the upper arm in the middle, and the dial 0 pointed to the far end.
- (2) Measuring abduction and adduction of the shoulder joints was performed in a standing position, with the head, back and hip close to the wall. The goniometer was placed in the middle of the inner edge of the upper arm, and the dial at 0 pointed to the far end.
- (3) Measuring internal rotation and external rotation of the shoulder joints was taken with the shoulder abducted 90°, the elbow 90°, and the forearm rotated to the end of the bed or the head of the bed. The goniometer was placed in the forearm ulnar edge, and the dial at 0 pointed to the far end.

#### The Melle scale: the evaluation index of shoulder joint activity and function

The Melle scale was used once before and after treatment to measure pain, local tenderness, range of joint passive motion, circumference of the deltoid muscle to quantitatively rate the level of activity and function in a patient.

#### Standard for efficacy evaluation

Efficacy evaluation referring to the standard for the curative effect of scapulohumeral periarthritis [1], was determined using the Criteria of diagnosis and therapeutic effect of diseases and syndromes in traditional Chinese medicine issued by the state administration of TCM.

- (1) A clinical cure was defined as the disappearance of pain in the shoulder joints and free movement in the shoulder, raised upper arm  $\geq 150^\circ$ , extended forward  $\geq 90^\circ$ , and abducted  $\geq 90^\circ$ .
- (2) An obvious effect was defined as no pain in the shoulder joints, or only occurring occasionally. The upper arms raised were  $\geq 130^\circ$ , extended forward  $\geq 75^\circ$ , and abducted  $\geq 75^\circ$ .
- (3) The treatment was considered effective if the pain of the shoulder joints was alleviated. The upper arms raised  $\geq 110^\circ$ , extended forward were  $\geq 60^\circ$ , and abducted  $\geq 60^\circ$ .
- (4) The treatment was considered invalid if the pain of the shoulder joints showed no significant improvement. The upper arms raised, extended forward and abducted were  $\leq 30^\circ$ .

#### Statistical methods

Statistical software SPSS Version 18.0 was used for all data. The paired *t* test was used for comparison of before and after treatment, and the total effective rate was tested by the Chi-square test. Pairwise rank sum test was used to compare the curative effect

between the 2 groups, and the difference was considered to be statistically significant when  $p < 0.05$ .

**Results**

**Comparison of visual analogue scale scores of shoulder pain between the 2 groups before and after treatment**

Since both sets of data were normally distributed and were not significantly different in VAS scores before treatment, the single sample  $t$  test was used to compare the groups. After treatment, there was a significant difference in the visual analogue scale VAS score for shoulder pain between the TCM acupotomy group and the Western medicine naproxen group ( $p < 0.01$ ). The VAS scores were significantly lower than before treatment for both the TCM acupotomy group ( $p < 0.01$ ) and the Western medicine naproxen group ( $p < 0.01$ ), but the acupotomy group was significantly superior to the naproxen group ( $p < 0.01$ ; Fig. 1).

**Comparison of ROM of the shoulder joint between the 2 groups**

The data before and after treatment in the TCM acupotomy group and the Western medicine naproxen group were normally distributed, so the single-sample  $t$  test was used. There was a significant difference in the ROM of the shoulder joint before and after both treatments ( $p < 0.01$ ). Compared with before treatment, the difference in the improvement in ROM of the TCM acupotomy group ( $p < 0.01$ ) was significantly better than of the Western medicine naproxen group ( $p < 0.05$ ; Table 2).

**Comparison of Melle scores to determine functional activity before and after treatment**

The Melle scores of the TCM acupotomy group and the Western medicine naproxen group before and after treatment, were normally distributed so a one-sample  $t$  test was used. There was a significant difference in Melle scores before and after treatment in the TCM acupotomy group ( $p < 0.01$ ) and Western medicine naproxen group ( $p < 0.01$ ). The change of Melle scores before and

after treatment was significantly higher in the TCM acupotomy group suggesting the acupotomy treatment was superior to the Western medicine naproxen treatment group ( $p < 0.01$ ; Fig. 2).

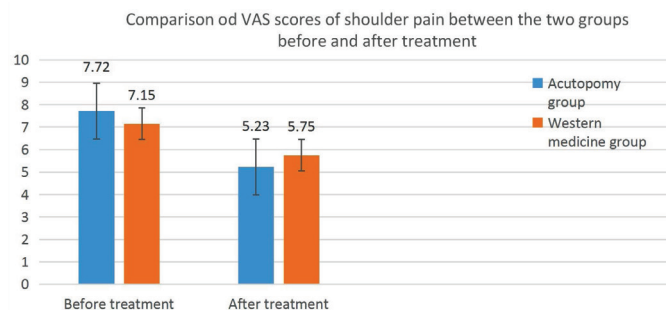


Fig. 1. Comparison of the VAS scores for shoulder pain between the 2 groups before and after treatment. Compared with the Western medicine naproxen group. TCM, traditional Chinese medicine.

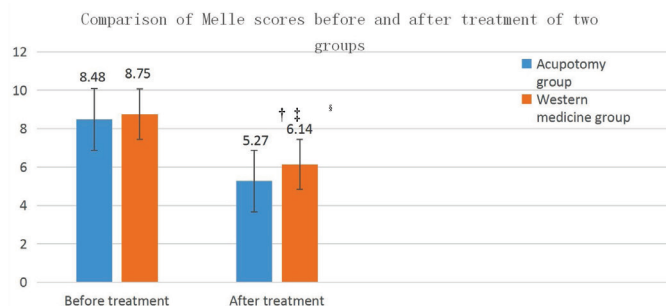


Fig. 2. Comparison of Melle scores before and after treatment in the 2 groups. Compared with the Western medicine naproxen group. \* $p < 0.05$ , † $p < 0.01$ ; compared with before treatment † $p < 0.05$ , § $p < 0.01$ . TCM, traditional Chinese medicine.

Table 2. Comparison of the ROM Evaluations Between the 2 Groups.

	Group	ROM		
		Before treatment	After treatment	The difference
Abduction	TCM acupotomy	108.59 ± 36.508	142.44 ± 38.574*	33.846 ± 26.519 <sup>†</sup>
	Western medicine naproxen	104.36 ± 28.658	124.74 ± 39.084*	20.385 ± 18.757 <sup>†</sup>
Flexion	TCM acupotomy	123.59 ± 27.240	146.03 ± 32.630*	22.436 ± 18.669 <sup>†</sup>
	Western medicine naproxen	126.67 ± 24.234	136.03 ± 25.240*	9.359 ± 7.538
Extension	TCM acupotomy	37.44 ± 12.133	47.44 ± 9.167*	10.000 ± 9.801 <sup>†</sup>
	Western medicine naproxen	39.87 ± 12.112	43.21 ± 10.729*	3.333 ± 3.504
External rotation	TCM acupotomy	56.41 ± 18.636	68.59 ± 19.499*	12.179 ± 12.019 <sup>†</sup>
	Western medicine naproxen	56.28 ± 17.272	59.87 ± 16.282*	3.590 ± 4.435
Internal rotation	TCM acupotomy	51.54 ± 16.589	71.67 ± 15.825*	20.128 ± 16.079 <sup>†</sup>
	Western medicine naproxen	53.21 ± 12.952	60.51 ± 15.825*	7.308 ± 7.241

Compared with the Western medicine naproxen group. \* $p < 0.01$ . † $p < 0.01$ ; compared with before treatment. TCM, traditional Chinese medicine.

Table 3. Comparison of Curative Effect Between the 2 Groups.

Group	Cases	Cure	Obvious effect	Effective	Invalid	Cure rate (%)	Total efficiency (%)
TCM acupotomy group	39	13	10	11	5	33.33*	87.18*
Western medicine naproxen group	39	1	13	10	15	2.56	61.54

Compared with the Western naproxen medicine group. \* $p < 0.01$ . TCM, traditional Chinese medicine.

### Comparison of curative effect between 2 groups of patients

The curative effects between groups are presented in Table 3. Using the Wilcoxon rank test, there was a statistically significant difference in the cure rate (all pain in the shoulder joints had disappeared and there was free movement) between the Western medicine naproxen group and the TCM acupotomy group where treatment with acupotomy was better than naproxen ( $p = 0.0003$ ). Using the Pearson Chi-square test (4 tables: all theoretical numbers  $T \geq 5$  and total sample size  $n \geq 40$ ) the cure rate was statistically significantly different between groups where TCM acupotomy treatment was superior to Western medicine naproxen treatment ( $p = 0.0004$ ). There was also a significant difference in the total effective rate between groups ( $p = 0.010$ ; Table 3).

### Discussion

Scapulohumeral periarthritis is the injury or degeneration of the soft tissue of the shoulder (such as muscle, tendon, or synovial sac), which leads to chronic inflammation, and extensive cell proliferation, and adhesion of shoulder tissue. This leads to a series of clinical symptoms, such as pain, limitation of movement and activity. This condition belongs to the category of arthralgia syndrome in TCM, and it is a disease of shoulder meridians and tendons. TCM meridian tendon therapy emphasizes that “the disease is in the tendons, which is ready to regulate,” and “the disease is in the bone, which is ready to regulate.” In the “Lingshu meridian tendon” the treatment principle of meridian tendon disease is “pain-point needling” where the focus on the meridian tendon is the main part of acupuncture. This study selected 1-2 shoulder joints around the Ashi point as the intervention site including the pressure points around the shoulder joint and the ropes and the nodes of the soft tissue, and therapeutic effect was achieved by releasing the Ashi acupoints with acupotomy.

The results of this study showed that the total effective rate of the TCM acupotomy treatment group was significantly higher than the Western medicine naproxen group ( $p < 0.01$ ), suggesting that acupotomy had a superior treatment effect compared with use of the anti-inflammatory drug naproxen. Due to the unique advantage of the small knife needle used in acupotomy therapy for scapulohumeral periarthritis, it allows accurate positioning of the affected area, to target the treatment effect. The VAS scores of the 2 groups of patients were significantly lower than before treatment ( $p < 0.05$ ); and the improvement of the acupotomy group was significantly better than the naproxen group ( $p < 0.01$ ), suggesting that the acupotomy treatment can effectively separate the adhesions of the soft tissue around the shoulder joint, which can effectively relieve pain in the patients. The activities of shoulder abduction, flexion, extension, internal rotation, and external rotation of the 2 groups of patients were significantly higher than

before treatment ( $p < 0.01$ ); and the acupotomy group improved more ( $p < 0.01$ ), indicating that the knife needle longitudinal and lateral stripping effectively improved the patient’s shoulder joint mobility. TCM acupotomy may improve shoulder joint mobility more quickly than Western medicine naproxen. However, for severe periarthritis, acupotomy and naproxen are not effective alone. It is recommended that when treating severe periarthritis clinically, doctors may consider other methods of combined treatment.

Under the guidance of the meridian tendon theory of TCM, acupotomy therapy can release the soft tissue injury points, separate the adhesion of the soft tissue around the shoulder joint, restore the balance of the tendons and bones, reduce the tension of the soft tissue, and release the compressed nerves and blood vessels, in order to restore the normal function of the nerves, smooth the blood circulation, take away a large number of analgesic substances, relieve pain and restore the activity function of the shoulder joint. Therefore, acupotomy has a beneficial effect on scapulohumeral periarthritis [3-4].

### Conclusion

Both TCM acupotomy and Western medicine naproxen can treat scapulohumeral periarthritis, improve local symptoms, and relieve pain, but the cure rate of acupotomy is higher and there is also a significant difference in total effective rate compared with naproxen.

Both TCM acupotomy and Western medicine naproxen can improve the abduction, flexion, extension, internal rotation and external rotation of scapulohumeral periarthritis, but compared with naproxen, acupotomy had the most obvious improvement on abduction functional range of the shoulder, followed by the more obvious improvement in the flexion range of shoulder.

### Conflicts of Interest

The authors have no conflicts of interest to declare.

### References

- [1] Guo CF. Diagnosis and rehabilitation of periarthritis of shoulder. Beijing (China): China Medical Science and Technology Press;1993. p.36-37.
- [2] Chen YB. State Administration of Traditional Chinese Medicine. Criteria of diagnosis and therapeutic effect of diseases and syndromes in traditional Chinese medicine. Nanjing (China): Nanjing University Press; 1994. p.218-219.
- [3] Pei Y. Mechanism of acupotomy combined with Tuina in the treatment of scapulohumeral periarthritis. World Latest Med Inf 2019;19:206-207. [in Chinese].
- [4] Feng JB, Wang CX. Clinical analysis of small acupotomy combined with Tuina manipulation in the treatment of scapulohumeral periarthritis. Chin J Tradit Med Traumatol Orthop 2015;23:42-43.