



## Urethroplasty of extensive penile urethral strictures with a longitudinal ventral tubed flap of penile skin (modified Orandi urethroplasty): 20 years of follow-up of two cases

Jae Won Heo, Woo Taik Hong, Yong Hun Kim, Chae Eun Yang, Jiye Kim, Sug Won Kim

Department of Plastic and Reconstructive Surgery, Wonju Severance Christian Hospital, Yonsei University Wonju College of Medicine, Wonju, Korea

The surgical treatment of extensive urethral strictures remains a controversial topic; although techniques have evolved, there is still no definite method of choice. Since 1968, when Orandi presented an original technique for one-stage urethroplasty using a penile skin flap, the Orandi technique has become the most prevalently used one-stage procedure for anterior urethral strictures. We present a 20-year follow-up experience with one-stage reconstruction of long urethral strictures using a longitudinal ventral tubed flap of penile skin, with some important technical changes to Orandi's original technique to overcome the deficient vascularity caused by periurethral scar tissue. In 1997, a 55-year-old male patient complained of severe voiding difficulty and a weak urinary stream because of transurethral resection of the prostate due to benign prostatic hyperplasia. Another 47-year-old male patient had the same problem due to self-removal of a Foley catheter in 2002. In both patients, a urethrogram demonstrated extensive strictures involving the long segment of the anterior urethra. A rectangular skin flap on the ventral surface of the penis was used considering the appropriate length, diameter, and depth of the neourethra. The modified Orandi flap provided a pedicled strip of penile skin measuring an average of 8 cm. The mean duration of follow-up was 20.5 years. A long-term evaluation revealed stable performance characteristics without any complications.

**Correspondence:** Sug Won Kim  
Department of Plastic and Reconstructive Surgery, Wonju Severance Christian Hospital, Yonsei University Wonju College of Medicine, 20 Ilsan-ro, Wonju 26426, Korea  
Tel: +82-33-741-0611  
Fax: +82-33-732-4022  
E-mail: sugwonkim@yonsei.ac.kr

Case Report

**Keywords** Surgical flap / Urethroplasty / Urethral stricture

Received: July 24, 2019 • Revised: May 26, 2020 • Accepted: June 15, 2020  
pISSN: 2234-6163 • eISSN: 2234-6171 • <https://doi.org/10.5999/aps.2019.00941> • Arch Plast Surg 2020;47:613-618

### INTRODUCTION

The management of extensive urethral strictures is among the most challenging clinical problems facing both urologic and plastic surgeons. Urethral strictures not only cause voiding difficulties, but can also bring about serious psychological problems

in people who are socially active. Urethral strictures caused by trauma, inflammatory disease, burns, or complicated priapism have been treated with many different surgical methods during the past centuries. However, many problems still remain with the current methods, making it a field of further exploration for reconstructive surgeons. The treatment of choice for all posteri-

or strictures is excision of the stricture and primary tension-free anastomosis, but for anterior long strictures, the optimal management remains an unsolved problem despite technological advances and the development of new surgical methods. We report our experience with one-stage reconstruction of long urethral strictures using a longitudinal ventral tubed flap of penile skin, which was chosen to as an option for extensive urethral reconstruction to overcome the poor vascularity due to periurethral scarred tissues and limitations in the choice of a local flap.

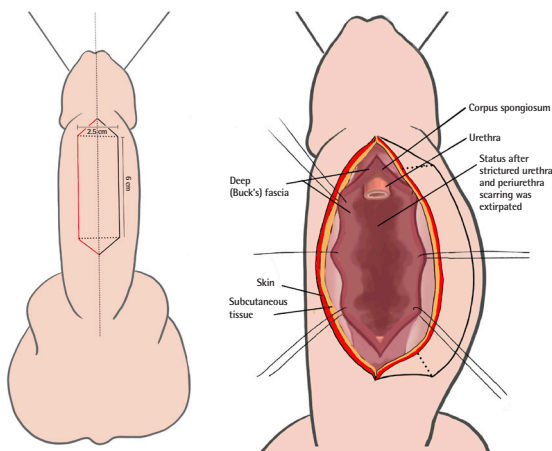
From 1997 to 2001, two patients underwent surgery for urethral reconstruction at our institution. One male patient complained of severe voiding difficulty and a weak urinary stream because of transurethral resection of the prostate (TURP) due

to benign prostate hyperplasia (BPH) and another had the same problem as a sequela of traumatic self-removal of a Foley catheter. They were admitted to the urology department for treatment. Both men had multiple or extensive strictures involving the long segment of the anterior urethra (at least 6 cm) on a urethrogram. None had undergone prior open urethroplasty. After suprapubic cystostomy was performed to resolve the patients' aggravated voiding difficulties, they were referred to our department to resolve the stricture and to construct the neourethra.

Under general anesthesia, a rectangular skin flap was designed on the ventral surface of the penis considering the appropriate length, diameter, location, and depth of the neourethra (Fig. 1). Resection of a portion of the urethral stricture was performed and the neourethra was constructed in the exaggerated lithotomy position or supine position. A right paramedian incision was made and dissection was conducted over the corpus spongio-

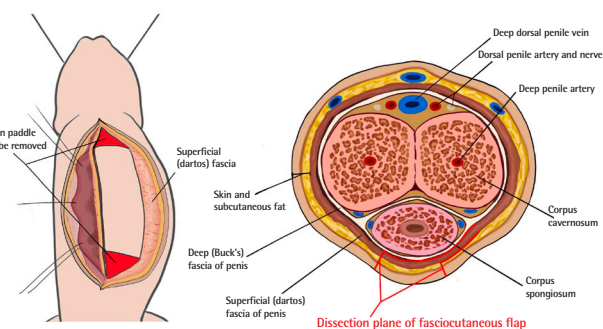
**Fig. 1. Schematic illustration of flap design**

A longitudinal ventral tubed flap measuring 2.5 × 6 cm was designed on the penile skin, including an extra triangle of skin for primary closure. The incision line was marked in red. After removal of the strictured part of the urethra, a 6-cm-long urethral defect was observed. The flap was developed in the layer immediately beneath Buck's fascia.



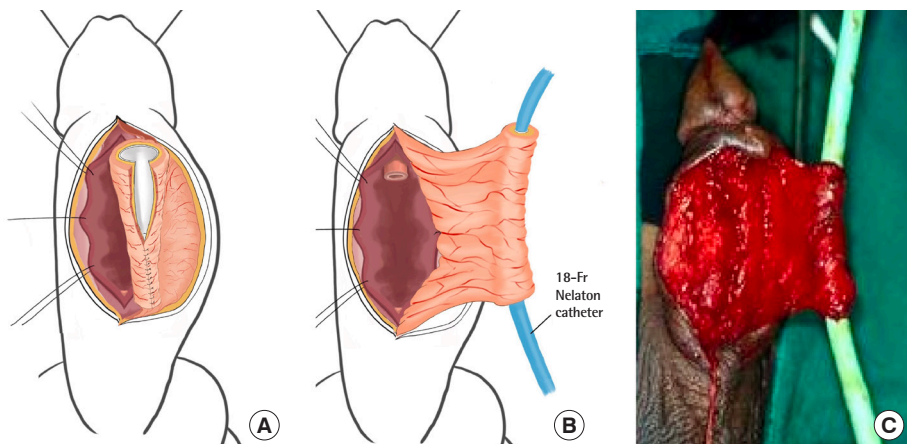
**Fig. 2. Schematic illustration of flap elevation**

After a contralateral incision was done, a skin paddle measuring 2.5 × 6 cm was observed and the parts to be removed were marked in red. The superficial (dartos) fascia was left intact as the pedicle. In a transverse section, the red line and highlight demonstrates the dissection of the fasciocutaneous flap.



**Fig. 3. Schematic illustration of neourethral tubing**

(A) Eccentric closure was performed using Vicryl #4-0. (B, C) Neourethral tubing after insertion of an 18-Fr Nelaton catheter. Taking care not to detach the skin flap from Buck's fascia to avoid flap distress, secure two-layer eccentric closure of the flap for tubing was performed.



sum by reflection of Buck's fascia from the tunica albuginea and the adventitia of the corpus spongiosum. The urethrectomy was extended into the normal urethra proximally and distally (Fig. 1).

A skin flap was developed in the layer immediately beneath Buck's fascia (Fig. 2). A contralateral skin incision was extended to the dartos fascia for tubing (Fig. 2). With caution not to detach the skin flap from the Buck's fascia to cause flap distress, a 20-Fr or 18-Fr Foley catheter was placed in the center of the flap and a secure two-layer eccentric closure of the flap for tubing was performed (Fig. 3). The tubed flap was then transferred to

the urethral defect, with the suture line oriented latero-dorsally toward the deep aspect against the corpora. The proximal and distal urethral anastomoses were spatulated to reduce the likelihood of stricture in two-layer repair (Fig. 4). The ventral surface of the penile shaft was closed primarily. The Foley catheter was removed on postoperative day 10 or 14, and the suprapubic cystostomy site was closed after self-voiding was confirmed.

## CASES

### Case 1

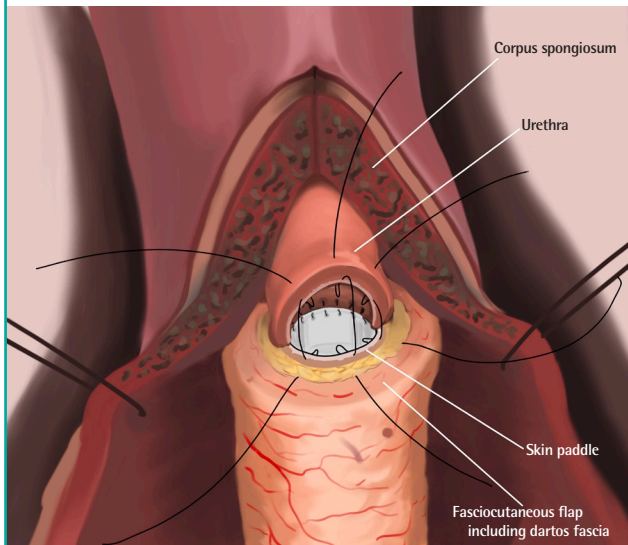
A 56-year-old man visited our hospital, complaining of voiding difficulty for 2 years due to BPH. TURP was attempted three times after sound dilatation, but a urethral stricture developed due to inflammation of the urethra. On preoperative retrograde urethrography (RGU), a stricture of the bulbous urethra was observed and the resection length of the urethral stricture measured 6 cm (Fig. 5). A neourethra was reconstructed using a longitudinal ventral tubed flap of penile skin and the Foley catheter was removed 2 weeks after the operation. Postoperative RGU and voiding cystourethrography (VCUG) demonstrated normal results at that time and the patient was discharged. Two months later, the patient reported ongoing voiding difficulties, and mild to moderate stricture recurrence was identified at the proximal site by Foley catheter insertion. Sound dilatation was performed immediately. Subsequently, no urethral strictures, voiding difficulty, or any other complications were observed for 21 years postoperatively (Fig. 6).

### Case 2

A 46-year-old man developed a urethral stricture and voiding difficulty due to self-removal of a Foley catheter in the setting of

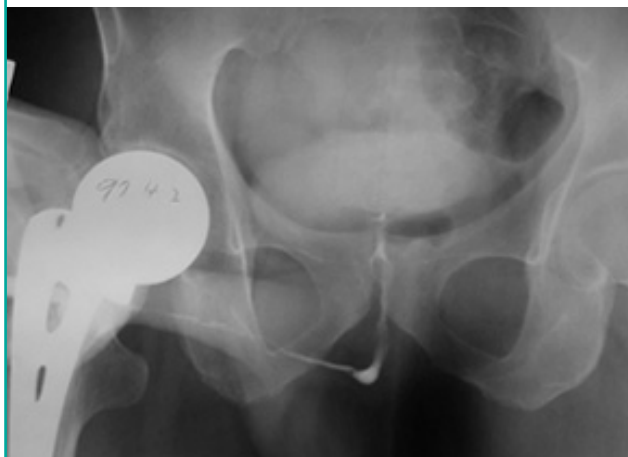
**Fig. 4. Illustration showing anastomosis of flaps and urethra**

We performed 12-point Vicryl #6-0 sutures in a vertical-mattress manner, with respect to eversion of the tissue. The full-thickness urethra and the tubed fasciocutaneous flap, including the whole skin layer and extending to the subcutaneous layer, were sutured in a vertical-mattress manner in 12 directions. The tie was made to be buried against the uroepithelial surface.



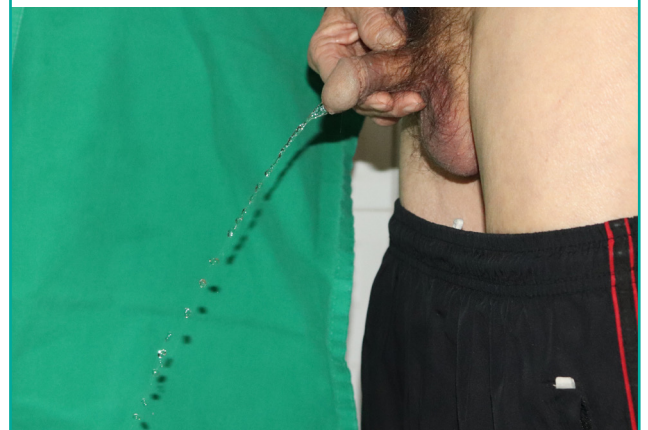**Fig. 5. Preoperative retrograde urethrography**

Severe strictures were observed along the entire anterior urethra.



**Fig. 6. Postoperative (long-term) outcomes**

Twenty-one years after surgery, active urination was well maintained.



cardiac surgery. Sound dilatation was attempted four times after suprapubic cystostomy, but no improvement of the urethral stricture was observed. The patient was referred to our department. Preoperative RGU showed stricture of the bulbous urethra. The length of the resected urethral stricture was 8 cm. Neourethra reconstruction was done using a longitudinal ventral tubed flap of penile skin. The Foley catheter was removed 2 weeks postoperatively and the suprapubic cystostomy was removed 3 weeks postoperatively for normal voiding. Postoperative RGU and VCUG showed no urethral strictures, diverticula, or urethrocutaneous fistulas. The patient has been followed up for 20 years without any complications.

The longitudinal ventral tubed flap of penile skin yielded a pedicled strip that was, on average, 8 cm long (range, 6–10 cm). There was no need for additional graft materials for reconstruction in either patient. The mean follow-up was 20.5 years. Postoperative imaging included RGU and VCUG at 2 weeks, which were repeated at follow-up if there was clinical evidence of stricture recurrence. In one case, sound dilatation was performed because of proximal mild to moderate stricture recurrence. There were no voiding difficulties and recurrence during the follow-up period.

## DISCUSSION

The number of patients with traumatic urethral strictures has increased in recent years due to the development of machines and automobiles, as well as the overall complexity of society. The causes of urethral injury include automobile accidents and falls, as well as inflammation. Trauma is one of the most common cause of strictures in the anterior urethra. Among these cases of trauma, post-instrumentation strictures—typically due to catheterization—are common [1].

Broadly speaking, the treatment strategies for urethral strictures can be classified as conservative or surgical. Conservative treatments include periodic urethral dilatation and staged catheter maintenance. However, these treatments are time-consuming and frequently result in complications; therefore, they are used in low-grade urethral strictures. Surgical methods are divided into internal urethrotomy and urethroplasty, and different authors have different opinions on the benefits and drawbacks of these two methods. After the introduction of visual internal urethrotomy by Sachse [2] in 1971, this procedure has been used extensively as the primary method of treatment. It is simple to perform and offers a short hospital stay; furthermore, it can be repeated. However, the recurrence rate of this procedure is high, for which reason it has been accepted as effective in cases of strictures shorter than 1 cm. In patients with urethral strictures

in whom urethral dilatation or visual internal urethrotomy is not possible, end-to-end anastomosis of both normal urethral segments without tension is possible. Nonetheless, end-to-end tension-free anastomosis is not feasible when the stricture is long or complex or when the scar from previous surgery is severe.

Therefore, visual internal urethrotomy and end-to-end anastomosis are not suitable in patients with urethral strictures due to extensive injury; instead, urethroplasty is needed. Although various procedures have been suggested according to the degree or site of stricture, no definitive treatment guideline has been established.

One-stage urethroplasty is the surgery of choice in cases of anterior urethral stricture with a normal penis (i.e., without congenital anomalies such as hypospadias). In turn, one-stage urethroplasty procedures can be classified according to whether a flap or graft is used [3-5].

If a graft is to be used for urethroplasty, options include skin [6], mucosal [7], vein [8], and appendix [9] grafts. These procedures have been used only in relatively short urethral strictures, but could cause chordee and impotence due to their limited extensibility [6,7]. Options for performing urethroplasty with a flap include scrotal flaps [10], free flaps [11,12], and fasciocutaneous flaps. The authors used fasciocutaneous flaps, which are suitable for the reconstruction of wider strictures, as in the cases described herein [13].

Scrotal skin island flaps could cause urethral stones due to the presence of hair and diverticulum due to skin dilation [10]. Although radial or ulnar forearm free flaps or free ileum flaps could be used for multiple severe strictures of the penile urethra, with defects in the entirety of the cavernous urethra, the use of these flaps is limited due to donor site morbidity [14].

Furthermore, the advantages of reconstruction using penile skin are associated with the original properties of the skin itself, including hairlessness, sufficient length (13 to 15 cm), flexibility, and versatility [15].

In strictures longer than 5 cm, corresponding to more than half of the total length of the penis [16], a fasciocutaneous flap using the dartos fascia [17,18] as a pedicle is most suitable.

In 1968, Orandi [19] reported one-stage urethroplasty for a pendulous urethral stricture using a longitudinal ventral island flap of penile skin. This Orandi procedure is still the gold standard in nonobliterative strictures within the penile urethra without lichen sclerosus. However, recurrence of the stricture or postoperative complications such as fistula formation due to periurethral scar tissue have been reported as sequelae of this method. Therefore, various modifications of the Orandi method have been developed [5,13].

The method used by the authors was also intended to address

the disadvantages of the Orandi method. A distinctive aspect of our technique is not only the design with one longitudinal incision line of the neourethra, but also the reconstruction of the whole urethra, which enabled complete removal of the stricture, unlike other modified Orandi methods. By removing the entire stricture, it was possible to resolve both the functional urethral stricture and anatomical narrowing. The design in the midline also minimized complications such as torsion of the penile shaft, which was previously reported [20].

A further strength of our study in terms of its academic value is that previous studies have only reported follow-up extending to 10 years, but we confirmed maintenance of the urinary stream over the course of a long-term follow-up period of 20 years after the procedure. In conclusion, we completely removed the stenosed urethra and used a sufficiently large piece of ventral penile skin to achieve sufficient neourethral length and diameter based on the reliable vasculature of the dartos fascia with minimal postoperative complications. This one-stage, longitudinal ventral tubed fasciocutaneous flap should be considered as an attractive option in cases of extensive anterior urethral strictures.

## NOTES

### Conflict of interest

No potential conflict of interest relevant to this article was reported.

### Ethical approval

The study was approved by the Institutional Review Board of Wonju Severance Christian Hospital (IRB No. CR320320) and performed in accordance with the principles of the Declaration of Helsinki. Written informed consents were obtained.

### Patient consent

The patients provided written informed consent for the publication and the use of their images.

### Author contribution

Conceptualization: SW Kim. Visualization: JW Heo. Writing - original draft: JW Heo. Writing - review & editing: WT Hong, YH Kim, CE Yang, J Kim, SW Kim. Approval of final manuscript: all authors.

### ORCID

Jae Won Heo <https://orcid.org/0000-0002-9070-5244>  
 Woo Taik Hong <https://orcid.org/0000-0002-6764-8755>  
 Yong Hun Kim <https://orcid.org/0000-0002-6092-4374>  
 Chae Eun Yang <https://orcid.org/0000-0001-8128-791X>

Jiye Kim <https://orcid.org/0000-0002-1724-4250>

Sug Won Kim <https://orcid.org/0000-0002-2354-7100>

## REFERENCES

1. Andrich DE, Mundy AR. What is the best technique for urethroplasty? *Eur Urol* 2008;54:1031-41.
2. Sachse H. Treatment of urethral stricture: transurethral slit in view using sharp section. *Fortschr Med* 1974;92:12-5.
3. Lee YJ, Lee BK. Tubularized penile-flap urethroplasty using a fasciocutaneous random pedicled flap for recurrent anterior urethral stricture. *Arch Plast Surg* 2012;39:257-60.
4. Park KR, Kim TG, Lee J, et al. Single-stage reconstruction of extensive defects after Fournier's gangrene with an exposed iliac crest and testes. *Arch Plast Surg* 2013;40:74-6.
5. Lee YJ, Kim SW. Current management of urethral stricture. *Korean J Urol* 2013;54:561-9.
6. Devine PC, Fallon B, Devine CJ Jr. Free full thickness skin graft urethroplasty. *J Urol* 1976;116:444-6.
7. Morey AF, McAninch JW. When and how to use buccal mucosal grafts in adult bulbar urethroplasty. *Urology* 1996;48:194-8.
8. Kahveci R, Kahveci Z, Sirmali S, et al. Urethral reconstruction with autologous vein graft: an experimental study. *Br J Plast Surg* 1995;48:500-3.
9. Koshima I, Inagawa K, Okuyama N, et al. Free vascularized appendix transfer for reconstruction of penile urethras with severe fibrosis. *Plast Reconstr Surg* 1999;103:964-9.
10. Gil-Vernet J, Arango O, Gil-Vernet A, et al. A new biaxial epilated scrotal flap for reconstructive urethral surgery. *J Urol* 1997;158:412-20.
11. Elia R, Pafitanis G, Ciudad P, et al. Accessory penis: a rare method of peno-urethral separation of sexual function and voiding following successful complex hypospadias reconstruction with a free ileum flap. *Arch Plast Surg* 2019;46:381-5.
12. Teven CM, Yu JW, Zhao LC, et al. Extended medial sural artery perforator free flap for groin and scrotal reconstruction. *Arch Plast Surg* 2020;47:354-59.
13. Barbagli G, Morgia G, Lazzeri M. Retrospective outcome analysis of one-stage penile urethroplasty using a flap or graft in a homogeneous series of patients. *BJU Int* 2008;102:853-60.
14. Boorman JG, Brown JA, Sykes PJ. Morbidity in the forearm flap donor arm. *Br J Plast Surg* 1987;40:207-12.
15. Whitson JM, McAninch JW, Elliott SP, et al. Long-term efficacy of distal penile circular fasciocutaneous flaps for single stage reconstruction of complex anterior urethral stricture

- disease. *J Urol* 2008;179:2259-64.
16. Schwentner C, Seibold J, Colleselli D, et al. Anterior urethral reconstruction using the circular fasciocutaneous flap technique: long-term follow-up. *World J Urol* 2011;29:115-20.
  17. Choi DS, Lee JW, Yang JD, et al. Correction of problematic hypospadias with dartos fascia-reinforced flap and slanted incision of fistula. *Arch Plast Surg* 2013;40:766-72.
  18. Buckley J, McAninch J. Distal penile circular fasciocutaneous flap for complex anterior urethral strictures. *BJU Int* 2007;100:221-31.
  19. Orandi A. One-stage urethroplasty. *Br J Urol* 1968;40:717-9.
  20. Greenwell TJ, Venn SN, Mundy AR. Changing practice in anterior urethroplasty. *BJU Int* 1999;83:631-5.