

# Therapeutic Effect of Teriparatide for Osteoporotic Thoracolumbar Burst Fracture in Elderly Female Patients

Dongwoo Yu,<sup>1</sup> Sungho Kim,<sup>2</sup> Ikchan Jeon<sup>1</sup>

Department of Neurosurgery,<sup>1</sup> Yeungnam University Hospital, Yeungnam University College of Medicine, Daegu, Korea  
Department of Neurosurgery,<sup>2</sup> Bogang Hospital, Daegu, Korea

**Objective :** Teriparatide is known as an effective anabolic agent not only for severe osteoporosis but also for bone healing and union. We explored the possibility of teriparatide as an alternative treatment option for osteoporotic thoracolumbar (TL) burst fracture.

**Methods :** This retrospective study enrolled 35 female patients with mean age of  $73.77 \pm 6.71$  years (61–88) diagnosed as osteoporotic TL burst fracture with  $\geq 4$  of thoracolumbar injury classification and severity (TLICS) score and no neurological deficits. All patients were treated by teriparatide only (12 of group A), teriparatide plus vertebroplasty (12 of group B), or surgical fixation with fusion (11 of group C), and followed up for 12 months. Radiological outcomes were evaluated using radiological parameters including kyphotic angle (KA), segmental vertebral kyphotic angle (SVKA), compression ratio (CR), and vertebral body height (anterior [AH], middle [MH], posterior [PH]). Functional outcomes were evaluated using visual analog scale (VAS) and Macnab classification (MC).

**Results :** There were no statistical significant differences in age, bone mineral density ( $-3.36 \pm 0.73$ ), and TLICS score ( $4.34 \pm 0.48$ ) among the three groups ( $p > 0.05$ ). Teriparatide was administered during  $8.63 \pm 2.32$  months in group A and B. In 12-month radiological outcomes, there were significant restoration in SVKA, CR, AH, and MH of group B and KA, SVKA, CR, AH, and MH of group C compared to group A with no radiological changes ( $p < 0.05$ ). All groups showed similar significant improvements in 12-month functional outcomes, although group B and C showed a better 1-month VAS, 1-month MC, 3-month MC compared to group A ( $p < 0.05$ ).

**Conclusion :** Non-surgical treatment with teriparatide showed similar 12-month functional outcomes compared to surgical fixation with fusion. The additional vertebroplasty to teriparatide and surgical fixation with fusion were more helpful to improve short-term functional outcomes with structural restoration compared to teriparatide only.

**Key Words :** Teriparatide · Spine · Fracture · Osteoporosis · Aged.

## INTRODUCTION

The pace of population aging is increasing rapidly around

the world. Therefore, as a society ages, the number of elderly patients is bound to increase. Elderly patients generally have more accompanying diseases including cardiopulmonary

• Received : April 10, 2020 • Revised : June 15, 2020 • Accepted : July 2, 2020

• Address for reprints : **Ikchan Jeon**

Department of Neurosurgery, Yeungnam University Hospital, Yeungnam University College of Medicine, 170 Hyeonchung-ro, Nam-gu, Daegu 42415, Korea  
Tel : +82-53-620-3790, Fax : +82-53-620-3770, E-mail : jicns@ynu.ac.kr, ORCID : <https://orcid.org/0000-0002-1293-2724>

This is an Open Access article distributed under the terms of the Creative Commons Attribution Non-Commercial License (<http://creativecommons.org/licenses/by-nc/4.0>) which permits unrestricted non-commercial use, distribution, and reproduction in any medium, provided the original work is properly cited.

problems, diabetes, hypertension, cerebrovascular disease, and osteoporosis. Fractures related to osteoporosis among various other geriatric diseases are continuously increasing and vertebral fractures can directly affect the quality of life among elderly patients.

The treatment of osteoporotic vertebral fractures includes conservative treatment, vertebroplasty/kyphoplasty, and open surgery for fixation and fusion. Non-surgical treatment often results in progression of vertebral collapse and nonunion in patients with severe osteoporosis, which increases the application of screw fixation and fusion surgery. However, patients with osteoporosis have lower screw-anchoring strength due to poor bone quality of the vertebrae, which leads to loosening of screw and pseudo-arthrosis after surgery<sup>13)</sup>. These problems are more frequent in the elderly patients with severe osteoporosis, and an additional surgery can be a big burden for both the patient and surgeon. In addition, perioperative medical complications significantly increase in elderly patients<sup>35)</sup>. Winkler et al.<sup>37)</sup> reported about perioperative morbidity and mortality after thoracolumbar (TL) injury in elderly patients. According to their results, spine fusion with instrumentation is associated with high perioperative complications and long-term hospitalization.

Anabolic agents are known to increase bone mass and decrease fracture risk in the patients with osteoporosis by directly stimulating osteoblast to produce new bone<sup>7)</sup>. Teriparatide, a human recombinant protein containing the first 34 amino acids of parathyroid hormone (PTH<sub>1-34</sub>), is the first anabolic agent to be approved for the treatment of osteoporosis in USA<sup>7)</sup>. Teriparatide has been shown to be superior to anti-resorptive agents for increasing bone mineral density (BMD) and lowering fracture risk<sup>29)</sup>. In addition, teriparatide is also commonly used in spine fusion, stress fracture, fracture healing, and arthroplasty due to its anabolic effect<sup>16)</sup>.

In this study, we analyzed the clinical effect of teriparatide as an alternative treatment option for osteoporotic TL burst fracture considered or indicated surgical treatment in elderly female patients.

## MATERIALS AND METHODS

This study was approved by the Institutional Review Board of Yeungnam University Hospital (No. 2020-03-003), which

waved the requirement for informed consent due to retrospective design.

## Study design and patient population

This retrospective study was conducted on 35 female patients presenting with acute back pain diagnosed as osteoporotic TL burst fracture caused by minor trauma between April 2009 to August 2018. TL area was defined as a range from T10 to L2. All patients underwent lateral plain X-ray, computed tomography, magnetic resonance imaging, and dual-energy X-ray absorptiometry scan to measure BMD. The inclusion criteria were as follows : 1) female, 2) age over 60 years, 3)  $\geq 4$  of thoracolumbar injury classification and severity (TLICS) score, and 4) no neurological deficits. Surgical fixation with fusion was initially considered based on TLICS score in all patients, but teriparatide was used as the second choice of treatment in 24 patients who refused or could not undergo operative treatment due to their inoperable condition (non-surgical group). Among 24 patients with 20  $\mu\text{g}$  of teriparatide once daily subcutaneous injection for at least 6-month, 12 patients were treated by teriparatide only (group A) and another 12 patients were treated by teriparatide plus vertebroplasty (group B). The remaining 11 patients were treated by surgical fixation with fusion (group C, surgical group). The condition of calcium and vitamin D were evaluated through blood test before starting teriparatide. In the case of deficiency, teriparatide was applied after correction of calcium and vitamin D. Thoracolumbo-sacral orthosis was applied for three months. All patients were followed up for 12-month. Patients were excluded if they had infectious spondylitis, tumor, rheumatoid arthritis, other metabolic bone diseases, less than 6-month teriparatide injection in group A and B, or TL burst fracture related to major trauma.

## Radiological assessment

### TLICS score

The TLICS score is a guideline for the treatment of TL injuries. The following three parameters were used to categorize TL fractures : 1) morphology of fracture, 2) neurological status, and 3) integrity of posterior ligament complex<sup>36)</sup>. The maximum score in this classification is 10 and the following measures are defined for each score : conservative treatments for scores  $\leq 3$ , surgery for scores  $\geq 5$ , and conservative treat-

ments or surgery for a score of 4. Based on previous evidences, the current system of categorization has an appropriate level of reliability and validity to classify TL fractures and take appropriate therapeutic measures against them<sup>24,28</sup>. However, the effects of surgery or conservative treatment in patients with TLICS score 4 is still controversial.

#### McCormack's load sharing (LS) score

The severity of skeletal injury was evaluated using McCormack's LS score. McCormack et al.<sup>18</sup> developed the LS classification, which shows the severity of the vertebra body fracture, based on the compression of the vertebral body in the sagittal plane, distance between the fragments of the vertebral body, and the degree of kyphotic correction on a lateral plain X-ray. The score ranges from 3 to 9.

#### Radiological parameters

Radiological factors including kyphotic angle (KA), segmental vertebral kyphotic angle (SVKA), compression ratio (CR), and vertebral body height (anterior [AH], middle [MH], posterior [PH]) were analyzed on lateral plain X-ray. The angle between the upper endplate of the vertebra above the fractured vertebra and the lower endplate of the vertebra under the fractured vertebra is defined as KA. The angle between the upper and lower endplate of the fractured vertebra is defined as SVKA. The percentage of anterior vertebral body compression with respect to the average height of anterior vertebra bodies located above and below to the fractured vertebra is defined as CR. Height of the collapsed vertebral body was measured at the AH, MH, and PH. Lordosis was recorded as a positive value, and kyphosis was recorded as a negative value. Measurements of radiological parameters are presented in Fig. 1.

### Functional assessment

#### Visual analog scale (VAS)

VAS, a psychometric measurement instrument, has been designed with 10 cm lines anchored at the ends by words that define the bounds of various pain dimensions, and it ranges from 0 (no pain) to 10 (maximum pain)<sup>2</sup>.

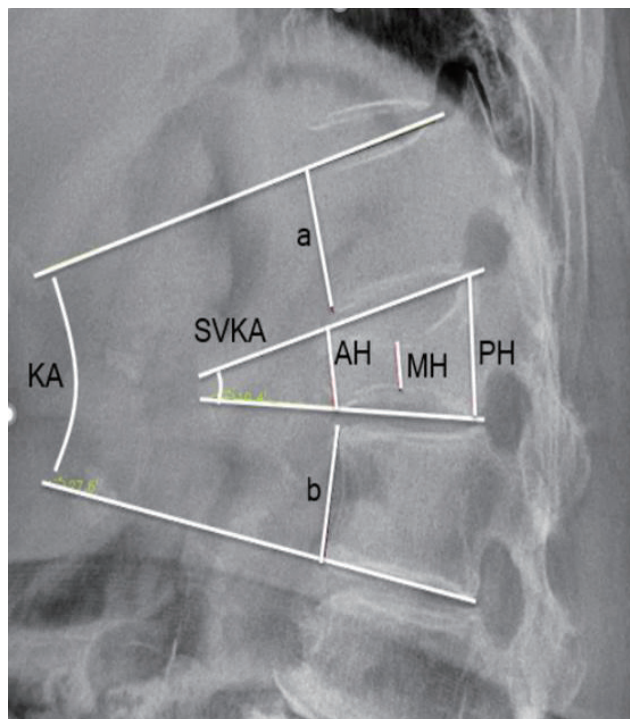
#### Macnab classification (MC)

MC was used to assess patient satisfaction when asked to rate their level of well-being, the patient choose one of the four

responses : excellent (free of pain, no restriction of mobility, and able to return to normal work and activities), good (occasional pain, relief of presenting symptoms, and able to return to modified work), fair (some improvement of functional capacity and still handicapped and/or unemployed), and poor (continuation of objective symptoms and requirement of additional operative intervention)<sup>17</sup>.

#### Statistical analysis

Student's t-test for parametric continuous variables and Mann-Whitney U test for non-parametric continuous variables were used to compare two population means. One-way analysis of variances (ANOVA) for parametric continuous variables and Kruskal-Wallis test for non-parametric continuous variables were used to compare three population means. Paired t test for parametric continuous variables was used to



**Fig. 1.** Measurement of radiological parameters on sagittal plain X-ray. Kyphotic angle (KA) is the angle between the upper endplate of the vertebra above the fractured vertebra and the lower endplate of the vertebra under the fractured vertebra. Segmental vertebral kyphotic angle (SVKA) is the angle between the upper and lower endplate of fractured vertebra, compression ratio (CR) is the percentage of anterior vertebral body compression with respect to the average height of anterior vertebra bodies just above and below to the fractured vertebra ( $1 - [2AH / a + b] \times 100\%$ ). Vertebral body height was measured at the anterior (AH), middle (MH), posterior (PH) borders.

compare two population means where there were paired samples. Spearman's rank correlation was used to analyze the correlation between two non-parametric continuous variables. Repeated measures ANOVA was used to compare the means of functional outcomes changing over time. Statistical analysis was carried out using SPSS version 25.0 software (SPSS Inc., Chicago, IL, USA) and probability values of  $<0.05$  were considered statistically significant.

## RESULTS

### Demographic and clinical data

Analyses were performed on 35 female patients with mean age of  $73.77 \pm 6.71$  years (61 to 88). The mean BMD and body mass index (BMI) were  $-3.36 \pm 0.73$  (-4.8 to -2.0) and  $22.30 \pm 2.62$  (16.9 to 29.0), respectively. There were no statistical significant differences in mean age, BMD, and BMI between group A, B, and C ( $p > 0.05$ ). The severity of TL fracture was presented as the mean TLICS score of  $4.34 \pm 0.48$  (4 to 5; 24 with score 4 and 11 with score 5) and the mean LS score of  $6.54 \pm 1.09$  (4 to 8; 2 with score 4, 3 with score 5, 11 with score 6, 12 with score 7, and 7 with score 8). There were no statistical significant differences in TLICS and LS scores among the

three groups ( $p > 0.05$ ). The reasons responsible for inoperable condition in non-surgical group were as follows : seven of refusal for surgical treatment related to old age, six of cardiac problems, eight of pulmonary problems, two of liver problems, and one of chronic kidney disease. The mean duration of teriparatide administration was  $8.63 \pm 2.32$  months (6 to 12). Demographic and clinical data are summarized in Table 1.

### Radiological outcomes

There were no statistical significant differences in all of radiological parameters at baseline between group A, B, and C ( $p > 0.05$ ). Group A showed no statistical significant differences in all of radiological parameters between baseline and 12-month findings ( $p > 0.05$ ). However, there were structural restorations with statistical significances in SVKA ( $p = 0.005$ ), CR ( $p = 0.007$ ), AH ( $p = 0.009$ ), and MH ( $p = 0.023$ ) of group B and KA ( $p < 0.001$ ), SVKA ( $p < 0.001$ ), CR ( $p < 0.001$ ), AH ( $p < 0.001$ ), and MH ( $p = 0.008$ ) of group C between baseline and 12-month findings. Surgical group (group C) showed statistically significantly better 12-month radiological outcomes in KA ( $p < 0.001$ ), SVKA ( $p = 0.006$ ), CR ( $p = 0.037$ ), AH ( $p = 0.001$ ), MH ( $p = 0.013$ ), and PH ( $p = 0.008$ ) than the non-surgical group (group A+B). The radiological parameters at baseline and 12-month are presented in Table 2. There were

**Table 1.** Demographic and clinical data

Variable	Group A	Group B	Group C	p-value
Age (years)	$76.00 \pm 6.59$ (61 to 88)	$75.17 \pm 6.81$ (65 to 88)	$69.82 \pm 5.36$ (61 to 77)	0.054
BMD	$-3.54 \pm 0.72$ (-4.8 to -2.6)	$-3.38 \pm 0.61$ (-4.3 to -2.5)	$-3.09 \pm 0.88$ (-4.6 to -2.0)	0.377
BMI (kg/m <sup>2</sup> )	$27.37 \pm 2.74$ (16.9 to 23.9)	$22.45 \pm 2.47$ (18.8 to 27.6)	$22.98 \pm 2.66$ (18.7 to 29.0)	0.372
TLICS score	$4.25 \pm 0.45$ (4 to 5)	$4.42 \pm 0.51$ (4 to 5)	$4.36 \pm 0.51$ (4 to 5)	0.700
4/5	9/3	8/4	7/4	
LS score	$6.75 \pm 1.14$ (5 to 8)	$6.08 \pm 1.24$ (4 to 8)	$6.82 \pm 0.75$ (6 to 8)	0.201
4/5/6/7/8	0/2/3/3/4	2/1/4/4/1	0/0/4/5/2	
Reasons of non-surgical treatment				
Refusal due to old age	3	4	-	
Cardiac problems	3	3	-	
Pulmonary problems	5	3	-	
Liver problems	0	2	-	
Chronic kidney disease	1	0	-	
Duration of teriparatide (months)	$8.92 \pm 2.31$ (6 to 12)	$8.33 \pm 2.39$ (6 to 12)	-	0.550

Group A treated by teriparatide only, group B treated by teriparatide plus vertebroplasty, and group C treated by surgical fixation with fusion. *p*-values of  $<0.05$  were considered statistically significant. BMD : bone mineral density, BMI : body mass index, TLICS : thoracolumbar injury classification and severity, LS : load sharing, COPD : chronic obstructive lung disease

statistical significant differences in the changes of radiological parameters including  $\Delta$ KA ( $p<0.001$ ),  $\Delta$ SVKA ( $p=0.010$ ),  $\Delta$ CR ( $p=0.001$ ),  $\Delta$ AH ( $p<0.000$ ),  $\Delta$ MH ( $p<0.000$ ),  $\Delta$ PH ( $p=0.001$ ) among the three groups. The surgical group showed statistically significantly better outcomes than the non-surgical group in  $\Delta$ KA ( $p<0.001$ ),  $\Delta$ AH ( $p=0.001$ ), and  $\Delta$ PH ( $p<0.001$ ). The changes in radiological parameters between baseline and 12-month findings are shown in Table 3. The relationships between the duration of teriparatide administration and the changes in radiological parameters during the

12-month period in group A are presented in Table 4. There were no statistically significant differences between the duration of teriparatide administration and the changes in any radiological parameter ( $p>0.05$ ).

**Functional outcomes**

Functional outcomes were evaluated using VAS and MC from baseline to 12-month. There were statistically significant improvements in VAS between baseline and 12-month findings in group A ( $p<0.001$ ), B ( $p<0.001$ ), and C ( $p<0.001$ ), re-

**Table 2.** Radiological parameters at baseline and 12-month in group A, B, and C

	Group A	Group B	Group C	p-value*	p-value <sup>†</sup>
Baseline					
KA (°)	24.15±9.18	21.56±11.83	20.13±5.73	0.583	0.426
SVKA (°)	18.72±6.89	18.84±6.54	17.93±5.63	0.934	0.713
CR (%)	50.73±19.78	51.29±18.19	46.45±9.13	0.751	0.338
AH (mm)	11.9 ±6.11	12.74±5.19	14.37±2.38	0.515	0.153
MH (mm)	11.48±3.72	12.31±5.59	14.23±1.84	0.270	0.042
PH (mm)	24.61±5.34	27.36±3.60	26.65±2.94	0.252	0.665
12-month					
KA (°)	25.43±11.04	24.61±12.65	9.71±5.57 <sup>‡</sup>	0.001	<0.001
SVKA (°)	17.48±6.13	10.98±5.92 <sup>‡</sup>	9.11±3.55 <sup>‡</sup>	0.002	0.006
CR (%)	52.16±19.12	28.88±18.46 <sup>‡</sup>	25.11±11.93 <sup>‡</sup>	0.001	0.037
AH (mm)	11.61±6.04	16.07±4.24 <sup>‡</sup>	20.86±3.41 <sup>‡</sup>	<0.001	0.001
MH (mm)	10.05±3.43	17.01±3.59 <sup>‡</sup>	17.89±3.53 <sup>‡</sup>	<0.001	0.013
PH (mm)	23.17±5.10	26.52±3.73	28.09±2.15	0.014	0.008

Group A treated by teriparatide only, group B treated by teriparatide plus vertebroplasty, and group C treated by surgical fixation with fusion. \*p-value between group A, B, and C. <sup>†</sup>p-value between group A+B (non-surgical group) and C (surgical group), p-values of <0.05 were considered statistically significant. <sup>‡</sup>There is statistical significant difference compared to baseline ( $p<0.05$ ). KA : kyphotic angle, SVKA : segmental vertebral kyphotic angle, CR : compression ratio, AH : anterior vertebral body height, MH : middle vertebral body height, PH : posterior vertebral body height

**Table 3.** Changes of radiological parameters during 12-month in group A, B, and C

	Group A	Group B	Group C	p-value*	p-value <sup>†</sup>
$\Delta$ KA (°)	1.28±2.96	3.05±7.20	-10.43±6.62	<0.001	<0.001
$\Delta$ SVKA (°)	-1.23±4.04	-7.87±6.98	-8.82±6.94	0.010	0.087
$\Delta$ CR (%)	1.43±1.59	-22.41±22.62	-21.34±14.94	0.001	0.117
$\Delta$ AH (mm)	-0.39±0.16	3.33±4.07	6.53±4.40	<0.001	0.001
$\Delta$ MH (mm)	-1.44±0.96	4.70±5.15	3.66±3.37	<0.001	0.216
$\Delta$ PH (mm)	-1.44±1.37	-0.84±1.92	1.44±2.04	0.001	<0.001

Group A treated by teriparatide only, group B treated by teriparatide plus vertebroplasty, and group C treated by surgical fixation with fusion. \*p-value between group A, B, and C. <sup>†</sup>p-value between group A+B (non-surgical group) and C (surgical group), p-values of <0.05 were considered statistically significant.  $\Delta$  : difference between baseline and 12-month, KA : kyphotic angle, SVKA : segmental vertebral kyphotic angle, CR : compression ratio, AH : anterior vertebral body height, MH : middle vertebral body height, PH : posterior vertebral body height



spectively. There were also statistically significant improvements in MC between baseline and 12-month findings in group A ( $p<0.001$ ), B ( $p<0.001$ ), and C ( $p<0.001$ ), respectively. Functional outcomes, including VAS and MC, changing over time during the 12-month period showed no statistically significant differences among the three groups ( $p>0.05$ ). However, there were statistically significant differences in 1-month VAS ( $p=0.003$ ), 1-month MC ( $p<0.001$ ), and 3-month MC ( $p=0.009$ ) among the three groups. The surgical group showed statistically significant better outcomes than the non-surgical

group in 1-month VAS ( $p=0.007$ ), 1-month MC ( $p=0.032$ ), and 3-month MC ( $p=0.007$ ). The functional outcomes during 12-month period are presented in Table 5.

### Complications during 12-month follow-up period

There were two cases of additional osteoporotic compression fracture in the other vertebral segment. These two cases were identified in group A and not in group B or C. In group C, two cases showed screw loosening and pulled out on the distal segment, and screw removal was performed after the confirmation of bone fusion in one case.

**Table 4.** Relationships between the duration of teriparatide and changes of radiological parameters during 12-month in group A

Changes of radiological parameter	Spearman's rho	p-value
Duration of teriparatide		
Δ KA	0.268	0.399
Δ SVKA	0.007	0.982
Δ CR	-0.261	0.412
Δ AH	0.097	0.765
Δ MH	0.054	0.869
Δ PH	-0.347	0.269

Group A treated by teriparatide only.  $p$ -values of  $<0.05$  were considered statistically significant. Δ : difference between baseline and 12-month, KA : kyphotic angle, SVKA : segmental vertebral kyphotic angle, CR : compression ratio, AH : anterior vertebral body height, MH : middle vertebral body height, PH : posterior vertebral body height

## DISCUSSION

This study presented the effects of teriparatide in the treatment of osteoporotic TL burst fractures in elderly female patients who were being considered for surgery. We focused on the effects of teriparatide on bone healing and union. Originally, intermittent administration of parathyroid hormone or parathyroid hormone-related peptide analogs has been shown to stimulate bone formation more than resorption and decrease the risk of fractures; thus it has approved by the Food and Drug Administration for the treatment of severe osteoporosis<sup>5</sup>. Teriparatide is a human recombinant protein containing the first PTH<sub>1-34</sub><sup>16</sup>. It increases osteoblast activity by di-

**Table 5.** Functional outcomes in group A, B, and C

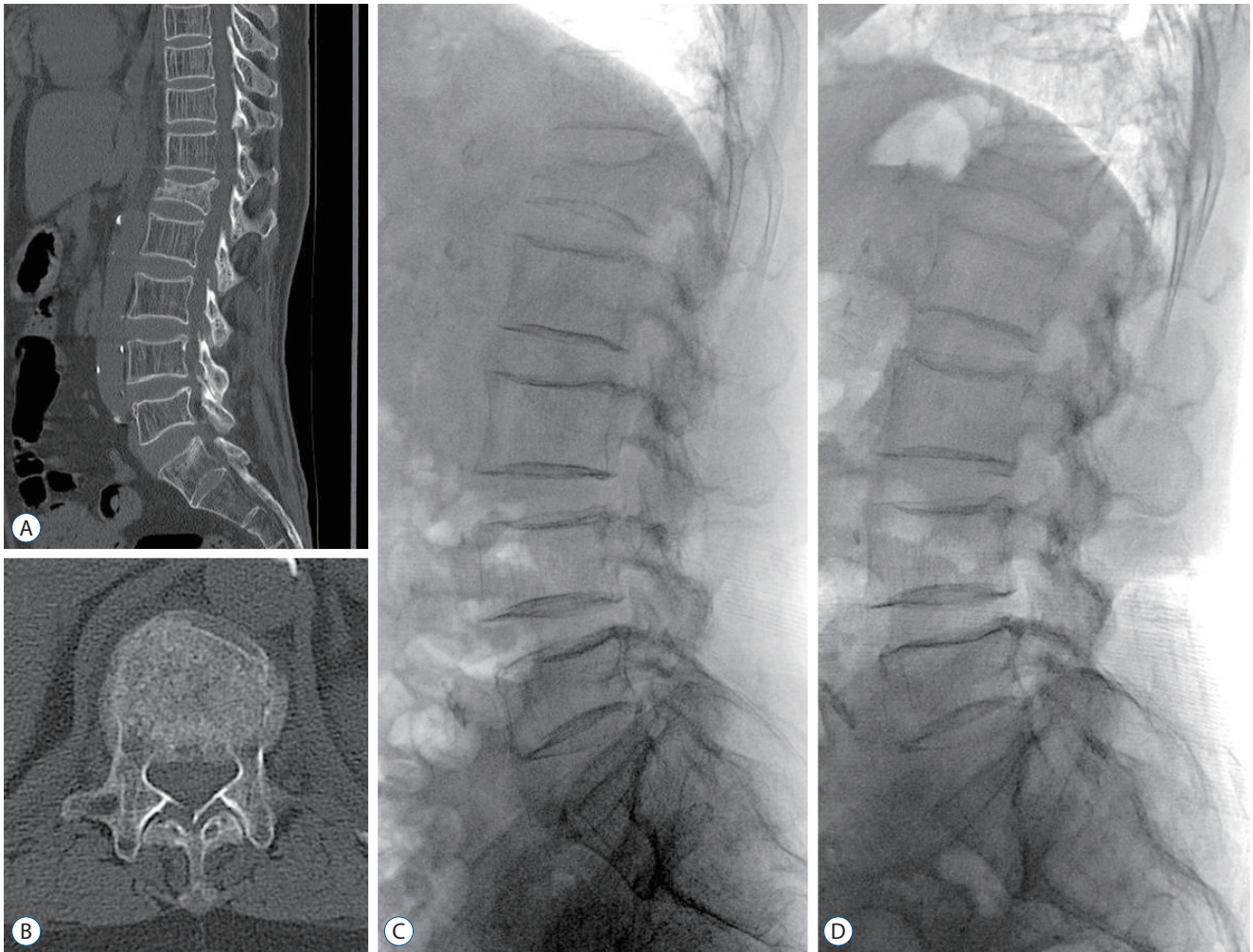
	Group A	Group B	Group C	p-value*	p-value <sup>†</sup>
VAS					
Baseline	6.42±1.73	6.83±0.94	7.18±0.75	0.579	0.219
1-month	5.58±1.62	4.00±1.41	3.36±0.67	0.003	0.007
3-month	4.17±1.85	3.75±1.42	2.91±0.94	0.130	0.056
6-month	2.75±1.60	2.58±1.17	2.54±0.68	0.912	0.784
12-month	2.33±1.44 <sup>‡</sup>	2.25±1.14 <sup>‡</sup>	1.73±0.79 <sup>‡</sup>	0.414	0.184
Macnab classification					
Baseline	1.33±0.49	1.42±0.52	1.09±0.30	0.920	0.045
1-month	1.42±0.52	2.25±0.62	2.36±0.50	<0.001	0.032
3-month	2.00±0.43	2.33±0.65	2.73±0.47	0.009	0.007
6-month	2.67±0.65	2.92±0.67	3.0±0.66	0.175	0.197
12-month	3.08±0.52 <sup>‡</sup>	3.17±0.58 <sup>‡</sup>	3.27±0.47 <sup>‡</sup>	0.110	0.438

Group A treated by teriparatide only, group B treated by teriparatide plus vertebroplasty, and group C treated by surgical fixation with fusion. \* $p$ -value between group A, B, and C. <sup>†</sup> $p$ -value between group A+B (non-surgical group) and C (surgical group).  $p$ -values of  $<0.05$  were considered statistically significant. <sup>‡</sup>There is statistical significant difference compared to baseline ( $p<0.05$ ). VAS : visual analog scale

rectly stimulating osteoblast and decreasing osteoblast apoptosis. Activated osteoblast induces bone formation<sup>6,11</sup>. Stimulation of new bone formation results in positive bone balance at the level of bone multicellular units, and improves bone microarchitecture and quality<sup>19,38</sup>.

In a murine model study, Zhang et al.<sup>39</sup> reported the anabolic effects of teriparatide on bone formation and its non-anabolic effects on bone defect healing. Teriparatide increases angiogenesis (blood vessel diameter, <30  $\mu\text{m}$ ) and decreases arteriogenesis (blood vessel diameter, >30  $\mu\text{m}$ ) and mast cell numbers, thus leading to decreased fibrosis and accelerated bone healing. Mast cells inhibit bone healing by stimulating arteriogenesis associated with fibrotic scarring. Teriparatide

exerts a non-anabolic effect on bone healing by suppressing arteriogenesis and fibrosis secondary to inhibiting mast cells. This non-anabolic effect alters vascularity and inhibits fibrosis to accelerate bone healing and union. In addition, Nishitani et al.<sup>20</sup> demonstrated in canine model that rPTH<sub>1-34</sub> increases callus formation and accelerates bone fusion. Several prior studies have shown the effect of teriparatide on enhanced fusion rates of lumbar arthrodesis in animal models<sup>1,15,27,33</sup>. Other retrospective studies revealed better fusion rates in patients treated with teriparatide than in patients given placebo or oral bisphosphonates<sup>9,12,21</sup>. Based on these previous studies, we applied the effect of teriparatide for bone healing and union instead of surgical treatment of osteoporotic TL



**Fig. 2.** A 70-year-old female patient with a L1 burst fracture (thoracolumbar injury classification and severity score 5 and McCormack's load sharing score 7) was treated conservatively using teriparatide because of severe chronic obstructive pulmonary disease. Sagittal (A) and axial (B) view of computed tomography at baseline shows L1 burst fracture with  $\geq 50\%$  of compression ratio and posterior column involvement. Lateral plain X-ray at 12-month (D) shows similar radiological features compared to baseline (C).

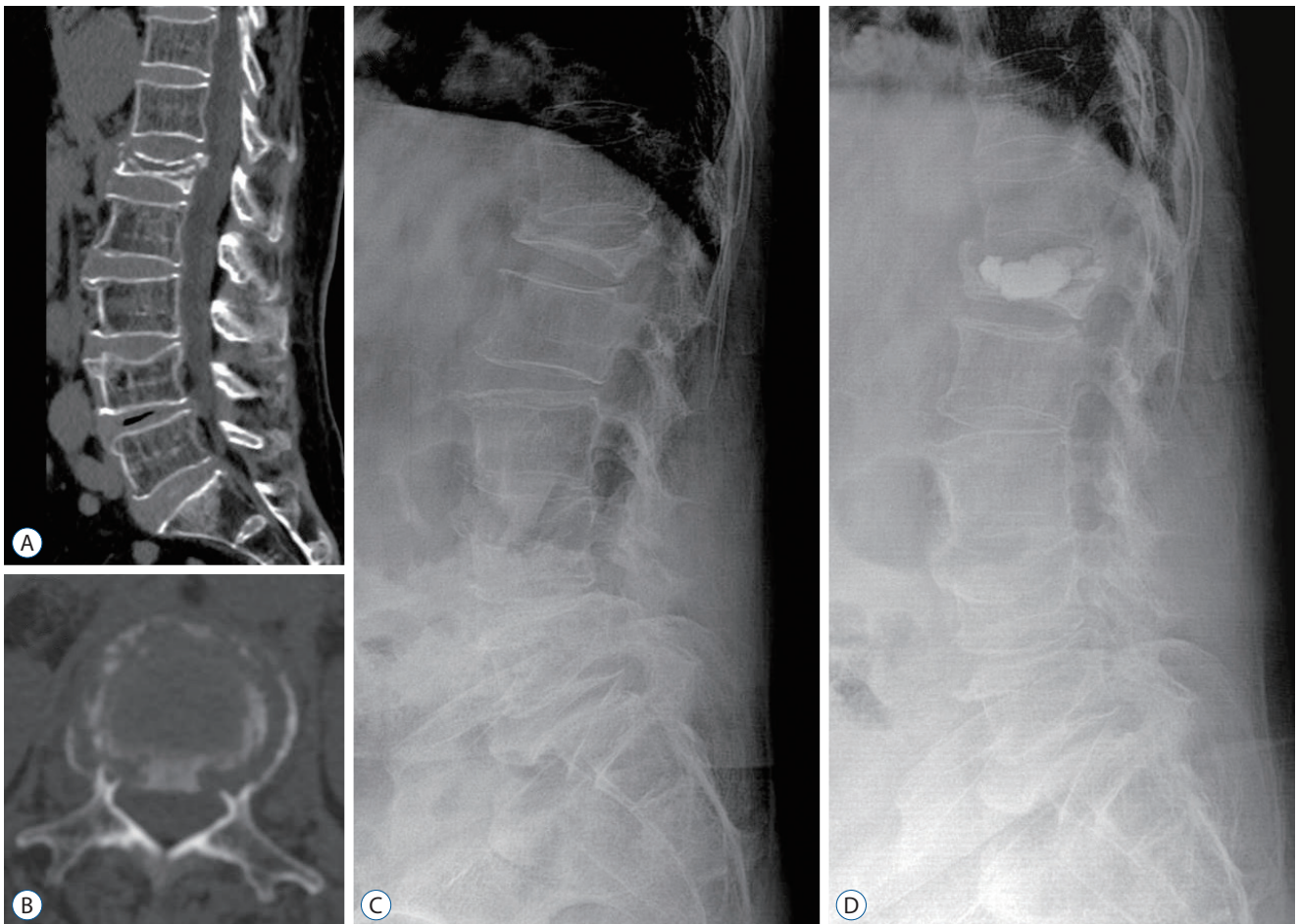


burst fractures in the elderly patients deemed unsuitable for surgery.

There are still controversies in the treatment of TL burst fracture. Surgical treatment of burst fractures has generally been indicated for patients with neurological deficits, kyphotic deformity  $\geq 30^\circ$ , canal compromise  $\geq 50\%$ , and loss of vertebral body height  $\geq 50\%$ <sup>4,10,25</sup>. Farcy et al.<sup>8</sup>) suggested that segmental kyphosis  $\geq 15^\circ$  indicates surgical treatment due to the possibility of progression of kyphosis. Schnee and Ansell<sup>30</sup>) recommended surgical treatment in the patients with neurological deficits or canal compromise  $\geq 40\%$  or kyphosis  $\geq 15^\circ$ . In addition, the decision between surgical and non-surgical treatment when the TLICS score is 4 is also remains controversial compared to clearer indications when the scores is  $\leq 3$

(conservative treatment) or scores  $\geq 5$  (surgery). Given the above, all patients included in this study may be indicated or considered for surgical treatment based on their SVKA, CR, or TLICS scores. Nevertheless, our 24 patients decided to receive non-surgical treatment concerning the higher risks associated with the surgery and patients' general conditions, and there were no significant differences in 12-month functional outcomes compared to group C treated by surgical fixation with fusion.

Burst fracture involves bone destruction of anterior and middle columns causing collapse of vertebral body under axial load; unlike compression fracture involves bone destruction of anterior column. Compared to typical compression fractures leaning anteriorly, burst fractures showed axial load



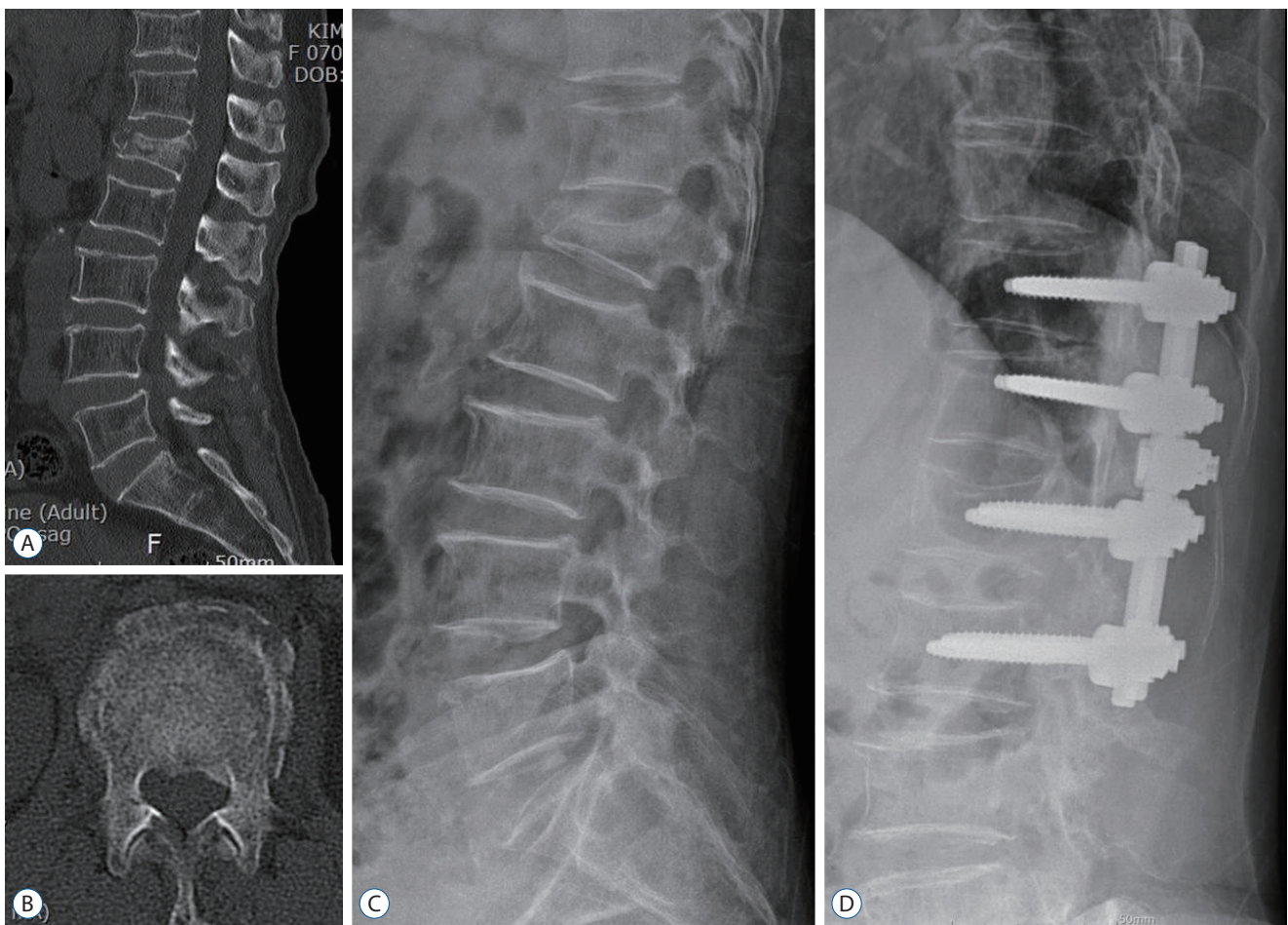
**Fig. 3.** A 78-year-old female patient with a L1 burst fracture (thoracolumbar injury classification and severity score 4 and McCormack's load sharing score 7) was treated conservatively using teriparatide with vertebroplasty because of congestive heart failure and old age. Sagittal (A) and axial (B) view of computed tomography at baseline shows L1 burst fracture with  $\geq 70\%$  of compression ratio and retropulsed bony fragment. Lateral plain X-ray at 12-month (D) shows similar kyphotic angle and restored segmental vertebral kyphotic angle with re-expanded vertebral body after cement filling compared to baseline (C).



without anterior inclination leading to the decreases of AH, MH, and PH over anterior and posterior vertebral body in group A treated with teriparatide only (Fig. 2). However, there were no statistically significant differences in AH, MH, and PH between baseline and 12-month findings. We assume that the collapse of middle and posterior portions of the vertebral body with axial load prevented the deterioration of kyphosis, thus resulting in no significant changes in KA and SVKA between baseline and 12-month findings. These features led to similar 12-month functional outcomes compared to group B and C with structural restorations including KA, SVKA, CR, and vertebral heights. In addition, we think the effects of teriparatide in enhancing bone formation and bone defect healing may be helpful in this process.

The effects of teriparatide for bone healing and union at

various fracture sites with different lengths of teriparatide administration have been described in the literatures. Aspenberg et al.<sup>3)</sup> reported in a prospective, randomized, double-blind study of 102 postmenopausal women that two months of teriparatide administration could enhance fracture repair in distal radius fracture. Peichl et al.<sup>26)</sup> conducted a randomized controlled trial including 65 patients with osteoporotic pubic bone fracture and reported that 24 months of teriparatide administration enhanced fracture healing. Tseng et al.<sup>34)</sup> reported that 18 months of teriparatide administration in the treatment of adjacent vertebral compression fractures after vertebroplasty was better than repeated vertebroplasty combined with anti-resorptive agent. Kim et al.<sup>14)</sup> reported that 2 months of teriparatide administration improved radiographic fracture healing in hip fractures.



**Fig. 4.** A 71-year-old female patient with a L1 burst fracture (thoracolumbar injury classification and severity score 5 and McCormack's load sharing score 7) was treated surgically with screw fixation and posterior fusion. Sagittal (A) and axial (B) view of computed tomography at baseline shows L1 burst fracture with  $\geq 50\%$  of compression ratio and retropulsed bony fragment. Lateral plain X-ray at 12-month (D) shows restored kyphotic, segmental vertebral kyphotic angle, and vertebral heights with bone fusion compared to baseline (C).

Although the duration of teriparatide administration required for bone healing and union reported varies among previous reports; we administered teriparatide for at least 6 months based on the literatures showing successful results<sup>32)</sup>. In our study, teriparatide administration lasted 6–12 months; however, we found no statistically significant correlations between the duration of teriparatide administration and the changes in any radiological parameters at 12-month in the patients treated with teriparatide only. Based on the result, we recommend at least 6 months of teriparatide administration to achieve favorable outcome for bone healing and union for the treatment of osteoporotic TL burst fractures, which is different from the treatment of osteoporosis. We think that the optimal duration of teriparatide administration for vertebral fractures differ from the results of other fracture sites due to differences in the structure and role among the various bones. Vertebrae support the body weight and are the center of motion, and the TL area is especially the junction of lordotic and kyphotic curves, which is vulnerable to trauma and has high incidence of fractures. In our study, teriparatide was used for 6–12 months for the treatment of osteoporotic TL burst fractures and showed favorable radiological and functional outcomes.

There have been some reports of the successful use of vertebroplasty for TL burst fractures, even though vertebroplasty is assumed to be contraindicated in burst fractures with posterior body involvement<sup>23,31)</sup>. In these studies, the authors mentioned the possibility of an alternative method for the treatment of TL burst fractures instead of surgery based on the effect of vertebroplasty in the reduction of pain, early ambulation, and restoration of vertebral deformity. In our results, we confirmed that the effect of additional vertebroplasty within the non-surgical group on the short-term functional recovery was as good as the result of surgical fixation with fusion. Additional vertebroplasty showed the restorations of SVKA and vertebral body height in the radiological parameters (Fig. 3). However, there was no definite effectiveness on KA compared to the result of teriparatide only. The role of bone cement holding the broken bone fragments together is still unclear. Moreover, Oner et al.<sup>22)</sup> reported that bone cement between bone fragments may interfere with bone healing and cause thermal damage.

Our results suggest considering teriparatide as an alternative treatment option for osteoporotic TL burst fractures

based on the favorable radiological and functional outcomes. There were no radiological deteriorations during 12-month period compared to the baseline in the patients treated with teriparatide only, and vertebroplasty performed additional to teriparatide led to partial structural restoration of fractured vertebrae presented as SVKA, CR, AH, and MH. Surgical fixation with fusion showed restoration of all radiological parameters, including KA, SVKA, CR, AH, and MH (Fig. 4). In the functional outcomes, we identified the early recovery of short-term functional outcomes with the surgical treatment or with additional vertebroplasty to teriparatide, although there was no significant difference in 12-month functional outcomes among the three groups. Considering these results, surgical treatment is the best treatment method to achieve ideal structural restoration and early functional recovery for the treatment of osteoporotic TL burst fracture. However, non-surgical treatment using teriparatide can be a considerable alternative option in elderly patients with higher risks associated with general conditions for the surgery. Moreover, the role of vertebroplasty performed additional to teriparatide administration is notable for early functional recovery through pain control in non-surgical treatment.

This study has limitations such as retrospective study design and small number of participants. The best way to identify the effects of teriparatide administration for osteoporotic TL burst fracture is by comparison with untreated patients under the same condition. However, it is not appropriate from practical and ethical standpoints. To overcome these limitations, further studies with large number of participants considering various factors are required to demonstrate the exact effect of teriparatide administration in the treatment of osteoporotic TL burst fracture in elderly female patients.

## CONCLUSION

Non-surgical treatment with teriparatide showed favorable functional outcomes compared to surgical fixation with fusion. Compared with the administration of teriparatide only, performing vertebroplasty in addition to teriparatide administration as well as surgical fixation and fusion were more helpful to improve short-term functional outcomes with structural restoration. We think that teriparatide can be a considered as an alternative treatment option for osteoporotic

TL burst fracture in elderly patients with higher risks associated with surgical treatment owing to their general conditions.

## CONFLICTS OF INTEREST

No potential conflict of interest relevant to this article was reported.

## INFORMED CONSENT

This type of study does not require informed consent.

## AUTHOR CONTRIBUTIONS

Conceptualization : IJ

Data curation : DY, SK, IJ

Formal analysis : DY, IJ

Funding acquisition : IJ

Methodology : IJ

Project administration : SK, IJ

Visualization : IJ

Writing - original draft : DY, IJ

Writing - review & editing : IJ

## ORCID

Dongwoo Yu <https://orcid.org/0000-0003-2100-5452>

Sungho Kim <https://orcid.org/0000-0002-9969-1707>

Ikchan Jeon <https://orcid.org/0000-0002-1293-2724>

## • Acknowledgements

This work was supported by the National Research Foundation of Korea (NRF) grant funded by the Korea government (Ministry of Science [MSIP], ICT & Future Plan [NRF-2019M3E5D1A02068142]).

## References

1. Abe Y, Takahata M, Ito M, Irie K, Abumi K, Minami A : Enhancement of graft bone healing by intermittent administration of human parathyroid hormone (1-34) in a rat spinal arthrodesis model. **Bone** 41 : 775-785, 2007
2. Argoff CE : **Pain management secrets**, ed 4. Philadelphia : Elsevier, 2018
3. Aspenberg P, Genant HK, Johansson T, Nino AJ, See K, Krohn K, et al. : Teriparatide for acceleration of fracture repair in humans: a prospective, randomized, double-blind study of 102 postmenopausal women with distal radial fractures. **J Bone Miner Res** 25 : 404-414, 2010
4. Been HD, Bouma GJ : Comparison of two types of surgery for thoracolumbar burst fractures: combined anterior and posterior stabilisation vs. posterior instrumentation only. **Acta Neurochir (Wien)** 141 : 349-357, 1999
5. Canalis E, Giustina A, Bilezikian JP : Mechanisms of anabolic therapies for osteoporosis. **N Engl J Med** 357 : 905-916, 2007
6. Dobnig H, Turner RT : Evidence that intermittent treatment with parathyroid hormone increases bone formation in adult rats by activation of bone lining cells. **Endocrinology** 136 : 3632-3638, 1995
7. Ensrud KE, Crandall CJ : Osteoporosis. **Ann Intern Med** 167 : ITC17-ITC32, 2017
8. Farcy JP, Weidenbaum M, Glassman SD : Sagittal index in management of thoracolumbar burst fractures. **Spine (Phila Pa 1976)** 15 : 958-965, 1990
9. Inoue G, Ueno M, Nakazawa T, Imura T, Saito W, Uchida K, et al. : Teriparatide increases the insertional torque of pedicle screws during fusion surgery in patients with postmenopausal osteoporosis. **J Neurosurg Spine** 21 : 425-431, 2014
10. Jacobs RR, Casey MP : Surgical management of thoracolumbar spinal injuries. General principles and controversial considerations. **Clin Orthop Relat Res** (189) : 22-35, 1984
11. Jilka RL, Weinstein RS, Bellido T, Roberson P, Parfitt AM, Manolagas SC : Increased bone formation by prevention of osteoblast apoptosis with parathyroid hormone. **J Clin Invest** 104 : 439-446, 1999
12. Kaliya-Perumal AK, Lu ML, Luo CA, Tsai TT, Lai PL, Chen LH, et al. : Retrospective radiological outcome analysis following teriparatide use in elderly patients undergoing multilevel instrumented lumbar fusion surgery. **Medicine (Baltimore)** 96 : e5996, 2017
13. Kim JW, Park SW, Kim YB, Ko MJ : The effect of postoperative use of teriparatide reducing screw loosening in osteoporotic patients. **J Korean Neurosurg Soc** 61 : 494-502, 2018
14. Kim SJ, Park HS, Lee DW, Lee JW : Short-term daily teriparatide improve postoperative functional outcome and fracture healing in unstable intertrochanteric fractures. **Injury** 50 : 1364-1370, 2019
15. Lawrence JP, Ennis F, White AP, Magit D, Polzhofer G, Drespe I, et al. : Effect of daily parathyroid hormone (1-34) on lumbar fusion in a rat model. **Spine J** 6 : 385-390, 2006
16. Liu Y, Levack AE, Marty E, Or O, Samuels BP, Redko M, et al. : Anabolic agents: what is beyond osteoporosis? **Osteoporos Int** 29 : 1009-

- 1022, 2018
17. Macnab I : Negative disc exploration. An analysis of the causes of nerve-root involvement in sixty-eight patients. **J Bone Joint Surg Am** **53** : 891-903, 1971
  18. McCormack T, Karaikovic E, Gaines RW : The load sharing classification of spine fractures. **Spine (Phila Pa 1976)** **19** : 1741-1744, 1994
  19. Neer RM, Arnaud CD, Zanchetta JR, Prince R, Gaich GA, Reginster JY, et al. : Effect of parathyroid hormone (1-34) on fractures and bone mineral density in postmenopausal women with osteoporosis. **N Engl J Med** **344** : 1434-1441, 2001
  20. Nishitani K, Mietus Z, Beck CA, Ito H, Matsuda S, Awad HA, et al. : High dose teriparatide (rPTH1-34) therapy increases callus volume and enhances radiographic healing at 8-weeks in a massive canine femoral allograft model. **PLoS One** **12** : e0185446, 2017
  21. Ohtori S, Orita S, Yamauchi K, Eguchi Y, Aoki Y, Nakamura J, et al. : Does discontinuing teriparatide treatment and replacing it with bisphosphonate maintain the volume of the bone fusion mass after lumbar posterolateral fusion in women with postmenopausal osteoporosis? **Asian Spine J** **11** : 272-277, 2017
  22. Oner FC, Verlaan JJ, Verbout AJ, Dhert WJ : Cement augmentation techniques in traumatic thoracolumbar spine fractures. **Spine (Phila Pa 1976)** **31(11 Suppl)** : S89-S104, 2006
  23. Ozsoy KM, Oktay K, Gezeran Y, Cetinalp NE, Okten AI, Erman T : Percutaneous vertebroplasty for the treatment of osteoporotic thoracolumbar fractures with posterior body involved in elderly patients. **Turk Neurosurg** **29** : 90-94, 2019
  24. Park HJ, Lee SY, Park NH, Shin HG, Chung EC, Rho MH, et al. : Modified Thoracolumbar Injury Classification and Severity Score (TLICS) and its clinical usefulness. **Acta Radiol** **57** : 74-81, 2016
  25. Payer M : Unstable burst fractures of the thoraco-lumbar junction: treatment by posterior bisegmental correction/fixation and staged anterior corpectomy and titanium cage implantation. **Acta Neurochir (Wien)** **148** : 299-306; discussion 306, 2006
  26. Peichl P, Holzer LA, Maier R, Holzer G : Parathyroid hormone 1-84 accelerates fracture-healing in pubic bones of elderly osteoporotic women. **J Bone Joint Surg Am** **93** : 1583-1587, 2011
  27. Qiu Z, Wei L, Liu J, Sochacki KR, Liu X, Bishop C, et al. : Effect of intermittent PTH (1-34) on posterolateral spinal fusion with iliac crest bone graft in an ovariectomized rat model. **Osteoporos Int** **24** : 2693-2700, 2013
  28. Rihn JA, Anderson DT, Harris E, Lawrence J, Jonsson H, Wilsey J, et al. : A review of the TLICS system: a novel, user-friendly thoracolumbar trauma classification system. **Acta Orthop** **79** : 461-466, 2008
  29. Saag KG, Shane E, Boonen S, Marin F, Donley DW, Taylor KA, et al. : Teriparatide or alendronate in glucocorticoid-induced osteoporosis. **N Engl J Med** **357** : 2028-2039, 2007
  30. Schnee CL, Ansell LV : Selection criteria and outcome of operative approaches for thoracolumbar burst fractures with and without neurological deficit. **J Neurosurg** **86** : 48-55, 1997
  31. Shin JJ, Chin DK, Yoon YS : Percutaneous vertebroplasty for the treatment of osteoporotic burst fractures. **Acta Neurochir (Wien)** **151** : 141-148, 2009
  32. Shin WC, Moon NH, Jang JH, Seo HU, Suh KT : A retrospective bicenter comparative study of surgical outcomes of atypical femoral fracture: Potential effect of teriparatide on fracture healing and callus formation. **Bone** **128** : 115033, 2019
  33. Sugiura T, Kashii M, Matsuo Y, Morimoto T, Honda H, Kaito T, et al. : Intermittent administration of teriparatide enhances graft bone healing and accelerates spinal fusion in rats with glucocorticoid-induced osteoporosis. **Spine J** **15** : 298-306, 2015
  34. Tseng YY, Su CH, Lui TN, Yeh YS, Yeh SH : Prospective comparison of the therapeutic effect of teriparatide with that of combined vertebroplasty with antiresorptive agents for the treatment of new-onset adjacent vertebral compression fracture after percutaneous vertebroplasty. **Osteoporos Int** **23** : 1613-1622, 2012
  35. Umekawa M, Takai K, Taniguchi M : Complications of spine surgery in elderly Japanese patients: implications for future of world population aging. **Neurospine** **16** : 780-788, 2019
  36. Vaccaro AR, Lehman RA Jr, Hurlbert RJ, Anderson PA, Harris M, Hedlund R, et al. : A new classification of thoracolumbar injuries: the importance of injury morphology, the integrity of the posterior ligamentous complex, and neurologic status. **Spine (Phila Pa 1976)** **30** : 2325-2333, 2005
  37. Winkler EA, Yue JK, Birk H, Robinson CK, Manley GT, Dhall SS, et al. : Perioperative morbidity and mortality after lumbar trauma in the elderly. **Neurosurg Focus** **39** : E2, 2015
  38. Zhang D, Potty A, Vyas P, Lane J : The role of recombinant PTH in human fracture healing: a systematic review. **J Orthop Trauma** **28** : 57-62, 2014
  39. Zhang L, Wang T, Chang M, Kaiser C, Kim JD, Wu T, et al. : Teriparatide treatment improves bone defect healing via anabolic effects on new bone formation and non-anabolic effects on inhibition of mast cells in a murine cranial window model. **J Bone Miner Res** **32** : 1870-1883, 2017