

Incidental findings of temporomandibular joint osteoarthritis and its variability based on age and sex

Adel Alzahrani¹, Sumit Yadav^{2,*}, Vaibhav Gandhi², Alan G. Lurie¹, Aditya Tadinada¹

¹Division of Oral and Maxillofacial Radiology, Department of Oral Health and Diagnostic Sciences, University of Connecticut School of Dental Medicine, Farmington, CT, USA

²Division of Orthodontics, University of Connecticut School of Dental Medicine, Farmington, CT, USA

ABSTRACT

Purpose: This study investigated the prevalence of temporomandibular joint osteoarthritis (TMJ-OA) using the Research Diagnostic Criteria for Temporomandibular Disorders image analysis criteria, assessed the severity of incidental osteoarthritic changes affecting the TMJ, and evaluated the correlations of sex and age with the prevalence and severity of TMJ-OA.

Materials and Methods: This retrospective study assessed 145 randomly selected cone-beam computed tomography scans (261 TMJs) from the authors' institutional maxillofacial radiology archive following the application of inclusion and exclusion criteria. The criteria described by Ahmad et al. were used to determine whether each TMJ was affected by OA, and the severity of the osteoarthritic changes was scored for each joint based on the method described by Alexiou et al. The chi-square, McNemar, Bhapkar chi-square, and Stuart-Maxwell chi-square tests were applied to evaluate the significance of the relationships between variables (age and sex).

Results: Sixteen TMJs (6.1%) had no OA, 74 (28.6%) were indeterminate for OA, and 171 (65.5%) had OA. Flattening and sclerosis were observed in 86.6% and 12.3% of cases, respectively, while resorption was observed in 7.3% of the joints. Only 21 (8.1%) of the examined TMJs had subchondral cysts. Erosion of the articular eminence was observed in 58 (22.1%) cases, while sclerosis and resorption were found in 68 (25.9%) and 16 (6.1%) TMJs, respectively.

Conclusion: Female patients had a higher prevalence and severity of TMJ-OA than male patients. The prevalence and severity of TMJ-OA increased with age, with peaks in the fifth and seventh decades of life. (*Imaging Sci Dent 2020; 50: 245-53*)

KEY WORDS: Cone-Beam Computed Tomography; Osteoarthritis; Temporomandibular Joint; Temporomandibular Joint Disorders

Introduction

The temporomandibular joint (TMJ) is a diarthrodial joint with articular surfaces formed by the mandibular condyle and the glenoid fossa of the squamous part of the temporal bone.¹ The TMJ is unique because it is the only load-bearing joint that is connected to its contralateral

counterpart by a single bone, the mandible. Furthermore, unlike other synovial joints in the body, which have hyaline cartilage covering the articular surfaces, the articular surfaces of the TMJ are lined by fibrocartilage; therefore, it is thought to be more resistant to degeneration over time.^{2,3}

Abnormal functioning of the TMJ may lead to temporomandibular disorders (TMDs). TMD is an umbrella term that refers to the musculoskeletal disorders that affect the masticatory system.⁴ Several epidemiological studies have examined the prevalence of TMDs in a given population; in a previous study, approximately 41% of the pop-

Received April 1, 2020; Revised May 28, 2020; Accepted June 12, 2020

*Correspondence to : Prof. Sumit Yadav

Division of Orthodontics, University of Connecticut School of Dental Medicine, 263 Farmington Ave., Room L7063, Farmington, CT 06032, USA
Tel) 1-860-679-3584, E-mail) syadav@uchc.edu

Copyright © 2020 by Korean Academy of Oral and Maxillofacial Radiology

This is an Open Access article distributed under the terms of the Creative Commons Attribution Non-Commercial License (<http://creativecommons.org/licenses/by-nc/3.0>) which permits unrestricted non-commercial use, distribution, and reproduction in any medium, provided the original work is properly cited.

Imaging Science in Dentistry · pISSN 2233-7822 eISSN 2233-7830

ulation examined reported at least 1 symptom related to TMD, and 56% of those examined had at least 1 clinical sign. Temporomandibular joint osteoarthritis (TMJ-OA) is a major TMD and is the most common degenerative joint disease.^{1,5} Among individuals with TMDs, 11% have been found to have symptoms of TMJ-OA.⁶ TMJ-OA affects the cartilage, subchondral bone, synovial membrane, and other hard and soft tissues, causing changes such as condylar flattening, sclerosis, resorption, erosion, subcondylar cyst, or osteophyte formation.⁷ Degenerative changes in the form of erosion, sclerosis, or resorption of the articular eminence are also characteristic of TMJ-OA.⁸⁻¹⁰

The results of epidemiological studies of the prevalence of TMJ-OA vary due to the existence of different diagnostic criteria for the condition.¹¹ Benhardt et al.¹² found the prevalence of TMJ-OA on clinical and magnetic resonance imaging examinations to be 25% among individuals 20-49 years old. Schmitter et al.¹³ found a prevalence of TMJ-OA of 70% among individuals aged 73-75 years, although most patients had mild pain and clinical signs of OA were not common. The most notable challenge in assessing the prevalence of TMJ-OA is the widely recognized disparity between objective diagnosis based on imaging evidence and subjective findings in the form of patient reports of pain or disability.^{7,14,15} However, objective diagnoses (such as those made using imaging modalities) provide more reproducible results and facilitate more accurate comparative studies than subjective findings.¹⁵ Although several studies have provided evidence regarding the prevalence of OA of the knee or other joints, very little is known about the prevalence of TMJ-OA.¹⁶ Furthermore, prevalence studies of TMJ based on the clinical assessment of pain and impairment are more complicated than would be expected for other joints because of the complex anatomy of the TMJ and its close proximity to other functional structures, leading to biased and questionable reliability.^{17,18}

According to the Research Diagnostic Criteria for Temporomandibular Disorders (RDC/TMD), numerous scoring options are used to evaluate the condition of the osseous structures of the TMJ associated with OA.¹⁹ The mineralized or calcified components of the TMJ are assessed for features that indicate remodeling or degenerative changes; based on these changes, the joint can be characterized as normal, indeterminate, or affected by osteoarthritis.²⁰

Our objectives were 1) to assess the prevalence of TMJ-OA using the RDC/TMD image analysis criteria and to determine the severity of incidental osteoarthritic changes

affecting the TMJ; and 2) to evaluate the correlations of sex and age with the prevalence and severity of TMJ-OA. The null hypothesis was that sex and age would have no correlation with the prevalence and severity of TMJ-OA.

Materials and Methods

An institutional review board exemption was obtained for the evaluation of cone-beam computed tomography (CBCT) volumes archived at the institution's Department of Oral and Maxillofacial Radiology. This retrospective cross-sectional study involved the review of CBCT scans of patients who underwent imaging for dental implant therapy between August 2011 and August 2015. All CBCT images were de-identified with regard to protected health information by authorized personnel from the department before their use in the study. The CBCT scans were acquired using an Accuitomo CBCT unit (J Morita, Kyoto, Japan; 90 kVp, 7 mA). A standardized protocol including an extended (170 mm × 120 mm) field of view with a 0.250-mm voxel size and a 17.5-second acquisition time was used. All scans were saved in the Digital Imaging in Communications and Medicine (DICOM) 3 format and were evaluated using the third-party CBCT reconstruction software InVivo5 (version 5.3.1) (Anatomage, San Jose, CA, USA).

A total of 145 CBCT scans of dental implant patients were selected from the archive of 200 scans after the application of inclusion and exclusion criteria and a quality assessment. To be included in the study, at least 1 TMJ must have been completely acquired during the scan and be clearly visualized in the field of view. The exclusion criteria consisted of scans with motion artifacts, as well as subjects with known history of TMJ or jaw trauma, TMJ surgery, condylar fracture, systemic arthritis such as rheumatoid arthritis, and other systemic or bone diseases. Patients were grouped by age into categories of 10-19, 20-29, 30-39, 40-49, 50-59, 60-69, 70-79, and 80-89 years for the analysis.

The images were viewed on a standard radiology workstation with 3 monitors designed for viewing picture archiving and communication system (PACS) images, under standardized conditions of ambient light and sound. The images were viewed in the axial, coronal, and sagittal planes in the software's multiplanar reformatted view. Corrected coronal and sagittal cross-sections of the joints were also viewed using the TMJ module of the InVivo dental software. Deviations in the head position during

Table 1. Age and sex distribution of the prevalence of temporomandibular joint osteoarthritis

	Group	Absent	Indeterminate	Present
Age (years)	10-19	0	4	2
	20-29	0	2	4
	30-39	0	2	2
	40-49	1	4	13
	50-59	1	9	33
	61-69	1	9	30
	70-79	1	4	19
	80-89	0	0	4
Sex	Female (n = 91)	4 (4.4%)	15 (16.5%)	72 (79.1%)
	Male (n = 54)	0 (0%)	19 (35.2%)	35 (64.8%)

CBCT acquisition were corrected with the reconstruction tools of the software. To avoid misinterpretation, changes had to be found in at least 2 consecutive sections. To verify the intra-rater reliability, 20 randomly selected scans were evaluated 4 weeks later by the same person with regard to both the prevalence and the severity of TMJ-OA.

The criteria described by Ahmad et al. were used to determine whether the TMJ was affected by OA.¹⁹ Scans were labeled as 1) no OA, 2) indeterminate for OA, or 3) OA. The severity of the osteoarthritic changes was rated for each joint based on the methodology used by Alexiou et al.²⁰ The presence or absence of condylar changes was evaluated with regard to flattening, sclerosis, resorption, and subcondylar cyst, and the severity was evaluated for condylar erosion and osteophyte formation. This method also included an assessment of the mandibular fossa and articular eminence with regard to the presence or absence of erosion, sclerosis, and resorption.²⁰

Each osseous change was cross-tabulated with sex and age using contingency tables, and the chi-square test was applied. For cases in which both joints were included in the scan, the findings were tested to identify whether a statistical difference existed between the joints with regard to the presence of osseous changes. The McNemar test was used for changes with 2 levels (presence or absence), and the Bhapkar chi-square and Stuart-Maxwell chi-square tests were used for changes with more than 2 levels (the severity scale). The Bhapkar chi-square test and Stuart-Maxwell chi-square test were carried out using the MH program (version 1.2; John Uebersax). A *P* value of <0.05 was deemed to indicate statistical significance. Statistical analyses were performed using SAS 9.4 software (SAS Institute, Cary, NC, USA).

Results

A total of 145 CBCT scans (261 TMJs) were included in the study. Of the scans, 116 included both TMJs, 10 included only the left side, and 19 included only the right side. Ninety-one of the scans were of female patients, and 54 were of male patients. The numbers of scans in the respective age groups are summarized in Table 1. No statistically significant difference was observed in the distribution of the osteoarthritic changes between the right and left TMJs of the patients (n = 116) with both TMJs included in the scan. The Cohen kappa value was 0.9 for intra-examiner reliability.

TMJ-OA status

Based on the RDC/TMD image analysis criteria, 16 TMJs (6.1%) had no OA, 74 (28.4%) were indeterminate for OA, and 171 (65.5%) had OA. Among the female patients, 72 (79.1%) patients had OA and 15 (16.5%) patients were indeterminate for OA, whereas 35 (64.8%) of the male patients had OA and 19 (35.2%) were indeterminate for OA (Table 1). A significant correlation was found between sex and the presence of OA (*P* < 0.05), with female patients having a higher prevalence of OA than male patients. The majority of the patients with TMJ-OA were 50-59 or 60-69 years old. Regarding the relationship between TMJ-OA and age, the prevalence of TMJ-OA began to increase in the 40-49-year age group. Specifically, 94.4% patients aged 40-49 years, 97.7% patients aged 50-59 years, 97.5% patients aged 60-69 years, 95.8% patients aged 70-79 years, and 100% patients aged 80-89 years exhibited structural changes indicative of TMJ-OA.

Table 2. Incidence and severity of condylar and articular eminence degeneration (n = 261)

		Incidence	Present	Absent
Condylar degeneration	Flattening		226 (86.6%)	35 (13.4%)
	Sclerosis		32 (12.3%)	229 (87.7%)
	Resorption		19 (7.3%)	242 (92.7%)
	Subchondral cyst		21 (8.1%)	240 (91.9%)
Degenerative changes of the articular eminence	Erosion		58 (22.1%)	204 (77.8%)
	Sclerosis		68 (25.9%)	194 (74.1%)
	Resorption		16 (6.1%)	246 (93.9%)
		Severity	Osteophyte formation	Erosion
Condylar degeneration	Extensive		39 (14.9%)	41 (15.7%)
	Moderate		66 (25.3%)	30 (11.5%)
	Slight		44 (16.9%)	36 (13.8%)
	Absent		112 (42.9%)	154 (59.0%)

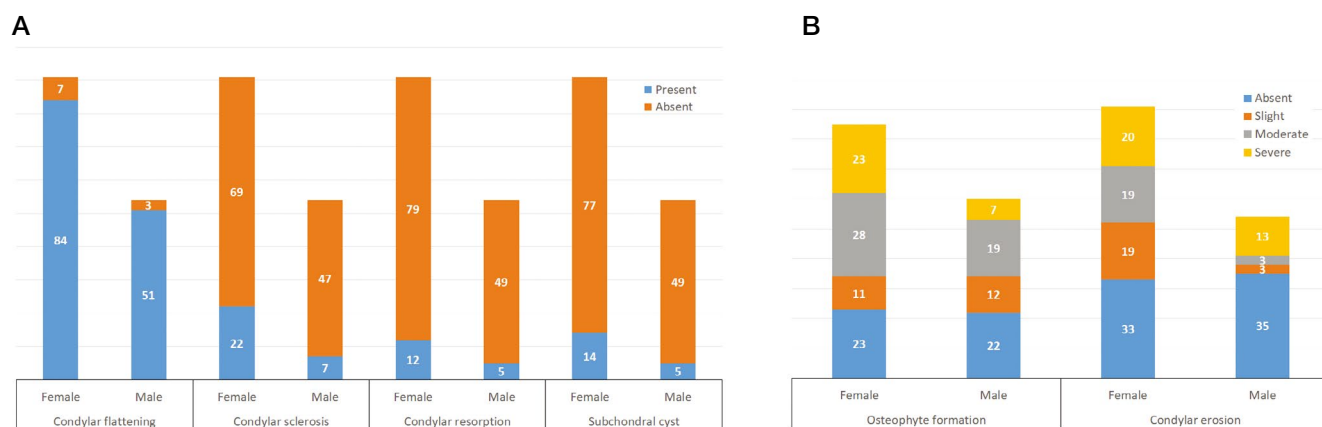


Fig. 1. A. Sex distribution of incidental findings of condylar degeneration. B. Sex distribution of severity of condylar degeneration.

Condylar changes

Condylar flattening and sclerosis were observed in 86.6% (226/261) and 12.3% (32/261) of the TMJs, respectively, while resorption was observed in 7.3% (19/261) of the TMJs. Only 21 (8.1%) of the examined TMJs had subchondral cysts (Table 2). Osteophyte formation was absent in 112 (42.9%) TMJs. Slight and moderate osteophyte formation were observed in 44 (16.9%) and 66 (25.3%) of the examined TMJs, respectively. Furthermore, 39 (14.9%) of the TMJs exhibited severe osteophyte formation. Thirty-six TMJs (13.8%) displayed slight and 30 (11.5%) displayed moderate erosion. Severe erosion was found in only 41 of the TMJs (15.7%). No erosion was observed in 154 (59%) TMJs (Table 2).

Condylar flattening was the most common incidental finding, affecting 92.4% (84/91) of the female patients and

94.4% (51/54) of the male patients (Fig. 1A). The sex distribution of incidental condylar degeneration is reported in Figure 1A. No correlation was found between sex and these changes ($P > 0.05$). A greater severity of osteophyte formation was observed among the female patients (Fig. 1B). A significant correlation was observed between sex and erosion ($P = 0.0009$), in which a higher prevalence of TMJ-OA was observed among the female participants (Fig. 1B).

Condylar flattening was observed in 17 patients aged 40-49 years, 40 patients aged 50-59 years, 37 patients aged 60-69 years, and 22 patients aged 70-79 years (Fig. 2A). The age distribution of incidental condylar degeneration is reported in Figures 2A-D. Severe osteophyte formation was observed in 3 patients aged 40-49 years, 12 patients aged 50-59 years, 6 patients aged 60-69 years, 7 patients

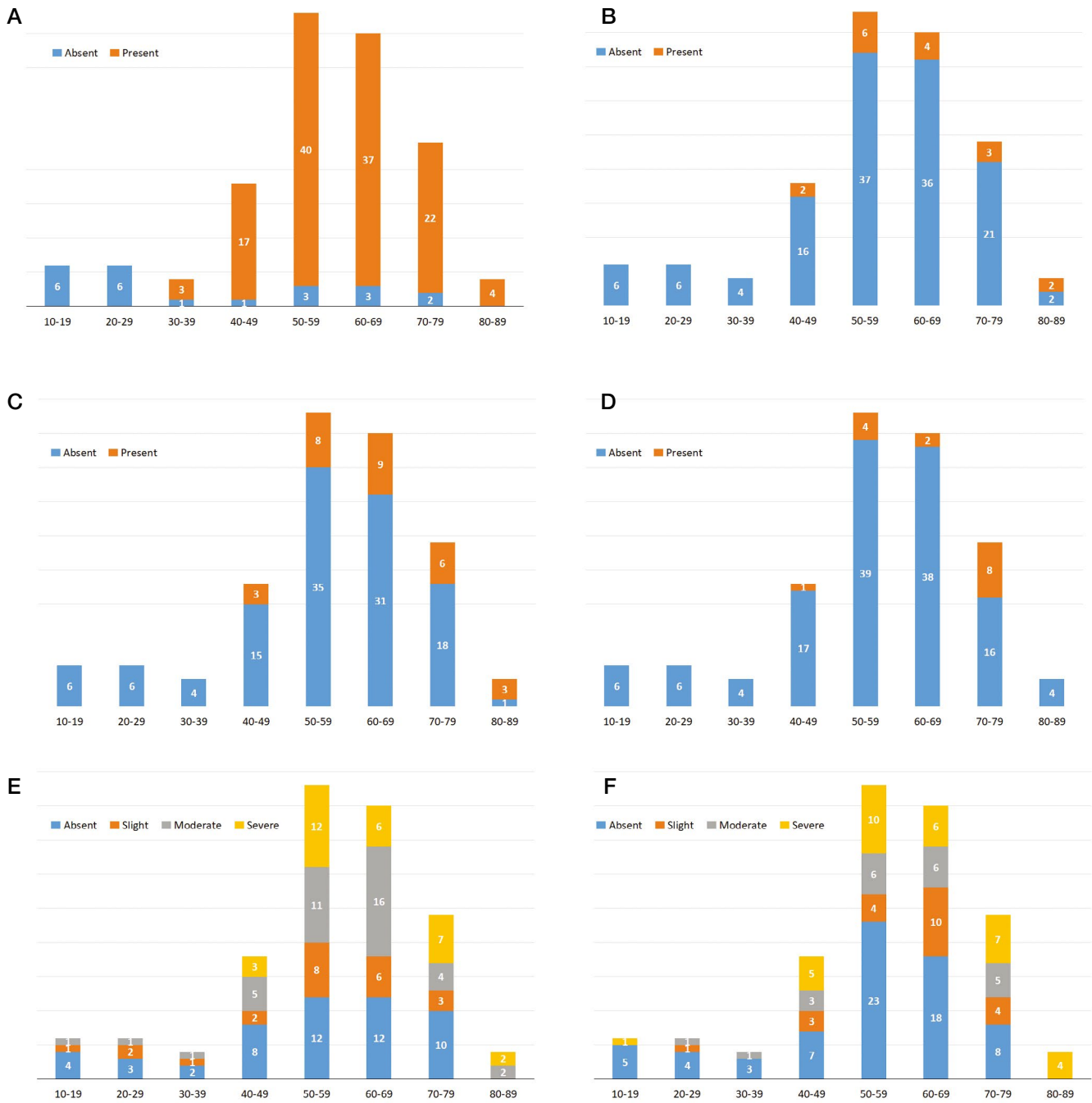

Fig. 2. Age distribution of condylar degeneration on cone-beam computed tomographic images. A. Incidental findings of condylar flattening. B. Incidental findings of condylar resorption. C. Incidental findings of condylar sclerosis. D. Incidental findings of subcondylar cyst. E. Severity of osteophyte formation. F. Severity of condylar erosion.

aged 70-79 years, and 2 patients aged 80-89 years (Fig. 2E). A statistically significant linear association was found between the severity of osteophyte formation and age ($P < 0.05$), suggesting that the severity of osteophyte formation increases with age. Severe condylar erosion was observed in 5 patients aged 40-49 years, 10 patients aged 50-59 years, 6 patients aged 60-69 years, 7 patients aged

70-79 years, and 4 patients aged 80-89 years (Fig. 2F).

Condylar flattening was present in almost all subjects in each age group following 30 years of age; however, condylar sclerosis, resorption, and subcondylar cyst appeared after 40 years of age, with the most cases reported in the age groups of 60-69 years, 50-59 years, and 70-79 years, respectively (Figs. 2A-D). Significant linear associations

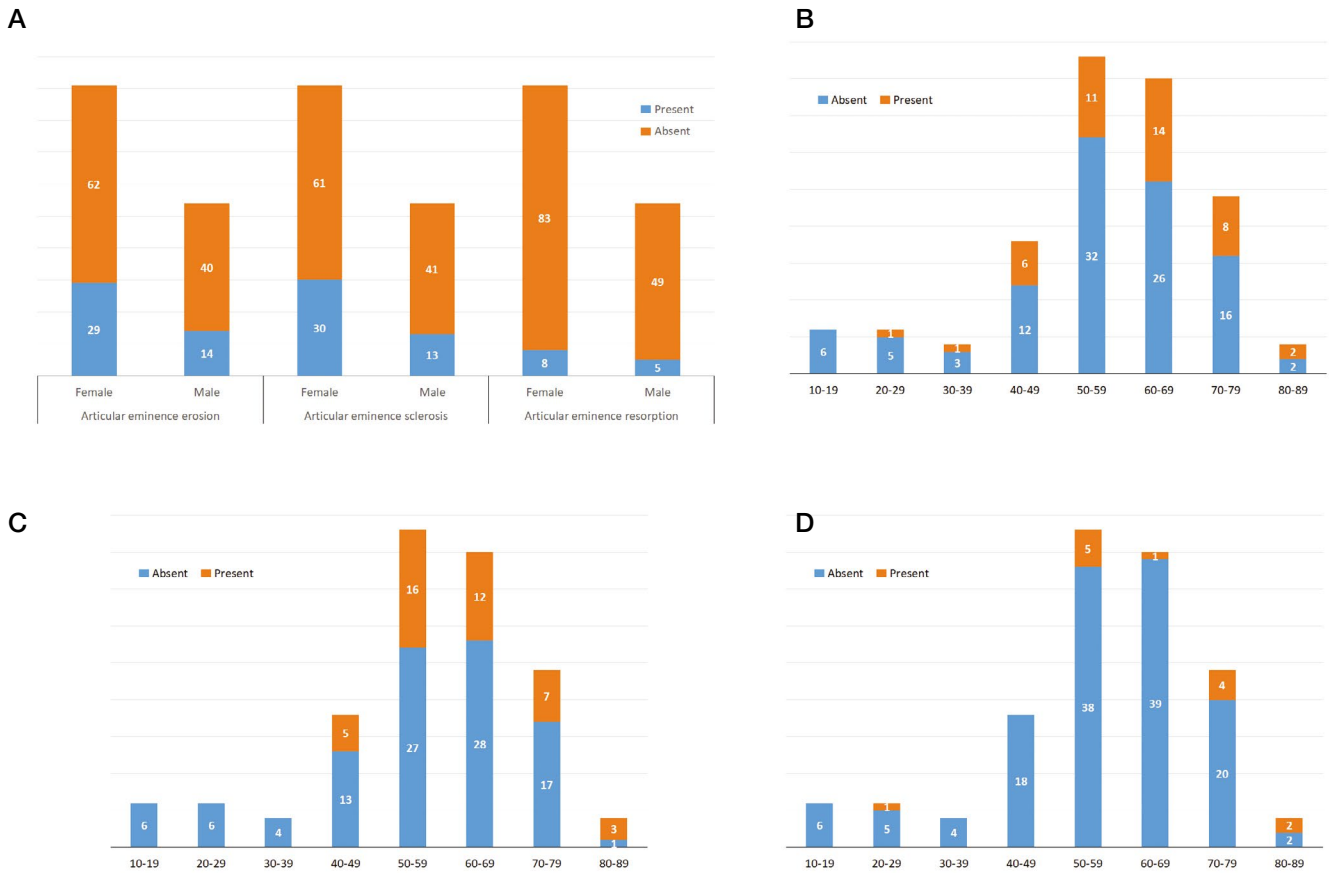


Fig. 3. Incidental findings of articular eminence degeneration. A. Sex distribution of erosion, sclerosis, and resorption. B. Erosion. C. Sclerosis. D. Resorption.

were observed between age and both sclerosis and subchondral cyst presence ($P < 0.05$). In addition, a significant linear association was found between the severity of erosion and age ($P = 0.0086$). The age distributions of these condylar changes are shown in Figure 2.

Osseous changes of the mandibular fossa and articular eminence

Erosion of the articular eminence was observed in 58 (22.1%) of the TMJs, while sclerosis and resorption were found in 68 (25.9%) and 16 (6.1%) of the TMJs, respectively (Table 2). No significant correlation was observed between sex and these degenerative changes of the articular eminence (Fig. 3A). However, a significant correlation was found between age and mandibular fossa sclerosis as well as resorption. Degenerative changes of the articular eminence were predominantly found among the patients between 40 and 89 years old, with the greatest number found in the 50-59-year group ($P < 0.05$) (Figs. 3B-D). Erosion of the articular eminence was observed in 6 patients aged 40-49 years, 11 patients aged 50-59 years, 14 patients aged 60-

69 years, 8 patients aged 70-79 years, and 2 patients aged 80-89 years; in comparison, sclerosis was reported in 5 patients aged 40-49 years, 16 patients aged 50-59 years, 12 patients aged 60-69 years, 7 patients aged 70-79 years, and 3 patients aged 80-89 years (Figs. 3B and C). A linear association was found between the presence of sclerosis and age ($P < 0.05$) (Fig. 3).

Discussion

TMJ-OA is a disease of the bone, cartilage, and supporting tissues of the TMJ and results from both mechanical and biological events that lead to the degeneration of the TMJ. The degeneration not only impacts the cartilage of the TMJ, but also is present in the subchondral bone.²¹ The degeneration leads to osseous erosion, flattening, sclerosis, and occasionally osteophyte formation occurring at the joint margins.

The RDC/TMD, a widely-used diagnostic system for TMD, is a very reliable and comprehensive system for the assessment of OA; however, it does not offer scoring op-

tions for severity. Other methods reported in the literature offer scales for the severity of TMD changes but do not do so specifically for OA.^{20,22,23} For this reason, this study expanded the investigation of the patterns (based on both sex and age) of radiography features associated with the severity of TMJ-OA.

In this study, the overall prevalence of TMJ-OA was reported to be 65.5%, which closely aligns with the reported prevalence of full-body OA of approximately 68.3%. Condylar flattening was the most common finding and was present in 86.6% of the joints, whereas advanced stages of degeneration such as sclerosis, resorption, and subchondral cyst were observed in approximately 10% of the TMJs (Table 2). The RDC/TMD image analysis criteria considered condylar flattening with an absence of other changes to be a sign of remodeling and graded the joints with flattening only as indeterminate for OA.¹⁹ It has been suggested that remodeling, particularly condylar flattening, should be considered to be a functional adaptation.²⁴ Furthermore, based on extensive osteophyte formation (14.9%) and condylar erosion (15.7%), nearly 15% of the patients were determined to have severe TMJ-OA (Table 2).

Amongst the various etiological factors of OA, researchers now agree that age and sex are the most important contributors. According to the present study, the prevalence of TMJ-OA was significantly higher for female than for male participants ($P < 0.05$) (Fig. 1A). Furthermore, this study found a statistically significant difference between male and female patients in terms of osteophyte formation and condylar erosion, parameters used to evaluate the severity of TMJ-OA (Fig. 1B). Female subjects had a significantly higher percentage of moderate and extensive osteophyte formation and condylar erosion than male subjects. Our results are further supported by a study published by Mani et al., who also observed a female predilection of TMJ-OA in their computed tomographic study.²⁵⁻²⁷

TMJ-OA has a female preponderance and occurs mainly after puberty during the reproductive years, suggesting a possible function of female hormones in the disease process.²⁸ Independent studies have shown the byproducts of estrone/17 β -estradiol serving as proinflammatory metabolites in OA synovial cells of the knee joint, the inhibitory effect of estrogen on mandibular condylar chondrocyte proliferation, and the degradation of cartilage and destruction of subchondral bone induced by estrogen in TMJ-OA.^{29,30} Moreover, as found by Wang et al., these effects of estrogen can be inhibited by an estrogen receptor antagonist.³¹ All of these findings strengthen the conclusion that estrogen plays a role in the sexual dimorphism of TMJ-OA.

However, estrogen has also shown an inhibitory effect on the expression of nitric oxide, which constitutes a protective effect by estrogen on the TMJ chondrocyte.³² Therefore, the role of estrogen in TMJ-OA pathogenesis is still inconclusive. Furthermore, in this study, no sex difference was found in terms of the osseous changes in the mandibular fossa and articular eminence.

Another aim of this study was to evaluate age and its correlation with the prevalence and severity of TMJ-OA. The prevalence of this condition peaks in the fifth to the sixth decade of life (Table 1, Figs. 2 and 3). Benhardt et al. found the prevalence of OA of the TMJ on clinical and magnetic resonance imaging examinations to be 25% among individuals 20-49 years old.¹² In comparison, Schmitter et al. found a prevalence of TMJ-OA of 70% among participants 73-75 years old.¹³ The increase in the prevalence and prevalence of OA with age is likely a consequence of cumulative exposure to various risk factors and biological changes that occur with aging that may make a joint less able to cope with stress, such as cartilage thinning, weak muscle strength, decreases in proprioception, and oxidative damage.³³ In the present study, condylar flattening was the most common sign of TMJ-OA and was consistently present in all age groups after 30 years of age (Fig. 2A). Other degenerative changes including condylar resorption, condylar sclerosis, and subcondylar cyst were common findings and were prevalent in the age groups of 50-59 years, 60-69 years, and 70-79 years (Figs. 2B-D). Considering the severity, osteophyte formation and condylar erosion were prominent features from the fourth decade of life onward (Figs. 2E and F). Changes in the articular eminence such as erosion, sclerosis, and resorption were also commonly found during the fourth decade of life and later (Figs. 3B-D).

Chondrocytes are unique cells that may be particularly prone to aging-related changes.³⁴ As one ages, little to no cell division or cell death occurs in normal adult articular cartilage, and no ready supply of progenitor cells appears to exist to replace chondrocytes if they do die.³⁵ Besides limiting cell replication, changes that occur in aging cells can result in the senescent secretory phenotype. This phenotype is characterized by the increased production of cytokines (including interleukin-6 and interleukin-1), matrix metalloproteinases, and growth factors such as epidermal growth factor. The accumulation of cells expressing the senescent secretory phenotype can contribute to tissue aging.^{36,37} All of these contributing factors align with the results of this study, which showed a higher prevalence of TMJ-OA in the fourth decade of life and later.

As is typical for scientific studies, this study had its limitations. First of all, including a nearly equal number of participants in all age groups would have provided a more accurate statistical outcome. Second, considering the specific ethnic or racial demographics of the participants would have provided clearer results indicating the geographic distribution of TMJ-OA. Finally, due to the radiation dose involved, it is challenging to curate CBCT scans of younger individuals unless they are being imaged for a specific reason, such as for management of a syndrome or preparation for a surgical procedure. In the future, it would be valuable to include an adequate number of patients in each group to study the progressive changes in the TMJ complex.

Based on the data evaluated, it can be concluded that women have a significantly higher prevalence and severity of TMJ-OA than men. The present study also found TMJ-OA in 65% of the male population. Additionally, the prevalence and severity of TMJ-OA increased with age, and a progressive increase in the prevalence of TMJ-OA was observed with each decade starting with the fourth decade of life.

Conflicts of Interest: None

References

- Okeson JP. Etiology of functional disturbances in the masticatory system. In: management of temporomandibular disorders and occlusion. 7th ed. St. Louis: Elsevier/Mosby; 2013. p. 102-28.
- Okeson JP. Functional anatomy and biomechanics of the masticatory system. In: management of temporomandibular disorders and occlusion. 7th ed. St. Louis: Elsevier/Mosby; 2013. p. 2-20.
- Wadhwa S, Kapila S. TMJ disorders: future innovations in diagnostics and therapeutics. *J Dent Educ* 2008; 72: 930-47.
- Surya Sudhakar GV, Laxmi MS, Rahman T, Anand DS. Long-term management of temporomandibular joint degenerative changes and osteoarthritis: an attempt. *Clin Cancer Investig J* 2018; 7: 90-6.
- Tanaka E, Detamore MS, Mercuri LG. Degenerative disorders of the temporomandibular joint: etiology, diagnosis, and treatment. *J Dent Res* 2008; 87: 296-307.
- Mejersjö C, Hollender L. Radiography of the temporomandibular joint in female patients with TMJ pain or dysfunction. *Acta Radiol Diagn (Stockh)* 1984; 25: 169-76.
- Song H, Lee JY, Huh K, Park JW. Long-term changes of temporomandibular joint osteoarthritis on computed tomography. *Sci Rep* 2020; 10: 6731.
- Milan SB. Temporomandibular disorders: an evidence-based approach to diagnosis and treatment. In: Laskin DM, Greene CS, Hylander WL. *TMJ osteoarthritis*. Hanover Park, IL: Quintessence Pub.; 2006. p. 105-23.
- de Leeuw R, Boering G, Stegenga B, de Bont LG. Radiographic signs of temporomandibular joint osteoarthrosis and internal derangement 30 years after nonsurgical treatment. *Oral Surg Oral Med Oral Pathol Oral Radiol Endod* 1995; 79: 382-92.
- Gynther GW, Tronje G, Holmlund AB. Radiographic changes in the temporomandibular joint in patients with generalized osteoarthritis and rheumatoid arthritis. *Oral Surg Oral Med Oral Pathol Oral Radiol Endod* 1996; 81: 613-8.
- Kalladka M, Quek S, Heir G, Eliav E, Mupparapu M, Viswanath A. Temporomandibular joint osteoarthritis: diagnosis and long-term conservative management: a topic review. *J Indian Prosthodont Soc* 2014; 14: 6-15.
- Benhardt O, Biffar R, Kocher T, Meyer G. Prevalence and clinical signs of degenerative temporomandibular joint changes validated by magnetic resonance imaging in a non-patient group. *Ann Anat* 2007; 189: 342-6.
- Schmitter M, Essig M, Seneadza V, Balke Z, Schröder J, Rammelsberg P. Prevalence of clinical and radiographic signs of osteoarthrosis of the temporomandibular joint in an older persons community. *Dentomaxillofac Radiol* 2010; 39: 231-4.
- Vrbanović E, Alajbeg IZ. A young patient with temporomandibular joint osteoarthritis: case report. *Acta Stomatol Croat* 2017; 51: 232-9.
- D'Ambrosia RD. Epidemiology of osteoarthritis. *Orthopedics* 2005; 28 (2 Suppl): s201-5.
- Bage E, Bjelle A, Eden S, Svanborg A. Osteoarthritis in the elderly: clinical and radiological findings in 79 and 85 year olds. *Ann Rheum Dis* 1991; 50: 535-9.
- Ohlmann B, Rammelsberg P, Henschel V, Kress B, Gabbert O, Schmitter M. Prediction of TMJ arthralgia according to clinical diagnosis and MRI findings. *Int J Prosthodont* 2006; 19: 333-8.
- John MT, Dworkin SF, Mancl LA. Reliability of clinical temporomandibular disorder diagnoses. *Pain* 2005; 118: 61-9.
- Ahmad M, Hollender L, Anderson Q, Kartha K, Ohrbach R, Truelove EL, et al. Research diagnostic criteria for temporomandibular disorders (RDC/TMD): development of image analysis criteria and examiner reliability for image analysis. *Oral Surg Oral Med Oral Pathol Oral Radiol Endod* 2009; 107: 844-60.
- Alexiou K, Stamatakis H, Tsiklakis K. Evaluation of the severity of temporomandibular joint osteoarthritic changes related to age using cone beam computed tomography. *Dentomaxillofac Radiol* 2009; 38: 141-7.
- Pritzker KP, Gay S, Jimenez SA, Ostergaard K, Pelletier JP, Revell PA, et al. Osteoarthritis cartilage histopathology: grading and staging. *Osteoarthr Cartilage* 2006; 14: 13-29.
- Cevidanes LH, Hajati AK, Paniagua B, Lim PF, Walker DG, Falconet G, et al. Quantification of condylar resorption in temporomandibular joint osteoarthritis. *Oral Surg Oral Med Oral Pathol Oral Radiol Endod* 2010; 110: 110-7.
- Kurita H, Koike T, Narikawa J, Nakatsuka A, Kobayashi H, Kurashina K. Relationship between alteration of horizontal size and bony morphological change in the mandibular condyle. *Dentomaxillofac Radiol* 2003; 32: 355-8.
- Brooks SL, Westesson PL, Eriksson L, Hansson LG, Barsotti

- JB. Prevalence of osseous changes in the temporomandibular joint of asymptomatic persons without internal derangement. *Oral Surg Oral Med Oral Pathol* 1992; 73: 118-22.
25. Massilla Mani F, Sivasubramanian SS. A study of temporomandibular joint osteoarthritis using computed tomographic imaging. *Biomed J* 2016; 39: 201-6.
 26. Emshoff R, Rudisch A. Validity of clinical diagnostic criteria for temporomandibular disorders: clinical versus magnetic resonance imaging diagnosis of temporomandibular joint internal derangement and osteoarthrosis. *Oral Surg Oral Med Oral Pathol Oral Radiol Endod* 2001; 91: 50-5.
 27. Wiberg B, Wänman A. Signs of osteoarthrosis of the temporomandibular joints in young patients: a clinical and radiographic study. *Oral Surg Oral Med Oral Pathol Oral Radiol Endod* 1998; 86: 158-64.
 28. Zhao YP, Zhang ZY, Wu YT, Zhang WL, Ma XC. Investigation of the clinical and radiographic features of osteoarthrosis of the temporomandibular joints in adolescents and young adults. *Oral Surg Oral Med Oral Pathol Oral Radiol Endod* 2011; 111: e27-34.
 29. Schmidt M, Hartung R, Capellino S, Cutolo M, Pfeifer-Leeg A, Straub RH. Estrone/17beta-estradiol conversion to, and tumor necrosis factor inhibition by, estrogen metabolites in synovial cells of patients with rheumatoid arthritis and patients with osteoarthritis. *Arthritis Rheum* 2009; 60: 2913-22.
 30. Chen J, Kamiya Y, Polur I, Xu M, Choi T, Kalajzic Z, et al. Estrogen via estrogen receptor beta partially inhibits mandibular condylar cartilage growth. *Osteoarthr Cartilage* 2014; 22: 1861-8.
 31. Wang XD, Kou XX, Meng Z, Bi RY, Liu Y, Zhang JN, et al. Estrogen aggravates iodoacetate-induced temporomandibular joint osteoarthritis. *J Dent Res* 2013; 92: 918-24.
 32. Hu F, Zhu W, Wang L. MicroRNA-203 up-regulates nitric oxide expression in temporomandibular joint chondrocytes via targeting TRPV4. *Arch Oral Biol* 2013; 58: 192-9.
 33. Zhang Y, Jordan JM. Epidemiology of osteoarthritis. *Clin Geriatr Med* 2010; 26: 355-69.
 34. Shane Anderson A, Loeser RF. Why is osteoarthritis an age-related disease? *Best Pract Res Clin Rheumatol* 2010; 24: 15-26.
 35. Aigner T, Hemmel M, Neureiter D, Gebhard PM, Zeiler G, Kirchner T, et al. Apoptotic cell death is not a widespread phenomenon in normal aging and osteoarthritis human articular knee cartilage: a study of proliferation, programmed cell death (apoptosis), and viability of chondrocytes in normal and osteoarthritic human knee cartilage. *Arthritis Rheum* 2001; 44: 1304-12.
 36. Campisi J. Senescent cells, tumor suppression, and organismal aging: good citizens, bad neighbors. *Cell* 2005; 120: 513-22.
 37. Campisi J, d'Adda di Fagagna F. Cellular senescence: when bad things happen to good cells. *Nat Rev Mol Cell Biol* 2007; 8: 729-40.