

Three-dimensional evaluation of the mandibular symphyseal region in block graft harvesting for dental implants using cone-beam computed tomography

Vaibhav Gandhi¹, Arianna Lowney², Lauren Cardarelli², Sumit Yadav^{1,*}, Aditya Tadinada³

¹Division of Orthodontics, School of Dental Medicine, University of Connecticut Health, Farmington, CT, USA

²School of Dental Medicine, University of Connecticut Health, Farmington, CT, USA

³Division of Oral and Maxillofacial Radiology, School of Dental Medicine, University of Connecticut Health, Farmington, CT, USA

ABSTRACT

Purpose: The purpose of this study was to analyze the quantity and quality of the mandibular anterior alveolar bone in terms of alveolar width, density, and total alveolar height (TAH) based on dental status, gender, and age. Additionally, this study aimed to quantitatively evaluate the available alveolar height for graft harvesting (AHGH) and examine its variability based on the aforementioned factors.

Materials and Methods: This retrospective cone-beam computed tomographic study included a total of 100 subjects. On the basis of gender, dental status, and age, the scans were divided into 3 primary groups and 8 subgroups. The mandibular alveolar width and density were measured 5 mm mesial to the mental foramen bilaterally and at the midline. The TAH was measured at the midline, and the AHGH was measured as the midline distance between 5 mm apical to the root of the canines and 5 mm superior to the lower border.

Results: The mandibular alveolar width was statistically similar between dentulous and edentulous patients ($P > 0.05$). A significantly greater density was observed at the midline in edentulous patients ($P < 0.05$). The TAH was significantly greater in edentulous male patients than in edentulous female patients ($P < 0.05$). Dentulous and male patients had significantly greater AHGH than edentulous and female patients, respectively ($P < 0.05$).

Conclusion: Based on the data evaluated in this study, it can be concluded that the mandibular symphyseal area has adequate bone quality and quantity for bone graft harvesting for dental implant therapy. (*Imaging Sci Dent* 2020; 50: 217-26)

KEY WORDS: Alveolar Bone Grafting; Cone-Beam Computed Tomography; Dental Implants; Mandible

Introduction

Autogenous bone grafts are considered the most reliable and effective option for the repair of bone defects.¹ Autogenous grafting is the only method that harnesses osteoconductive, osteoinductive, and osteogenic properties. It also has success rates exceeding 95% even under conditions of advanced bone resorption in both vertical and horizontal defects; thus, it is considered the gold standard for bone regenerative procedures.^{2,3} Furthermore, autoge-

nous grafts are devoid of any immunological reactions and contain osteoprogenitor cells along with other growth factors. While allogenic bone grafts have grown in popularity, they have been shown to yield poor outcomes, with slower remodeling and action that is limited to osteoconduction.⁴

The quantity of bone required at the recipient site and the biological qualities of the donor bone are 2 of the most important factors to consider before determining the autogenous donor site.⁵ Intraoral donor sites are the most highly preferred bone harvesting locations, not only for the repair of maxillofacial bony defects but also for ridge augmentation and jaw reconstruction procedures. The apparent advantages of local bone grafts are their convenient surgical access and reduced operative and anesthe-

Received March 26, 2020; Revised June 1, 2020; Accepted June 25, 2020

*Correspondence to : Prof. Sumit Yadav

Division of Orthodontics, University of Connecticut Health, 263 Farmington Ave, Room L7063, Farmington, CT 06032, USA
Tel) 1-860-679-3584, E-mail) syadav@uchc.edu

Copyright © 2020 by Korean Academy of Oral and Maxillofacial Radiology

This is an Open Access article distributed under the terms of the Creative Commons Attribution Non-Commercial License (<http://creativecommons.org/licenses/by-nc/3.0>) which permits unrestricted non-commercial use, distribution, and reproduction in any medium, provided the original work is properly cited.

Imaging Science in Dentistry · pISSN 2233-7822 eISSN 2233-7830

sia time, making them ideal for most outpatient implant procedures.⁶ Additionally, intraoral areas may offer other advantages over extraoral donor sites, such as decreased morbidity from graft harvesting and the use of a transoral approach, which does not leave cutaneous scars.⁷

To select an appropriate intraoral donor site, parameters such as the amount, geometry, and type of bone required for alveolar reconstruction, as well as the risk of intraoperative and postoperative complications, should be considered.³ Within the mouth, the mandible tends to present more sources than the maxilla, and the anterior border of the ramus, the mandibular body, or the symphysis are almost always preferred as donor sites.⁸ Mandibular bone grafts result in better-quality bone and a shorter healing period than other methods of bone repair.⁴ Other advantages include minimal resorption (5%-28%),^{9,10} no need for hospitalization (and thus lower cost),⁶ minimal discomfort,¹¹ no alteration in ambulation, and the absence of cutaneous scars.⁷

Compared to other mandibular sites, the symphyseal area has advantages such as easy accessibility, the presence of both cortical and cancellous bone volume (with greater cancellous bone mass), and suitability for bone defects involving up to 1-6 teeth.⁸ Evidence shows that autogenous bone blocks within the retromandibular region only offer 80% of the bone volume available in the chin region.⁵ Furthermore, neurosensory dysfunction, mandibular fractures, and extensive bleeding are all acknowledged risks associated with retromolar grafting sites.^{12,13} One drawback to autogenous bone blocks in the chin region is the high rate of morbidity due to nerve bundle and blood vessel damage.¹⁴ However, technological advances in harvesting, such as the piezoelectric osteotomy technique, have reduced morbidity at this site by decreasing soft tissue damage.^{15,16}

Although the symphyseal region is considered superior to any other intraoral donor site for bone harvesting, very little is known about the influence of dental status, age, and gender on the area available for bone harvesting. The primary objective of this study was to analyze the quantity and quality of the mandibular anterior alveolar bone in terms of the alveolar width, density, and total alveolar height (TAH) based on dental status, gender, and age. This study also aimed to quantitatively evaluate the available alveolar height for graft harvesting (AHGH) and to study its variability based on the aforementioned factors. Furthermore, the bone parameters (alveolar width, density, TAH, and AHGH) of the mandibular symphyseal region were compared between dentulous and edentulous pa-

tients, between male and female patients, and among the 3 age groups. The null hypothesis was that the bone parameters of the mandibular symphyseal region would not be different between dentulous and edentulous patients, between males and females, or among the age groups.

Materials and Methods

An institutional review board exemption was obtained for evaluating cone-beam computed tomography (CBCT) volumes archived by the Department of Oral and Maxillofacial Radiology. This retrospective study involved the review of 100 CBCT scans of patients who had been previously referred to the department. All CBCT images were de-identified with regard to protected health information by authorized department personnel prior to their use in the study. The CBCT scans were acquired using an Accuitomo CBCT unit (J Morita, Kyoto, Japan; 90 kVp, 7 mA). A standardized protocol including an extended (170 × 120 mm) field of view, a 0.250-mm voxel size, and a 17.5-second acquisition time was used. All CBCT scans were evaluated using the third-party CBCT reconstruction software InVivo5 (version 5.3; Anatomage Inc., San Jose, CA, USA).

On the basis of gender, dental status, and age, the scans were divided into the following primary groups: 1) male or female; 2) dentulous or edentulous; and 3) 0-30 years, 31-60 years, or 61 years and older. For the subgroup comparisons, the scans were further allocated into 8 subgroups, as shown in Figure 1. The exclusion criteria were set as follows, as these criteria may impact the mandibular anterior alveolar dimensions and density: 1) congenitally missing teeth, 2) CBCT scans showing supernumerary teeth, enlarged/cystic follicle, or any other pathology, 3) systemic disease affecting the bone, 4) history of tooth extraction for orthodontic purposes, and 5) periodontal disease, history of orthognathic surgery, or any genetic syndromes.

All CBCT volumes were imported into the InVivo5 software. Prior to the initiation of image evaluation, a calibration session was performed by a senior, board-certified oral and maxillofacial radiologist. Subsequently, 25 randomly sampled scans were scored by the senior radiologist and a dental student, and interrater reliability was calculated to calibrate the raters. The rater then reviewed the images on a split-screen dual display monitor (HP Compaq LA2205wg; Hewlett-Packard, Palo Alto, CA, USA) under standardized conditions of ambient light and sound. The investigator had the full capability to evaluate

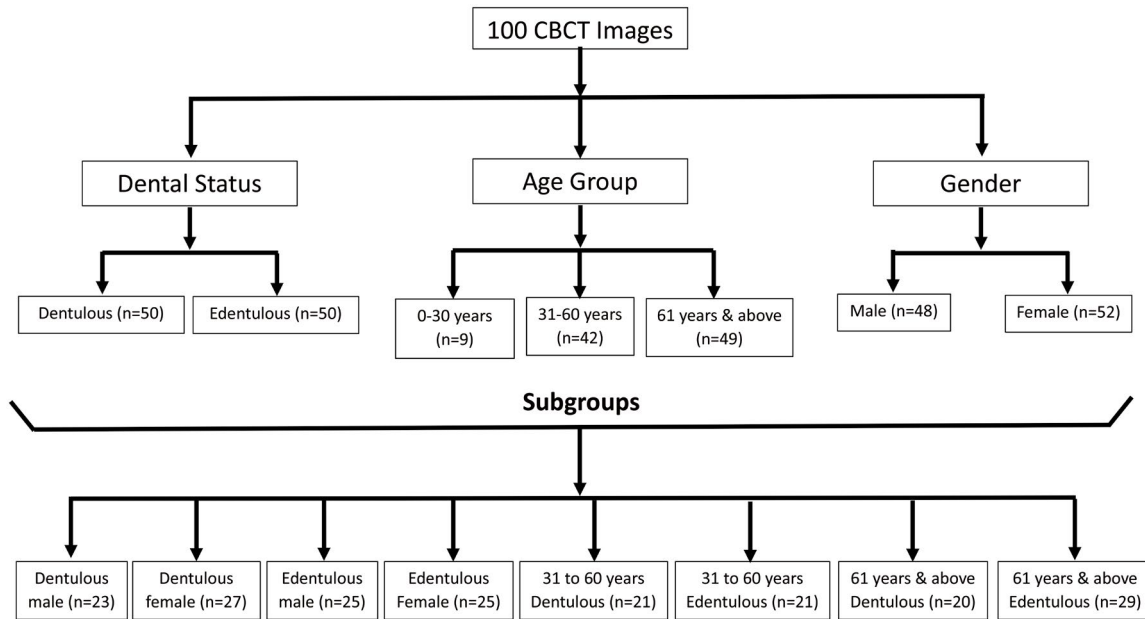


Fig. 1. Distribution of subjects in groups and subgroups based on gender, dental status, and age. CBCT: cone-beam computed tomography.

the volumes in all 3 orthogonal planes and to manipulate the contrast and histogram.

Once the scans were imported into the reconstruction program, they were aligned in the axial plane at the level of the mental foramen. The mandibular alveolar bicortical width was measured using the ruler tool by drawing lines 5 mm mesial to the mental foramen bilaterally and in the mid-symphyseal region (Figs. 2A and B). In the same axial slice, the mean density of mid-alveolar cancellous bone was measured. The selection of a specific pixel for density measurement is highly subjective, and adjacent pixels may have significantly different pixel intensity values. To overcome this individual variation and to provide a standardized method of density measurement, instead of a single pixel, a 3×3 mm square area bilaterally and a 10×5 mm rectangular area in the mid-symphyseal region were used (Fig. 2B). The grayscale density value was measured using the pixel intensity value equivalent to the Hounsfield unit scale in the software program. Next, the TAH for dentulous patients and the ridge height for edentulous patients were measured in the sagittal plane. The maximum distance between the alveolar crest or superior end of the edentulous ridge and the lower border of the mandible at the mid-symphyseal region was considered for this parameter (Fig. 2C). Finally, in the coronal plane at the level of the mid-symphyseal region, the alveolar bone height was measured. Two horizontal lines were drawn, the first 5 mm apical to the canine roots and the

second 5 mm superior to the lower border of the mandible. The distance between these 2 horizontal lines was considered to represent the AHGH (Fig. 2D). To assess intra-examiner reliability, the same person measured the bone parameters on 20 randomly selected scans 4 weeks later.

Statistical analysis

Simple descriptive statistics were used to summarize the data. The mean, standard deviation, percentile distributions, maximum, minimum, and range were computed for the alveolar bone width and density (right, left, and mid-symphyseal region), and TAH and AHGH were reported for each group (dentulous, edentulous, male, female, 0-30 years, 31-60 years, and 61 years and above) and subgroup (Fig. 1). For all of the outcomes, the inter-examiner reliability was assessed using Cronbach alpha values (intraclass correlation coefficients). The 1-sample Kolmogorov-Smirnov test was used to examine the normality of the distribution of bone width and bone height at the different locations. All measurements were normally distributed. For bone width and bone height at the locations, an unpaired samples *t*-test was applied for comparison between the aforementioned groups and subgroups. The same test was applied for the mid-sagittal and coronal vertical alveolar bone height to make comparisons between groups and subgroups. Analysis of variance and Tukey multiple comparisons were used for

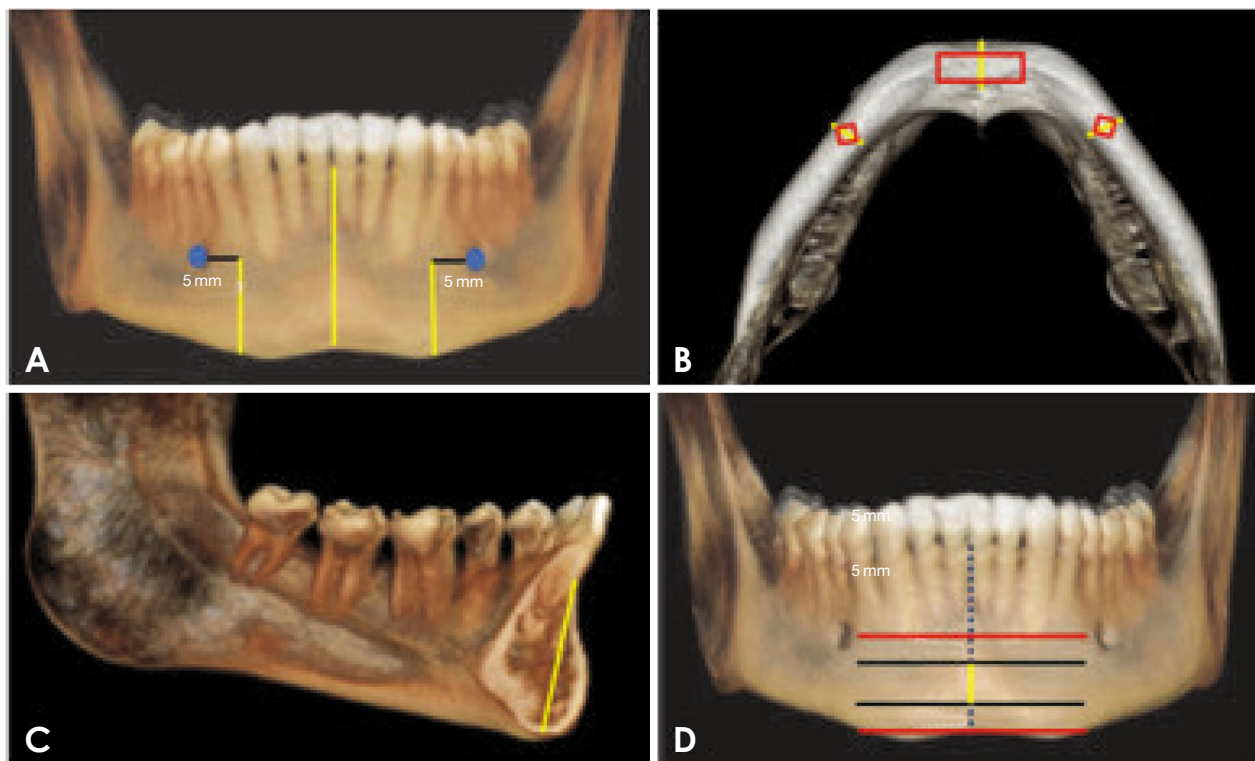


Fig. 2. Diagram shows the methodology used to make bone measurements. A. Figure shows the coronal level chosen in this study to make bicortical width and density measurements: the mid-symphyseal region and 5 mm mesial to the mental foramen bilaterally. B. The mandibular alveolar bicortical width and density are measured in the axial slice as shown. C. The total alveolar width is measured from the lower border of the mandible to the alveolar crest at the midline. D. In the coronal plane at the level of the mid-symphyseal region, the alveolar bone height for graft harvesting is measured. Two horizontal lines are drawn, the first 5 mm apical to the canine roots and the second 5 mm superior to the lower border of the mandible. The distance between these 2 horizontal lines represents the AHGH.

Table 1. Linear regression model for mandibular symphyseal alveolar bone height available for graft harvesting

Variable	Estimate	Standard error	95% confidence interval		P value
			Lower	Upper	
Intercept	-5.51	2.35	-10.18	-0.84	<0.05
Gender	1.39	0.69	0.03	2.75	<0.05
Dental status	7.22	0.64	5.95	8.50	<0.05
Age	-0.93	0.51	-1.93	0.08	0.07
Total alveolar height	0.44	0.08	0.29	0.60	<0.05
Midline width	0.16	0.16	-0.16	0.47	0.33
Left side width	-0.61	0.37	-1.34	0.11	0.10
Right side width	0.70	0.35	0.01	1.39	<0.05

the age groups (0-30 years, 31-60 years, and 61 years and above). Multivariate regression model analyses were used to investigate the factors associated with the variability of AHGH. All statistical tests were 2-sided, and a *P*-value of <0.05 was deemed to indicate statistical significance. Statistical analyses were conducted using GraphPad soft-

ware version 8.1.1 (GraphPad Software Inc., San Diego, CA, USA).

Results

A total of 100 patients were included in the study. This

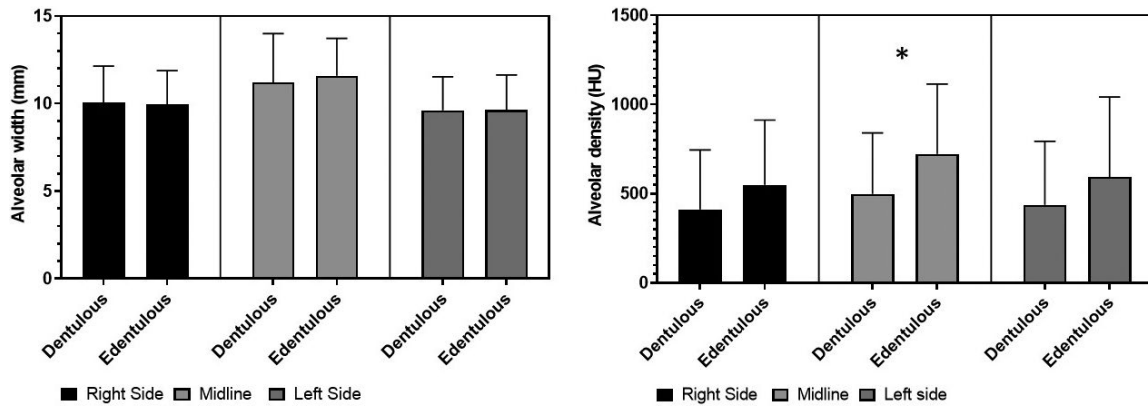


Fig. 3. Comparison of alveolar width and density between dentulous and edentulous subjects. *: $P < 0.05$. HU: Hounsfield units.

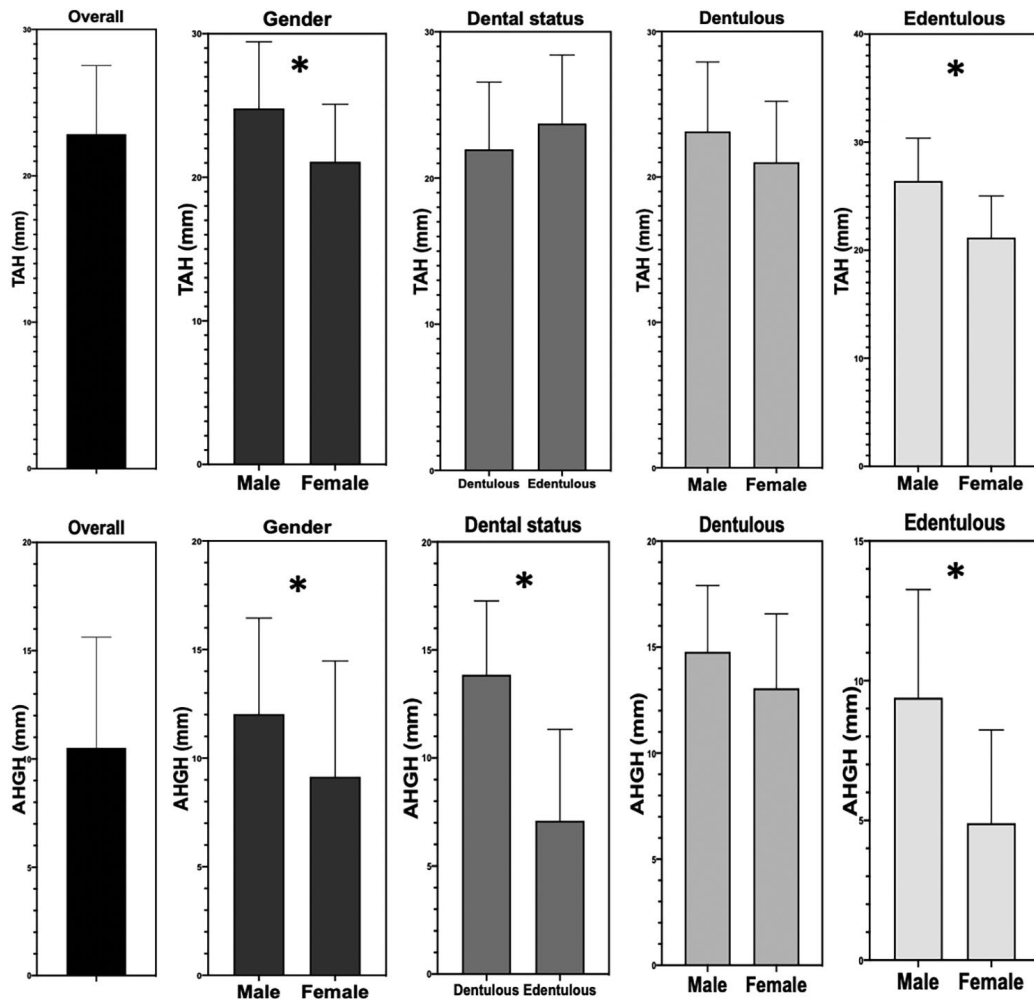


Fig. 4. Comparison of total alveolar height (TAH) and alveolar height available for graft harvesting (AHGH) in the groups and subgroups. *: $P < 0.05$.

included 50 dentulous (mean age, 51.7 ± 19.3 years) and 50 edentulous (mean age, 63.1 ± 13.6 years) patients; 48 men (mean age, 56.3 ± 16.3 years) and 52 women (mean

age, 57.3 ± 17.3 years); and 9, 42, and 49 patients in the age groups of 0-30 years, 31-60 years, and 61 years and above, respectively (Fig. 1). The initial calibration sample

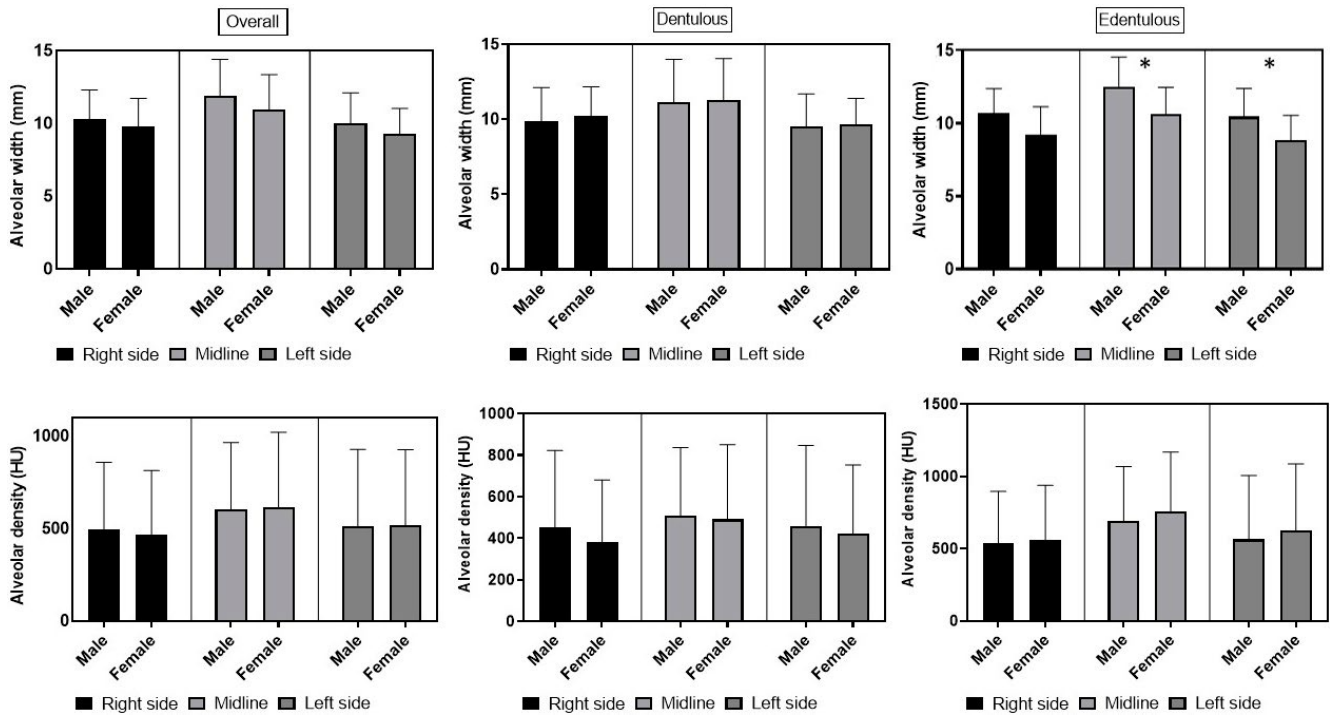


Fig. 5. Comparison of alveolar width and density based on gender for overall, dentulous, and edentulous subjects. *: $P < 0.05$.

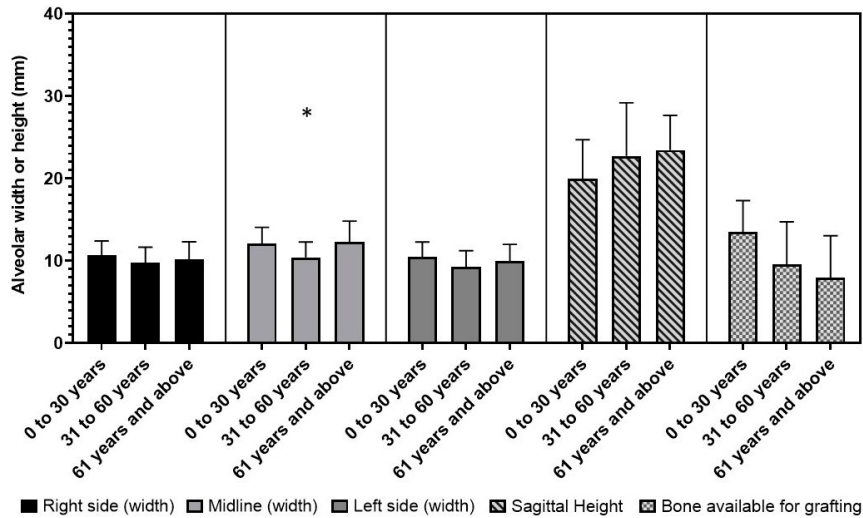


Fig. 6. Comparison of alveolar width, total alveolar height, and alveolar height for graft harvesting among age groups. *: $P < 0.05$.

yielded a high interrater reliability, with a kappa value of 0.89. The Cohen kappa value for intra-examiner reliability was 0.91.

Regarding dental status, descriptive statistics for bone parameters (alveolar width, alveolar density, TAH, and AHGH) are summarized in Table 1 for the dentulous and edentulous subjects. No statistically significant difference in alveolar width or density was observed between den-

tulous and edentulous patients ($P > 0.05$) except in the midline density ($P < 0.05$) (Fig. 3). The TAH was statistically similar between dentulous and edentulous patients ($P > 0.05$) (Fig. 4). However, a statistically significant difference between these groups was observed for the AHGH ($P < 0.05$) (Fig. 4). Dentulous subjects (13.9 ± 3.4 mm) had more bone height available for symphyseal graft harvesting than edentulous subjects (7.1 ± 4.2 mm) (Table 1).

The distribution of bone parameters for male and female subjects is reported in Table 1. The gender comparison showed non-significant differences in alveolar width and density at all 3 locations ($P > 0.05$) (Fig. 5). The TAH was significantly greater in male than female patients ($P < 0.05$) (Fig. 4). Regarding AHGH, a statistically significant difference was also observed between males and females ($P < 0.05$) (Fig. 4). Male patients had a mean of 12 ± 4.4 mm of bone height available for graft harvesting, which was significantly higher than the AHGH of 9.1 ± 5.3 mm observed in female patients (Table 1).

Regarding age, a statistically significant difference in alveolar width among age groups was found only at the midline ($P < 0.05$) (Fig. 6). A statistically significant difference was also observed in alveolar bone density on the right side and at the midline between the age groups of 0-30 years and 31-60 years ($P < 0.05$) (Fig. 7). For the TAH and AHGH, no statistically significant difference was observed between the 3 age groups ($P > 0.05$, Table 1).

Of the 4 subgroups based on dental status and gen-

der, only the edentulous male patients had significantly greater alveolar width at the midline and on the left side

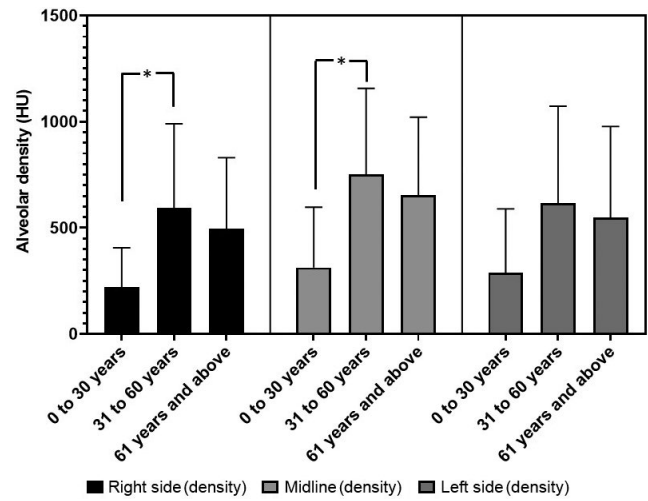


Fig. 7. Comparison of alveolar density among age groups. *: $P < 0.05$.

Table 2. Comparison of mandibular symphyseal bone parameters between different subgroups based on dental status, gender, and age group

Comparison			Mean difference	95% confidence interval		P value
				Lower	Upper	
Male vs female	Alveolar width	Right (dentulous)	-0.3	-2.2	1.6	>0.05
		Midline (dentulous)	-0.1	-2	1.8	>0.05
		Left (dentulous)	-0.2	-2	1.7	>0.05
		Right (edentulous)	0.2	-1.3	1.7	>0.05
		Midline (edentulous)	1.9	0.4	3.4	<0.05
		Left (edentulous)	1.6	0.1	3.2	<0.05
	Alveolar density	Right (dentulous)	70.9	-213	354.7	>0.05
		Midline (dentulous)	17.9	-265.9	301.7	>0.05
		Left (dentulous)	38.4	-245.4	322.2	>0.05
		Right (edentulous)	-21.3	-352.9	310.4	>0.05
		Midline (edentulous)	-62.5	-394.1	269.2	>0.05
		Left (edentulous)	-62.8	-394.5	268.8	>0.05
Total alveolar height	Dentulous	2.1	-1.8	6.1	>0.05	
	Edentulous	5.2	1.3	9.2	<0.05	
Alveolar height available for graft harvesting	Dentulous	1.7	-2.2	5.6	>0.05	
	Edentulous	4.5	0.6	8.4	<0.05	
Dentulous vs edentulous	Total alveolar height	31-60	1.1	-2.5	4.6	>0.05
		61 and above	0.5	-2.3	3.2	>0.05
	Alveolar height available for graft harvesting	31-60	-6.4	-8.8	-4	<0.05
		61 and above	-7	-9.3	-4.7	<0.05

Table 3. Linear regression model for mandibular symphyseal alveolar bone height available for graft harvesting

Variables	Estimate	Standard error	95% confidence interval		P value	
			Lower	Upper		
Intercept	-5.509	2.352	-10.18	-0.84	<0.05	
Gender	1.389	0.685	0.03	2.75	<0.05	
Dental status	7.222	0.642	5.95	8.50	<0.05	
Age	-0.9251	0.505	-1.92	0.08	>0.05	
Total alveolar height	0.4398	0.078	0.28	0.59	<0.05	
Alveolar width	Midline	0.1559	0.159	-0.16	0.48	>0.05
	Left	-0.6134	0.365	-1.34	0.11	>0.05
	Right	0.703	0.347	0.01	1.39	<0.05

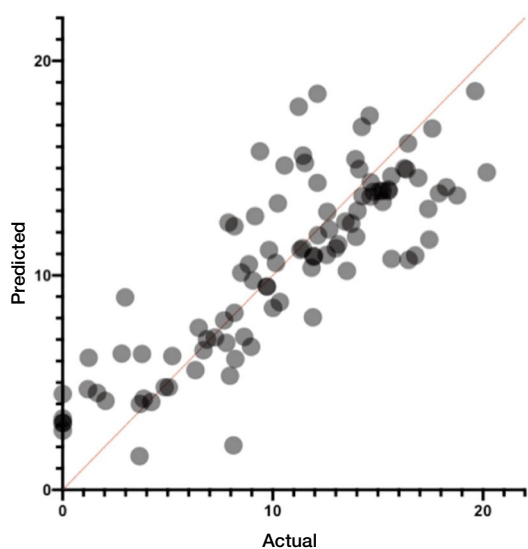


Fig. 8. Actual versus predicted alveolar height available for graft harvesting, as determined with multiple linear regression.

($P < 0.05$, Fig. 5). No significant difference in alveolar density was found for the subgroups based on dental status and gender at any of the 3 locations ($P > 0.05$, Fig. 5, Table 2). Similarly, the comparison of the TAH between edentulous male and female patients revealed a statistically significant difference ($P < 0.05$, Fig. 4). Regarding AHGH, a statistically significant difference was reported between edentulous male and edentulous female patients ($P < 0.05$, Fig. 4, Table 2).

In the comparison of subgroups based on dental status and age, no significant difference in TAH was observed ($P > 0.05$, Table 2). However, a significant difference was reported for the AHGH between 31- to 60-year-old dentulous and edentulous patients ($P < 0.05$) as well as between the 61-year-old and above dentulous and edentulous pa-

tients ($P < 0.05$, Table 2).

The multivariate regression model analyses are presented in Table 3 and Figure 8. Dental status, gender, and TAH were identified as predictors influencing the variability of AHGH (Fig. 8).

Discussion

A review of the literature provided evidence about the quantification of symphyseal bone grafts in adult human cadavers. However, none of the available studies included data regarding an exact map of the symphyseal area that could be used to qualitatively and quantitatively evaluate the safe zone for bone graft harvesting. Furthermore, no study is currently available that provides data regarding variation in the symphyseal dimensions based on dental status, gender, and age, which could contribute to decision-making algorithms for surgical procedures. This study was conducted to close the gap in knowledge regarding the variation in the alveolar bone dimensions at the symphysis, with the thought that this information can be used to accurately and reliably predict the outcome of the surgical intervention. The null hypothesis of this study was rejected, as male and edentulous male patients had significantly greater TAH and AHGH in the mandibular symphyseal region than female and edentulous female patients, respectively. Furthermore, dentulous patients had significantly greater AHGH than edentulous patients.

Although the mandibular symphyseal region is considered an easily accessible donor site with a relatively high volume of cancellous as well as cortical bone, it is not free of postoperative complications. Pain, discomfort, temporary or permanent sensory alteration of the skin and mucosa, and loss of dental vitality are a few of the poten-

tial complications of harvesting a symphyseal bone graft.⁸

The rate of temporary sensory disturbance is reported to be in the range of 9.6% to 46.6%, while that of permanent sensory alteration is in the range of 0% to 51.7%.^{11,17-20} Before performing any surgical procedure in the proximity of the mental foramen, it is important to understand not only the location, but also the trajectory of the mental nerve as it emerges from the mandibular bone. The anterior loop of the mental nerve or posterior emergence is the most common trajectory by which the mental nerve emerges from the mental foramen.²¹ Evidence suggests that the extension of the anterior loop ranges from 1.50 to 2.40 mm.²²⁻²⁴ Thus, misunderstanding of the area could inadvertently increase the risk of damaging this portion of the nerve, leading to transient or persistent loss of sensation in the chin region. To avoid these negative consequences, measurements were made 5 mm anterior to the mental foramen to provide leeway for the possibility of the anterior loop and to avoid damage to the mental nerve.

Loss of dental sensation and pulpal necrosis are other potential complications associated with the harvest of symphyseal bone. The rate of loss of dental sensation observed in published research varies, with a range of 2 patients to 37 patients.^{11,17-19} However, no plausible reason for the loss of dental sensation has been identified in the literature. Furthermore, Cordaro et al.¹⁷ considered 4 mm to be a sufficient safety margin to avoid this problem, whereas other studies left a safety margin of 5 mm. This study considered 5 mm from the apex of the canine to be a safe zone for an osteotomy cut in the harvest of symphyseal bone grafts.

The mandibular symphysis can be a suitable donor site for ridge augmentation procedures before or in conjunction with implant placement. Even after leaving a 3-mm width of lingual cortical bone, according to this study, a bone block with minimum dimensions of 6.6 mm (buccolingual) × 7.1 mm (vertical) can be harvested in an edentulous patient. For dentulous patients, a bone block with minimum dimensions of 6.6 mm (buccolingual) × 13.9 mm (vertical) can be harvested for reconstructive surgery (Fig. 4, Table 1). Furthermore, the alveolar bone density was higher in the edentulous participants than in the dentulous patients; however, a statistically significant difference was found only at the mid-symphyseal region (Fig. 3, Table 1). Thus, during the planning of reconstructive surgery using a mandibular symphyseal donor site, these dimensions may prove useful in avoiding possible complications in both dentulous and edentulous patients.

Alterations in the size and shape of the jawbones due to bone remodeling occur throughout the adult lifespan.²⁵ In the present study, male patients (12 ± 4.4 mm) had statistically significant greater bone height than female patients (9.1 ± 5.3 mm) (Fig. 4). However, only edentulous male subjects had statistically significantly greater AHGH than edentulous female patients (Fig. 4). Similarly, Panchalbai²⁶ found a greater degree of mandibular ridge resorption in older female patients than in male patients, a phenomenon that may have been due to the age of the patients. The average age of the edentulous female patients was 63.1 ± 13.6 years; therefore, they were likely in the postmenopausal phase and might have experienced more bone loss due to estrogen deficiency, perhaps ultimately leading to mandibular ridge resorption.^{25,27,28}

A limitation of this study was the use of a single site examination, as well as the fact that the measurements were taken by a single examiner, albeit after calibration with a senior radiologist. Overall, the mandibular symphyseal area appears to be an appealing site for bone block harvesting for dental implant placement. In addition, the buccolingual width and shape of the bone are key parameters to understand to avoid complications. The key findings from this study that may add value to clinical practice are as follows. First, the mandibular anterior alveolar width was statistically similar between dentulous and edentulous patients, while significantly greater density was observed at the midline in edentulous patients. Second, the TAH was significantly higher in male - and specifically, edentulous male - patients than in female and edentulous female patients, respectively. Third, dentulous and male patients had significantly greater AHGH than edentulous and female patients, respectively. In addition, dentulous male and edentulous male patients had greater AHGH than dentulous female and edentulous female patients, respectively. However, the difference was statistically significant only for the edentulous subgroup.

Based on the scans evaluated, it can be concluded that the mandibular symphyseal area has adequate bone quality and quantity for the harvest of bone grafts for dental implant therapy. According to this study, the quality and quantity of the bone, the buccolingual width, and the curvature of the mandible are key considerations for harvesting bone grafts in this area.

References

1. Jensen OT, Kuhlke L, Bedard JF, White D. Alveolar segmental sandwich osteotomy for anterior maxillary vertical aug-

- mentation prior to implant placement. *J Oral Maxillofac Surg* 2006; 64: 290-6.
2. Nkenke E, Neukam FW. Autogenous bone harvesting and grafting in advanced jaw resorption: morbidity, resorption and implant survival. *Eur J Oral Implantol* 2014; 7 Suppl 2: S203-17.
 3. Sakkas A, Wilde F, Heufelder M, Winter K, Schramm A. Autogenous bone grafts in oral implantology - is it still a "gold standard"? A consecutive review of 279 patients with 456 clinical procedures. *Int J Implant Dent* 2017; 3: 23.
 4. Spin-Neto R, Stavropoulos A, Dias Pereira LA, Marcantonio E Jr, Wenzel A. Fate of autologous and fresh-frozen allogeneic block bone grafts used for ridge augmentation. A CBCT-based analysis. *Clin Oral Implants Res* 2013; 24: 167-73.
 5. Santhanakrishnan M, Rangarao S. Mandibular tori: a source of autogenous bone graft. *J Indian Soc Periodontol* 2014; 18: 767-71.
 6. Garg V, Giraddi GB, Roy S. Comparison of efficacy of mandible and iliac bone as autogenous bone graft for orbital floor reconstruction. *J Maxillofac Oral Surg* 2015; 14: 291-8.
 7. Di Bari R, Coronelli R, Cicconetti A. Radiographic evaluation of the symphysis menti as a donor site for an autologous bone graft in pre-implant surgery. *Imaging Sci Dent* 2013; 43: 135-43.
 8. Reininger D, Cobo-Vázquez C, Monteserín-Matesanz M, López-Quiles J. Complications in the use of the mandibular body, ramus and symphysis as donor sites in bone graft surgery. A systematic review. *Med Oral Patol Oral Cir Bucal* 2016; 21: e241-9.
 9. Gultekin BA, Bedeloglu E, Kose TE, Mijiritsky E. Comparison of bone resorption rates after intraoral block bone and guided bone regeneration augmentation for the reconstruction of horizontally deficient maxillary alveolar ridges. *Biomed Res Int* 2016; 2016: 4987437.
 10. Lumetti S, Galli C, Manfredi E, Consolo U, Marchetti C, Ghiacci G, et al. Correlation between density and resorption of fresh-frozen and autogenous bone grafts. *Biomed Res Int* 2014; 2014: 508328.
 11. Reininger D, Cobo-Vázquez C, Rosenberg B, López-Quiles J. Alternative intraoral donor sites to the chin and mandibular body-ramus. *J Clin Exp Dent* 2017; 9: e1474-81.
 12. von Arx T, Kurt B. Endoral donor bone removal for autografts. A comparative clinical study of donor sites in the chin area and the retromolar region. *Schweiz Monatsschr Zahnmed* 1998; 108: 446-59.
 13. Nogami S, Yamauchi K, Shiiba S, Kataoka Y, Hirayama B, Takahashi T. Evaluation of the treatment modalities for neurosensory disturbances of the inferior alveolar nerve following retromolar bone harvesting for bone augmentation. *Pain Med* 2015; 16: 501-12.
 14. Zeltner M, Flückiger LB, Hämmerle CH, Hüsler J, Benic GI. Volumetric analysis of chin and mandibular retromolar region as donor sites for cortico-cancellous bone blocks. *Clin Oral Implants Res* 2016; 27: 999-1004.
 15. Sohn DS, Ahn MR, Lee WH, Yeo DS, Lim SY. Piezoelectric osteotomy for intraoral harvesting of bone blocks. *Int J Periodontics Restorative Dent* 2007; 27: 127-31.
 16. Pereira CC, Gealh WC, Meorin-Nogueira L, Garcia-Júnior IR, Okamoto R. Piezosurgery applied to implant dentistry: clinical and biological aspects. *J Oral Implantol* 2014; 40: 401-8.
 17. Cordaro L, Torsello F, Miuccio MT, di Torresanto VM, Eliopoulos D. Mandibular bone harvesting for alveolar reconstruction and implant placement: subjective and objective cross-sectional evaluation of donor and recipient site up to 4 years. *Clin Oral Implants Res* 2011; 22: 1320-6.
 18. Andersson L. Patient self-evaluation of intra-oral bone grafting treatment to the maxillary frontal region. *Dent Traumatol* 2008; 24: 164-9.
 19. Raghoebar GM, Meijndert L, Kalk WW, Vissink A. Morbidity of mandibular bone harvesting: a comparative study. *Int J Oral Maxillofac Implants* 2007; 22: 359-65.
 20. Silva FM, Cortez AL, Moreira RW, Mazzonetto R. Complications of intraoral donor site for bone grafting prior to implant placement. *Implant Dent* 2006; 15: 420-6.
 21. Velasco-Torres M, Padiál-Molina M, Avila-Ortiz G, Garcia-Delgado R, Catena A, Galindo-Moreno P. Inferior alveolar nerve trajectory, mental foramen location and incidence of mental nerve anterior loop. *Med Oral Patol Oral Cir Bucal* 2017; 22: e630-5.
 22. Hu KS, Yun HS, Hur MS, Kwon HJ, Abe S, Kim HJ. Branching patterns and intraosseous course of the mental nerve. *J Oral Maxillofac Surg* 2007; 65: 2288-94.
 23. Rosa MB, Sotto-Maior BS, Machado Vde C, Francischone CE. Retrospective study of the anterior loop of the inferior alveolar nerve and the incisive canal using cone beam computed tomography. *Int J Oral Maxillofac Implants* 2013; 28: 388-92.
 24. Sahman H, Sisman Y. Anterior loop of the inferior alveolar canal: a cone-beam computerized tomography study of 494 cases. *J Oral Implantol* 2016; 42: 333-6.
 25. Jayam R, Annigeri R, Rao B, Gadiputi S, Gadiputi D. Panoramic study of mandibular basal bone height. *J Orofac Sci* 2015; 7: 7-10.
 26. Panchbhai AS. Quantitative estimation of vertical heights of maxillary and mandibular jawbones in elderly dentate and edentulous subjects. *Spec Care Dentist* 2013; 33: 62-9.
 27. Güler AU, Sumer M, Sumer P, Biçer I. The evaluation of vertical heights of maxillary and mandibular bones and the location of anatomic landmarks in panoramic radiographs of edentulous patients for implant dentistry. *J Oral Rehabil* 2005; 32: 741-6.
 28. Sağlam AA. The vertical heights of maxillary and mandibular bones in panoramic radiographs of dentate and edentulous subjects. *Quintessence Int* 2002; 33: 433-8.