

Accuracy and Precision of Three-dimensional Imaging System of Children's Facial Soft Tissue

Kyunghwa Choi¹, Misun Kim^{1,2}, Koeun Lee³, Okhyung Nam^{2,3}, Hyo-seol Lee^{2,3}, Sungchul Choi^{2,3}, Kwangchul Kim^{1,2}

¹*Department of Pediatric Dentistry, Kyung Hee University, Dental Hospital at Gangdong*

²*Department of Pediatric Dentistry, School of Dentistry, Kyung Hee University*

³*Department of Pediatric Dentistry, Kyung Hee University Dental Hospital*

Abstract

The purpose of this study was to evaluate the accuracy and precision of the three-dimensional (3D) imaging system of children's facial soft tissue by comparing linear measurements. The subjects of the study were 15 children between the ages of 7 and 12. Twenty-three landmarks were pointed on the face of each subject and 16 linear measurements were directly obtained 2 times using an electronic caliper. Two sets of 3D facial images were made by the 3D scanner. The same 16 measurements were obtained on each 3D image. In the accuracy test, the total average difference was 0.9 mm. The precision of 3D photogrammetry was almost equivalent to that of direct measurement. Thus, 3D photogrammetry by the 3D scanner in children had sufficient accuracy and precision to be used in clinical setting. However, the 3D imaging system requires the subject's compliance for exact images. If the clinicians provide specific instructions to children while obtaining 3D images, the 3D device is useful for investigating children's facial growth and development. Also the device can be a valuable tool for evaluating the results of orthodontic and orthopedic treatments.

Key words : Three-dimensional imaging system, Accuracy and precision of 3D images, Facial anthropometry, Children's facial soft tissue

I. Introduction

In the early 21st century, orthodontics switched from the Angle paradigm to the soft tissue paradigm. The soft tissue paradigm emphasizes the ideal soft tissue proportions, functional occlusion, and soft tissue movements[1]. In this respect, facial anthropometry is important to provide an accurate diagnosis and a treatment plan for individual patients. It is needed for estimating facial growth and evaluating the results of the

treatment and efficiency of the surgery in dentistry[2-4].

There are many methods to acquire patients' facial data ; photography, cone-beam computed tomography (CBCT), and three-dimensional (3D) imaging system[5,6]. The 3D face analysis uses ultrasound, laser scanning, magnetic resonance imaging, contact digitization, stereophotogrammetry and white light system[5-7].

Although photography, the traditional approach, is the easiest way, it is likely to have perspective distortions subject to

Corresponding author : Kwangchul Kim

Department of Pediatric Dentistry, Kyung Hee University Dental Hospital at Gangdong, 892, Dongnam-ro, Gangdong-gu, Seoul, 05278, Korea

Tel: +82-2-440-7505 / Fax: +82-2-440-7549 / E-mail: juniordent@khu.ac.kr

Received July 15, 2019 / Revised October 17, 2019 / Accepted September 5, 2019

the angle and distance of view of the image[2]. Despite CBCT can obtain the 3D soft tissue images, CBCT exposes the subjects to radiation. CBCT also cannot retain information on the color and texture of the subjects' soft tissue[8,9].

The use of 3D imaging systems was recently introduced in the field of medicine to obtain 3D images. It can simulate facial changes following treatments. It can also store integumentary information of the soft tissue. There is no direct contact with the facial surface, avoiding modifications of the soft tissues, which may cause errors in direct measurements[6,7,10,11].

In dental field, 3D photogrammetry is commercially available for orthodontic treatments[5,9-13]. The Morpheus 3D® scanner (Morpheus Co., Seoul, Korea) is a 3D photogrammetry device using a structured light system. It uses light emitting diode (LED) light to create 3D images based on data, obtained 3 times for 0.8 seconds[14].

The purpose of this study was to evaluate the accuracy and the precision of 3D images obtained from the 3D imaging system of children's facial soft tissue by comparing 16 linear measurements. In addition, the study aimed to confirm the children's error range compared to adults' error range and determine the reliability of 3D imaging for children.

II. Materials and Methods

1. Subjects

The inclusion criteria were 15 children with normal facial growth and development between the ages of 6 to 15 (Table 1).

The purpose of the study was explained to the guardians of all the subjects, following which they signed the consent form. The study was, performed at the Department of Pediatric Den-

tistry, Kyung Hee University Hospital at Gangdong, Seoul, Korea. It was conformed to approved international review board (IRB) protocols (IRM No : KHNMC 2018-11-009-002).

2. Data capture technique

Twenty-three landmarks were pointed on the face of each subject using pencil eyeliner (Fig. 1). The labeled points were followed by the standard anthropometric landmarks defined by Farkas (Table 2). La1 - 4 were defined as the points 4.0 cm above each Exocanthion (Ex) and Endocanthion (En) on the subject's forehead[2]. Sixteen linear measurements were directly obtained 2 times using an electronic caliper (Fig. 2). The linear distances comprised of 8 horizontal and 8 vertical mea-

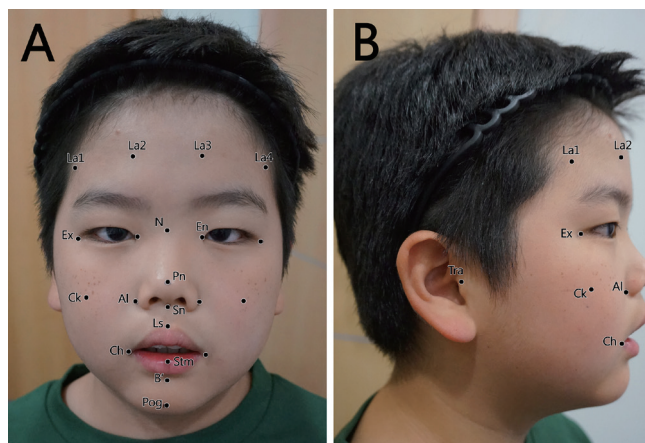


Fig. 1. The 23 landmarks used in this study on the facial soft tissue. (A) The frontal view. (B) The lateral view.

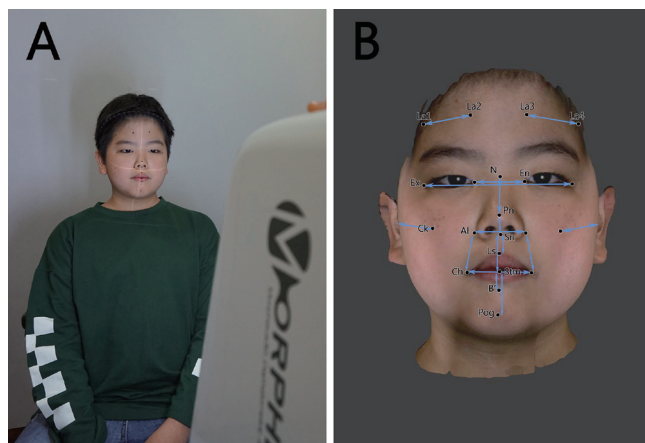


Fig. 2. (A) The subject sat on a stool with molar-bite occlusion, sealed lips and relaxed facial muscles. (B) The 16 linear measurements on the three-dimensional image made by the device.

Table 1. The subjects participated in this study

Age (years)	Number of subjects	Male	Female
7	3	0	3
8	2	1	1
9	3	2	1
10	5	3	2
11	1	1	0
12	1	1	0
Sum	15	8	7

Table 2. Definitions of facial landmarks[2]

Landmark		Definition
Nasion	N	Point in the midline of both the nasal root and the nasofrontal suture
Alare	Al	The most lateral point on each alar contour
Pronasale	Pn	The most protruded point of the apex nasi, identified in lateral view of the head in resting position
Subnasale	Sn	The midpoint of the angle at the columella base where the lower border of the nasal septum and the surface of the upper lip meet
Labialesuperius	Ls	The midpoint of the upper vermilion line
Stomion	Stm	The imaginary point at the crossing of the vertical facial midline and the horizontal labial fissure between gently closed lips, with teeth shut in the natural position
Cheilion	Ch	The most lateral aspect of the vermilion border of the corner of the mouth
Tragion	Tra	The notch on the upper margin of the tragus
Sublabiale	B'	The lower border of the lower lip or the upper border of the chin
Pogonion	Pog	The most anterior midpoint of the chin, located on the skin surface in front of the identical bony landmark of the mandible
Endocanthion	En	The point at the inner commissure of the eye fissure (In this study, the nearest points on the skin from the actual landmarks.)
Exocanthion	Ex	The point at the outer commissure of the eye fissure (In this study, the nearest points on the skin from the actual landmarks.)
Cheek	Ck	The intersecting point of lines connecting Ala-Tra and Ex-Ch
La1,2,3 and 4		The points located 4.0 cm above the right exocanthion, right endocanthion, left endocanthion, and left exocanthion

surements.

The subject sat on a stool in front of the Morpheus 3D device with molar-bite occlusion, sealed lips and relaxed facial muscles. The facial images of each subject were captured 3 times from 3 different angles (front, left, and right), and merged into a single 3D image using the 3D imaging program. Two sets of 3D images were acquired, and the same 16 linear measurements were acquired from both 3D images. All 3D data acquisitions and measurements were performed by a single operator.

3. Data analysis

Prior to analysis, the data were evaluated using the Shapiro-Wilk test, to determine the normality of distribution. For normally distributed values, the paired *t*-test was performed. For the other values, the Wilcoxon signed-rank test was performed. All tests were conducted using the SPSS software, version 18.0 (SPSS Inc., Chicago, IL, USA).

Accuracy

The mean values of each measurement from the direct mea-

surement and from the 3D image were compared to determine the accuracy of the scanner.

Precision

For the precision test, 2 sets obtained from direct measurement and 3D image were compared using 3 precision estimates : Mean absolute difference (MAD), relative error magnitude (REM), and technical error of measurement (TEM). The MAD, the mean absolute value of each measurement; it is easy to calculate and is commonly used for estimation of precision. The REM is the value obtained by dividing the MAD by the mean value and multiplying it by 100. The REM compensates for the error in relation to the size of the measurements. The TEM is the standard deviation calculated using the following formula :

$$TEM = \sqrt{(\sum D^2) / 2N}$$

where *D* is the difference between the first and second measurements, and *N* is the number of subjects. As may be deduced from the 3 estimates, smaller values indicate higher precision[7,10,11].

III. Results

1. Accuracy

When the mean values of each measurement in the direct and 3D images were compared, 7 of the 16 measurements were found to be significantly different. There were no statistically significant differences in the other 9 of the 16 measurements. The mean difference of all the measurements ranged from 0.1 mm to 1.4 mm. The average of all the mean differences was 0.9 mm (Table 3).

2. Precision

The precisions results were compared using MAD, REM and TEM. The MAD ranged from 0.26 mm to 0.96 mm for direct measurements and from 0.41 mm to 1.27 mm for 3D photogrammetry. The mean values of MAD were 0.69 mm for direct measurement and 0.72 mm for 3D photogrammetry. The REM of direct measurements ranged from 0.75% to 6.76% with a mean value of 2.44% and 3D photogrammetry ranged from

0.59% to 4.50% with a mean value of 2.32%. All the TEM was below 1.00 mm except Lt.Tra-Ck in 3D photogrammetry (1.13 mm). The mean value of TEM in direct measurement was 0.62 mm and in 3D photogrammetry was 0.66 mm (Table 4).

IV. Discussion

Currently, 3D photogrammetry is commercially available and is used in medical fields associated with facial surgeries for facial changes[6,15]. It is more intuitive compared to the other methods, even when there are marked variations in the appearance. For instance, in the dental field, orthodontic treatment can lead to facial changes. Recently, following orthodontic treatments, evaluation of facial changes on the soft-tissue level is performed. Children, like people in general, are concerned about their facial appearance following orthodontic treatments.

In pediatric dentistry, a study was conducted on 3D imaging for children with an orofacial cleft. Babies usually undergo surgeries for cleft repair when they are young. The precise records of facial data before and after the surgery are necessary.

Table 3. Accuracy of the linear distance obtained from direct measurements and from measurement on three-dimensional images

Variable	Mean 3D photo (mm)	Mean caliper (mm)	Mean difference (mm)	<i>p</i> value
Ex-Ex	103.3	103.0	0.7	0.151
En-En	30.7	29.9	0.9	0.015
Al-Al	35.7	35.2	0.9	0.098
Ch-Ch	48.8	49.0	1.2	0.731
Rt.Tra-Ck	79.0	78.1	1.1	0.028
Lt.Tra-Ck	78.7	77.7	1.1	0.001
N-Pn	33.6	33.5	0.3	0.156
Pn-Sn	15.3	15.3	0.1	0.089
Sn-Ls	12.1	11.6	0.7	0.023
Sn-Stm	23.2	22.1	1.2	0.018
Stm-Pog	27.8	26.6	1.4	0.003
Stm-B'	14.0	12.9	1.2	0.001
La1-La2	40.3	40.3	0.7	0.889
La3-La4	36.0	36.2	0.8	0.332
Rt.Al-Ch	28.0	27.8	0.6	0.328
Lt.Al-Ch	27.6	27.1	1.2	0.148
Mean	-	-	0.9	-

Paired *t*-test, Wilcoxon signed rank test
3D, Three-dimensional; Rt, right; Lt, left

Table 4. Three precision values obtained from direct measurements and from measurements on three-dimensional images

Variable	Caliper			3D		
	MAD (mm)	REM (%)	TEM (mm)	MAD (mm)	REM (%)	TEM (mm)
Ex-Ex	0.77	0.75	0.67	0.61	0.59	0.51
En-En	0.60	1.99	0.52	0.53	1.76	0.47
Al-Al	0.75	2.13	0.66	0.66	1.84	0.56
Ch-Ch	0.86	1.77	0.68	1.00	2.04	0.92
Rt.Tra-Ck	0.72	0.92	0.61	0.77	0.98	0.67
Lt.Tra-Ck	0.84	1.10	0.70	1.27	1.60	1.13
N-Pn	0.64	1.95	0.58	0.52	1.59	0.45
Pn-Sn	0.26	1.82	0.23	0.49	3.12	0.51
Sn-Ls	0.59	5.16	0.56	0.41	3.66	0.46
Sn-Stm	0.58	2.67	0.57	0.76	3.19	0.81
Stm-Pog	0.96	3.76	0.86	0.61	2.19	0.53
Stm-B'	0.87	6.76	0.95	0.60	4.50	0.56
La1-La2	0.66	1.77	0.59	1.05	2.64	0.94
La3-La4	0.58	1.61	0.55	0.79	2.35	0.78
Rt.Al-Ch	0.56	2.06	0.53	0.64	2.31	0.56
Lt.Al-Ch	0.76	2.76	0.68	0.75	2.76	0.70
Mean	0.69	2.44	0.62	0.72	2.32	0.66

3D, three-dimensional; Rt, right; Lt, left; MAD, mean absolute difference; REM, relative error magnitude; TEM, technical error of measurement

It is possible to improve the treatment plan using 3D images owing to the better comprehension of the facial anatomy. Thus, it is useful for the follow-up evaluations of the patient's facial condition[12].

There are 2 ways to obtain 3D facial images ; laser-scanning system and white light system. In the early stages of 3D photogrammetry, laser scanning technique was used more frequently. However, direct radiations from the laser can harm the patients' eyes. Therefore, it is being supplemented by white light system. The white light system is divided into stereophotogrammetry and structured light system. In stereophotogrammetry, 2 cameras obtain images from different angles simultaneously and form a 3D image through the triangulation algorithm. In structured light system, the scanner projects points, lines, and patterns formed by light, and calibrates the 3D image using the distortion of the projections. The white light system poses no harm to the human body[5,7,16].

The purpose of this study was to determine the accuracy and precision of the 3D device by comparing 16 linear measurements in children. The 15 children between the ages of 6 to 15 were asked to be participated and 8 boys and 7 girls

were included (Table 1). The children in this age often undergo orthodontic treatments that may cause facial morphologic changes[17-19]. The lower age limit was chosen to be 6 years because students begin elementary school at 6 years of age in general. The upper age limit was decided based on the Nolla stage of teeth. The final Nolla stage is the 10th grade, in which children are 15 years of age on average[20].

In the accuracy test, 7 measurements were significantly different (Table 3, $p < 0.05$), which were En-En, Rt.Tra-Ck, Lt.Tra-Ck, Sn-Ls, Sn-Stm, Stm-Pog, and Stm-B'.

The device error in the merging process of the images and error based on the children's facial expression might have caused the significant difference. The 3D images using 3 photographs were created through the registration and merging processes. During this process, the overlapping areas of the images were connected. When the landmark was located in this area, small distortion might have occurred[5]. In this study, the increased error in the 3D images could be attributed to the location of the Ck landmarks in this overlapping area.

The 4 measurements that were significantly different were located around the lips ; Sn-Ls, Sn-Stm, Stm-Pog, and Stm-B'.

Compared to adults, children are easily distracted. In addition, the muscles around the lips are involved in many facial expressions. It is challenging to keep them sufficiently still to obtain 3 images with the same facial expression, especially in children. We believed that this might have caused the increased error in measurements in the accuracy test.

The same study that was performed in adults revealed that the mean difference in the accuracy of the 3D images was 0.75 mm, compared to the 0.9 mm obtained in this study for children[5]. The MAD, REM, and TEM values of 3D photogrammetry were compared with the same values of direct measurements to evaluate the precision of 3D photogrammetry. The mean MAD values of 3D photogrammetry and direct measurements were 0.72 mm and 0.69 mm, respectively, and the difference was 0.03 mm. Differences in the TEM and REM values were 0.04 mm and 0.12%, respectively. The precision of 3D photogrammetry was almost equivalent to that of the direct measurement. However, the values were higher than the values in the same study on adult[5]. The mean MAD values of 3D photogrammetry and direct measurements in adults were 0.38 mm and 0.31 mm respectively. The values in adults were smaller than that in children.

In this study, 3D photogrammetry in children had sufficient accuracy and precision to be used in clinical settings. The mean difference in accuracy was under 1.0 mm, and the 3D precision level was almost that same as that in direct measurements. However, the accuracy and precision were not as high as in adults. The gap in the mean differences between children and adult was 0.15 mm in the accuracy test. The precision in children was also slightly lower than that in adults, which meant that 3D images of children had lower repeatability. In the clinical environment, errors are more likely in cases of children. More specific instructions are required to obtain accurate 3D images of children. These include instructions on the general posture, facial expression, occlusion, and lip position. In the future, devices or merging programs that yield 3D images in shorter time periods should be developed to reduce the error for children.

Recently, both parents and children are more interested in their appearances. Moreover, many authors claimed that early orthodontic interventions could produce a more significant improvement for skeletal class II or class III malocclusion in children[17,19,21]. In this regard, children before adolescence have more opportunities for orthodontic treatment that can result in facial change. They want more intuitive data that

can be simulated prior to the treatment. Therefore, this study could expand the utilization of 3D photogrammetry for children's facial changes. Based on this study, further studies could be performed for facial changes with growth and evaluation of orthodontic and orthopedic treatment results in children's soft tissues after providing more detailed instructions.

The limitations of this study were the absence of age categorization for the subjects and the small number of subjects. In future studies, the error range should be verified based on the children's age category. It should be determined if the younger children tend to have larger mean differences between 3D and direct measurements. Studies with more subjects are also required. Nonetheless, this study verified that the children's 3D facial images obtained using the 3D imaging system could be put into practice with accuracy and precision after providing detailed instructions.

V. Conclusion

The 3D surface-imaging system using the 3D scanner had accuracy and precision of children's soft tissue. The total average of accuracy was 0.9 mm and the precision of 3D photogrammetry was almost equivalent to that of direct measurements. However, the accuracy and precision in this study were lesser than those observed for adults. Therefore, when the clinicians understand the likelihood of errors in cases of children and provide specific instructions regarding the posture for acquiring exact images, the 3D device could be useful for investigating children's facial growth and development. Furthermore, the 3D surface-imaging system could be a valuable method for evaluating the results of orthodontic and orthopedic treatments. Future studies are required to verify if there are tendencies for errors based on children's age category with more subjects. Also 3D devices should be developed in future to reduce for more accurate and precise 3D images of children's face.

ORCID

Misun Kim <https://orcid.org/0000-0001-8338-1838>

Okhyung Nam <https://orcid.org/0000-0002-6386-803X>

Hyo-seol Lee <https://orcid.org/0000-0001-7287-5082>

Sungchul Choi <https://orcid.org/0000-0001-7221-2000>

References

1. Proffit WR, Fields Jr HW, Sarver DM : Contemporary orthodontics, 4th ed., Mosby, 3-22, 2006.
2. Farkas LG : Anthropometry of the Head and Face, 2nd ed., Raven Press, 20-88, 191-221, 1994.
3. Toma AM, Zhurov A, Playle R, Richmond S : A three-dimensional look for facial differences between males and females in a British-Caucasian sample aged 15½ years old. *Orthod Craniofac Res*, 11:180-185, 2008.
4. Sforza C, Peretta R, Ferrario VF, *et al.* : Three-dimensional facial morphometry in skeletal Class III patients : A non-invasive study of soft-tissue changes before and after orthognathic surgery. *Br J Oral Maxillofac Surg*, 45:138-144, 2007.
5. Kim SH, Jung WY, Park YG, *et al.* : Accuracy and precision of integumental linear dimensions in a three-dimensional facial imaging system. *Korean J Orthod*, 45:105-112, 2015.
6. Weinberg SM, Scott NM, Marazita ML, *et al.* : Digital three-dimensional photogrammetry : evaluation of anthropometric precision and accuracy using a Genex 3D camera system. *Cleft Palate Craniofac J*, 41:507-518, 2004.
7. de Menezes M, Rosati R, Ferrario VF, Sforza C : Accuracy and reproducibility of a 3-dimensional stereophotogrammetric imaging system. *J Oral Maxillofac Surg*, 68:2129-2135, 2010.
8. Mollemans W, Schutyser F, Suetens P, *et al.* : Predicting soft tissue deformations for a maxillofacial surgery planning system : from computational strategies to a complete clinical validation. *Med Image Anal*, 11:282-301, 2007.
9. Ayoub AF, Xiao Y, Hadley D, *et al.* : Towards building a photo-realistic virtual human face for craniomaxillofacial diagnosis and treatment planning. *Int J Oral Maxillofac Surg*, 36:423-428, 2007.
10. Weinberg SM, Naidoo S, Marazita ML, *et al.* : Anthropometric precision and accuracy of digital three-dimensional photogrammetry : comparing the Genex and 3dMD imaging systems with one another and with direct anthropometry. *J Craniofac Surg*, 17:477-483, 2006.
11. Wong JY, Oh AK, Deutsch CK, *et al.* : Validity and reliability of craniofacial anthropometric measurement of 3D digital photogrammetric images. *Cleft Palate Craniofac J*, 45:232-239, 2008.
12. Li G, Wei J, Feng X, *et al.* : Three-dimensional facial anthropometry of unilateral cleft lip infants with a structured light scanning system. *J Plastic Reconstr Aesthet Surg*, 66:1109-1116, 2013.
13. Kusnoto B, Evans CA : Reliability of a 3D surface laser scanner for orthodontic applications. *Am J Orthod Dentofacial Orthop*, 122:342-348, 2002.
14. Morpheus Co., Ltd. : Morpheus 3D Scanner. Available from URL: <https://morpheus3d.co.kr/wp/en/imaging-solutions/morpheus3d-scanner/> (Accessed on March 20, 2019).
15. Camison L, Bykowski M, Weinberg SM, *et al.* : Validation of the Vectra H1 portable three-dimensional photogrammetry system for facial imaging. *Int J Oral Maxillofac Surg*, 47:403-410, 2018.
16. Faugeras O : Three-dimensional computer vision : a geometric viewpoint, MIT press, 165-243, 1993.
17. Kim JH, Viana MA, BeGole EA, *et al.* : The effectiveness of protraction face mask therapy : a meta-analysis. *Am J Orthod Dentofacial Orthop*, 115:675-685, 1999.
18. Kurt G, Uysal T, Yagci A : Soft and hard tissue profile changes after rapid maxillary expansion and face mask therapy. *World J Orthod*, 11:e10-18, 2010.
19. Mandall N, DiBiase A, Doherty B, *et al.* : Is early class III protraction facemask treatment effective? A multicentre, randomized, controlled trial : 15-month follow-up. *J Orthod*, 37:149-161, 2010.
20. The Council of the Faculty of Orthodontics : Textbook of Orthodontics, 2nd ed., DaehanNarae, 69, 2006.
21. Tulloch JF, Phillips C, Koch G, Proffit WR : The effect of early intervention on skeletal pattern in Class II malocclusion : a randomized clinical trial. *Am J Orthod Dentofacial Orthop*, 111:391-400, 1997.

국문초록

소아 얼굴 연조직의 3차원 입체영상의 정확성 및 재현성 평가

최경화¹ 전공의 · 김미선^{1,2} 교수 · 이고은³ 전임의 · 남옥형^{2,3} 교수 · 이효설^{2,3} 교수 · 최성철^{2,3} 교수 · 김광철^{1,2} 교수

¹ 강동경희대학교병원 치과병원 소아치과

² 경희대학교 치의학전문대학원 소아치과학교실

³ 경희대학교 치과병원 소아치과

이 연구의 목적은 소아 얼굴 연조직의 선형 길이를 비교하여 삼차원 입체영상의 정확성과 재현성을 평가하는 것이다. 연구는 7 - 12 세 아동 15명을 대상으로 하였다. 환자의 안모에 23개의 계측 점을 표시하고, 전자 캘리퍼를 이용하여 16 개의 선형길이를 직접 2번 계측하였다. 3차원(3D) 스캐너를 이용하여 2개의3D 얼굴 영상을 만들었으며, 직접계측과 동일한 16개의 선형 길이를 계측하였다. 연구결과 정확성 평가에서 전체 평균 차이 값은 0.9 mm였다. 3D 영상의 재현성은 직접계측의 재현성과 거의 유사한 정도로 나타났다. 이에 따라 이 3D 영상장비는 소아에서 임상적으로 충분한 정확성과 재현성을 가지고 있었다. 3D 영상 시스템은 정확한 이미지를 위하여 대상의 협조가 필요하다. 소아의 정확한 3D영상을 얻기 위한 구체적인 지시사항을 바탕으로 촬영을 한다면, 이 3D 영상 장비는 향후 소아의 성장과 발달을 조사하고, 소아교정치료에서 결과를 평가하는데 유용하게 사용될 수 있을 것이다.