

Case Report

Case Report for Severe Hepatitis A Treated in a Korean Hospital

Sul-Ki Kim¹, Cheon-Hoo Jeon³, Nam-Heon Lee², Jung-Hyo Cho¹, Chang-Gue Son^{1*}

¹Liver and Immunology Research Center, Dunsan Oriental Hospital of Daejeon Univ., Daejeon, Republic of Korea

²Liver and Immunology Research Center, Cheonan Oriental Hospital of Daejeon Univ.,
Cheonan, Republic of Korea

³Department of Internal Medicine, Dunsan Oriental Hospital of Daejeon Univ., Daejeon, Republic of Korea

A 25-year-old male presented with influenza-like symptoms and took Western anti-inflammatory analgesic drugs for 2 days. The symptoms aggravated, so the patient decided to rely on Korean medicine (KM). Based on the highly elevated hepatic enzymes (AST 4,621 IU/L and ALT 2,763 IU/L) with a positive result of anti-HAV IgM, he was diagnosed with hepatitis A. The patient was hospitalized and given herbal drugs (*Chunggan-plus extract*, *Innae-Tang*) and acupuncture, according to symptom differentiation, the accumulation of damp heat (濕熱纏結¹). The subjective symptoms (fatigue, nausea, gastric discomfort) including jaundice and dark urine as well as laboratory abnormalities gradually improved gradually in 10 hospital days, and the patient completely recovered in 25 days as an out-patient. This case presents a classic case of severe hepatitis A in 2019 Korean outbreak, and is informative to physicians for diagnosis and treatment in the traditional Korean medicine field.

Key Words : hepatitis A, HAV, Traditional Korean medicine

Introduction

Hepatitis A is a kind of viral hepatitis, with the incidence rate of approximately 1000 to 10,000 cases annually in Korea and 4000 to 30,000 cases in USA.^{1,2)} Hepatitis A virus (HAV) belongs to the family *picornaviridae* and the genus *hepatovirus*, and is a non-enveloped RNA virus with the diameter of 27 nm.^{3,4)} HAV viral transmission occurs in a fecal-oral fashion; therefore, hygiene and socio-economic status play important role in hepatitis A pathology.⁵⁾

After infection, HAV lies dormant for approximately

25 days, and infectivity is the strongest in this stage. Then, the subsequent hepatic cell damage causes elevation of serum liver enzymes and influenza-like symptoms such as fatigue, weakness, anorexia, nausea, vomiting, abdominal pain, and fever. This is followed by elevated bilirubin stage, causing jaundice.⁶⁾ Hepatitis A is highly contagious, but does not become chronic, and symptomatic treatments, such as resting and providing sufficient nutrition, are enough due to spontaneous cure within 6 months.⁷⁾ However, about 15 % of hepatitis A cases have a prolonged clinical stage of over 6 months, and 20 % of hepatitis A cases

• Received : 16 December 2020

• Revised : 22 January 2020

• Accepted : 28 January 2020

• Correspondence to : Chang-Gue Son

Liver and Immunology Research Center, Dunsan Oriental Hospital of Daejeon University

75, Daedeok-daero 176beon-gil, Seo-gu, Daejeon, Republic of Korea

Tel : +82-42-470-9134, Fax : +82-42-470-9008, E-mail : ckson@dju.ac.kr

relapse within 2 to 3 months.⁸⁾ Although for a small percentage, hepatitis A can cause complications, such as acute liver failure, renal failure, interstitial nephritis, pancreatitis, red blood cell aplasia, and so on. Fulminant hepatitis occurs in 0.14~0.35 % of hepatitis A cases, which may require liver transplantation.⁹⁾ Recently, reports of poor prognosis of hepatitis A, including such complications as liver transplantation, and death have been steadily increasing in the developed countries including Korea.^{10,11)} Furthermore, many cases of hepatitis A could be misdiagnosed as a common cold, which leads to administration with antipyretic analgesic including acetaminophen, most of which have to be avoided.¹²⁾

Korean medicine (KM) describes hepatitis A as *jaundice*, a typical symptom of hepatitis A. In fact, approximately 70 % of hepatitis A cases present jaundice. Hepatitis A has been well controlled in KM clinics from the ancient period; however, to the recent ban on chemical/immunological diagnostic tools, it has become a rare disease treated by Oriental doctors.

Therefore, this case study presents severe hepatitis A in a 20's male in the 2019 outbreak of hepatitis A in Chungcheong-do province, Korea will arouse awareness of the misdiagnosis of hepatitis A and provide therapeutically useful information in Korean Medicine-based treatments.

Report of the case

1. Patient and diagnosis

A 25-year-old male felt sudden severe fatigue and pantalgia. He thought he had a cold and took over-the-counter medicine (Dexibuprofen 300 mg, Acetaminophen 320 mg) for two days. However, symptoms did not resolve, and when his urine

became darker, the patient visited a KM hospital on Sep. 10th. 2019. He did not remember personal or family history of liver disease. He denied traveling, eating contaminated food or water, and consuming alcohol, energy drinks, or illicit drugs within the last two months. On physical examination, mild jaundice of the sclera was observed, and there was a mild tenderness in the epigastric point. The tongue was red without fur, and the pulse was floating. His symptom differentiation was the “*Accumulation of damp heat* (濕熱蘊結)”. The initial serum liver enzymes were more than 100 times higher than the normal range (AST 4,621 IU/L and ALT 2,763 IU/L). Total bilirubin (4.4 mg/dL), γ -GTP (227 IU/L), ALP (151 IU/L) and monocytes portion in CBC (21.0%) were also notably elevated. Anti-HAV IgM was elevated to 6.58 signal cutoff (S/Co), and other hepatitis virus tests were negative. There was no significant abnormal shadow on Abdomen X-ray. Based on these results, he was diagnosed as hepatitis A and hospitalized.

2. Treatment and course of symptoms

Based on the diagnosis of hepatitis A, two herbal drugs CGX and *Innae-Tang* (Table 1) were given to the patient, 3 times a day. Acupuncture was performed twice daily (morning and afternoon) mainly at LI4 (合谷), LR3 (太衝), PC6 (內關), SP4 (公孫) for 15 minutes at the depth of 10mm. To provide sufficient volume and nutrition, 1000 ml of dextrose 5 % mixed with a vitamin complex was supplied intravenously each day. Improvement of the symptoms was soon noted: fatigue on Day 4 and dyspepsia on Day 7. On Day 8, AST (163 IU/L), ALT (667 IU/L) was decreased, and the patient discharged on Sep. 18th. 2019. The subsequent blood tests showed the normalization of items including AST (20 IU/L), ALT (27 IU/L),

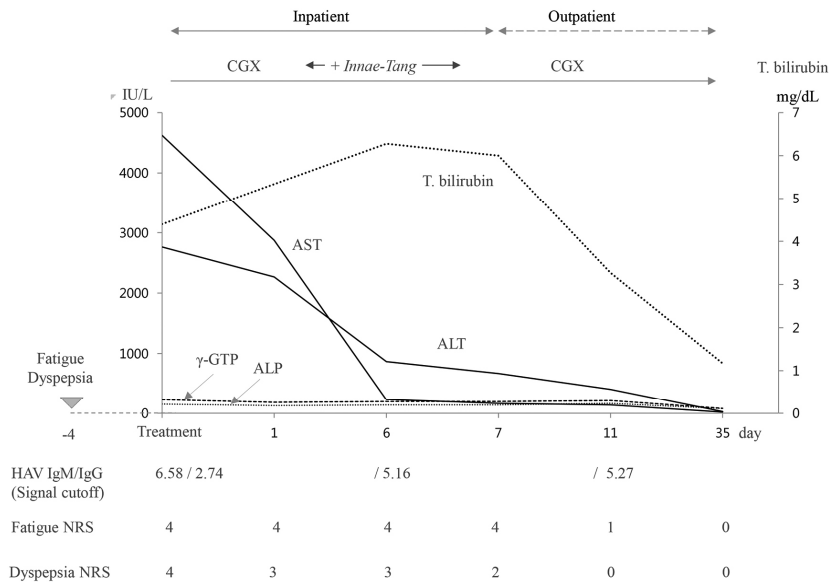


Fig. 1. Summary for changes of laboratory results and treatment courses.

Abbreviation: NRS, numeric rating scale.

The upper limits are follow; 40 IU/L for AST and ALT, 64 IU/L for γ -GTP, 120 IU/L for ALP, 1.2 mg/dL for Total bilirubin.

and total bilirubin (1.17 mg/dL) on Day 35 (Figure 1).

Discussion and Conclusion

HAV is usually an asymptomatic infection in young children, but its clinical symptoms become more severe in adults.¹³ In recent years, hygiene in South Korea has dramatically improved, and seroprevalence of HAV has changed.¹⁴ In the young adult group, HAV seropositivity was over 80

% during the 1970s, but decreased to below 20 % in 2006.¹⁵ Accordingly, the high susceptibility to HAV in young adults increases the incidence rate of hepatitis A with a poor prognosis. Pandemics occurred in 2009 and 2019.^{16,17} In 2009, 15,231 people were diagnosed with hepatitis A in 2009; in 2019, this number reached 17,636.^{18,1)}

The case reported in this study showed a severe liver injury, which required attention for the risk of a poor prognosis. In clinics, many doctors could misdiagnose hepatitis as a cold and usually

Table 1. Prescription and Compositional Volume of Drugs

Prescription	Compositional Volume of Drugs(gram)
Chunggan-plus (清肝plus)	Artemisia capillaris Herba (5), Trionycis Carapax (5), Raphani Semen(5), Atractylodis Rhizoma Alba (3), Hoelen (3), Alismatis Rhizoma (3), Atractylodis rhizoma (3), Salvia miltiorrhizae Radix (3), Polyporus (2), Amomi Fructus (2), Ponciri Fructus (2), Glycyrrhizae Radix (1), Aucklandiae Radix (1)
Innae-Tang (茵萊湯)	Artemisia capillaris Herba(50), Raphani Semen(20), Glycyrrhizae Radix(10)

prescribe non-steroidal anti-inflammatory drugs or acetaminophen. However, as these drugs can aggravate liver damage, these drugs should be avoided by patients with hepatitis A.¹⁹⁾ Doctors should consider the possibility of an HAV infection in any case with complaints about digestive problems and cold-like symptoms, especially in the periods of hepatitis A pandemics in the region. Prior to presentation, the patient of our study took acetaminophen 640mg for 2 days. However, upon receiving CM treatment, the patient recovered within one week in terms of his subjective symptoms, and within 5 weeks in terms of the laboratory abnormalities. The slight abnormality of γ -GTP (81 IU/L) on Day 35 can be explained by the fact that this enzyme will take longer than other enzymes to improve to the normal range.²⁰⁾ The increased portion of monocytes in the CBC test might have resulted from the fact that HAV inhibits the differentiation of monocytes.²¹⁾

CGX is an hepato-therapeutic syrup composed of 13 herbs, and its pharmacological activities were proved in preclinical and clinical studies,²²⁾ while *Innae-Tang* (*Artemisiae Capillaris Herba* plus *Raphani Semen* (see Table 1) can eliminate dampness and removes X.^{23,24)} Acupuncture points (LI4, LR3, PC6 SP4) were selected to facilitate digestion and help the *Qi* (氣) and blood circulation as recommended in a previous study.²⁵⁾ Regarding herbal drugs, there are many considerations for the hepatotoxic effects in the patients with hepatic inflammations and other disorders.²⁶⁾ However, there is evidence that the risk of herb-related hepatotoxicity is overestimated.²⁷⁾ As shown in this case report, the proper use of herbal drugs could be a better option in treatments of various liver disorders.²⁸⁾ In summary, the adequate level of hygiene and vaccination resulted in a very low

incidence of hepatitis A; however, certain age groups (people in the 20s to 40s in South Korea) are risk groups for the HAV infection. Accordingly, doctors should consider the possibility of HAV infection when hepatitis A is pandemic, particularly in younger patients (aged in their 20s and 40s). In addition, KM-based treatments is an appropriated option for hepatitis A. The present case report provides meaningful insights for the prevention, management, and treatment of hepatitis A.

Acknowledgment

This work was supported by the National Research Foundation of Korea (NRF) grant funded by the Korea government (MSIT) (No. 2019R1A2C2088201).

Reference

1. Korean Centers for Disease Control and Prevention. Infectious Disease Portal. <http://www.cdc.go.kr/npt/biz/npp/portal/nppLwcrIcdMain.do> Accessed January 22, 2020.
2. Centers for Disease Control and Prevention, Data & Statistics. <http://www.cdc.gov/DataStatistics/> Accessed November 11, 2019.
3. Najarian R, Caput D, Gee W, Potter SJ, Renard A, Merryweather J, et al. Primary structure and gene organization of human hepatitis A virus. PNAS. 1985;82:2627-2631.
4. Song HU, Hwang SG, Kwon CI, Lee JE, Ko KH, Hong SP, et al. Molecular Epidemiology of Hepatitis A Virus in the South - East Area of Gyeonggi-do in Korea. Yonsei medicine Journal 2009;50(4):512-516.
5. Jennifer AC. Hepatitis A: Old and New. Clin Microbiol Rev. 2001;14(1): 38-58.

6. Charles P, Blaine H. Hepatitis A: Natural History, Immunopathogenesis, and Outcome. *Clin Liver Dis.* 2013;2(6):231-234.
7. Shigeki T. *STEP Internal Medicine Gastroenterology.* Seoul: Hankook Medicine; 2014, 183-197.
8. Olivia A, Ahmed E, Adam H, Alexandra H. A very rare complication of hepatitis A infection: Acute Myocarditis - A Case Report with Literature Review. *Case reports in Medicine* 2018;e3625139.
9. Oh SH, Lee JH, Hwang JW, Kim HY, Lee CH, Gwak GY, et al. Four patients with hepatitis A presenting with fulminant hepatitis and acute renal failure and who underwent liver transplantation. *Korean J Hepatol.* 2009;15: 362-369.
10. Ryan MT, Timothy D, Santiago M, Stephen-Huy H, Brendan M, Anne ML, et al. Fulminant Hepatitis A Virus Infection in the United States: Incidence, Prognosis, and Outcomes. *Hepatol.* 2006;44(6):1589-1597.
11. Lee JH, Choi MS, Gwak GY, Lee JH, Koh KC, Paik SW, et al. Clinical Features and predictive Factors of Acute Hepatitis A Complicated with Acute Kidney Injury. *Korean J gastroenterol.* 2010;56:359-364.
12. Eric Y, Arooj B, Moaz C, Matthew K, Nikolaos P. Acetaminophen-Induced Hpatotoxicity : A Comprehensive Update. *J Clin Transl Hepatol.* 2016;4:131-142.
13. Jung J, Ahn YJ, Moon K. An Epidemiologic Study on the Seropositive Rate of Hepatitis A Virus in children of Gwangju and Jeonnam. *Korean J Pediatr Gastroenterol nutr.* 2016; 14(1):67-73.
14. Lee HJ, Cho HK, Kim JH, Kim KH. Seroepidemiology of Hepatitis A in Korea: Changes over the Past 30 Years. *J Korean Med Sci.* 2011;26:791-796.
15. Jung YK, Kim JH. Epidemiology and clinical features of acute hepatitis A: from the domestic perspective. *Korean J Hepatol.* 2009;15:438-445.
16. Yoon JG, Choi MJ, Yoon JW, Noh JY, Song JY, Cheong H.J, et al. Seroprevalence and disease burden of acute hepatitis A in adult population in South Korea. *PLoS ONE* 2017;12:e0186257.
17. Lee KY, Song KH, Kang JH. Seroepidemiology of Hepatitis A in Taejon, Korea 1996. *Korean J Pediatr.* 1998;41(1):53-61.
18. Yoon EL, Sinn DH, Lee HW, Kim JH. Current status and strategies for the control of viral hepatitis A in Korea. *Clin Mol Hepatol.* 2017; 23(3):196-204.
19. Maryam S, Farnad I, Saeid S, Sarvi S, Hassan S, Hoorolnesa A, et al. The Role of Non-Steroidal Anti-Inflammatory Drugs (NSAIDs) in the Treatment of Patients With Hepatic Disease : A Review Article. *Anesth Pain Med.* 2016;6(4): e37822.
20. Jiang SY, Jiang DL, Tao YJ. Role of gamma-glutamyl transterase in cardiovascular diseases. *Exp Clin Cardiol.* 2013;18:53-56.
21. Sabina W, Britta B, Angelika V. Hepatitis A Virus suppresses Monocyte-to Macrophage Maturation In Vitro. *J Virol.* 2002;76(9):4350 -4356.
22. Hu XP, Shin JW, Wang JH, Cho JH, Son JY, Cho CK, et al. Antioxidative and hepatoprotective effect of CGX, an herbal medicine, against toxic acute injury in mice. *J Ethnopharmacol.* 2008;120(1):51-55.
23. Wendong H, Jun Z, David DM. A traditional herbal medicine enhances bilirubin clearance by activating the nuclear receptor CAR. *J Clin Invest.* 2004;113(1):137-143.

24. He QF, Luo YJ, Zhang PP, An CS, Zhang AL, Li XD, et al. Hepatoprotective and antioxidant potential of radish seed aqueous extract on cadmium-induced hepatotoxicity and oxidative stress in mice. *Phcog mag*. 2019;15(61):283-289.
25. Li H, He T, Xu Q, Li Z, Liu Y, Li F, et al. Acupuncture and regulation of gastrointestinal function. *World J Gastroenterol*. 2015;21(27):8304-8313.
26. Cecillia NA, Orish EO. Herb-Induced Liver Injuries in Developing Nations. *Toxics* 2018; 6(2):24.
27. Liu CX, Fan HR, Li YZ, Xiao XH. Research advances on Hepatotoxicity of Herbal Medicines in China. *BioMed Research International* 2016;7150391.
28. Dicya S, William CC, Ghanshyam U. Drug-Induced Liver Toxicity and Prevention by Herbal Antioxidants: An Overview. *Frontiers in Physiol*. 2016; 26(6):36.

ORCID

- Sul-Ki Kim <https://orcid.org/0000-0001-5981-7849>
Cheon-Hoo Jeon <https://orcid.org/0000-0003-2474-412X>
Nam-Heon Lee <https://orcid.org/0000-0002-5039-2423>
Jung-Hyo Cho <https://orcid.org/0000-0002-1094-0165>
Chang-Gue Son <https://orcid.org/0000-0003-4876-0167>