



Paclitaxel-Coated Balloon versus Plain Balloon Angioplasty for Dysfunctional Autogenous Radiocephalic Arteriovenous Fistulas: A Prospective Randomized Controlled Trial

Jong Woo Kim, MD, PhD¹, Jeong Ho Kim, MD², Sung Su Byun, MD³,
Jin Mo Kang, MD, PhD⁴, Ji Hoon Shin, MD, PhD¹

¹Department of Radiology and Research Institute of Radiology, Asan Medical Center, University of Ulsan College of Medicine, Seoul, Korea; Departments of ²Radiology and ⁴Surgery, Gil Medical Center, Gachon University College of Medicine, Incheon, Korea; ³Health Promotion Center, Inha University Hospital, Incheon, Korea

Objective: To report the mid-term results of a single-center randomized controlled trial comparing drug-coated balloon angioplasty (DBA) and plain balloon angioplasty (PBA) for the treatment of dysfunctional radiocephalic arteriovenous fistulas (RCAVFs).

Materials and Methods: In this prospective study, 39 patients (mean age, 62.2 years; 21 males, 18 females) with RCAVFs failing due to juxta-anastomotic stenosis were randomly assigned to undergo either both DBA and PBA (n = 20, DBA group) or PBA alone (n = 19, PBA group) between June 2016 and June 2018. Primary endpoints were technical and clinical success and target lesion primary patency (TLPP); secondary outcomes were target lesion secondary patency (TLSP) and complication rates. Statistical analysis was performed using the Kaplan-Meier product limit estimator.

Results: Demographic data and baseline clinical characteristics were comparable between the groups. Technical and clinical success rates were 100% in both groups. There was no significant difference between the groups in the mean duration of TLPP (DBA group: 26.7 ± 3.6 months; PBA group: 27.0 ± 3.8 months; *p* = 0.902) and TLSP (DBA group: 37.3 ± 2.6 months; PBA group: 40.4 ± 1.5 months; *p* = 0.585). No procedural or post-procedural complications were identified.

Conclusion: Paclitaxel-coated balloon use did not significantly improve TLPP or TLSP in the treatment of juxta-anastomotic stenosis of dysfunctional RCAVFs.

Keywords: Hemodialysis; Arteriovenous fistula; Paclitaxel drug-coated balloon; Angioplasty; Patency

INTRODUCTION

Autogenous arteriovenous fistulas (AVFs) are currently recognized as the preferred route of access for hemodialysis in patients with end-stage renal disease (ESRD), as AVFs are associated with the lowest risk of complications, lowest need for intervention, and best long-term patency compared

to other access routes (1). However, stenosis as a result of neointimal hyperplasia remains a major concern associated with AVF dysfunction (2-4). Radiocephalic arteriovenous fistulas (RCAVFs) are commonly the first choice for autogenous vascular access (5); studies have shown that stenotic lesions occur at the juxta-anastomotic site in up to 64% of dysfunctional RCAVFs (2).

Received: January 29, 2020 **Revised:** April 3, 2020 **Accepted:** April 7, 2020

This study was supported by the Dong Kook Lifescience. Co., Ltd., Republic of Korea (2016-38).

Corresponding author: Jeong Ho Kim, MD, Department of Radiology, Gil Medical Center, Gachon University College of Medicine, 21 Namdong-daero 774beon-gil, Namdong-gu, Incheon 21565, Korea.

• E-mail: ho7ok7@gilhospital.com

This is an Open Access article distributed under the terms of the Creative Commons Attribution Non-Commercial License (<https://creativecommons.org/licenses/by-nc/4.0>) which permits unrestricted non-commercial use, distribution, and reproduction in any medium, provided the original work is properly cited.

According to the updated Kidney Disease Outcomes Quality Initiative (KDOQI) guidelines (1), percutaneous transluminal angioplasty (PTA) is the first choice for the treatment of juxta-anastomotic stenosis. As the primary patency rates at one year are relatively low with this technique, ranging from 26% to 62% (2, 3), multiple therapeutic sessions may be needed to maintain long-term patency (6, 7).

Recently, drug-coated balloon angioplasty (DBA) has been reported to result in superior primary patency as compared to plain balloon angioplasty (PBA) (8-12). Drug-coated balloons (DCBs) are usually coated with paclitaxel, a microtubule-stabilizing drug that inhibits the vascular smooth muscle cell migration and proliferation that contributes to neointimal hyperplasia (13).

Currently, no consensus exists regarding the comparative safety and efficacy of DBA and PBA. Until now, there have been no comparative studies performed in Korea. Therefore, in the present study, the authors sought to further investigate the effectiveness of DBA as compared to PBA in the treatment of dysfunctional RCAVFs in dialysis patients.

MATERIALS AND METHODS

Study Design

This was an investigator-initiated, single-center, prospective, randomized, single-blinded, controlled trial investigating DBA versus PBA for the treatment of dysfunctional RCAVFs in dialysis patients. After Institutional Review Board approval, written informed consent was obtained from all participants prior to the commencement

of the study. This trial was registered in one of the primary registries in the WHO Registry Network, "Clinical Research Information Service (CRIS), Republic of Korea" (KCT0004870).

The overall sample size was calculated on the assumption of a 50% expected primary patency rate in the active treatment group and a 25% rate in the reference treatment control group at one year, on the basis of findings from a previous randomized study (11). For the demonstration of non-inferiority, a 15% margin of difference between the two methods was used ($\alpha = 0.05$ and statistical power set at 0.80).

All patients referred to the study center for treatment of a dysfunctional AVF or arteriovenous graft (AVG) between June 2016 and June 2018 were screened for eligibility. Of the 200 patients screened, 40 dialysis patients (21 male, 19 female; mean age, 62.2 ± 11.9 years; range, 39–84 years) with dysfunctional RCAVFs who were referred for angioplasty on the basis of well-accepted indications according to the 2006 KDOQI recommendations (1) were enrolled and written informed consent was obtained. One patient in the PBA group withdrew voluntarily two months after randomization, so a total of 39 patients were included in the final analysis. The inclusion and exclusion criteria are summarized in Table 1. A 1:1 randomization was performed via sealed envelopes to determine whether patients underwent either angioplasty with both a DCB and PBA ($n = 20$, DBA group) or a PBA ($n = 20$, PBA group).

Procedures

All procedures were performed by board-certified

Table 1. Eligibility Criteria for Patient Enrollment

Inclusion Criteria
Malfunctioning RCAVF*
Lesions (<i>de novo</i> or restenosis) located at juxta-anastomotic venous site within 8 cm of anastomotic point of RCAVF
Angiographic confirmation of stenosis greater than 50% (vs. proximal reference diameter)
Ability to cross lesion with guide wire
Exclusion Criteria
Dialysis access type other than RCAVFs
Thrombosed RCAVFs
Evidence of systemic or local infection associated with RCAVF
Uncorrectable coagulopathy (despite transfusion) or hypercoagulable state
Allergy or other known contraindications to iodinated contrast media or paclitaxel
Age < 19 years
Life expectancy < 1 year

*Clinical signs of failing dialysis access: i) abnormally decreased inflow, including decreased thrill or bruit, collapsed draining veins, increased bleeding and prolonged hemostasis time after dialysis, and progressive decrease in flow obtained with needles of same gauge; ii) prescribed blood inflow rate < 250–300 mL/min; or iii) decreased inflow rate $\geq 25\%$ from baseline. RCAVF = radiocephalic arteriovenous fistula

interventionists with 3–15 years of angioplasty experience. Before angioplasty, diagnostic fistulograms were obtained using a 21-gauge scalp vein needle. After obtaining sequential venograms of the draining outflow veins as well as the central veins, the arteriovenous anastomosis and juxta-anastomotic segment of the outflow vein were highlighted using contrast agent, with the inflation of a blood pressure cuff on the arm to occlude outflow. The site, degree, and length of each stenosis were documented. The target lesion (TL) was defined as stenosis in the juxta-anastomotic venous segment within 8 cm of the anastomotic point of the RCAVF.

Based on the fistulographic findings, the outflow vein was punctured under local anesthesia (2% lidocaine), and a 6- or 7-F vascular sheath (Radiofocus, Terumo) was inserted in the retrograde direction. Heparin was administered at a dose of 2500 IU. Through this sheath, a 5-F Kumpe Catheter (Cook Medical) and a 0.035-inch Hydrophilic Guide Wire (Terumo) were manipulated across the identified stenosis. The balloon size was determined according to the measured diameter of the reference vessel. In each patient, after dilation using a 4-mm plain balloon (Mustang, Boston Scientific), one of two treatment strategies was followed depending on the randomly assigned treatment group. Lesions in the DBA group were treated with a 4-mm or 5-mm paclitaxel-coated balloon (IN.PACT Admiral, Medtronic) and a 6-mm plain balloon (Mustang), while lesions in the PBA group were treated with a 6-mm plain balloon (Mustang) alone. The balloon was maintained inflated for 2 minutes and the procedure was repeated if necessary. An inflation pressure as high as the manufacturer's stated burst pressure (14 atm for the IN.PACT Admiral DCB and 24 atm for the Mustang balloon) was employed. If a residual stenosis of 30% or more was seen on the final angiogram, post-dilation using a cutting balloon was performed. After removing the introducer sheath, puncture site hemostasis was achieved using a purse-string suture.

Study Endpoints and Follow-Up

All study endpoints were defined according to the Society of Interventional Radiology's reporting standards for percutaneous interventions in dialysis access (14). Primary endpoints were technical (anatomic) success, defined as successful completion of the angioplasty procedure with less than 30% residual stenosis on the final angiogram; clinical success, defined as the performance of at least one successful dialysis session using the RCAVF after angioplasty;

and target lesion primary patency (TLPP), defined as the presence of a functional dialysis circuit with no clinical need for repeat intervention at the TL. Secondary endpoints were complication rates; target lesion secondary patency (TLSP), defined as patency until access was surgically re-established or abandoned; renal transplantation; and loss to follow-up. All follow-up was clinically driven. Unless an earlier re-assessment was indicated, patients were clinically evaluated every 3 months by the attending nephrologist and vascular surgeon. If deemed necessary, an ultrasound examination was performed, and if a hemodynamically significant stenosis at any part of the dialysis circuit was found to correlate with inadequate dialysis, the patient was taken to the interventional suite for angioplasty.

Statistical Analysis

Data are expressed as mean \pm standard deviation or number (n) and percentage (%) where appropriate. Continuous variables were analyzed using Student's *t* test, while categorical variables were analyzed using the χ^2 test or Fisher's exact test. Kaplan-Meier analysis with the log-rank test was used to estimate the difference in TLPP and TLSP rates in the DBA and PBA groups during the follow-up period. Statistical analysis was performed using SPSS Statistics for Windows software, version 24.0 (IBM Corp.). A *p* value of < 0.05 was considered to be statistically significant.

RESULTS

Patient Demographics

A flow diagram to illustrate the study protocol is provided in Figure 1. Demographic data and baseline clinical data are presented in Table 2. There were no significant differences in demographics or AVF and TL characteristics between the DBA and PBA groups.

Technical (Anatomic) Success, Clinical Success, and Complications

Procedural outcomes in DBA and PBA groups are presented in Table 3. Device success was achieved in 85% (17/20) of the DBA group and 84.2% (16/19) of the PBA group. A total of six patients (three in the DBA group and three in the PBA group) underwent post-dilation treatment with cutting balloons due to the persistence of stenosis greater than 30% on post-angioplasty angiography despite the performance of repeat angioplasty. Technical (anatomic) and clinical success rates were 100% for both the DBA

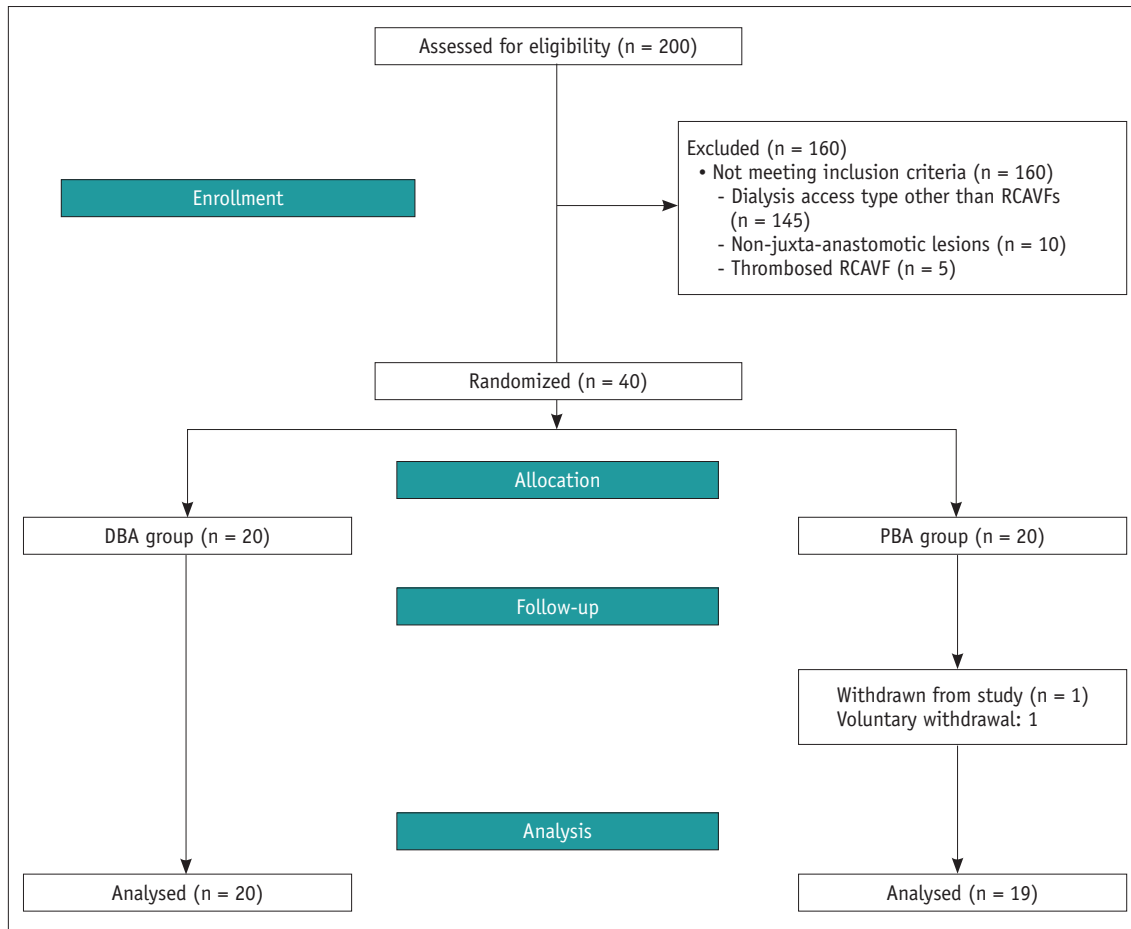


Fig. 1. Flowchart illustrating study protocol. DBA = drug-coated balloon angioplasty, PBA = plain balloon angioplasty, RCAVF = radiocephalic arteriovenous fistula

and PBA groups. No major or minor procedure-related complications occurred in either group.

Target Lesion Primary Patency

Recurrent stenosis at the TL occurred in nine patients (46.2%) in the DBA group and nine patients (47.4%) in the PBA group ($p = 1.000$). Figure 2 shows the Kaplan-Meier analysis of TLPP rates in the DBA and PBA groups. The TLPP rates for the DBA and PBA groups at 6, 12, 24, and 36 months after the procedure were 90.0% and 84.2% ($p = 0.589$), 65.0% and 68.4% ($p = 0.822$), 55.0% and 57.0% ($p = 0.900$), and 55.0% and 48.9% ($p = 0.714$), respectively. The mean duration of TLPP did not significantly differ between the groups (26.7 ± 3.6 months in the DBA group vs. 27.0 ± 3.8 months in the PBA group; $p = 0.902$).

Target Lesion Secondary Patency

Three patients (DBA, $n = 2$ at 4 months and 7 months; PBA, $n = 1$ at 15 months) underwent surgery to recreate

the dialysis access due to thrombosis. Two patients were censored as a result of death (DBA, $n = 1$ at 20 months; PBA, $n = 1$ at 11 months). No deaths during the follow-up period were related to dysfunction of the dialysis circuit. Figure 3 shows the Kaplan-Meier analysis of the TLSP rates of the DBA and PBA groups. The TLSP rates for the DBA and PBA groups at 6, 12, 24, and 36 months after the procedure were 95.0% and 100% ($p = 0.589$), 90.0% and 100% ($p = 0.822$), 90.0% and 94.1% ($p = 0.900$), and 90.0% and 94.1% ($p = 0.714$), respectively. There was no significant difference between the groups in the mean duration of TLSP (37.3 ± 2.6 months in the DBA group vs. 40.4 ± 1.5 in the PBA group; $p = 0.585$).

DISCUSSION

RCAVF is the first choice for autogenous AVF creation because the distal location allows venipuncture of a larger venous territory (15). This randomized controlled trial (RCT)

Table 2. Demographic Characteristics of Hemodialysis Access in DBA and PBA Groups

Characteristic	DBA (n = 20)	PBA (n = 19)	P
Age (years)	60.7 ± 12.2	63.7 ± 11.8	0.450
Sex			0.429
Male	12 (60.0)	9 (47.4)	
Female	8 (40.0)	10 (52.6)	
Diabetes mellitus	16 (80.0)	15 (78.9)	1.000
Age of RCAVF (months)			
Mean ± SD	27.3 ± 30.7	19.1 ± 11.1	0.325
Median (range)	17 (2-108)	13 (2-85)	
Side of RCAVF			0.127
Left	13	17	
Right	7	2	
Stenosis type			0.695
<i>De novo</i>	15 (75.0)	16 (84.2)	
Restenosis	5 (25.0)	3 (15.8)	
Degree of TL stenosis (%)	80.0 ± 6.5	80.3 ± 8.2	0.912
TL length (cm)	3.0 ± 1.5	3.4 ± 1.5	0.435
Follow-up time (months)			
Mean ± SD	19.1 ± 11.1	21.7 ± 14.6	0.528
Median (range)	19 (3-40)	23 (2-40)	

Data in parentheses are percentages. DBA = drug-coated balloon angioplasty, PBA = plain balloon angioplasty, SD = standard deviation, TL = target lesion

aimed to investigate the potential added value of DCBs in patients with dysfunctional autogenous AVFs, focusing on a specific access type to lessen heterogeneity. This RCT has two main strengths: it is the first randomized comparative study to evaluate the efficacy of DBA exclusively in dysfunctional RCAVFs as opposed to other types of dialysis access, and it has a relatively long follow-up period compared to previously published studies (9, 10, 12, 16-20).

The present study showed that paclitaxel-coated balloons were not superior to plain balloons for the treatment of juxta-anastomotic stenosis of RCAVFs at 6, 12, 24, or 36 months. The TLPP rates for the DBA and PBA groups at 6, 12, 24, and 36 months after the procedure were 90.0% and 84.2% ($p = 0.589$), 65.0% and 68.4% ($p = 0.822$), 55.0% and 57.0% ($p = 0.900$), and 55.0% and 48.9% ($p = 0.714$), respectively. This study finding contrasts with that of Lai et al. (10), who used a similar methodology to compare PTA techniques; lesions were randomized such that each patient had one lesion treated with PBA + DCB and another with PBA alone. Unlike in the present study, a different lesion in the same patient was used as the control (10). Lai et al. (10) found that TLPP was significantly higher in the PBA + DCB

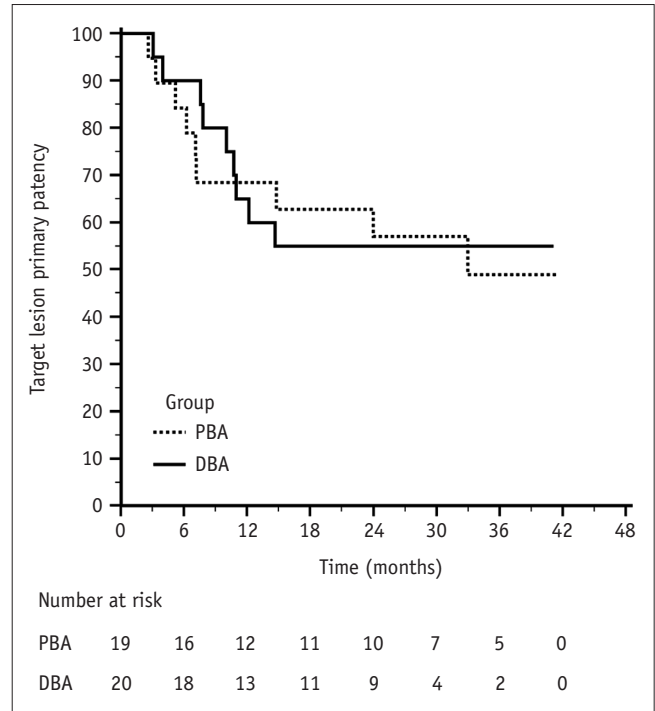


Fig. 2. Kaplan-Meier analysis of target lesion primary patency in DBA and PBA groups.

group than in the PBA group at 6 months (70% vs. 0%; $p < 0.01$), but not 12 months (20% vs. 0%; $p > 0.05$) after the procedure.

To date, multiple observational and randomized controlled studies have evaluated the use of DCBs for prolonging patency, but caution should be taken when interpreting the results due to clinical heterogeneity resulting from the non-uniform level of intervention (8, 9, 11, 12, 16-30). In a retrospective study in 2014, Patanè et al. (9) presented a case series of 26 patients who had juxta-anastomotic radiocephalic stenosis treated using DBA. The results appeared excellent, with TLPP rates at 6 months, 1 year, and 2 years of 96.1%, 90.9%, and 57.8%, respectively, and TLSP rates at 1 year and 2 years of 100% and 94.7%, respectively. In a recent retrospective report by the same team (28), two groups of 26 and 44 patients treated with two different DCBs were compared with a control group of 86 patients treated with PBA. TLPP rates at 12 months were higher in the two DCB groups (In.Pact Amphirion, Medtronic: 90.9%; Lutonix, BD: 86.4%) than in the PBA group (62.8%, $p = 0.002$). That study is one of relatively few to focus on the effectiveness of DCB treatment for juxta-anastomotic stenosis of distal RCAVFs. Differences in methodology between that study and the present study include the use of PBA to reach an appropriate

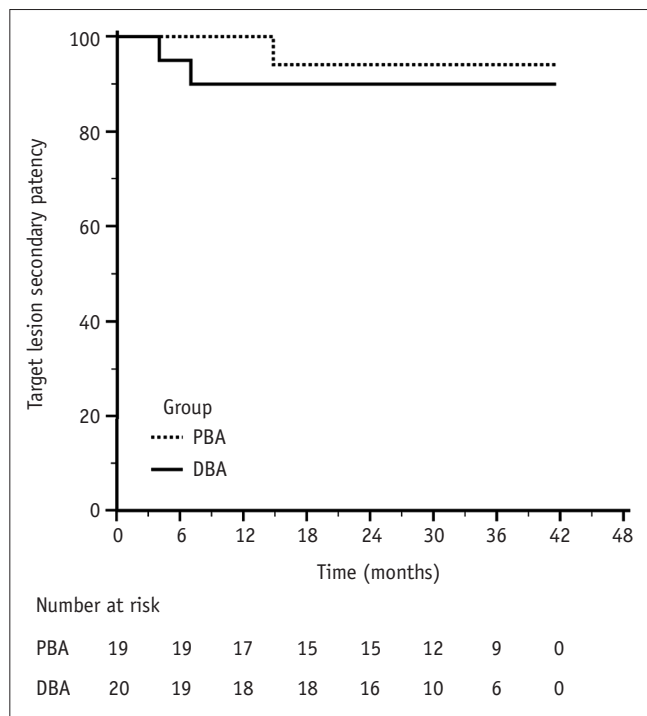


Fig. 3. Kaplan-Meier analysis of target lesion secondary patency in DBA and PBA groups.

dilatation of the stenosis and the application of DCBs to deliver paclitaxel onto the entire surface of the vessels. In another retrospective comparative study of 26 patients who underwent re-intervention (13 DBA vs. 13 PBA) to treat restenosis in RCAVFs after at least one previous PTA, Haave et al. (26) reported that DBA was associated with significantly improved patency. After 12 and 24 months, the estimated proportion of stenosis-free patients in the DBA cohort was 61% and 31%, respectively, compared to 40% and 15% in the PBA cohort. In our study, the 12-month patency in the DBA group was very similar to that reported by Haave et al. (26), whereas the control arm patency was much higher. In contrast, in another two-cohort study with 26 patients in each of the DBA and PTA groups, Çildağ et al. (22) found no significant difference in the 6-month primary patency rate (77% vs. 65%, respectively, $p = 0.45$), whereas there was a significant difference in the 12-month primary patency rate (65% vs. 35%, respectively, $p < 0.05$). These results are not similar to our findings except for the 12-month primary patency in the DBA group.

In another retrospective comparative study, Lučev et al. (24) reported that TLPP was significantly higher in the DBA group than the PBA group at 6 months (90.3% vs. 61.3%; $p = 0.016$), 12 months (77.4% vs. 29.0%; $p = 0.0004$), and 24 months (45.2% vs. 16.1%; $p = 0.026$). In

Table 3. Procedural Outcomes in DBA and PBA Groups

Characteristics	DBA (n = 20)	PBA (n = 19)	P
Device success*	17 (85.0)	16 (84.2)	1.000
Post-dilation†	3 (15.0)	3 (15.8)	1.000
Technical (anatomic) success	20 (100)	19 (100)	1.000
Clinical success	20 (100)	19 (100)	1.000
Recurrence	9 (45.0)	9 (47.4)	0.882
TLPP (%)			
6 months	90.0	84.2	0.589
1 year	65.0	68.4	0.822
2 years	55.0	57.0	0.900
3 years	55.0	48.9	0.714
TLPP duration (months)	26.7 ± 3.6	27.0 ± 3.8	0.902
95% CI	19.6–33.7	19.5–34.6	
TLSP (%)			
6 months	95.0	100	0.305
1 year	90.0	100	0.136
2 years	90.0	94.1	0.642
3 years	90.0	94.1	0.642
TLSP duration (months)	37.3 ± 2.6	40.4 ± 1.5	0.585
95% CI	33.5–43.2	37.4–43.4	
Circuit thrombosis‡	2 (10.0)	1 (5.3)	1.000
Complications	0 (0)	0 (0)	1.000

Unless otherwise indicated, data are mean ± SD, and data in parentheses are percentages. *Defined as less than 30% residual stenosis immediately after angioplasty on intent-to-treat analysis, †Additional cutting balloon angioplasty for more than 30% residual TL stenosis, ‡One at 4 months and other one at 7 months in DBA group; one at 15 months in PBA group. CI = confidence interval, TLPP = target lesion primary patency, TLSP = target lesion secondary patency

a recent prospective RCT comparing DBA and PBA groups, Irani et al. (17) reported a TLPP of 81% and 61% ($p = 0.03$) at 6 months, and 51% and 34% ($p = 0.04$) at 12 months, respectively. However, this RCT involved some AVGs as well as AVFs.

Meanwhile, in a multicenter RCT, Maleux et al. (25) demonstrated no significant difference between DBA and PBA in terms of primary patency. At 3, 6, and 12 months, the primary patency rates after DBA and PBA were 87.9% and 80.7% ($p = 0.43$), 66.7% and 64.5% ($p = 0.76$), and 43.4% and 38.7% ($p = 0.95$), respectively.

The most recently published large, multicenter RCT to compare DBA with PBA was conducted by Trerotola et al. (18, 20). This study included patients with an AVF at any location in the arm. Efficacy results were variable; TLPP was significantly higher with DBA at 9 months (58% vs. 46%; $p = 0.02$) but not at any other time point over the two-year study period.

In contrast to previous studies, an RCT conducted by Björkman et al. (19) yielded negative results regarding DBA; a total of 88.9% (16/18 patients) in the DBA group experienced revascularization or occlusion within one year, compared to 22.2% (4/18 patients) in the PBA group (relative risk for DBA: 7.09).

It is important to note that there are conflicting results amongst meta-analyses (31-33). One meta-analysis published by Khawaja et al. (31) in 2016, assessing two RCTs and four cohort studies, showed improved TLPP at six months for DBA as opposed to PBA. However, the included studies were clinically heterogeneous and only involved a small number of participants. A meta-analysis published by Kennedy et al. (33) in 2019, including both AVFs and AVGs, reported that DBA resulted in a significant improvement in lesion patency at 3, 6, 12, and 24 months compared to PBA. However, a meta-analysis by Abdul Salim et al. (32) in 2020 found no significant difference in TLPP between DBA and PBA at 1, 3, 6, 7, 12, and 24 months across six RCTs of AVFs. Thus, more adequately powered multicenter randomized trials are needed in the future.

A potential reason that the present study did not show superiority of DBA over PBA is the multifactorial nature of juxta-anastomotic stenosis in RCAVF; stenosis can be associated with fibromuscular hyperplasia at the venipuncture sites, uremia, oxidative stress and inflammation induced by ESRD, and vessel injury from needle punctures (34-36). In addition, methodological factors in this study such as the use of a small-diameter DCB and the use of a plain balloon after DBA may have affected the effectiveness of drug delivery to the vessel wall. Arguably, however, there is still no consensus regarding the optimal methodology for DBA.

Consistent with previous studies of DBA in dysfunctional AVFs (20, 33), the present study showed that DBA can be used safely to manage dysfunctional RCAVFs. Moreover, this study offered the opportunity to explore three-year mortality rates. No procedure-related mortality was recorded within the three-year follow-up period. A recent review drew attention to a possible increase in late mortality in patients undergoing DBA for peripheral arterial disease (37). However, the first meta-analysis investigating mortality following DCB use in the treatment of dysfunctional dialysis access circuits found no increased risk of all-cause mortality following DBA as compared to PBA at short- and mid-term follow-up (38).

This study has several limitations. First, only a small

number of patients were enrolled at a single center, which raises the risk of bias to the results. Second, this was a single-blinded study, whereas it would ideally have been double-blinded. However, the DCB has a different appearance from that of a plain balloon and thus the interventionists performing the index PTA could not be blinded to the device. Theoretically, the lack of double-blinding could have affected outcomes.

In conclusion, DCB use did not significantly improve TLPP or TLSP in the treatment of juxta-anastomotic stenosis of dysfunctional RCAVFs. This study is underpowered but provides some additional evidence regarding the use of DCBs for the treatment of dysfunctional RCAVFs. Further studies involving a larger number of cases are required to verify these results.

Conflicts of Interest

The authors have no potential conflicts of interest to disclose.

ORCID iDs

Jong Woo Kim

<https://orcid.org/0000-0002-5784-922X>

Jeong Ho Kim

<https://orcid.org/0000-0002-1404-2821>

Sung Su Byun

<https://orcid.org/0000-0001-7630-3663>

Jin Mo Kang

<https://orcid.org/0000-0002-1477-9778>

Ji Hoon Shin

<https://orcid.org/0000-0001-6598-9049>

REFERENCES

1. Vascular Access 2006 Work Group. Clinical practice guidelines for vascular access. *Am J Kidney Dis* 2006;48:S176-S247
2. Rajan DK, Bunston S, Misra S, Pinto R, Lok CE. Dysfunctional autogenous hemodialysis fistulas: outcomes after angioplasty—Are there clinical predictors of patency? *Radiology* 2004;232:508-515
3. Heye S, Maleux G, Vaninbrouckx J, Claes K, Kuypers D, Oyen R. Factors influencing technical success and outcome of percutaneous balloon angioplasty in de novo native hemodialysis arteriovenous fistulas. *Eur J Radiol* 2012;81:2298-2303
4. Riella MC, Roy-Chaudhury P. Vascular access in haemodialysis: strengthening the Achilles' heel. *Nat Rev Nephrol* 2013;9:348-357
5. Jennings WC, Kindred MG, Broughan TA. Creating

- radiocephalic arteriovenous fistulas: technical and functional success. *J Am Coll Surg* 2009;208:419-425
6. Beathard GA, Arnold P, Jackson J, Litchfield T; Physician Operators Forum of RMS Lifeline. Aggressive treatment of early fistula failure. *Kidney Int* 2003;64:1487-1494
 7. Napoli M, Prudenzano R, Russo F, Antonaci AL, Aprile M, Buongiorno E. Juxta-anastomotic stenosis of native arteriovenous fistulas: surgical treatment versus percutaneous transluminal angioplasty. *J Vasc Access* 2010;11:346-351
 8. Katsanos K, Karnabatidis D, Kitrou P, Spiliopoulos S, Christeas N, Siablis D. Paclitaxel-coated balloon angioplasty vs. plain balloon dilation for the treatment of failing dialysis access: 6-month interim results from a prospective randomized controlled trial. *J Endovasc Ther* 2012;19:263-272
 9. Patanè D, Giuffrida S, Morale W, L'Anfusa G, Puliatti D, Bisceglie P, et al. Drug-eluting balloon for the treatment of failing hemodialytic radiocephalic arteriovenous fistulas: our experience in the treatment of juxta-anastomotic stenoses. *J Vasc Access* 2014;15:338-343
 10. Lai CC, Fang HC, Tseng CJ, Liu CP, Mar GY. Percutaneous angioplasty using a paclitaxel-coated balloon improves target lesion restenosis on inflow lesions of autogenous radiocephalic fistulas: a pilot study. *J Vasc Interv Radiol* 2014;25:535-541
 11. Kitrou PM, Katsanos K, Spiliopoulos S, Karnabatidis D, Siablis D. Drug-eluting versus plain balloon angioplasty for the treatment of failing dialysis access: final results and cost-effectiveness analysis from a prospective randomized controlled trial (NCT01174472). *Eur J Radiol* 2015;84:418-423
 12. Kitrou PM, Spiliopoulos S, Katsanos K, Papachristou E, Siablis D, Karnabatidis D. Paclitaxel-coated versus plain balloon angioplasty for dysfunctional arteriovenous fistulae: one-year results of a prospective randomized controlled trial. *J Vasc Interv Radiol* 2015;26:348-354
 13. Axel DI, Kunert W, Göggelmann C, Oberhoff M, Herdeg C, Küttner A, et al. Paclitaxel inhibits arterial smooth muscle cell proliferation and migration in vitro and in vivo using local drug delivery. *Circulation* 1997;96:636-645
 14. Gray RJ, Sacks D, Martin LG, Trerotola SO; Society of Interventional Radiology Technology Assessment Committee. Reporting standards for percutaneous interventions in dialysis access. *J Vasc Interv Radiol* 2003;14:S433-S442
 15. Long B, Brichart N, Lermusiaux P, Turmel-Rodrigues L, Artru B, Boutin JM, et al. Management of perianastomotic stenosis of direct wrist autogenous radial-cephalic arteriovenous accesses for dialysis. *J Vasc Surg* 2011;53:108-114
 16. Verbeeck N, Pillet JC, Toukouki A, Prospert F, Leite S, Mathieu X. Paclitaxel-coated balloon angioplasty of venous stenoses in native dialysis fistulas: primary and secondary patencies at 6 and 12 months. *J Belg Soc Radiol* 2016;100:69
 17. Irani FG, Teo TKB, Tay KH, Yin WH, Win HH, Gogna A, et al. Hemodialysis arteriovenous fistula and graft stenoses: randomized trial comparing drug-eluting balloon angioplasty with conventional angioplasty. *Radiology* 2018;289:238-247
 18. Trerotola SO, Lawson J, Roy-Chaudhury P, Saad TF; Lutonix AV Clinical Trial Investigators. Drug coated balloon angioplasty in failing AV fistulas: a randomized controlled trial. *Clin J Am Soc Nephrol* 2018;13:1215-1224
 19. Björkman P, Weselius EM, Kokkonen T, Rauta V, Albäck A, Venermo M. Drug-coated versus plain balloon angioplasty in arteriovenous fistulas: a randomized, controlled study with 1-year follow-up (the drecorest Ii-study). *Scand J Surg* 2019;108:61-66
 20. Trerotola SO, Saad TF, Roy-Chaudhury P; Lutonix AV Clinical Trial Investigators. The Lutonix AV randomized trial of paclitaxel-coated balloons in arteriovenous fistula stenosis: 2-year results and subgroup analysis. *J Vasc Interv Radiol* 2020;31:1-14.e5
 21. Boitet A, Massy ZA, Goeau-Brissonniere O, Javerliat I, Coggia M, Coscas R. Drug-coated balloon angioplasty for dialysis access fistula stenosis. *Semin Vasc Surg* 2016;29:178-185
 22. Çıldaç MB, Köseoğlu ÖF, Akdam H, Yeniçerioglu Y. The primary patency of drug-eluting balloon versus conventional balloon angioplasty in hemodialysis patients with arteriovenous fistula stenoses. *Jpn J Radiol* 2016;34:700-704
 23. Kitrou PM, Papadimatos P, Spiliopoulos S, Katsanos K, Christeas N, Broutzos E, et al. Paclitaxel-coated balloons for the treatment of symptomatic central venous stenosis in dialysis access: results from a randomized controlled trial. *J Vasc Interv Radiol* 2017;28:811-817
 24. Lučev J, Breznik S, Dinevski D, Ekart R, Ruprecht M. Endovascular treatment of haemodialysis arteriovenous fistula with drug-coated balloon angioplasty: a single-centre study. *Cardiovasc Intervent Radiol* 2018;41:882-889
 25. Maleux G, Vander Mijnsbrugge W, Henroteaux D, Laenen A, Cornelissen S, Claes K, et al. Multicenter, randomized trial of conventional balloon angioplasty versus paclitaxel-coated balloon angioplasty for the treatment of dysfunctioning autologous dialysis fistulae. *J Vasc Interv Radiol* 2018;29:470-475.e3
 26. Haave TR, Manstad-Hulaas F, Brekken R. Treatment of restenosis in radiocephalic arteriovenous hemodialysis fistulas: percutaneous transluminal angioplasty or drug-coated balloon. *Acta Radiol* 2019;60:1584-1589
 27. Liao MT, Lee CP, Lin TT, Jong CB, Chen TY, Lin L, et al. A randomized controlled trial of drug-coated balloon angioplasty in venous anastomotic stenosis of dialysis arteriovenous grafts. *J Vasc Surg* 2020;71:1994-2003
 28. Patanè D, Failla G, Coniglio G, Russo G, Morale W, Seminara G, et al. Treatment of juxta-anastomotic stenoses for failing distal radiocephalic arteriovenous fistulas: drug-coated balloons versus angioplasty. *J Vasc Access* 2019;20:209-216
 29. Swinnen JJ, Hitos K, Kairaitis L, Gruenewald S, Larcos G, Farlow D, et al. Multicentre, randomised, blinded, control trial of drug-eluting balloon vs sham in recurrent native dialysis fistula stenoses. *J Vasc Access* 2019;20:260-269
 30. Yazar O, Provoost A, Broughton A, Ghijssels L, Leclef Y, Van Calster K, et al. Paclitaxel drug-coated balloon angioplasty for

- the treatment of failing arteriovenous fistulas: a single-center experience. *Acta Chir Belg* 2020;120:85-91
31. Khawaja AZ, Cassidy DB, Al Shakarchi J, McGrogan DG, Inston NG, Jones RG. Systematic review of drug eluting balloon angioplasty for arteriovenous haemodialysis access stenosis. *J Vasc Access* 2016;17:103-110
 32. Abdul Salim S, Tran H, Thongprayoon C, Fülöp T, Cheungpasitporn W. Comparison of drug-coated balloon angioplasty versus conventional angioplasty for arteriovenous fistula stenosis: systematic review and meta-analysis. *J Vasc Access* 2020;21:357-365
 33. Kennedy SA, Mafeld S, Baerlocher MO, Jaber A, Rajan DK. Drug-coated balloon angioplasty in hemodialysis circuits: a systematic review and meta-analysis. *J Vasc Interv Radiol* 2019;30:483-494.e1
 34. Bolton CH, Downs LG, Victory JG, Dwight JF, Tomson CR, Mackness MI, et al. Endothelial dysfunction in chronic renal failure: roles of lipoprotein oxidation and pro-inflammatory cytokines. *Nephrol Dial Transplant* 2001;16:1189-1197
 35. Roy-Chaudhury P, Sukhatme VP, Cheung AK. Hemodialysis vascular access dysfunction: a cellular and molecular viewpoint. *J Am Soc Nephrol* 2006;17:1112-1127
 36. Diskin CJ. Novel insights into the pathobiology of the vascular access—Do they translate into improved care? *Blood Purif* 2010;29:216-229
 37. Katsanos K, Spiliopoulos S, Kitrou P, Krokidis M, Karnabatidis D. Risk of death following application of paclitaxel-coated balloons and stents in the femoropopliteal artery of the leg: a systematic review and meta-analysis of randomized controlled trials. *J Am Heart Assoc* 2018;7:e011245
 38. Dinh K, Limmer AM, Paravastu SCV, Thomas SD, Bennett MH, Holden A, et al. Mortality after paclitaxel-coated device use in dialysis access: a systematic review and meta-analysis. *J Endovasc Ther* 2019;26:600-612