



Mediastinal Emphysema, Giant Bulla, and Pneumothorax Developed during the Course of COVID-19 Pneumonia

Ruihong Sun, MD^{1*}, Hongyuan Liu, MD^{2*}, Xiang Wang, MD¹

¹Department of Radiology, Central Hospital of Wuhan, Tongji Medical College, Huazhong University of Science and Technology, Wuhan, China;

²Cancer Center, Union Hospital, Tongji Medical College, Huazhong University of Science and Technology, Wuhan, China

The coronavirus disease 2019 (COVID-19) pneumonia is a recent outbreak in mainland China and has rapidly spread to multiple countries worldwide. Pulmonary parenchymal opacities are often observed during chest radiography. Currently, few cases have reported the complications of severe COVID-19 pneumonia. We report a case where serial follow-up chest computed tomography revealed progression of pulmonary lesions into confluent bilateral consolidation with lower lung predominance, thereby confirming COVID-19 pneumonia. Furthermore, complications such as mediastinal emphysema, giant bulla, and pneumothorax were also observed during the course of the disease.

Keywords: COVID-19; Coronavirus; Pneumonia; Complication; Tomography, X-ray computed

INTRODUCTION

Since December 2019, several cases of “a new coronavirus infection” having an unknown origin have emerged from the city of Wuhan in China’s Hubei province (1, 2). The novel coronavirus was identified on January 6, 2020 and was termed as 2019-nCoV (3); the virus was speculated to be linked to the Huanan Seafood Market, Wuhan. As of February 25, 2020, widespread human-to-human transmission has resulted in 80239 cases in 26 countries, with 2701 deaths (4). To date, there have been few reports on chest computed tomography (CT) findings of complications arising from severe coronavirus disease 2019 (COVID-19) pneumonia. We reviewed a case of COVID-19 pneumonia with mediastinal emphysema, giant bulla, and pneumothorax.

Received February 26, 2020; accepted after revision March 5, 2020.

*These authors contributed equally to this work.

Corresponding author: Xiang Wang, MD, Department of Radiology, Central Hospital of Wuhan, Tongji Medical College, Huazhong University of Science and Technology, Shengli Street No. 26, Jiangan District, Wuhan 430014, China.

• Tel: (86) 13971369643 • Fax: (86) 65697500

• E-mail: wangxiang385@aliyun.com

This is an Open Access article distributed under the terms of the Creative Commons Attribution Non-Commercial License (<https://creativecommons.org/licenses/by-nc/4.0>) which permits unrestricted non-commercial use, distribution, and reproduction in any medium, provided the original work is properly cited.

CASE REPORT

A 38-year-old man from Wuhan, the epicenter of the COVID-19 outbreak, presented with binaural hearing loss and tinnitus lasting for two months. He underwent endoscopic tympanometry on January 16; on the second postoperative day, he went outdoors and caught a cold. His body temperature was elevated to 38.1°C.

Laboratory examination revealed a normal percentage neutrophil count (75%, normal range: 40–75%) and a decreased percentage lymphocyte count (14.8%, normal range: 20–50%). Screening was negative for multiple respiratory pathogens including influenza A, influenza B, respiratory syncytial virus, adenovirus, human parainfluenza virus, *mycoplasma pneumoniae*, and *chlamydia pneumoniae*. The patient’s sputum tested positive for 2019-nCoV in a real-time polymerase chain reaction assay.

On January 26, the patient developed a high fever and cough and was initiated on high-flow nasal cannula (HFNC) oxygen therapy. The fraction of inspired O₂ (FiO₂) was 80%, while the gas flow-rate was 20 L/min. The patient was continued on HFNC oxygen therapy from January 26 to February 4. On February 1, he suffered from chest tightness and palpitation. The arterial oxygen saturation (SpO₂) could reach 90% after oxygen therapy. On February 5, he exhibited aggravated dyspnea and severe hypoxemia (SpO₂ < 70%). He received non-invasive mechanical ventilation in

the intensive care unit until February 10 with symptomatic relief. The initial FiO₂ was 60%, while the gas flow-rate was 50 L/min. The modes used were pressure support ventilation and positive end-expiratory pressure with 1.18 KPa (12 cmH₂O) and 0.98 KPa (10 cmH₂O), respectively. Thereafter, the patient continued to receive HFNC oxygen therapy until the last follow-up CT scan.

The initial chest CT showed ground-glass opacities (GGO) in the left lower lobe (Fig. 1A). Over the next 10 days, the lesions increased in extent and density and progressed to consolidation (Fig. 1B-D). The clinical symptoms deteriorated, and acute respiratory distress syndrome was diagnosed. A follow-up CT scan revealed emphysema (Figs. 1D, 2A, B). After 15 days of supportive treatment, chest CT showed an improvement in the pulmonary lesions, disappearance of the mediastinal emphysema, and appearance of a giant bulla in the left lung (Figs. 1E, F, 2C, D). Eight days later, the final follow-up CT scan revealed a small pneumothorax and pleural effusion in the left thorax (Figs. 1F, 2E, F).

DISCUSSION

Due to its high sensitivity and ease-of-use, chest CT is an important screening tool for suspected COVID-19 patients. The most common CT finding in COVID-19 pneumonia is GGO in the subpleural regions of the lower lobes (5). These findings are mainly seen in the early stages of COVID-19 pneumonia and may be attributed to alveolar swelling, a small amount of exudation in the alveolar space, and alveolar septal inflammation caused by infection (6). Some cases respond poorly to treatment, and localized lung lesions progress to multiple and diffuse lesions.

This case, occurring in the epicenter of the COVID-19 pneumonia outbreak, illustrates the potential severity of this disease. Serial follow-up chest CT showed the progression of the pulmonary lesions into confluent bilateral consolidation with a lower lung predominance. The patient did not have a history of pneumothorax or any underlying pulmonary disease; no abnormalities, such as a small bulla or emphysema, were observed in the initial CT

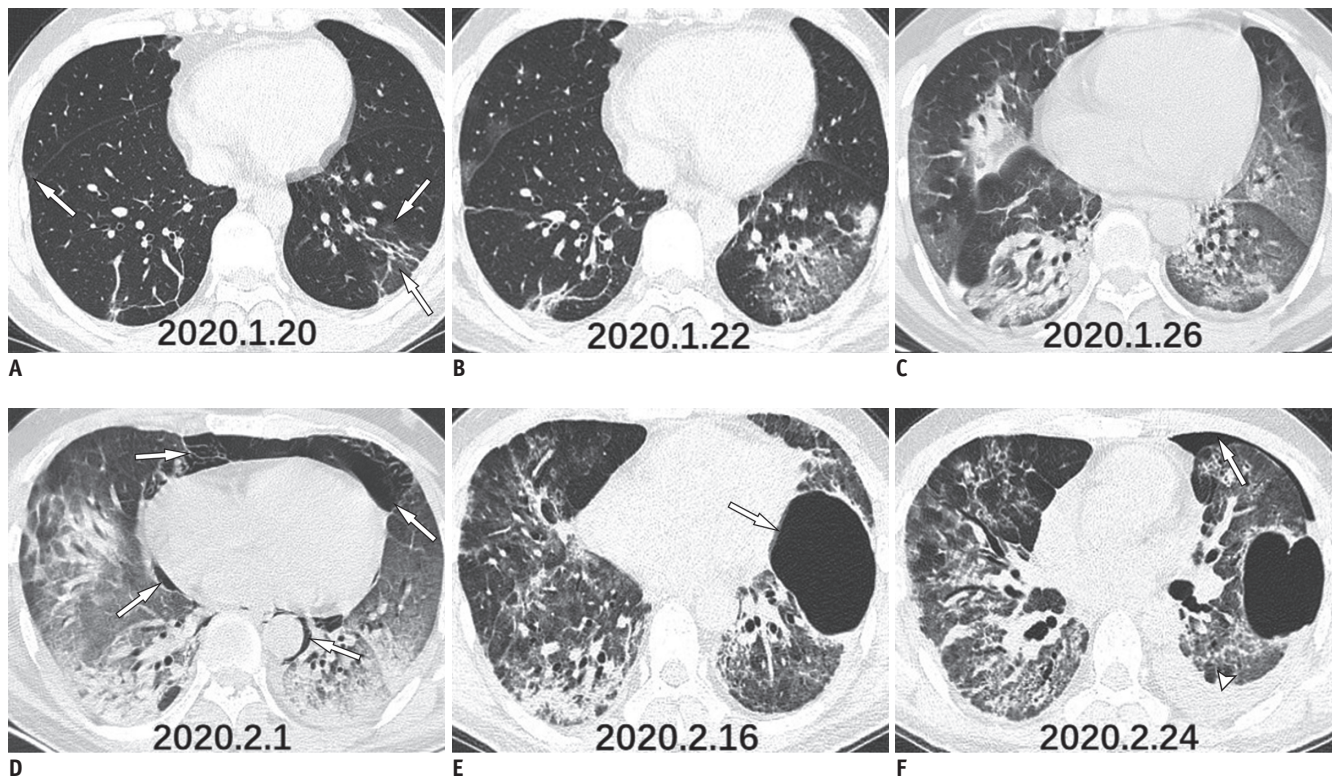


Fig. 1. CT scans of 38-year-old man who presented with fever.

A. Chest CT scan shows multifocal GGO along bronchovascular bundles and subpleural areas (arrows). **B, C.** CT scans obtained on day 3 and 7 show rapid progression of GGO and consolidation in both lower lung zones. **D.** Chest CT scan obtained on day 11 shows bilateral subpleural consolidation and mediastinal emphysema (arrows). **E.** After serial supportive measures, chest CT scan obtained on day 26 shows improvement of pulmonary lesions and mediastinal emphysema; however, giant bulla (arrow) is noted in left lung. **F.** Final follow-up CT scan obtained on day 34 shows pneumothorax (arrow) and pleural effusion (arrowhead) in left thorax. GGO = ground-glass opacities

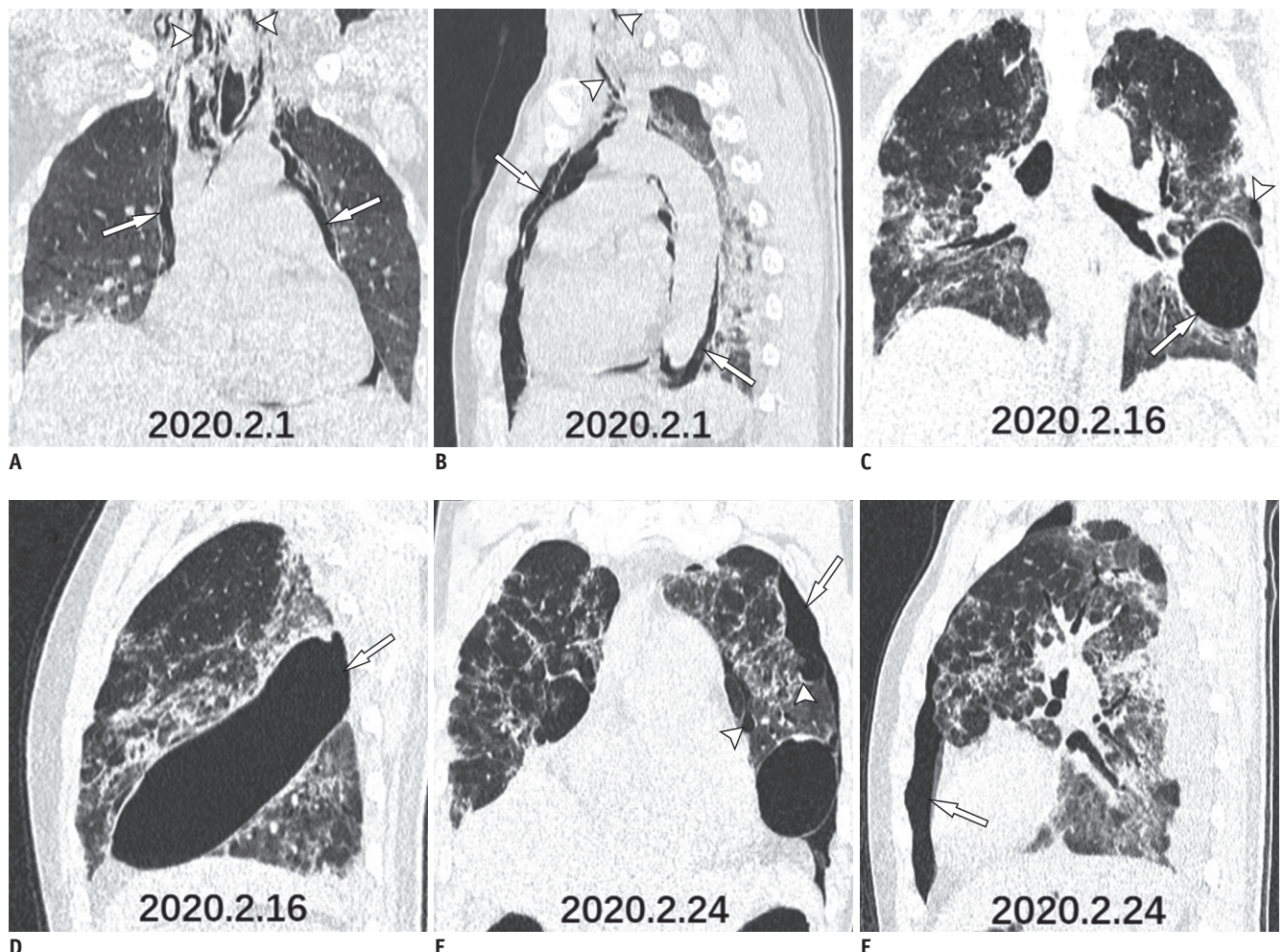


Fig. 2. Coronal and sagittal thin-slice chest CT images.

A, B. Chest CT scans showing pneumomediastinum (arrows) extending up toward neck (arrowheads). **C, D.** CT scan obtained on day 26 shows giant bulla (5.2 × 4.9 × 15.0 cm) in left lung (arrows) and another bulla (arrowhead). **E, F.** Final follow-up CT scan obtained on day 34 shows pneumothorax in left thorax (arrows) and bullae (arrowheads).

scan. The patient had no history of smoking. As a result of diffuse alveolar injury in severe COVID-19 pneumonia, the alveoli may be prone to rupturing. Furthermore, the patient developed a pronounced cough, which may also induce alveolar rupture. Mediastinal emphysema results from a sudden increase in the alveolar pressure, causing alveolar rupture and air leakage with interstitial emphysema (7); this can be observed in the severe acute respiratory syndrome (8). In addition to the giant bulla, chest CT also revealed multiple bullae in the subpleural lung zones (arrowheads; Fig. 2C, E), where pneumonic consolidation was more prominent than in the contralateral areas, which could easily rupture and cause pneumothorax. While mediastinal emphysema and pneumothorax are well-known complications of mechanical ventilation, the patient only received HFNC oxygen therapy before the emphysema

occurred. Therefore, in this particular case, we speculate that the mediastinal emphysema and pneumothorax may be related to COVID-19 pneumonia.

In conclusion, we reported the CT findings in a patient with COVID-19 pneumonia who developed mediastinal emphysema and pneumothorax. Once the signs of these complications are observed during the course of COVID-19 pneumonia, special attention should be paid, and active measures should be taken. Therefore, early imaging diagnosis and timely treatment of COVID-19 complications can improve the therapeutic effect and reduce mortality.

Conflicts of Interest

The authors have no potential conflicts of interest to disclose.

ORCID iDs

Xiang Wang

<https://orcid.org/0000-0002-6876-4264>

Ruihong Sun

<https://orcid.org/0000-0002-9843-707X>

Hongyuan Liu

<https://orcid.org/0000-0002-9272-852X>

REFERENCES

1. Zhu N, Zhang D, Wang W, Li X, Yang B, Song J, et al.; China Novel Coronavirus Investigating and Research Team. A novel coronavirus from patients with pneumonia in China, 2019. *N Engl J Med* 2020;382:727-733
2. Huang C, Wang Y, Li X, Ren L, Zhao J, Hu Y, et al. Clinical features of patients infected with 2019 novel coronavirus in Wuhan, China. *Lancet* 2020;395:497-506
3. Li Q, Guan X, Wu P, Wang X, Zhou L, Tong Y, et al. Early transmission dynamics in Wuhan, China, of novel coronavirus-infected pneumonia. *N Engl J Med* 2020 Jan 29 [Epub]. <https://doi.org/10.1056/NEJMoa2001316>
4. World Health Organization. Coronavirus disease 2019 (COVID-19) situation report-36. Available at: https://www.who.int/docs/default-source/coronaviruse/situation-reports/20200225-sitrep-36-covid-19.pdf?sfvrsn=2791b4e0_2. Accessed February 25, 2020
5. Lin X, Gong Z, Xiao Z, Xiong J, Fan B, Liu J. Novel coronavirus pneumonia outbreak in 2019: computed tomographic findings in two cases. *Korean J Radiol* 2020;21:365-368
6. Xu Z, Shi L, Wang Y, Zhang J, Huang L, Zhang C, et al. Pathological findings of COVID-19 associated with acute respiratory distress syndrome. *Lancet Respir Med* 2020 Feb 18 [Epub]. [https://doi.org/10.1016/S2213-2600\(20\)30076-X](https://doi.org/10.1016/S2213-2600(20)30076-X)
7. Park SJ, Park JY, Jung J, Park SY. Clinical manifestations of spontaneous pneumomediastinum. *Korean J Thorac Cardiovasc Surg* 2016;49:287-291
8. Ooi GC, Khong PL, Müller NL, Yiu WC, Zhou LJ, Ho JC, et al. Severe acute respiratory syndrome: temporal lung changes at thin-section CT in 30 patients. *Radiology* 2004;230:836-844