



Neuroimaging in Randomized, Multi-Center Clinical Trials of Endovascular Treatment for Acute Ischemic Stroke: A Systematic Review

Chong Hyun Suh, MD¹, Seung Chai Jung, MD, PhD¹, Byungjun Kim, MD, PhD², Se Jin Cho, MD¹, Dong-Cheol Woo, PhD³, Woo Yong Oh, MA⁴, Jong Gu Lee, PhD⁴, Kyung Won Kim, MD, PhD^{1, 5}

¹Department of Radiology and Research Institute of Radiology, University of Ulsan College of Medicine, Asan Medical Center, Seoul, Korea;

²Department of Radiology, Korea University Anam Hospital, Korea University College of Medicine, Seoul, Korea; ³Bioimaging Center, Biomedical Research Center, Asan Institute for Life Sciences, Asan Medical Center, Seoul, Korea; ⁴Clinical Research Division, National Institute of Food and Drug Safety Evaluation, Ministry of Food and Drug Safety, Cheongju, Korea; ⁵Asan Image Metrics, Clinical Trial Center, Asan Institute for Life Sciences, Asan Medical Center, Seoul, Korea

Appropriate use and analysis of neuroimaging techniques is an inevitable aspect of clinical trials for patients with acute ischemic stroke. Neuroimaging examinations were recently used to define the core eligibility criteria and outcomes in acute ischemic stroke research. Recent clinical trials for endovascular treatment in acute ischemic stroke have also demonstrated the efficacy or safety of endovascular treatment using various imaging modalities as well as clinical indices. Furthermore, independent imaging reviews and imaging core laboratory assessments are essential to manage and analyze imaging data in order to enhance the reliability of the outcomes. Therefore, we systematically reviewed the use of neuroimaging in recent randomized clinical trials for endovascular treatment of acute ischemic stroke in order to provide a thorough summary, which would serve as a resource guiding the use of appropriate imaging protocols and analyses in future clinical trials for acute ischemic stroke. This review will help researchers select appropriate imaging biomarkers among the various imaging protocols available and apply the selected type of imaging examination for each study in accordance with the academic purpose.

Keywords: Acute ischemic stroke; Endovascular treatment; Clinical trials; Neuroimaging; Systematic review

INTRODUCTION

In clinical trials for acute ischemic stroke, imaging modalities such as computed tomography (CT) or magnetic resonance imaging (MRI) may play critical roles by ruling out acute hemorrhage, allowing detection of the infarct

core or vessel occlusion, evaluating collateral circulation, and assessing the penumbra (1, 2). In 1995, the European Cooperative Acute Stroke Study (ECASS) and The National Institute of Neurological Disorders and Stroke rt-PA stroke study group used noncontrast-enhanced CT (NECT) findings as the eligibility criteria and safety outcomes for detection of intracranial hemorrhage (3, 4). In seven recent successful clinical trials for determining the efficacy of endovascular treatment (endovascular mechanical thrombectomy) in acute ischemic stroke (5-11), neuroimaging was used not only for selecting eligible patients for the trials but also for evaluating one of the primary or secondary outcomes. The recommendations from the American Heart Association/American Stroke Association (AHA/ASA) 2018 guidelines for the early management of patients with acute ischemic stroke reconfirmed the role of imaging modalities in diagnosing acute ischemic stroke and guiding treatment options (2).

Received June 4, 2019; accepted after revision October 1, 2019. This study was supported by a grant from the Ministry of Food and Drug Safety in 2018 (No. 18182MFDS402).

Corresponding author: Seung Chai Jung, MD, PhD, Department of Radiology and Research Institute of Radiology, University of Ulsan College of Medicine, Asan Medical Center, 88 Olympic-ro 43-gil, Songpa-gu, Seoul 05505, Korea.

- Tel: (822) 3010-3949 • Fax: (822) 476-4719
- E-mail: dynamics79@gmail.com

This is an Open Access article distributed under the terms of the Creative Commons Attribution Non-Commercial License (<https://creativecommons.org/licenses/by-nc/4.0>) which permits unrestricted non-commercial use, distribution, and reproduction in any medium, provided the original work is properly cited.

Appropriate use and analysis of imaging techniques is essential for successfully conducting clinical trials for acute ischemic stroke. Imaging-based outcomes such as the infarct core volume, including infarct growth, revascularization, recanalization, and reperfusion as well as hemorrhage, are gaining popularity as primary or secondary outcomes in clinical trials for acute ischemic stroke (5-20). In addition, independent imaging reviews and imaging core laboratory assessments are essential for conducting clinical trials with reliable imaging-based outcomes.

Recent clinical trials for acute ischemic stroke applied various imaging modalities to each study appropriately by using NECT, CT angiography (CTA, single-phase or multiple-phase), CT perfusion (CTP), diffusion-weighted imaging (DWI), MR angiography (MRA), T2*-weighted gradient echo (GRE), MR perfusion (MRP), or fluid attenuated inversion recovery (FLAIR).

Therefore, we systematically reviewed the use of neuroimaging in recent, randomized clinical trials for the efficacy of endovascular treatment for acute ischemic stroke so as to provide a thorough summary that could serve as a resource guiding the use of appropriate imaging protocols and analyses in future clinical trials for acute ischemic stroke. This review will help researchers select appropriate imaging biomarkers among the various imaging protocols available and apply the selected imaging biomarkers to each study in accordance with the purpose.

MATERIALS AND METHODS

This study was performed and reported in accordance with the Preferred Reporting Items for Systematic Reviews and Meta-Analyses guidelines (21). The following research questions were established: What are the roles, appropriate protocols, and reviewing systems for neuroimaging assessments in randomized, multi-center clinical trials of endovascular treatment for acute ischemic stroke?

Literature Search

A systematic, computerized search of Ovid-MEDLINE and EMBASE was performed to identify published randomized trials of endovascular treatment for acute ischemic stroke. The search terms were as follows: ((stroke)) AND ((thrombectomy)) AND ((randomized) OR (randomly)). The databases were searched for articles published on or before May 22, 2018. This systematic, computerized search was limited to clinical trials. The bibliographies of the identified

articles were screened manually to expand the literature search. Our search was not limited by sample size, type of design, endpoint selection, or blinding. There were also no limits related to the language of publication, the trial's geographic origin, or sponsorship.

Eligibility Criteria

Randomized trials of endovascular treatment for acute ischemic stroke were included. Conference abstracts without published full texts were not considered to be eligible for this study. Review articles, non-randomized trials, protocols, observational studies, and case reports were also excluded. Subgroup analyses or sequential studies of original randomized trials were excluded.

Data Extraction

A standardized, predesigned data extraction form was used. The data were independently extracted from each eligible randomized trial by two authors. Publication year, sample size, eligibility criteria, imaging-based outcomes or radiologic outcomes, imaging core laboratory or imaging core lab, imaging modalities for initial work-up or follow-up imaging, imaging protocols for vessel occlusion or perfusion, use of the Alberta Stroke Program Early CT (ASPECT) score, the definition of the ischemic core, the definition of the penumbra, analysis software, reviewing systems, and standardization were reviewed. The data retrieved from all included trials were cross-checked, and a third author was consulted for consensus in cases of unclear definitions.

RESULTS

Literature Search

The systematic literature search identified 216 articles. Full-text reviews of 21 potentially eligible articles were conducted and five studies were excluded due to the following reasons: two studies assessed intravenous tissue plasminogen activators (IV tPAs) (22, 23), one study was not a randomized trial (24), one study was not in the field of interest (25), and one study was a single-center study (26). Finally, a total of 16 randomized, multi-center clinical trials published between 2012 and 2018 were identified for our study (Fig. 1) (5-20). The eligible trials covered a total of 4080 patients.

Characteristics of the Included Studies

The characteristics of the included trials are described in

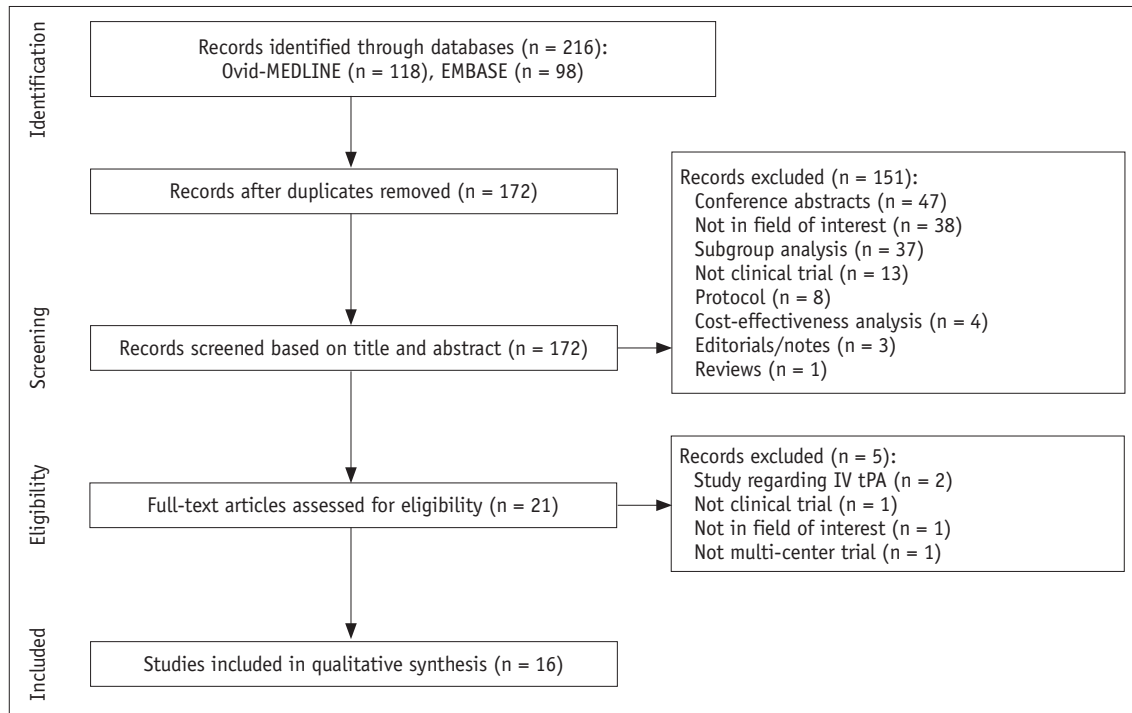


Fig. 1. Study selection protocol. IV tPA = intravenous tissue plasminogen activator

Table 1. The size of the study populations ranged from 65 to 656 patients, and the number of participating centers ranged from 4 to 58. The purpose of the clinical trials was to demonstrate the efficacy or safety of endovascular treatment in comparison with conventional medical treatment. The inclusion criteria for the time after symptom or randomization onset ranged from 5 to 24 hours, which indicates the eligible time to perform endovascular treatment. In the THERAPY trial, the time was 3–4.5 hours based on the IV tPA (14). Other trials applied the following inclusion times on the basis of the endovascular treatment: 6 hours in eight trials (7, 10-13, 15, 17, 18), within 8 hours in four trials (8, 16, 19, 20), and within 12 hours in one trial (9). Two trials (2%) published in 2018 included patients 6–16 hours (6) and 6–24 hours (5) after symptoms onset. The techniques used for endovascular treatments varied from intra-arterial thrombolysis using urokinase, suction or aspiration using a penumbra or catheter, or stent retriever. Four clinical trials used a single device for endovascular treatment, including the Solitaire (7-10) and Trevo retrieval stent (5). Three clinical trials compared the efficacy and safety of the devices as follows: comparison between aspiration and stent retriever treatment (13); between Solitaire stent and Merci device (19); and between Trevo and Merci device (20). Only 10 of the 16 trials

demonstrated the efficacy of endovascular treatments (5-11, 15, 19, 20).

Eligibility and Neuroimaging Criteria for Acute Ischemic Stroke Trials

The eligibility and neuroimaging criteria used in the included trials are described in Tables 1 and 2. All trials except the SYNTHESIS trial included patients with arterial occlusion that was assessed on vessel imaging. Among the 15 trials, 10 included only anterior circulation occlusion (internal carotid artery [ICA] and the middle cerebral artery [MCA]) (5-10, 12-14, 16), 1 included only anterior circulation occlusion (anterior cerebral artery as well as ICA or MCA) (11), and 4 included posterior circulation (basilar artery or vertebral artery) as well as anterior circulation (15, 18-20). Although most trials used CTA or MRA for vessel imaging, two trials used only CTA (7, 14), two trials used only digital subtraction angiography (DSA) (19, 20), and one trial included transcranial Doppler ultrasonography as well as CTA, MRA, or DSA (11). Neuroimaging played a critical role in the exclusion criteria in the trials for detecting intracranial hemorrhage, significant mass effect with midline shift, intracranial tumors except small meningiomas, extensive infarct core volumes, and pre-existing proximal arterial

Table 1. Characteristics of Included Clinical Trials

Author	Publication Year	Trial Nickname	No. of Patients (n)	No. of Centers	Purpose	Inclusion Time* (Hours)	Eligibility	
							Inclusion	Inclusion: Neuroimaging
Nogueira et al. (5)	2018	DAWN	206	26	Efficacy of EVT	6–24	1) Ineligible or failed respond to IV tPA, 2) NIHSSs 10–42	1) Mismatch between clinical and infarct volume on CT or MR, 2) occlusion of intracranial ICA or M1 on CTA or MRA
Albers et al. (6)	2018	DEFUSE 3	182	38	Efficacy of EVT	6–16	NIHSSs \geq 6	1) Mismatch between infarct volume and penumbra on CT or MR ¹ , 2) occlusion of ICA and M1 on CTA or MRA
Muir et al. (12)	2017	PISTE	65	10	Efficacy of EVT	6	NIHSSs \geq 6	Occlusion of intracranial ICA, M1, or single M2 on CTA or MRA
Lapergue et al. (13)	2017	ASTER	381	8	Comparison of aspiration and stent retrieval	6	-	Occlusion of intracranial ICA, M1, or M2 on CTA or MRA
Mocco et al. (14)	2016	THERAPY	108	36	Efficacy of EVT		NIHSSs \geq 8	Occlusion of intracranial ICA and MCA on CTA and thrombus > 8 mm on CT
Bracard et al. (15)	2016	THRACE	414	26	Efficacy of EVT	5	NIHSSs 10–25	Occlusion of intracranial ICA, M1, or upper 1/3 BA on CTA or MRA
Saver et al. (7)	2015	SWIFT PRIME	196	39	Efficacy of EVT	6	NIHSSs 8–29	Occlusion of intracranial ICA and M1 on CTA or MRA (TICI 0–1)
Jovin et al. (8)	2015	REVASCAT	206	4	Efficacy of EVT	8	1) Ineligible or failed respond to IV tPA, 2) NIHSSs \geq 6	Occlusion of intracranial ICA or M1 on CTA, MRA, or DSA (TICI 0–1)
Goyal et al. (9)	2015	ESCAPE	316	22	Efficacy of EVT	12	NIHSSs > 5	1) Infarct core (small: ASPECTs 6–10) on NECT, 2) occlusion of carotid T/L and M1/immediate M2 on CTA, 3) moderate-to-good collaterals (filling of 50% or more of MCA) on CTA [‡] , 4) groin puncture \leq 60 min after NECT and CT-to-recanalization time \leq 90 min
Campbell et al. (10)	2015	EXTEND-IA	70	14	Efficacy of EVT	6	-	1) Occlusion of ICA, M1, or M2 on CTA or MRA, 2) infarct core volume (< 70 mL on CTP-CBF or DWI), 3) mismatch between infarct core and penumbra on CT or MR ¹
Berkhemer et al. (11)	2015	MR CLEAN	500	16	Efficacy of EVT	6	NIHSSs \geq 2	Occlusion of intracranial ICA, M1–2, A1–2 on CTA, MRA, DSA, or TCD
Kidwell et al. (16)	2013	MR RESCUE	127	22	Efficacy of EVT and penumbral imaging	8	1) Ineligible or failed respond to IVT, 2) NIHSSs 6–29	1) Occlusion of ICA, M1–2 on CTA or MRA, 2) multimodal CT or MR (MR RESCUE protocol)
Ciccone et al. (17)	2013	SYNTHESIS	362	24	Efficacy of EVT	6	-	-
Broderick et al. (18)	2013	IMS III	656	58	Efficacy of EVT	5	NIHSSs \geq 10 or 8–9 with occlusion of ICA or M1 or BA	Occlusion of ICA or M1 or BA on CTA in NIHSSs 8–9
Saver et al. (19)	2012	SWIFT	113	18	Efficacy and safety of solitaire	8	1) Ineligible or failed respond to IVT, 2) NIHSSs 8–30	Occlusion of M1, M2, ICA, BA, or VA on DSA (TIMI 0–1)
Nogueira et al. (20)	2012	TREVO 2	178	27	Efficacy and safety of Trevo	8	1) Ineligible or failed respond to IVT, 2) NIHSSs 8–29	Occlusion of M1, M2, ICA, BA, or VA on DSA

*Inclusion time means eligible time to perform EVT, ¹Definition of mismatch were as follows: infarct core volume < 70 mL, penumbral to infarct core volume \geq 1.8, absolute penumbral volume (Tmax > 6 s) \geq 15 mL in DEFUSE 3 trial; infarct core volume > 50 mL, severe penumbral volume (Tmax \geq 10 s) \geq 100 mL, or penumbral to infarct core volume \leq 1.8 and penumbral volume < 15 mL in SWIFT PRIME trial; infarct core volume < 70 mL on CTP-CBF or DWI, mismatch ratio > 1.2, and absolute mismatch volume > 10 mL (infarct core: CTP-CBF < 30% of normal tissue; penumbra: Tmax > 6 s on CTP or MRP) in EXTEND-IA trial, [‡]Multiphase CTA was preferred. ASPECTs = Alberta Stroke Program Early CT score, BA = basilar artery, CBF = cerebral blood flow, CT = computed tomography, CTA = CT angiography, CTP = CT perfusion, DSA = digital subtraction angiography, DWI = diffusion-weighted imaging, EVT = endovascular treatment, ICA = internal carotid artery, IV tPA = intravenous tissue plasminogen activator, MCA = middle cerebral artery, MR = magnetic resonance, MRA = MR angiography, MRP = MR perfusion, NECT = noncontrast-enhanced CT, NIHSSs = National Institutes of Health Stroke Scale score, TCD = transcranial Doppler, TICI = thrombolysis in cerebral infarction scale, TIMI = thrombolysis in myocardial ischemia, Tmax = time to maximum of residue function, VA = vertebral artery

Table 2. Eligibility, Outcomes, Conclusion of Included Clinical Trials

Trial Nickname	Eligibility Exclusion: Neuroimaging	Outcomes				Conclusion
		Primary	Secondary	Safety	Imaging	
DAWN	1) Intracranial hemorrhage, 2) significant mass effect and midline shift, 3) intracranial tumor on CT or MR, 4) steno-occlusion or tortuosity of cervical ICA on CTA or MRA	mRS*	Clinical indexes, infarct core volume, recanalization, reperfusion	1) Death (90 days), 2) SICH (24 hours), 3) NIHSSs increase, 4) SAE	Included in second outcomes	Positive
DEFUSE 3	1) ASPECTs < 6 on NECT, 2) significant mass effect and midline shift on 3) intracranial tumor on CT or MR, 4) ICA dissection of cervical ICA, 5) ≥ 1 vascular territory infarct on CTA or MRA	mRS*	Clinical index	1) Death (90 days), 2) SICH (36 hours), 3) SAE	1) Infarct core volume, 2) recanalization, 3) reperfusion	Positive
PISTE	1) Intracranial hemorrhage, 2) infarct (> 1/3 MCA hypodensity), 3) occlusion of extracranial ICA or BA	mRS*	Clinical indexes, recanalization	1) Death (90 days), 2) SICH (24 hours), 3) procedural complication	Reperfusion [†]	Negative
ASTER	Occlusion of cervical carotid artery	Revascularization	Clinical indexes, revascularization, time to successful revascularization	1) Procedural complication, 2) intracranial hemorrhage (24 hours)	Included in primary and secondary outcomes	No difference
THERAPY	1) Significant mass effect with midline shift, 2) infarct (acute ischemic change) > 1/3 of MCA territory, 3) intracranial hemorrhage, 4) intracranial tumor, 5) ipsilateral extracranial steno-occlusion, 6) preexisting arterial injury	mRS*	Clinical indexes, infarct core volume	1) SAE, 2) SICH (24 hours), 3) death (90 days)	Included in second outcomes	Negative
THRACE	1) Steno-occlusion of ipsilateral cervical carotid artery, 2) intracranial hemorrhage, 3) intracranial tumor, 4) mass effect with midline shift on CT or MR	mRS*	Clinical indexes	1) Death (90 days), 2) hemorrhage (24 hours), 3) procedural complication	None	Positive
SWIFT PRIME	1) ASPECTs < 6 on NECT or DWI, 2) > 1/3 MCA territory or > 100 cc in other vascular territory (hypodensity on CT or hyperintensity on MR), 3) intracranial hemorrhage, 4) mass effect, 5) intracranial tumor on CT or MR, 6) occlusion of BA or PCA, 7) occlusion or dissection of cervical ICA on CTA or MRA	mRS*	Clinical indexes, revascularization, reperfusion	1) SAE, 2) SICH (27 hours)	Included in second outcomes and infarct core volume [‡]	Positive
REVASCAT	1) Intracranial hemorrhage, 2) significant mass effect and midline shift, 3) intracranial tumor, 4) steno-occlusion of cervical ICA on CTA, MRA or DSA, 5) infarct volume (ASPECTs < 7 on CT; ASPECTs < 6 on DWI)	mRS*	Clinical indexes, infarct core volume, revascularization, recanalization	1) Death (90 days), 2) SICH (90 days), 3) procedural complication, 4) SAE	Included in second outcomes	Positive
ESCAPE	1) Infarct core (moderate to large: ASPECTs 0–5) on NCCT, 2) infarct core on CTA or CTP (moderate to large: no or minimal collaterals in region greater than 50% of MCA territory compared to contralateral side on CTA, low CBV and very low CBF ASPECT < 6 [\geq 8 cm coverage] or low CBV and very low CBF > 1/3 MCA territory [$<$ 8 cm coverage] on CTP), 3) suspected intracranial dissection, 4) chronic intracranial occlusion	mRS*	Clinical indexes, reperfusion, recanalization	1) Death, 2) SICH, 3) malignant infarct, 4) procedural complication	Included in second outcomes	Positive

steno-occlusions, which represent ineligible conditions for undergoing endovascular treatment. In some trials, neuroimaging was used as a part of the core eligibility criteria for selection of patients with a small infarct or the presence of mismatch between the infarct core volume and the salvageable tissue volume (5-7, 10). This mismatch may have contributed to the extension of the therapeutic time window up to 16 and 24 hours from the

symptom onset for endovascular treatment in the DAWN and DEFUSE 3 trials. The DAWN trial enrolled patients who showed a mismatch between the severity of the clinical deficit and the infarct core volume as seen on DWI or CTP. The mismatch was divided into three groups based on a patient age threshold of 80 years (5). The DEFUSE 3 trial included patients who had an initial infarct core volume < 70 mL, a penumbral tissue volume to initial infarct core

Table 2. Eligibility, Outcomes, Conclusion of Included Clinical Trials (Continued)

Trial Nickname	Eligibility	Outcomes				Conclusion
	Exclusion: Neuroimaging	Primary	Secondary	Safety	Imaging	
EXTEND-IA	1) Infarct volume (hypodensity > 1/3 MCA territory) on NECT, 2) intracranial hemorrhage on CT or MR, 3) difficulty or inability to access to cerebral arteries (proximal stenosis, dissection)	Reperfusion, NIHSSs (3 days)	Clinical indexes, infarct core volume [†] , recanalization	1) Death, 2) SICH, 3) PH	Included in primary and secondary outcomes	Positive
MR CLEAN	Intracranial hemorrhage on CT or MR	mRS*	Clinical indexes, infarct core volume, reperfusion, recanalization	1) Neurologic deterioration, 2) SICH, 3) procedural complication, 4) SAE (death)	Included in second outcomes	Positive
MR RESCUE	1) Intracranial hemorrhage, 2) cervical carotid steno-occlusion on CTA or MRA	mRS*	Clinical indexes, infarct core volume, reperfusion, revascularization	1) Death (90 days), 2) ICH (7 days), 3) SAE	Included in second outcomes	Negative
SYNTHESIS	1) Intracranial hemorrhage, 2) intracranial tumor except small meningioma, 3) acute infarct (may be > 4.5 hours after onset)	mRS*	Clinical indexes	1) Hemorrhage, 2) infarct, 3) death, 4) NIHSSs ≥ 4 increase, 5) extracerebral events at 7 days	None	Negative
IMS III	1) Infarct (> 1/3 of MCA territory), 2) intracranial hemorrhage, 3) significant mass effect with midline shift, 4) intraparenchymal tumor, 5) baseline CTA without evidence of arterial occlusion	mRS*	Clinical indexes, infarct core volume, reperfusion, recanalization	1) Death, 2) hemorrhage, 3) major complication due to nonintracerebral bleeding, 4) recurrent stroke, 5) device or procedural complication	Included in second outcomes	Negative
SWIFT	1) Infarct volume (> 1/3 MCA territory or > 100 cc of volume), 2) intracranial hemorrhage, 3) intracranial tumor or mass effect on CT or MR, 4) complete cervical carotid occlusion, carotid dissection on DSA	Recanalization	Clinical indexes, time to successful recanalization	1) SICH, 2) death, 3) SAE	Included in primary outcomes	Positive
TREVO 2	1) Infarct volume (> 1/3 MCA territory or > 100 cc of volume), 2) intracranial hemorrhage, 3) significant mass effect with midline shift, 4) intracranial tumor on CT or MR, 5) cervical carotid steno-occlusion including excessive tortuosity	Reperfusion	Clinical indexes, time to successful reperfusion, asymptomatic SICH	1) Death, 2) SICH, 3) SAE, 4) device or procedural complication	Included in primary outcomes	Positive

*mRS was evaluated at 90 days after symptom onset or randomization, [†]Tertiary outcomes, [‡]Additional outcomes. CBV = cerebral blood volume, ICH = intracranial hemorrhage, mRS = modified Rankin scale, NCCT = noncontrast CT, PCA = posterior cerebral artery, PH = parenchymal hematoma, SAE = severe adverse event, SICH = symptomatic intracranial or intracerebral hemorrhage

volume ratio ≥ 1.8 , and an absolute volume of penumbra ≥ 15 mL based on CTP, MRP, or DWI (6).

Penumbral Imaging

The DEFUSE 3, SWIFT PRIME, and EXTEND-IA trials used penumbral imaging data representing the mismatch between the volume of the ischemic core and salvageable tissue as eligibility criteria (6, 7, 10). The DEFUSE 3 and EXTEND-IA trials defined the penumbral volume as the time to a maximum of the residue function (Tmax) value > 6 seconds and the definition of the infarct core volume was relative to cerebral blood flow (CBF) $< 30\%$, which was analyzed based on the software Rapid processing of Perfusion and Diffusion (RAPID, iSchemaView, Menlo Park, CA, USA) (6, 10). The SWIFT PRIME trial used penumbral imaging findings as the exclusion criteria (7). The DAWN trial used the mismatch between the severity of the clinical deficit and the infarct core volume, representing the infarct core volume on DWI or CTP-CBF to the National Institutes of Health Stroke Scale (NIHSS) score (5) (Table 1).

Outcomes in the Acute Ischemic Stroke Trials

The outcomes and the neuroimaging data used in assessing the outcomes of the included trials are described in Table 2. Revascularization, reperfusion, or recanalization was adopted as the primary outcome in four trials (10, 13, 19, 20), while other trials used the modified Rankin scale (mRS) score at 90 days as the primary outcome. Thirteen trials used imaging-based outcomes as secondary ($n = 12$) or tertiary ($n = 1$) outcomes as well as clinical indices such as the mRS score, the NIHSS score, Barthel index, and the EuroQol EQ-5D questionnaire score. Among the 13 trials, 7 and 12 adopted the infarct core volume and revascularization, reperfusion, or recanalization as secondary or tertiary outcomes, respectively. With respect to safety outcomes, neuroimaging was mainly used for detection of hemorrhage or malignant infarcts. The DEFUSE 3 trial presented imaging outcomes, including the infarct core volume, reperfusion, and recanalization separately from the primary or secondary outcomes (6). The PISTE trial separately presented reperfusion as a procedural outcome (12). The SWIFT PRIME trial presented infarct core volume as an additional outcome (7). The EXTEND-IA presented the infarct core volume (growth), reperfusion, and recanalization as tertiary outcomes (10).

Imaging-Based Outcomes for the Acute Ischemic Stroke Trial

Imaging-based outcomes and their definitions are described in Tables 3 and 4. The infarct core volume and infarct growth were assessed on CT or MR in the enrolled trials. The definition in each imaging modality does not appear to have been disclosed completely across the published articles, supplementary appendices, and protocols in some trials.

The THERAPY and IMS III trial evaluated the infarct core volume using the ASPECT score. All trials that adopted infarct core volume as an outcome used semi- or automated algorithms to segment the infarct core volume, except the THERAPY trial. RAPID was the most commonly used software ($n = 4$) and Olea (Olea Medical, La Ciotat, France) software was used as an alternative ($n = 1$). The REVASCAT trial used a semi-automated algorithm with a threshold-based region growing fashion, Quantomo (27). The MR RESCUE trial used a study-specific predictive model for assessing the initial infarct core volume, which was presented in the MR RESCUE protocol, and employed the hyperintensity in FLAIR and hypodensity in CT to determine the final infarct volume. The MR CLEAN trial used a semi-automated algorithm, with the intensity-based region growing algorithm centered on the seed point by an experienced radiologist, for determining the infarcted hypo-attenuated area on NECT (28).

Revascularization, reperfusion, or recanalization were interchangeably used for evaluation of the patency or perfusion in proximal arteries, distal vessels, or the downstream vascular territory. Revascularization was used in four trials as follows: DSA with the modified thrombolysis in cerebral infarction scale (mTICI, 2b–3) in three trials (7, 8, 13) and CTA or MRA with TICI (2a–3) (16). Reperfusion was used in 10 trials as follows: DSA with the mTICI (2b–3) or TICI (2b–3 or 2–3) scales in 7 trials (5–7, 11, 12, 18, 20) and CTP or MRP with the reduction percentage of perfusion lesion volumes in 4 trials (6, 7, 10, 16). Recanalization was used in nine trials as follows: CTA or MRA with various scoring systems in eight trials (5–12, 18) and DSA with the thrombolysis in myocardial ischemia (TIMI) (2–3) scale in one trial (19). The various scoring systems for recanalization included the modified arterial occlusive lesion scale (mAOL), TIMI, and the third international stroke trial CTA score (29) (Table 4). Recanalization was mainly evaluated between baseline and follow-up imaging assessments on CTA or MRA. Among the eight trials, the ESCAPE trial involved follow-up imaging at 2–8 hours (9), and the other seven trials

Table 3. Outcome Data for Infarct Core Volume and Hemorrhagic Transformation

Trial Nickname	Infarct Core Volume				Hemorrhagic Transformation
	Baseline	24 Hours	5–7 Days or Discharge	Definition	Classification
DAWN	DWI, CTP	DWI, NECT	-	RAPID [†] (with semi-automated algorithm using manual lesion outlining; CTP-CBF, < 30% of contralateral normal tissue; DWI, based ADC) Manually outlining hypodense lesion (NECT)	ECASS
DEFUSE 3	DWI, CTP	MR (DWI), CT	-	RAPID	ECASS
PISTE	-	-	-	-	ECASS (PH 1, 2), SITS-MOST
ASTER	-	-	-	-	ECASS
THERAPY	CT	CT	-	ASPECTs	ECASS
THRACE	-	-	-	-	ECASS
SWIFT PRIME	DWI, CTP	DWI/FLAIR/MRP, NECT/CTP*	-	RAPID (DWI [ADC], < 620 x 10 ⁶ mm ² ; CTP-CBF, > 70% reduced region)	ECASS
REVASCAT	DWI, NECT	DWI, NECT	-	Quantomo	ECASS, SITS-MOST
ESCAPE	-	-	-	-	-
EXTEND-IA	CTP	DWI, NECT	-	RAPID (CTP-CBF, automated ischemic core volume < 30% of normal tissue), DWI or NECT (manually outlined)	SITS-MOST
MR CLEAN	NECT, CTP	-	NECT	Semi-automated algorithm for CT hypodensity	ECASS
MR RESCUE	DWI (MRP), CT	-	FLAIR, CT	Study-specific predictive model on baseline, hyperintensity (FLAIR), hypodensity (CT)	ECASS
SYNTHESIS	-	-	-	-	Study specific definitions
IMS III	CT	CT	-	ASPECTs, digital measurement	ECASS
SWIFT	-	-	-	-	ECASS
TREVO 2	-	-	-	-	ECASS, SITS-MOST

*At 27 hours, [†]RAPID, iSchemaView. ADC = apparent diffusion coefficient, ECASS = European cooperative acute stroke study (Hemorrhage was classified based on ECASS study), FLAIR = fluid attenuated inversion recovery, RAPID = Rapid processing of Perfusion and Diffusion, SITS-MOST = Safe Implementation of Thrombolysis in Stroke-Monitoring Study (Hemorrhage was classified based on SITS-MOST study)

involved follow-up imaging at 24 hours after the onset or randomization. The ESCAPE trial preferred to use multiphase CTA for quick determination of the collateral status: the first phase for a conventional arch to vertex CT-angiogram and the next two phases for sequential skull-base to vertex acquisitions obtained in the mid-venous and late venous phases (9).

The DEFUSE3, SWIFT PRIME, EXTEND-IA, and MR RESCUE trials evaluated reperfusion using CTP or MRP. The reperfusion was assessed with the percentage reduction in perfusion lesion volume, which was defined as Tmax > 6 seconds between baseline and follow-up imaging (6, 7, 10, 16). Three trials defined successful reperfusion as a reduction of perfusion lesion volume by 90% or more in the follow-up imaging examination in comparison with the baseline imaging examination (6, 7, 16).

Hemorrhagic transformation was assessed in most trials based on ECASS (n = 13), The Safe Implementation of Thrombolysis in Stroke-Monitoring Study (SITS-MOST, n = 4) or the Study specific definition (n = 1). The SYNTHESIS trial defined a hemorrhagic infarct as one or more hyperdensity areas due to presence of blood, with a speckled or mottled appearance and with indistinct margins, in the context of the area of low attenuation representing infarction or edema. The SYNTHESIS trial defined intracerebral hemorrhage as a very dense, homogeneous region of increased density with distinct margins with or without a mass effect, including all or the major part of the infarcted lesion, on CT. Symptomatic intracerebral hemorrhage in the SITS-MOST protocol was defined as local or remote parenchymal hemorrhage type 2 at 22–36 hours after treatment, which was characterized by neurological

Table 4. Outcome Data for Revascularization, Reperfusion, or Recanalization

Trial Nickname	Revascularization			Reperfusion			Recanalization		
	Imaging	Time Interval	Definition	Imaging	Time Interval	Definition	Imaging	Time Interval	Definition
DAWN	-	-	-	DSA	Post- procedure	mTICI (2b-3)	CTA or MRA	24 hours	No, partial, or complete
DEFUSE 3	-	-	-	1) CTP or MRP, 2) DSA	1) 24 hours, 2) post- procedure	1) Reduction (> 90%) in perfusion lesion volume with Tmax > 6 s, 2) mTICI (2b-3)	CTA or MRA	24 hours	Complete or not
PISTE	-	-	-	DSA	Post- procedure	mTICI (2b-3)	CTA or MRA	24 hours	IST-3 CTA score
ASTER	DSA	Post- procedure	mTICI (2b-3)	-	-	-	-	-	-
THERAPY	-	-	-	-	-	-	-	-	-
THRACE	-	-	-	-	-	-	-	-	-
SWIFT PRIME	DSA	Post- procedure	mTICI (2b-3)	CTP or MRP	27 hours	Reduction (\geq 90%) in perfusion lesion volume	-	-	-
REVASCAT	DSA	Post- procedure	mTICI (2b-3)	-	-	-	CTA or MRA	24 hours	Patent or occluded
ESCAPE	-	-	-	DSA	Post- procedure	TICI (2b-3)	CTA	2-8 hours	mAOL (2-3)
EXTEND-IA	-	-	-	CTP or MRP	24 hours	RAPID (reduction [%] in perfusion lesion volume with Tmax > 6 s)	CTA or MRA	24 hours	TIMI (2-3)
MR CLEAN	-	-	-	DSA	Post- procedure	mTICI (2b-3)	CTA or MRA	24 hours	mAOL (2-3)
MR RESCUE	CTA or MRA	7 days	TICI (2a-3)	CTP or MRP	7 days	Reduction (\geq 90%) in perfusion lesion volume with Tmax > 6 s	-	-	-
SYNTHESIS	-	-	-	-	-	-	-	-	-
IMS III	-	-	-	DSA	Post- procedure	TICI (2-3)	CTA > MRA	24 hours	Partial or complete recanalization
SWIFT	-	-	-	-	-	-	DSA	Post- procedure	TIMI (2-3)
TREVO 2	-	-	-	DSA	Post- procedure	TICI (2-3)	-	-	-

IST-3 CTA score = third international stroke trial CTA score, mAOL = modified arterial occlusive lesion scale, mTICI = modified thrombolysis in cerebral infarction scale

deterioration indicated by a NIHSS score increase \geq 4 compared to the baseline score, the lowest NIHSS score between baseline and 24 hours, or patient death (30).

Independent Image Review, Imaging Core Laboratory Assessments, and Standardization

Neuroimaging data in all trials were evaluated on the basis of an independent image review system using a centralized imaging core laboratory. The imaging core laboratory assessment was used to provide an unbiased, independent assessment of imaging-based outcomes, and images were sent directly from the site to the imaging core laboratory. The imaging review in the imaging core laboratory was performed blinded to treatment information. The imaging

review in most clinical trials was performed by multiple reviewers. Five trials included only neuroradiologists, two trials included neuroradiologists and a neurologist or other experts, and one trial included only interventionists as reviewers. However, detailed information, such as the reviewers and review systems, standardization including imaging protocols, and quality control or assurance were not presented completely in some trials.

The DAWN trial recommended in the DAWN supplementary appendix that sites should be encouraged to use the same imaging modality at 24 hours as the one used at baseline. The DEFUSE 3 trial presented detailed imaging protocols and parameters for CT and MR. They commented that the baseline and follow-up imaging assessments should be

performed with the DEFUSE 3 protocol, which was installed at all study sites. The THERAPY trial required thin section thickness (≤ 2.5 mm) for NECT (14). The SWIFT PRIME trial commented that the sponsor will collaborate with the participating centers to evaluate and optimize the quality of imaging and image transfer in the SWIFT PRIME protocol. The ESCAPE trial acknowledged that imaging quality is critical in the trial even though the trial showed significant variation across imaging modalities (9). Therefore, they presented dedicated imaging protocols for NECT and CTA in the ESCAPE protocol. The EXTEND-IA trial declared that

the imaging protocol will follow international consensus guidelines (31) in the EXTEND-IA protocol. In the SWIFT protocol, the SWIFT trial commented that the same imaging modality should be performed at 24 hours as the one used at baseline (32). The DAWN and DEFUSE 3 trials revealed that MR is preferred to CT for follow-up imaging (Table 5).

DISCUSSION

We systematically reviewed 16 recent randomized clinical trials for establishing the efficacy or safety of endovascular

Table 5. Independent Image Review, Imaging Core Laboratory, Standardization, and Proportions of CT:MR

Trial Nickname	Independent Image Review and Core Laboratory	Reviewers	Standardization	CT:MR*
DAWN	Used	-	Same imaging modality is encouraged to be used during follow-up	131:75 (63.6:36.4%)
DEFUSE 3	Used	-	Baseline and follow-up imaging should be performed with DEFUSE 3 protocol, which is installed at all study sites	133:49 (73.1:26.9%)
PISTE	Used	3 neuroradiologists	-	-
ASTER	Used	2 + 1	-	-
THERAPY	Used	1 neuroradiologist	Nonenhanced thin-section (≤ 2.5 mm) CT	-
THRACE	Used	4 neuroradiologists for CT and MR, 3 interventional neuroradiologists for DSA	-	-
SWIFT PRIME	Used	2 + 1	Sponsor will collaborate with participating centers to evaluate and optimize quality of imaging and image transfer	189:15 (92.6:7.4%)
REVASCAT	Used	-	-	-
ESCAPE	Used	-	NECT and CTA protocols were presented	13:54 (19.4:80.6% at 24 hours)
EXTEND-IA	Used	Neuroradiologist/stroke neurologist	Imaging protocols will follow current international consensus guidelines. Standard CT and MR protocols were presented	-
MR CLEAN	Used	Two neuroradiologists	-	24:94 (20:80%)
MR RESCUE	Used	-	MR RESCUE protocols were presented	-
SYNTHESIS	Used	-	-	-
IMS III	Used	3 CT experts (including one neuroradiologist was mandatory)	-	-
SWIFT	Used	2 neurointerventionalists	It is preferred that whether CT or MR is taken at baseline, same imaging modality should be obtained at follow-up	-
TREVO 2	Used	-	-	-

*Data indicates numbers of patients and parentheses indicate proportions.

treatment for acute ischemic stroke in terms of the role, protocols, and reviewing system for neuroimaging. Among the 16 trials, 15 included neuroimaging data in the eligibility criteria and 14 used neuroimaging data as the main outcomes. Infarct core volume and revascularization, recanalization, or reperfusion were core imaging-based outcomes that were evaluated on the basis of independent image review systems with the imaging core laboratory. The independent imaging core laboratory played a critical role in the acquisition, transfer, processing, and analysis of neuroimaging data, which contributed to standardization and enhanced the reliability of study outcomes.

The definition of infarct core volume varied across the clinical trials. RAPID, Quantomo, and study-specific algorithms used automated segmentation. Automated methods mainly segmented the infarct core based on the thresholding apparent diffusion coefficient or CTP-CBF value. The infarct core volume for CTP-CBF was defined as the region that is reduced by less than 30% of the normal tissue. Semi-automated algorithms consisted of manual interventions (outlining or placing seed) followed by automated intensity-based region growing. The ASPECT score was also adopted even though it may have limited reproducibility (33, 34).

Some clinical trials used similar assessment methods for revascularization, recanalization, and reperfusion, even though these three are often used interchangeably. Revascularization reflects all treatment-related flow improvement, including local arterial recanalization and reperfusion of the downstream territory. Recanalization is required for antegrade tissue reperfusion but may not be necessary for reperfusion in distal regions (35, 36). Revascularization and reperfusion appear to be interchangeable terms while recanalization seems to focus on the restoration of proximal vessel patency. In this review, we attempted to reflect the terms and meaning that they represented in each trial.

Clinical trials in oncology and Alzheimer's dementia have emphasized standardization of imaging protocols because imaging data were used as the main outcomes in these clinical trials (37-41). Consensus recommendations expressed concerns that minor differences in imaging scanners and parameters may result in significant changes in image contrast, leading to significant measurement discordance across centers and masking the effect of the disease (42). Although unlike tumor imaging, acute stroke imaging has an inherent limitation due to the need

for urgent management, groups leading stroke imaging research have postulated the need for standardized imaging techniques and imaging assessment, especially with respect to the final infarct volume, in order to enhance its reliability, even in acute stroke research (31, 43, 44). Therefore, maintaining the balance between the urgent management pathway and standardization will be important in future clinical trials of acute stroke patients, and this may lead to a greater role for the imaging core laboratory.

The relatively larger salvageable tissue volume to the infarct core volume became more important with the extension of the therapeutic time window for endovascular treatment up to 24 hours. The DEFUSE 3 and DAWN trials demonstrated that appropriate selection of eligible patients for endovascular treatment using neuroimaging assessments for the infarct core and penumbral volume is a key point to extend the time window. However, the difference in the cutoff values to determine the infarct core or penumbral volume across the trials remains a limitation.

Although there are no published thresholds for the infarct core and penumbra, the following criteria have been generally used: a decrease in CBF of 30–50% (5, 7, 22, 45, 46); cerebral blood volume less than 2 to 2.5 g/100 mL relative to the normal cerebral hemisphere for the infarct core (45, 47, 48); a Tmax delay of more than 6 seconds for the penumbra for CTP and DWI lesions for the infarct core (6, 10, 16); and a Tmax delay of more than 6 seconds for the penumbra on MRP (49). However, if imaging protocols or modalities are not standardized or synchronized, reliability cannot be guaranteed regardless of the threshold or post-processing software used.

Most of the studies evaluated hemorrhagic transformation by using the ECASS criteria. However, detection of hemorrhagic transformation can vary depending on imaging modalities such as CT and MRI (50, 51). In CT criteria adapted to MRI, the detailed criteria may differ for each MRI sequence (52). Therefore, comparisons between baseline and follow-up assessments or among enrolled patients that ignore the imaging modalities should be cautiously performed.

A thorough survey of the imaging modalities and protocols used at each site in a multi-center study could help improve and enlarge the number of imaging protocols in future clinical trials or studies. Investigators should endeavor to balance imaging protocols between those used in study designs and those used under realistic circumstances across all centers. The imaging modalities

and protocols must follow the actual clinical protocols. Therefore, guidelines for patients with acute ischemic stroke were considered (2) while planning imaging protocols in clinical trials or studies.

The three protocols based on imaging modalities are CT-based protocols, MR-based protocols, and mixed CT- and MR-based protocols. Based on the results of previous clinical trials, NECT and angiography are essential to exclude acute hemorrhage and evaluate occluded large arteries in acute stroke patients, which are the principal eligibility criteria (5, 6). NECT is inevitably the first screening modality, although MR-based protocols are also used; thus, there may be no pure MR-based protocol. However, NECT is much less sensitive for the detection of acute infarct core volume than DWI (47). Furthermore, in small population studies in which the infarct core volume is the main outcome, NECT may not be sufficient for the analysis of infarct core volume and for measuring precise changes in this volume. Therefore, CTP in CT-based protocols or DWI in mixed CT- and MR-based protocols could be helpful in future imaging protocols. However, NECT and/or CTP for the detection of the infarct core in posterior circulation stroke still remains challenging (53, 54).

Angiography can be performed with CTA, MRA, or DSA. CTA has the advantage of allowing a combination of NECT and CTP, with collateral imaging performed using multiphase CTA. Because CT images can be acquired quickly, the results of whole protocols with NECT, CTP, and CTA can be obtained in minutes (55). However, radiation exposure and ionized contrast media may be obstacles, and precise evaluation of the infarct core volume in comparison with that of DWI may be limited, even when automated or semi-automated post-processing software or specific thresholds for NECT or CTP are used. The radiation dose increases as the coverage area increases when multiphase CTA and CTP are employed. The contrast media can be infused in double doses when CTP and CTA are combined. If MRA is chosen for the evaluation of occluded vessels, its combination with MRI, especially DWI, can be a good strategy. Time-of-flight MRA (TOF-MRA) can evaluate occluded arteries without the need for contrast media, but the scan time is quite long (56). TOF-MRA can reduce the scan time using advanced techniques such as compressed sensing. Contrast-enhanced MRA images can be acquired within minutes and used to simultaneously cover the intracranial and neck arteries, including the aortic arch (57). DSA is mainly used for endovascular thrombectomy rather than for pure evaluation of steno-occlusion. MR has the advantage of providing information from

multiparametric sequences and allows precise delineation of the infarct core using DWI without any radiation hazard. Conversely, it has the disadvantage of a longer scan time and has lower accessibility than CT. However, institutional trials designed to enhance accessibility (58) and fast-scan MR sequences (59, 60) may encourage the use of MR in acute stroke patients.

The guidelines recommend (2) that imaging modalities should not delay treatment and also state that the risk of contrast-induced nephropathy is low, especially in patients without prior renal impairment, although both CT and MRI may be necessary for the evaluation of kidney function using contrast media.

CTP or MRP is not essential in acute stroke imaging based on the guidelines (2), but they can be added because the penumbra has been reported to be important when considering treatment options in many clinical trials (5, 6, 10). Therefore, the first imaging modality is generally NECT, followed by CTA or MRA. If MRA is chosen, the mixed CT and MR protocol becomes the main imaging protocol and can include other MR protocols, generally DWI with the possible addition of GRE, FLAIR, CTP, or MRP. Therefore, the CT-based protocol generally consists of NECT and CTA, and CTP can be added according to the study design. NECT, DWI, and MRA (or CTA) are key imaging sequences, to which MRP, GRE, and FLAIR can be added. However, the combination of imaging protocols can vary depending on the nature of the clinical trial or study. In addition, pure MR-based protocols could be used in more sophisticated study designs, and strict eligibility criteria can be used to overcome ethical issues.

NECT and GRE are the main sequences used for evaluation of hemorrhagic transformation, but GRE is much more sensitive than NECT for the detection of hemorrhage (49, 51). Therefore, in studies focusing on hemorrhagic transformation, GRE may be another imaging option. In addition, the results obtained using GRE can differ considerably depending on magnet strength (1.5T vs. 3T) or sequences (conventional GRE vs. susceptibility weighted imaging). Therefore, standardized imaging protocols are quite important and enhance reliability when GRE is used to evaluate hemorrhage.

Our study had several limitations. In an effort to overcome the paucity of randomized trials of endovascular treatment for acute ischemic stroke, we conducted an exhaustive systematic search and included all published trials regarding acute ischemic stroke. Therefore, our study included a variety of different study populations

with different eligibility criteria and thereby included data from trials with variable sample sizes. This could have potentially increased the level of bias. Furthermore, although we thoroughly reviewed the published articles, supplementary appendices, protocols, published protocols, and clinicalTrials.gov data for the selected studies, detailed information might have been missed. Therefore, our results need to be interpreted with caution.

SUMMARY

When researchers plan to perform a study regarding acute ischemic stroke, appropriate eligibility criteria and outcomes should be selected based on clinical and imaging indexes. The eligibility criteria based on clinical indexes may vary depending on the purpose, hypothesis, or sample size of the study. In the case of imaging indexes, angiographic information obtained using CTA, MRA, or DSA and data for the infarct core volume and penumbra volume obtained using CT or MR are used as eligibility criteria, but the detailed standards also vary depending on the study. Therefore, a thorough review of previous studies may be helpful for planning a study.

Among clinical indexes, the mRS score at 90 days is used as the primary outcome in most studies, followed by the NIHSS score, Barthel index, and the EuroQol EQ-5D questionnaire score as secondary or tertiary clinical outcomes. Among imaging indexes, infarct core volume, revascularization (or reperfusion), and hemorrhagic transformation are used as outcomes in most studies, but the detailed criteria for infarct core volume and revascularization are not standardized. Therefore, neuroimaging assessments should preferably be performed using the same imaging protocols and analyzed by an independent image review committee and imaging core laboratory. However, it may be unreasonable or unrealistic to mandate (or encourage) the use of the same imaging modality for comparisons of outcomes because the same imaging protocol can be difficult to employ in urgent circumstances. A dedicated imaging protocol would be the best option in any study or clinical trial. In particular, a dedicated or standardized imaging protocol could be important in a small population study with limited resources. If a dedicated imaging protocol is difficult to achieve in all patients, the same imaging modality, irrespective of CT or MRI, should be recommended for imaging the same patient in the baseline and follow-up examinations to

facilitate intra-individual comparisons. Infarct core volume is more likely to be analyzed quantitatively based on the recent semi- or fully automated segmentation relative to the ASPECT score alone. Hemorrhagic transformation is evaluated in most of the studies traditionally based on ECASS criteria. Revascularization in DSA is more likely to be analyzed based on the scales such as mTICI, including the local arterial recanalization and reperfusion of the downstream territory, while CTA or MRA may be preferred to analyze the recanalization scores such as mAOL, focusing on antegrade tissue reperfusion.

In conclusion, neuroimaging became an essential component to demonstrate the hypothesis effectively and to enhance the reliability of study outcomes in recent clinical trials for endovascular treatment in acute ischemic stroke. The role of neuroimaging may increase and extend in applied areas to various research studies beyond clinical trials for endovascular treatment in acute ischemic stroke. However, it is difficult for each researcher to select the appropriate imaging protocols and analytic methods among the diverse imaging biomarkers proposed in various studies in accordance with one's purpose and to decide the degree and extent of standardization in the imaging acquisition, protocols, and analysis methods, even though the standardized protocols may be necessary to improve the reliability and quality of studies. This review may serve as a reference helping each researcher to appropriately use neuroimaging biomarkers for observational studies as well as clinical trials in acute ischemic stroke.

Conflicts of Interest

The authors have no potential conflicts of interest to disclose.

ORCID iDs

Seung Chai Jung

<https://orcid.org/0000-0001-5559-7973>

Chong Hyun Suh

<https://orcid.org/0000-0002-4737-0530>

Byungjun Kim

<https://orcid.org/0000-0001-9462-5885>

Se Jin Cho

<https://orcid.org/0000-0001-6450-7554>

Dong-Cheol Woo

<https://orcid.org/0000-0001-8202-015X>

Woo Yong Oh

<https://orcid.org/0000-0001-7442-7128>

Jong Gu Lee

<https://orcid.org/0000-0002-0282-8720>

Kyung Won Kim

<https://orcid.org/0000-0002-1532-5970>

REFERENCES

- Lee JS, Demchuk AM. Choosing a hyperacute stroke imaging protocol for proper patient selection and time efficient endovascular treatment: lessons from recent trials. *J Stroke* 2015;17:221-228
- Powers WJ, Rabinstein AA, Ackerson T, Adeoye OM, Bambakidis NC, Becker K, et al.; American Heart Association Stroke Council. 2018 guidelines for the early management of patients with acute ischemic stroke: a guideline for healthcare professionals from the American Heart Association/American Stroke Association. *Stroke* 2018;49:e46-e110
- Hacke W, Kaste M, Fieschi C, Toni D, Lesaffre E, von Kummer R, et al. Intravenous thrombolysis with recombinant tissue plasminogen activator for acute hemispheric stroke. The European Cooperative Acute Stroke Study (ECASS). *JAMA* 1995;274:1017-1025
- National Institute of Neurological Disorders and Stroke rt-PA Stroke Study Group. Tissue plasminogen activator for acute ischemic stroke. *N Engl J Med* 1995;333:1581-1587
- Nogueira RG, Jadhav AP, Haussen DC, Bonafe A, Budzik RF, Bhuva P, et al.; DAWN Trial Investigators. Thrombectomy 6 to 24 hours after stroke with a mismatch between deficit and infarct. *N Engl J Med* 2018;378:11-21
- Albers GW, Marks MP, Kemp S, Christensen S, Tsai JP, Ortega-Gutierrez S, et al.; DEFUSE 3 Investigators. Thrombectomy for stroke at 6 to 16 hours with selection by perfusion imaging. *N Engl J Med* 2018;378:708-718
- Saver JL, Goyal M, Bonafe A, Diener HC, Levy EI, Pereira VM, et al.; SWIFT PRIME Investigators. Stent-retriever thrombectomy after intravenous t-PA vs. t-PA alone in stroke. *N Engl J Med* 2015;372:2285-2295
- Jovin TG, Chamorro A, Cobo E, de Miquel MA, Molina CA, Rovira A, et al.; REVASCAT Trial Investigators. Thrombectomy within 8 hours after symptom onset in ischemic stroke. *N Engl J Med* 2015;372:2296-2306
- Goyal M, Demchuk AM, Menon BK, Eesa M, Rempel JL, Thornton J et al.; ESCAPE Trial Investigators. Randomized assessment of rapid endovascular treatment of ischemic stroke. *N Engl J Med* 2015;372:1019-1030
- Campbell BC, Mitchell PJ, Kleinig TJ, Dewey HM, Churilov L, Yassi N, et al.; EXTEND-IA Investigators. Endovascular therapy for ischemic stroke with perfusion-imaging selection. *N Engl J Med* 2015;372:1009-1018
- Berkhemer OA, Fransen PS, Beumer D, van den Berg LA, Lingsma HF, Yoo AJ, et al.; MR CLEAN Investigators. A randomized trial of intraarterial treatment for acute ischemic stroke. *N Engl J Med* 2015;372:11-20
- Muir KW, Ford GA, Messow CM, Ford I, Murray A, Clifton A, et al.; PISTE Investigators. Endovascular therapy for acute ischaemic stroke: the Pragmatic Ischaemic Stroke Thrombectomy Evaluation (PISTE) randomised, controlled trial. *J Neurol Neurosurg Psychiatry* 2017;88:38-44
- Lapergue B, Blanc R, Gory B, Labreuche J, Duhamel A, Marnat G, et al.; ASTER Trial Investigators. Effect of endovascular contact aspiration vs stent retriever on revascularization in patients with acute ischemic stroke and large vessel occlusion: the ASTER randomized clinical trial. *JAMA* 2017;318:443-452
- Mocco J, Zaidat OO, von Kummer R, Yoo AJ, Gupta R, Lopes D, et al.; THERAPY Trial Investigators. Aspiration thrombectomy after intravenous alteplase versus intravenous alteplase alone. *Stroke* 2016;47:2331-2338
- Bracard S, Ducrocq X, Mas JL, Soudant M, Oppenheim C, Moulin T, et al.; THRACE investigators. Mechanical thrombectomy after intravenous alteplase versus alteplase alone after stroke (THRACE): a randomised controlled trial. *Lancet Neurol* 2016;15:1138-1147
- Kidwell CS, Jahan R, Gornbein J, Alger JR, Nenov V, Ajani Z, et al.; MR RESCUE Investigators. A trial of imaging selection and endovascular treatment for ischemic stroke. *N Engl J Med* 2013;368:914-923
- Ciccone A, Valvassori L, Nichelatti M, Sgoifo A, Ponzio M, Sterzi R, et al.; SYNTHESIS Expansion Investigators. Endovascular treatment for acute ischemic stroke. *N Engl J Med* 2013;368:904-913
- Broderick JP, Palesch YY, Demchuk AM, Yeatts SD, Khatri P, Hill MD, et al.; Interventional Management of Stroke (IMS) III Investigators. Endovascular therapy after intravenous t-PA versus t-PA alone for stroke. *N Engl J Med* 2013;368:893-903
- Saver JL, Jahan R, Levy EI, Jovin TG, Baxter B, Nogueira RG, et al.; SWIFT Trialists. Solitaire flow restoration device versus the Merci retriever in patients with acute ischaemic stroke (SWIFT): a randomised, parallel-group, non-inferiority trial. *Lancet* 2012;380:1241-1249
- Nogueira RG, Lutsep HL, Gupta R, Jovin TG, Albers GW, Walker GA, et al.; TREVO 2 Trialists. Trevo versus Merci retrievers for thrombectomy revascularisation of large vessel occlusions in acute ischaemic stroke (TREVO 2): a randomised trial. *Lancet* 2012;380:1231-1240
- Liberati A, Altman DG, Tetzlaff J, Mulrow C, Gøtzsche PC, Ioannidis JP, et al. The PRISMA statement for reporting systematic reviews and meta-analyses of studies that evaluate health care interventions: explanation and elaboration. *Ann Intern Med* 2009;151:W65-W94
- Campbell BC, Mitchell PJ, Churilov L, Yassi N, Kleinig TJ, Dowling RJ, et al.; EXTEND-IA TNK Investigators. Tenecteplase versus alteplase before thrombectomy for ischemic stroke. *N Engl J Med* 2018;378:1573-1582
- Logallo N, Novotny V, Assmus J, Kvistad CE, Altheheld L, Rønning OM, et al. Tenecteplase versus alteplase for management of acute ischaemic stroke (NOR-TEST): a phase 3,

- randomised, open-label, blinded endpoint trial. *Lancet Neurol* 2017;16:781-788
24. Wouters A, Lemmens R, Christensen S, Wilms G, Dupont P, Mlynash M, et al.; AXIS 2 and DEFUSE 2 study investigators. Magnetic resonance imaging-based endovascular versus medical stroke treatment for symptom onset up to 12 h. *Int J Stroke* 2016;11:127-133
 25. Schönenberger S, Uhlmann L, Hacke W, Schieber S, Mundiyapurath S, Purrucker JC, et al. Effect of conscious sedation vs general anesthesia on early neurological improvement among patients with ischemic stroke undergoing endovascular thrombectomy: a randomized clinical trial. *JAMA* 2016;316:1986-1996
 26. Khoury NN, Darsaut TE, Ghostine J, Deschaintre Y, Daneault N, Durocher A, et al.; EASI trial collaborators. Endovascular thrombectomy and medical therapy versus medical therapy alone in acute stroke: a randomized care trial. *J Neuroradiol* 2017;44:198-202
 27. Kosior JC, Idris S, Dowlatshahi D, Alzawahmah M, Eesa M, Sharma P, et al.; PREDICT/Sunnybrook CTA ICH study investigators. Quantomo: validation of a computer-assisted methodology for the volumetric analysis of intracerebral haemorrhage. *Int J Stroke* 2011;6:302-305
 28. Boers AM, Marquering HA, Jochem JJ, Besselink NJ, Berkhemer OA, van der Lugt A, et al.; MR CLEAN investigators. Automated cerebral infarct volume measurement in follow-up noncontrast CT scans of patients with acute ischemic stroke. *AJNR Am J Neuroradiol* 2013;34:1522-1527
 29. Wardlaw JM, von Kummer R, Carpenter T, Parsons M, Lindley RI, Cohen G, et al. Protocol for the perfusion and angiography imaging sub-study of the Third International Stroke Trial (IST-3) of alteplase treatment within six-hours of acute ischemic stroke. *Int J Stroke* 2015;10:956-968
 30. Wahlgren N, Ahmed N, Dávalos A, Ford GA, Grond M, Hacke W, et al.; SITS-MOST investigators. Thrombolysis with alteplase for acute ischaemic stroke in the Safe Implementation of Thrombolysis in Stroke-Monitoring Study (SITS-MOST): an observational study. *Lancet* 2007;369:275-282
 31. Wintermark M, Albers GW, Alexandrov AV, Alger JR, Bammer R, Baron JC, et al. Acute stroke imaging research roadmap. *Stroke* 2008;39:1621-1628
 32. Saver JL, Jahan R, Levy EI, Jovin TG, Baxter B, Nogueira R, et al.; SWIFT Trialists. SOLITAIRE™ with the intention for thrombectomy (SWIFT) trial: design of a randomized, controlled, multicenter study comparing the SOLITAIRE™ flow restoration device and the MERCI retriever in acute ischaemic stroke. *Int J Stroke* 2014;9:658-668
 33. Coutts SB, Demchuk AM, Barber PA, Hu WY, Simon JE, Buchan AM, et al.; VISION Study Group. Interobserver variation of ASPECTS in real time. *Stroke* 2004;35:e103-e105
 34. Gupta AC, Schaefer PW, Chaudhry ZA, Leslie-Mazwi TM, Chandra RV, González RG, et al. Interobserver reliability of baseline noncontrast CT Alberta Stroke Program early CT score for intra-arterial stroke treatment selection. *AJNR Am J Neuroradiol* 2012;33:1046-1049
 35. Zaidat OO, Yoo AJ, Khatri P, Tomsick TA, von Kummer R, Saver JL, et al.; Cerebral Angiographic Revascularization Grading (CARG) Collaborators; STIR Revascularization working group; STIR Thrombolysis in Cerebral Infarction (TICI) Task Force. Recommendations on angiographic revascularization grading standards for acute ischemic stroke: a consensus statement. *Stroke* 2013;44:2650-2663
 36. Zaidat OO, Lazzaro MA, Liebeskind DS, Janjua N, Wechsler L, Nogueira RG, et al. Revascularization grading in endovascular acute ischemic stroke therapy. *Neurology* 2012;79(13 Suppl 1):S110-S116
 37. Carrillo MC, Rowe CC, Szoeki C, Masters CL, Ames D, O'Meara T, et al.; NIA/Alzheimer Association and International Working Group. Research and standardization in Alzheimer's trials: reaching international consensus. *Alzheimers Dement* 2013;9:160-168
 38. Weiner MW, Veitch DP, Aisen PS, Beckett LA, Cairns NJ, Green RC, et al.; Alzheimer's Disease Neuroimaging Initiative. Recent publications from the Alzheimer's Disease Neuroimaging Initiative: reviewing progress toward improved AD clinical trials. *Alzheimers Dement* 2017;13:e1-e85
 39. deSouza NM, Winfield JM, Waterton JC, Weller A, Papoutsaki MV, Doran SJ, et al. Implementing diffusion-weighted MRI for body imaging in prospective multicentre trials: current considerations and future perspectives. *Eur Radiol* 2018;28:1118-1131
 40. Shukla-Dave A, Obuchowski NA, Chenevert TL, Jambawalikar S, Schwartz LH, Malyarenko D, et al. Quantitative imaging biomarkers alliance (QIBA) recommendations for improved precision of DWI and DCE-MRI derived biomarkers in multicenter oncology trials. *J Magn Reson Imaging* 2019;49:e101-e121
 41. Packer RA, Rossmeisl JH, Kent MS, Griffin JF 4th, Mazcko C, LeBlanc AK. Consensus recommendations on standardized magnetic resonance imaging protocols for multicenter canine brain tumor clinical trials. *Vet Radiol Ultrasound* 2018;59:261-271
 42. Ellingson BM, Bendszus M, Boxerman J, Barboriak D, Erickson BJ, Smits M, et al.; Jumpstarting Brain Tumor Drug Development Coalition Imaging Standardization Steering Committee. Consensus recommendations for a standardized Brain Tumor Imaging Protocol in clinical trials. *Neuro Oncol* 2015;17:1188-1198
 43. Warach SJ, Luby M, Albers GW, Bammer R, Bivard A, Campbell BC, et al.; Stroke Imaging Research (STIR) and VISTA-Imaging Investigators. Acute stroke imaging research roadmap III: imaging selection and outcomes in acute stroke reperfusion clinical trials: consensus recommendations and further research priorities. *Stroke* 2016;47:1389-1398
 44. Wintermark M, Albers GW, Broderick JP, Demchuk AM, Fiebach JB, Fiehler J, et al.; Stroke Imaging Research (STIR) and Virtual International Stroke Trials Archive (VISTA)-Imaging Investigators. Acute stroke imaging research roadmap II.

- Stroke* 2013;44:2628-2639
45. Heit JJ, Wintermark M. Perfusion computed tomography for the evaluation of acute ischemic stroke: strengths and pitfalls. *Stroke* 2016;47:1153-1158
 46. Lin L, Bivard A, Parsons MW. Perfusion patterns of ischemic stroke on computed tomography perfusion. *J Stroke* 2013;15:164-173
 47. Vilela P, Rowley HA. Brain ischemia: CT and MRI techniques in acute ischemic stroke. *Eur J Radiol* 2017;96:162-172
 48. Wintermark M, Reichhart M, Thiran JP, Maeder P, Chalaron M, Schnyder P, et al. Prognostic accuracy of cerebral blood flow measurement by perfusion computed tomography, at the time of emergency room admission, in acute stroke patients. *Ann Neurol* 2002;51:417-432
 49. Vert C, Parra-Fariñas C, Rovira À. MR imaging in hyperacute ischemic stroke. *Eur J Radiol* 2017;96:125-132
 50. Eliasziw M, Paddock-Eliasziw L. Comparison of MRI and CT for detection of acute intracerebral hemorrhage. *JAMA* 2005;293:550; author reply 550-551
 51. Arnould MC, Grandin CB, Peeters A, Cosnard G, Duprez TP. Comparison of CT and three MR sequences for detecting and categorizing early (48 hours) hemorrhagic transformation in hyperacute ischemic stroke. *AJNR Am J Neuroradiol* 2004;25:939-944
 52. Neeb L, Villringer K, Galinovic I, Grosse-Dresselhaus F, Ganeshan R, Gierhake D, et al. Adapting the computed tomography criteria of hemorrhagic transformation to stroke magnetic resonance imaging. *Cerebrovasc Dis Extra* 2013;3:103-110
 53. Caplan LR. *Vertebrobasilar ischemia and hemorrhage: clinical findings, diagnosis and management of posterior circulation disease*, 2nd ed. Cambridge: Cambridge University Press, 2015
 54. Nouh A, Remke J, Ruland S. Ischemic posterior circulation stroke: a review of anatomy, clinical presentations, diagnosis, and current management. *Front Neurol* 2014;5:30
 55. Wintermark M, Rowley HA, Lev MH. Acute stroke triage to intravenous thrombolysis and other therapies with advanced CT or MR imaging: pro CT. *Radiology* 2009;251:619-626
 56. Kim JS, Caplan LR, Wong KS. *Intracranial atherosclerosis: pathophysiology, diagnosis and treatment*. Basel: Karger, 2016
 57. Yang JJ, Hill MD, Morrish WF, Hudon ME, Barber PA, Demchuk AM, et al. Comparison of pre- and postcontrast 3D time-of-flight MR angiography for the evaluation of distal intracranial branch occlusions in acute ischemic stroke. *AJNR Am J Neuroradiol* 2002;23:557-567
 58. Shah S, Luby M, Poole K, Morella T, Keller E, Benson RT, et al. Screening with MRI for accurate and rapid stroke treatment: SMART. *Neurology* 2015;84:2438-2444
 59. Nael K, Khan R, Choudhary G, Meshksar A, Villablanca P, Tay J, et al. Six-minute magnetic resonance imaging protocol for evaluation of acute ischemic stroke: pushing the boundaries. *Stroke* 2014;45:1985-1991
 60. Chung MS, Lee JY, Jung SC, Baek S, Shim WH, Park JE, et al. Reliability of fast magnetic resonance imaging for acute ischemic stroke patients using a 1.5-T scanner. *Eur Radiol* 2019;29:2641-2650