

Radiosurgery for Cerebral Arteriovenous Malformation (AVM) : Current Treatment Strategy and Radiosurgical Technique for Large Cerebral AVM

Joonho Byun, Do Hoon Kwon, Do Heui Lee, Wonhyoung Park, Jung Cheol Park, Jae Sung Ahn

Department of Neurological Surgery, Asan Medical Center, University of Ulsan College of Medicine, Seoul, Korea

Arteriovenous malformations (AVMs) are congenital anomalies of the cerebrovascular system. AVM harbors 2.2% annual hemorrhage risk in unruptured cases and 4.5% annual hemorrhage risk of previously ruptured cases. Stereotactic radiosurgery (SRS) have been shown excellent treatment outcomes for patients with small- to moderated sized AVM which can be achieved in 80–90% complete obliteration rate with a 2–3 years latency period. The most important factors are associated with obliteration after SRS is the radiation dose to the AVM. In our institutional clinical practice, now 22 Gy (50% isodose line) dose of radiation has been used for treatment of cerebral AVM in single-session radiosurgery. However, dose-volume relationship can be unfavorable for large AVMs when treated in a single-session radiosurgery, resulting high complication rates for effective dose. Thus, various strategies should be considered to treat large AVM. The role of pre-SRS embolization is permanent volume reduction of the nidus and treat high-risk lesion such as AVM-related aneurysm and high-flow arteriovenous shunt. Various staging technique of radiosurgery including volume-staged radiosurgery, hypofractionated radiotherapy and dose-staged radiosurgery are possible option for large AVM. The incidence of post-radiosurgery complication is varied, the incidence rate of radiological post-radiosurgical complication has been reported 30–40% and symptomatic complication rate was reported from 8.1% to 11.8%. In the future, novel therapy which incorporate endovascular treatment using liquid embolic material and new radiosurgical technique such as gene or cytokine-targeted radio-sensitization should be needed.

Key Words : Arteriovenous malformations · Radiosurgery · Complication.

INTRODUCTION

Arteriovenous malformations (AVMs) are congenital anomalies of the cerebrovascular system with poorly formed blood vessels that shunt blood directly from the arterial to venous system bypassing the capillary network. AVM harbors

2.2% annual hemorrhage risk in unruptured cases and 4.5% annual hemorrhage risk of previously ruptured cases, deep location, deep venous drainage, associated aneurysm were proven risk factors of hemorrhage²²⁾. The highest individual rupture rate of AVM which harbored risk factors may be as high as 34%⁵⁴⁾.

• Received : January 7, 2020 • Revised : February 27, 2020 • Accepted : February 29, 2020

• Address for reprints : **Do Hoon Kwon**

Department of Neurological Surgery, Asan Medical Center, University of Ulsan College of Medicine, 88 Olympic-ro 43-gil, Songpa-gu, Seoul 05505, Korea
Tel : +82-2-3010-3555; Fax : +82-2-476-6738, E-mail : ykwon@amc.seoul.kr, ORCID : <https://orcid.org/0000-0002-3429-7119>

This is an Open Access article distributed under the terms of the Creative Commons Attribution Non-Commercial License (<http://creativecommons.org/licenses/by-nc/4.0>) which permits unrestricted non-commercial use, distribution, and reproduction in any medium, provided the original work is properly cited.

The risks and benefits of AVM management must be weighed carefully in each patient. In the recent randomized prospective trial (ARUBA study), medical therapy alone showed superiority for outcome compared to interventional therapy in unruptured AVM³⁵. However, ARUBA trial harbored several limitations^{12,57}. For now, three treatment modalities, microsurgery, embolization and stereotactic radiosurgery (SRS) are available treatment modalities. Theoretically, microsurgical complete removal of AVM is ideal treatment. However, microsurgical removal harbored very high postoperative morbidity⁵². SRS have been shown excellent treatment outcomes for patients with small- to moderated sized AVM¹⁵. It is clear that angiographic nidus obliteration, which has been considered to eliminate the risk of hemorrhage as effectively as surgical resection, can be achieved in 80–90% of cases with a 2–3 years latency period¹⁵. Thus, SRS is widely accepted as an alternative to microsurgery in the treatment of AVMs, particularly in deep brain locations (i.e., brain stem, basal ganglia or thalamus) or critical lobar areas (i.e., sensorimotor, speech or visual cortex).

SRS has been shown favorable outcome for small to medium sized AVM. However, the efficacy of SRS for large volume AVM is still questionable. Large volume AVM are typically treated with reduced radiation doses which are associated with a lower chance of obliteration. Recently, various radiosurgical technique including staged-radiosurgery, hypofractionated radio-

therapy (HfRT) and adjunctive endovascular therapy used to reduce radiation dose and to improve obliteration¹⁵⁻¹⁷.

Herein, we will mention about current consensus and our institutional strategy of SRS (gamma knife radiosurgery, GKRS) for AVM which have been established by authors' (especially, D.H.K.) personal experiences during the more than three-decade period from 1990 through 2018. Also, this report will be summarized along with much of what we have learned from already published data.

METHOD

We summarized our institutional strategy for GKRS for AVM based on 30-year experience. In our institution, majority of GKRS for cerebral AVM have done by single experienced neurosurgeon (D.H.K.).

Also, we reviewed literature for current radiosurgical strategies (volume-staged radiosurgery [VS-RS], dose-staged radiosurgery and HfRT) for large AVM (volume >10 cm³). Studies for this study were selected based on the following criteria : 1) the study must include at least 10 patients with cerebral AVMs treated with SRS. 2) The study must include posttreatment outcomes data. And 3) the language of the study must be English. Studies pertaining to repeat SRS for AVMs or SRS for other types of cerebrovascular lesions were excluded (Fig. 1).

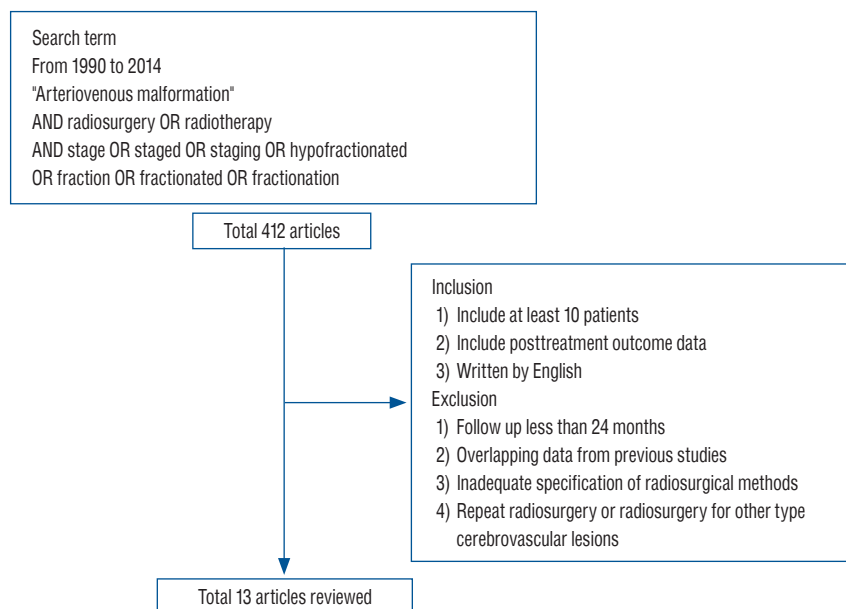


Fig. 1. Literature research for radiosurgery for large AVM. AVM : arteriovenous malformation.

Literature research was performed using PubMed (<https://www.ncbi.nlm.nih.gov/pubmed>) and the following search term “Arteriovenous malformation” AND radiosurgery OR radiotherapy AND stage OR staged OR staging OR hypofractionated OR fraction OR fractionated OR fractionation.

This search yielded 412 articles from 1990 to 2014, which were further screened based on the inclusion criteria above using the title and abstracts of the search results. With excluded articles from this study due to insufficient follow-up time (less than 24 months), overlapping data from previous studies, and inadequate specification of radiosurgical methods. A total of 13 articles’ radiosurgical methods and outcomes for large AVM SRS were reviewed in tables.

CURRENT CONSENSUS OF CEREBRAL AVM RADIOSURGERY IN OUR INSTITUTE

Dose-volume guideline of cerebral AVM have been already reported^{15,20,28}. The most important factors are associated with obliteration after SRS is the radiation dose to the AVM. In our institutional clinical practice, now 22 Gy (50% isodose line) dose of radiation has been used for treatment of cerebral AVM in single-session radiosurgery. In early 1990, 25 Gy dose of radiation was used for AVM radiosurgery, however, the dose of radiation gradually decreased to 22 Gy. Over dose of 25 Gy had been showed similar obliteration rate and higher complication rate¹⁵. The “12 Gy volume” has been known the most important factors of symptomatic radiation injury, we have tried to minimize irradiated normal brain area which received over 12 Gy^{13,16}.

In our institute, all of AVM radiosurgery was performed by the Leksell model G stereotactic frame and, after 2011 Leksell model Perfexion stereotactic frame (ELEKTA Instruments INC., Stockholm, Sweden) was used. Treatment plans were generated using the Elekta Gamma Plan system based on conventional cerebral angiography, gadolinium-enhanced axial 3-dimensional T1-magnetization-prepared rapid acquisition gradient echo magnetic resonance (MR) (1.25 mm slice thickness) and time of flight (TOF) MR images (1 mm slice thickness). The optimal plan was created by adjustment of the collimator and sectors so that the optimal dose coverage of the target can be achieved while minimizing the dose to the surrounding normal tissues. Until June 2005, the Leksell Gamma

Knife unit model B type was used, replaced by the C type from July 2005 to January 2011. The Gamma Knife Perfexion unit has been adopted to treat patients from February 2011 onwards.

Follow-up MR digital subtraction angiography (DSA) images including angiography were performed at 1 year, 2 years, and 3 years after GKRS. If complete obliteration was demonstrated in MR DSA, cerebral angiography was performed in 2 or 3 years after GKRS to identify residual AVM or complete obliteration. If there was persistent lesion, follow up MR DSA is checked annually or considering additional treatment.

REPEATED RADIOSURGERY FOR RESIDUAL AVM

This residual or persistent AVM after SRS could be treated by microsurgical resection or embolization. However, microsurgical resection of residual AVM still harbors higher treatment related-complications. Considering invasiveness of microsurgical resection of AVM, surgical decision making of previously irradiated nidus is complicated. Also, embolization for residual AVM nidus is complicated because selection of small serpentine feeding arteries is technically difficult and embolization alone therapy have been shown poor obliteration rate⁴⁸.

Thus, repeated radiosurgery can be a viable option for residual AVM after latent period of first radiosurgery. In the recent systematic review of Awad et al.⁴, median obliteration rate of repeated radiosurgery was 61.5%. Also, Maesawa et al.³⁵ reported 70% complete obliteration rate after second radiosurgery for AVM, they reported that dose-response curve of second radiosurgery was not significantly different from first radiosurgery.

The factors associated with obliteration after repeated radiosurgery have been reported, marginal dose was the most important factor for obliteration³⁵. Stahl et al.⁵³ reported that volume of AVM, prescription dose and pretreatment hemorrhage were significant factors for obliteration after second radiosurgery. Third radiosurgery for residual nidus after second radiosurgery were also reported, the reported obliteration rate of third radiosurgery was 54%⁵³.

In our institute, if the persistent AVM nidus is located in the area of previous irradiation field, AVM nidus could be ob-

served for 2–4 years. However, if the residual AVM is located outside of previous irradiation field, early repeat radiosurgery could be applied.

In repeated radiosurgery, radiation-induced complication such as brain edema, radiation necrosis and cyst formation should be closely monitored. The rate of radiation induced complication after repeated radiosurgery for AVM reported that range from 4.9% and 7.4%^{4,35,53}.

RADIOSURGERY FOR LARGE CEREBRAL AVM

Dose-volume relationship can be unfavorable for large AVMs when treated in a single-session radiosurgery, resulting high complication rates for effective dose^{15,17}. In large AVM, reported obliteration rate is low (less than 50%) and large area of irradiated normal tissue adjacent AVM could increase radiation-induced complication^{10,11,16}. For this reason, single-session radiosurgery could not be a good treatment option of higher grade AVM (Spetzler-Martin grade III–V). There has been relentless endeavor to improve complete obliteration rate with minimizing post-treatment complication of high-grade AVM radiosurgery. Adjunctive embolization and several radiosurgical strategies have been introduced to treat large AVM.

Radiosurgery after embolization of AVM

Embolization alone could be used sole curing modality of cerebral AVM, however, embolization alone treatment has not been shown favorable complete obliteration rate⁴⁶. Embolization still have played important role in multimodality treatment of cerebral AVM and embolization has been used as an adjunct before SRS for large volume AVM³⁶. The role of pre-SRS embolization is permanent volume reduction of the nidus and treat high-risk lesion such as AVM-related aneurysm and high-flow arteriovenous shunt^{9,25,36}. Several drawbacks of this approach include the morbidity associated with embolization, the potential for recanalization and the fact that embolization may divide the nidus into multiple compartments without reducing the nidus size for SRS^{24,30,48,60}.

In previous report, embolization of AVM nidus before radiosurgery decrease the obliteration rate compared to radiosurgery alone⁵². There were proposed reasons of decreased obliteration rate of embolized nidus, embolized nidus can in-

creased the difficulty of defining or delineation of nidus during planning of radiosurgery⁴⁴. Embolization can compartmentalize compact nidus into noncontiguous or diffuse one, it can make the difficulty of deciding target area of AVM nidus⁵⁰. Furthermore, the embolized nidus may recanalize and recruit feeding vessels during latency period after radiosurgery^{21,47}. Furthermore, Andrade-Souza et al.² reported embolic agents may absorb or scatter radiation, the overall dose to nidus could be reduce in AVM radiosurgery.

Despite the lower obliteration rates of embolized AVM, embolization has its clear strength of AVM volume reduction and eradicate high risk angiographical lesions. Volume reduction of AVM can improve probability of total obliteration and reduce radiation-induced complication^{29,31}. Although there is periprocedural risk of AVM embolization, for now, embolization has been considered important adjunctive tool of AVM radiosurgery.

VS-RS for large AVM

VS-RS is one option of large volume AVM radiosurgery, it permits a higher radiation dose to be delivered to the AVM nidus and reduce radiation exposure to the adjacent normal brain. VS-RS compartmentalize the AVM nidus into geometrically distinct, smaller volume targets, each subdivided nidi are treated sequentially in a separate radiosurgical session²⁶. The interval of each radiosurgery sessions are usually from 3 to 6 months^{26,40}.

The each session volume is decided on the chance of developing a radiation-induced complication based on the 12-Gy volume⁴³. AVM usually fed by multiple arteries, volume staging can be based on different feeding arterial area on planning angiogram and major draining veins is treated last session⁴³. Recommended minimum marginal dose is typically 16 Gy because the 3-year obliteration rate were approximately 70%^{17,37}.

In the report of Seymour et al.⁴⁹, they treated 31 patients of large AVM (largest diameter >3 cm) using VS-RS and followed up for 4.8 years. They divided treatment sessions from 2 to 4 stages (2 stages, 71%; 3 stages, 26%; and 4 stages, 3%), they applied marginal dose was 17 Gy for 6.8 mL volume (median session interval, 3.7 months). Near or complete obliteration rate was 42% and complication rate was 13%. In addition, they compared treatment outcomes of VS-RS for large AVM between marginal dose of ≥ 17 Gy and < 17 Gy group, ≥ 17 Gy group showed better obliteration rate than < 17 Gy group (42%

vs. 22%). However, the complication rate was not significantly different (<17Gy group, 27% and \geq 17Gy group, 15%)⁴⁷. They proposed at least 17 Gy marginal dose for VS-RS for AVM.

Also, in the recent report of Pollock et al.⁴⁵, they treated 34 AVM (mean volume, 22.2 cm³) using GKRS and followed-up for 8.2 years. In their report, they used marginal dose of 16 Gy for 2 stages (6 months interval) of VS-RS. They reported overall 71% nidus obliteration rate and 6% rate of adverse radiation effect. Despite of relatively large volume over 22 cm³, they showed high obliteration rate and favorable functional outcome (65% showed excellent outcome). However, six of 34 (18%) patients experienced bleeding from AVM after completion of VS-RS and one patient experienced bleeding between stages⁴⁵.

The strategy of the surgical resection after downgrading of large AVM after VS-RS was reported. Abla et al.¹ reported 93.8% (15 of 16 patients) cure rate of surgical resection after VS-RS for large AVM. In their report, mean number of VS-RS sessions was 2.7 (volume per stage, 8–10 cm³; dose per stage, >17 Gy) and interval of first session to surgery was 5.7 years¹. This treatment strategy may be a viable surgical adjunct of VS-RS for large AVM.

To author's personal experience, nidus usually divided two portions (two sessions), and nidus division was performed based on different feeding arterial area (anterior circulation and posterior circulation). The interval of each session was 3 to 6 months, usually. However, in our institution, second-stage radiosurgery could be applied after 2–4 years first-stage radiosurgery (after firstly-irradiated area nidus obliteration). In this long-term staging method, second irradiation field delineation becomes easier than short-term staging method; it may lead better outcome of VS-RS for large AVM.

Complete obliteration rate of VS-RS was reported from 33% to 53% and the rate of complication was from 4% to 67% (Table 1)^{31,40,45,52}. The rate of latent period hemorrhage of VS-RS was from 10–74%. Seymour et al.⁴⁹ reported the most important factors for higher obliteration was radiation dose (over 17 Gy).

HfRT for large AVM

The benefit of hypofractionation in radiation therapy may be achieved by the difference in the α/β ratio which is tissue's intrinsic characteristics between AVM nidus and normal brain. Hypofractionation make deliver higher dose to AVM

nidus than single-session radiosurgery and minimize biologic equivalent dose (BED) to normal brain tissue. As fractionation increase, the obliteration rates become less favorable. In early report, fraction size of 2 to 4 Gy (a total 50 Gy) showed poor obliteration rates of 8%³³. Thus, modern HfRT for large AVM delivers dose of over 4 Gy per fraction is recommended and proposed the fraction strategies are 7 Gy \times 4, 5.6 Gy \times 6, 4.7 Gy \times 8, and 4.2 Gy \times 10 which is the BED to a single-session radiosurgery 15 Gy⁶¹. In the previous report, the obliteration rates of HfRT were reported from 5% to 74% and the complication rate of HfRT rate were reported from 3% to 41% (Table 2)^{3,6-8,39,56,58,61}.

However, theoretically, the α/β ratio of AVM vasculature is similar to late responding tissue, therapeutic advantage of HfRT is still questionable. Previously published reports for HfRT for large AVM were small sample size study, thus, cautious interpretation should be needed for efficacy of HfRT for large AVM.

Dose-staged radiosurgery for large AVM

The definition of dose-staged radiosurgery is confusing. Conventional radiotherapy or HfRT could be considered 'dose-staged' treatment. However, in this report, dose-staged radiosurgery for AVM is defined as repeated radiosurgery of the whole nidus using low doses for each single session over an interval period of 3–4 years⁴¹. In general, suboptimal radiation dose (under 18 Gy) is given in each radiosurgical session. In systematic review, complete obliteration rate of dose-staged radiosurgery for large AVM were reported from 0% to 70% and radiation induced complication rate was reported from 0% to 20%, However, most of studies including this systematic review used linear accelerator (LINAC) instead of GKRS⁵². According to this systematic review, dose-staged radiosurgery for large AVM showed less favorable outcome in terms of complete obliteration rate and compared to VS-RS³⁸. The optimal dose and time interval have not been defined.

Inoue et al reported that lower dose of irradiation (mean marginal dose, 19.5 Gy) showed over 85% obliteration rate in AVM⁴⁷. Also, Foote et al.¹⁸ reported 66% of size reduction of low-prescribed dose radiosurgery (median marginal dose, 12.5 Gy) for large AVM. Salvage radiosurgery (median marginal dose, 15 Gy; medial interval from 1st treatment, 41 months) was performed, they reported 60% cure rate after salvage re-treatment and 1.9% of radiation-induced complication. Al-

Table 1. Summary of patient and treatment characteristics in series using volume staged radiosurgery for large AVMs

Study	Number of enrolled patients	Median age (years)	Median total AVM volume (cm ³)	Treatment modality	Dose of each session	Mean volume of each session (cm ³)	No. of stages	Time interval of stages (months)	S-M grade	Previous hemorrhage	Pre-radiosurgery embolization	Rate of complete obliteration	Rate of radiation induced complication	Latent period hemorrhage	FU period (median, years)
Sirin et al. ⁵¹ (2006)	28	37	24.9	GKRS	13–18 Gy/ 13–18 Gy	Median 12.3/11.5	2: 26 (93%) 3: 2 (7%)	Median 5	III: 2 (7%) IV: 11 (39%) V: 15 (54%)	13/28 (46%)	13/28 (46%)	7/14 (50%)	4/28 (14%)	4/28 (14%)	4.2
Kano et al. ³¹ (2012)	47	33	22.0	GKRS	13–18 Gy/ 13–18 Gy	11.5/9.5	2: 32 (89%) 3: 4 (11%)	Mean 4.9	III: 5 (11%) IV: 28 (60%) V: 14 (30%)	18/47 (38%)	21/47 (45%)	17/47 (36%)	3/47 (6%)	8/47 (17%)	7.3
Franzin et al. ¹⁹ (2016)	20	Mean 38	Mean 15.9	GKRS	18–25 Gy/ 13–24 Gy	7.8/4.7	2	Mean 13	III: 10 (50%) IV: 7 (35%) V: 3 (6%)	6/30 (25%)	11/20 (55%)	8/20 (40%)	5/20 (25%)	2/20 (10%)	3.8
Seymour et al. ⁴⁹ (2016)	31	35	18.9	GKRS	16–18 Gy	Median 6.8/6.8	2: 22 (71%) 3: 8 (26%) 4: 1 (3%)	Median 3.7	III: 10 (32%) IV: 16 (52%) V: 5 (16%)	11/31 (35%)	5/31 (16%)	13/31 (42%)	13/31 (37%)	23/31 (74%)	4.8
Hanakita et al. ²³ (2016)	18	Mean 37	38	GKRS	16 Gy/ 16 Gy/ 16 Gy	NA	2: 10 (56%) 3: 8 (44%)	Median 6	III: 4 (22%) IV: 7 (39%) V: 7 (39%)	12/18 (67%)	3/18 (17%)	6/18 (33%)	12/18 (67%)	4/18 (22%)	4.4
Pollock et al. ⁴⁵ (2017)	34	31	22.2	GKRS	14–18 Gy	10.7	2–4	Median 5	III: 8 (34%) IV: 19 (56%) V: 5 (15%)	12/34 (35%)	4/34 (12%)	18/34 (53%)	2/34 (6%)	6/34 (18%)	8.2

AVM : arteriovenous malformation, S-M grade : Spetzler-Martin grade, GKRS : gamma knife radiosurgery, FU : follow-up, NA : not applicable

Table 2. Summary of hypofractionated radiotherapy for large AVM

Study	Number of enrolled patients	Median age (years)	Mean AVM volume (cm ³)	Treatment modality	Total dose (Gy)/ Fraction (Fr)	S-M grade	Previous hemorrhage	Pre-radiosurgery embolization	Rate of complete obliteration	Rate of radiation induced complication	Latent period hemorrhage	FU period (median, years)
Aoyama et al. ³⁾ (2001)	26	NA	NA	LINAC	35/4	NA	12/26 (46%)	1/26 (4%)	53% (3-year actuarial rate)	0%	2/26 (8%)	3
Chang et al. ⁷⁾ (2004)	33	NA	NA	LINAC	35/4	Grade 3≥17 (52%)	15/33 (45%)	3/30 (10%)	32% (3-year actuarial rate)	1/33 (3%)	6/33 (18%)	3.1
Xiao et al. ^{5b)} (2010)	20	34	46.8	LINAC	30/5 30/6 25/5	IV : 7 (35%) V : 13 (65%)	11/20 (55%)	10/20 (50%)	1/20 (5%)	1/20 (5%)	1/20 (5%)	2.7
Murray et al. ³⁹⁾ (2014)	10	Mean 43.2	22.4	LINAC	55/11	NA	4/10 (40%)	NA	5/10 (50%)	NA	NA	3.5
Chen et al. ⁸⁾ (2016)	34	Mean 43.8	11.4	LINAC	35/5	mRBAS : 2.01	17/34 (50%)	8/34 (23%)	26/34(74%)	14/34 (41%)	2/34 (6%)	8
Boström et al. ⁶⁾ (2016)	14	37	11.4	LINAC	30–55/5–11	III : 5 (36%) IV : 4 (29%) V : 3 (21%)	8/15 (53%)	5/14 (36%)	4/14 (29%)	1/14 (7%)	2/14 (14%)	3.6

AVM : arteriovenous malformation, S-M grade : Spetzler-Martin grade, FU : follow-up, NA : not applicable, LINAC : linear accelerator, mRBAS : modified Radiosurgery-Based Arteriovenous Malformation Score

though, they did not intend dose-staging radiosurgery, they reviewed the volume reduction rate of low dose radiosurgery and indirectly showed favorable outcome of dose-staging radiosurgery.

In the representative study of Park et al.⁴¹⁾, they reported favorable outcome of dose-staged radiosurgery for large AVM (mean volume, 20.42 cm³) (Table 3). They treated 37 patients of AVM by dose-staged (2 stages) radiosurgery (GKRS) and followed-up after completion of session for 3.1 years. In first session, marginal dose of 13 Gy was given for mean nidus volume 19.6 cm³, and in second session, marginal dose of 17 Gy was given for mean nidus volume 6.9 cm³ (interval of session, 39 months). In first session, they treated larger volume of nidus using lower dose of radiation compared to second session of radiosurgery and reported 62.5% complete obliteration rate with no symptomatic radiation necrosis⁴¹⁾.

There has been debate of superiority between VS-RS and dose-staged radiosurgery for AVM. In the systematic review of Moosa et al.³⁸⁾, dose-staged SRS for AVM showed lower obliteration and similar complication rates compared with volume staged SRS for AVM. They preferred VS-RS to dose-staged SRS for large AVM. However, in their study, the definition of dose-staged RS included HfRT⁵²⁾. For now, in our institution, we also prefer VS-RS to dose-staged radiosurgery for large AVM. Future comparative study for dose-staged and VS-RS will be needed to evaluate superiority between two methods.

COMPLICATION OF RS FOR CEREBRAL AVM

Dose prescription of AVM radiosurgery must take into account not only the chance of obliteration but also the risk of radiation induced complication. Post-radiosurgery complications include brain edema, radiation necrosis, arterial stenosis, delated cyst formation and organizing hematoma^{16,28,42)}.

Two possible mechanism of postradiosurgery complication have been suggested. First, direct radiation injury of adjacent parenchyma, and another mechanism is the hemodynamic change after irradiation³⁴⁾. Radiation injury of adjacent white matter seems to be damage to oligodendrocytes following reactions of other glial cells such as microglia and astrocytes, which may be related to brain edema, necrosis, and delayed cyst formation. Radiation effects on arteries or draining veins seem to involve damage to endothelial cells followed by reac-

Table 3. Summary of dose-staged radiosurgery for large AVMs

Study	Number of patients	Mean age (years)	Mean volume (cm ³)	Mean dose of each session (Gy)	Treatment modality	Number of stages	Time interval of stages (months)	S-M grade	previous hemorrhage	Pre-radiosurgery embolization	Rate of complete obliteration	Rate of radiation induced complication	Latent period hemorrhage	Mean FU period (years)
Park et al. ⁴¹⁾ (2016)	45	29	20.4	2 stages : 13 Gy/ 17 Gy 3 stages : 12.25 Gy/ 13.5 Gy/ 15.5 Gy	GKRS	2 stages : 37 (82%) 3 stages : 8 (18%)	Median : 39	III : 17 (38%) IV : 11 (24%) V : 2 (4%)	10/45 (22%)	6/45 (13%)	29/45 (64%)	0%	5/45 (11.1%)	8.7

AVM : arteriovenous malformation, S-M grade : Spetzler-Martin grade, FU : follow-up, GKRS : gamma-knife radiosurgery

tions of the microscopic and macroscopic vascular wall, which may cause arterial stenosis, encapsulated hematoma, and hemorrhage after nidus obliteration²⁷⁾.

The incidence of post-radiosurgery complication is varied, the incidence rate of radiological post-radiosurgical complication has been reported 30–40%^{11,14,16)}. However, symptomatic complication rate was reported from 8.1 to 11.8%^{11,14)}. Izawa et al.²⁸⁾ reported long-term complication of GKRS for AVM, they reported 3.4% of delayed cyst formation, 1.7% of increasing seizure activity and 0.4% of white matter signal change in MRI. Also, there was report of new nidus development around the obliterated nidus after GKRS, Yun et al.⁵⁹⁾ reported successfully treated redo GKRS for new nidus development around obliterated nidus and new nidi were detected after 31, 132, and 36 months after initial GKRS.

Management of post-radiosurgical complication should be performed individually. Corticosteroid showed favorable symptom resolution of post-radiosurgical complication, corticosteroid showed 34% of complete resolution of symptoms and 49% of partial improvement of symptoms¹⁴⁾.

The risk factors of post-radiosurgical complication also has been reported. Flickinger et al.¹⁶⁾ suggested “The 12-Gy volume” which is normal brain area received over 12 Gy adjacent of lesion was associated symptomatic post-radiosurgical image changing. Friedman et al.²⁰⁾ reported 12-Gy volume and eloquent location were predictive factors for radiation-induced complication. Also, Izawa et al.²⁸⁾ reported large nidus volume and lobar location were risk factors for long-term complication. In addition, they also reported higher dose of GKRS, large volume, complete nidus obliteration and lobar location of AVM were associated with delayed cyst formation²⁸⁾.

The rate of latent period hemorrhage after SRS for AVM were reported 2.6% to 10%^{5,11,20,28)}. In meta-analysis of van Beijnum et al.⁵⁵⁾, the rate of hemorrhage after SRS was 5.8% which showed higher than hemorrhage rate after microsurgery and embolization (0% and 1.9%, respectively). The risk of latent period hemorrhage was higher in older age, larger AVM and lower when used higher radiation dose³²⁾. However, prior rupture of AVM before SRS was not a predictor of post-radiosurgery hemorrhage¹¹⁾.

The relatively non-invasiveness of treatment itself of SRS is strong advantage in AVM treatment. However, there has been potential risk of radiation induced complication and risk of latent period hemorrhage. It should be informed to patient

and their caretaker, moreover, clinicians should keep in their mind of this complications.

CONCLUSION

SRS plays major role in treatment of brain AVM. SRS showed excellent obliteration rate in small AVM. Although SRS showed favorable outcome in large AVM in some studies, the radiosurgical treatment of large AVM still have challenges which including low obliteration rate and radiation-induced complications. We should keep in mind of posttreatment complication and relatively higher latent period hemorrhage after SRS of AVM. To author’s personal experience, long-term staging method of VS-RS (interval of session, >2 years) is the most suitable strategy for large AVM. In the future, novel therapy which incorporate endovascular treatment using liquid embolic material and new radiosurgical technique such as gene or cytokine-targeted radio-sensitization should be needed.

CONFLICTS OF INTEREST

No potential conflict of interest relevant to this article was reported.

INFORMED CONSENT

This type of study does not require informed consent.

AUTHOR CONTRIBUTIONS

Conceptualization : JB, DHK

Data curation : JB

Formal analysis : JB, DHL, WP, JSA

Methodology : JB, JCP, JSA

Project administration : JB, DHK

Visualization : JB

Writing - original draft : JB

Writing - review & editing : JB, DHK

ORCID

Joonho Byun	https://orcid.org/0000-0003-0687-3286
Do Hoon Kwon	https://orcid.org/0000-0002-3429-7119
Do Heui Lee	https://orcid.org/0000-0002-8264-8040
Wonhyoung Park	https://orcid.org/0000-0002-9977-0595
Jung Cheol Park	https://orcid.org/0000-0001-6677-455X
Jae Sung Ahn	https://orcid.org/0000-0001-6134-6214

• Acknowledgements

We are indebted to neuroradiologists and members of Gamma Knife Center at our institute who cooperate with us. We appreciate their efforts for the consultation and collaborative management of neurosurgical patients. We also thank Jae Woong Jeon, MD, in Daejeon who gave us warm advice for manuscript.

References

1. Abla AA, Rutledge WC, Seymour ZA, Guo D, Kim H, Gupta N, et al. : A treatment paradigm for high-grade brain arteriovenous malformations: volume-staged radiosurgical downgrading followed by microsurgical resection. **J Neurosurg** **122** : 419-432, 2014
2. Andrade-Souza YM, Ramani M, Beachey DJ, Scora D, Tsao MN, terBrugge K, et al. : Liquid embolisation material reduces the delivered radiation dose: a physical experiment. **Acta Neurochir (Wien)** **150** : 161-164; discussion 164, 2008
3. Aoyama H, Shirato H, Nishioka T, Kageia K, Onimaru R, Suzukic K, et al. : Treatment outcome of single or hypofractionated single-isocentric stereotactic irradiation (STI) using a linear accelerator for intracranial arteriovenous malformation. **Radiother Oncol** **59** : 323-328, 2001
4. Awad AJ, Walcott BP, Stapleton CJ, Ding D, Leed CC, Loeffler JS : Repeat radiosurgery for cerebral arteriovenous malformations. **J Clin Neurosci** **22** : 945-950, 2015
5. Bir SC, Ambekar S, Maiti TK, Nanda A : Clinical outcome and complications of gamma knife radiosurgery for intracranial arteriovenous malformations. **J Clin Neurosci** **22** : 1177-1122, 2015
6. Boström JP, Bruckermann R, Pintea B, Boström A, Surber G, Hamm K : Treatment of cerebral arteriovenous malformations with radiosurgery or hypofractionated stereotactic radiotherapy in a consecutive pooled linear accelerator series. **World Neurosurg** **94** : 328-338, 2016
7. Chang TC, Shirato H, Aoyama H, Ushikoshi S, Kato N, Kuroda S, et al. : Stereotactic irradiation for intracranial arteriovenous malformation using stereotactic radiosurgery or hypofractionated stereotactic radiotherapy. **Int J Radiat Oncol Biol Phys** **60** : 861-870, 2004
8. Chen JC, Mariscal L, Girvigian MR, Vanefsky MA, Glousman BN, Miller MJ, et al. : Hypofractionated stereotactic radiosurgery for treatment of cerebral arteriovenous malformations: outcome analysis with use of the modified arteriovenous malformation scoring system. **J Clin Neurosci** **29** : 155-161, 2016
9. Chun DH, Kim MS, Kim ST, Paeng SH, Jeong HW, Lee WH : Embolization with gamma knife radiosurgery of giant intracranial arteriovenous malformations. **Turk Neurosurg** **26** : 709-713, 2016
10. Chytka T, Liscak R, Kozubiková P, Vymazal J : Radiosurgery for large arteriovenous malformations as a single-session or staged treatment. **Stereotact Funct Neurosurg** **93** : 342-347, 2015
11. Ding D, Yen CP, Starke RM, Xu Z, Sun X, Sheehan JP : Outcomes following single-session radiosurgery for high-grade intracranial arteriovenous malformations. **Br J Neurosurg** **28** : 666-674, 2014
12. Elhamady MS, Heros RC : Editorial: the ARUBA study: where do we go from here? **J Neurosurg** **126** : 481-485, 2017
13. Flickinger JC, Kondziolka D, Lunsford LD, Kassam A, Phuong LK, Liscak R, et al. : Development of a model to predict permanent symptomatic postradiosurgery injury for arteriovenous malformation patients. Arteriovenous Malformation Radiosurgery Study Group. **Int J Radiat Oncol Biol Phys** **46** : 1143-1148, 2000
14. Flickinger JC, Kondziolka D, Lunsford LD, Pollock BE, Yamamoto M, Gorman DA, et al. : A multi-institutional analysis of complication outcomes after arteriovenous malformation radiosurgery. **Int J Radiat Oncol Biol Phys** **44** : 67-74, 1999
15. Flickinger JC, Kondziolka D, Maitza AH, Lunsford LD : An analysis of the dose-response for arteriovenous malformation radiosurgery and other factors affecting obliteration. **Radiother Oncol** **63** : 347-354, 2002
16. Flickinger JC, Kondziolka D, Pollock BE, Maitz AH, Lunsford LD : Complications from arteriovenous malformation radiosurgery: multivariate analysis and risk modeling. **Int J Radiat Oncol Biol Phys** **38** : 485-490, 1997
17. Flickinger JC, Pollock BE, Kondziolka D, Lunsford LD : A dose-response analysis of arteriovenous malformation obliteration after radiosurgery. **Int J Radiat Oncol Biol Phys** **36** : 873-879, 1996
18. Foote KD, Friedman WA, Ellis TL, Bova FJ, Buatti JM, Meeks SL : Salvage retreatment after failure of radiosurgery in patients with arteriovenous malformations. **J Neurosurg** **98** : 337-341, 2003
19. Franzin A, Panni P, Spatola G, Del Vecchio A, Gallotti AL, Gigliotti CR, et al. : Results of volume-staged fractionated gamma knife radiosurgery for large complex arteriovenous malformations: obliteration rates and clinical outcomes of an evolving treatment paradigm. **J Neurosurg** **125(Suppl 1)** : 104-113, 2016
20. Friedman WA, Bova FJ, Bollampally S, Bradshaw P : Analysis of factors predictive of success or complications in arteriovenous malformation radiosurgery. **Neurosurgery** **52** : 296-308; discussion 307-308, 2003
20. Gobin YP, Laurent A, Merienne L, Schlienger M, Aymard A, Houdart E, et al. : Treatment of brain arteriovenous malformations by embolization and radiosurgery. **J Neurosurg** **85** : 19-28, 1996
22. Gross BA, Du R : Natural history of cerebral arteriovenous malformations: a meta-analysis. **J Neurosurg** **118** : 437-443, 2013
23. Hanakita S, Shin M, Koga T, Igaki H, Saito N : Outcomes of volume-

- staged radiosurgery for cerebral arteriovenous malformations larger than 20 cm³ with more than 3 years of follow-up. **World Neurosurg** **87** : 242-249, 2016
24. Haw CS, terBrugge K, Willinsky R, Tomlinson G: Complications of embolization of arteriovenous malformations of the brain. **J Neurosurg** **104** : 226-232, 2006
 25. Hodgson TJ, Kemeny AA, Gholkar A, Deasy N : Embolization of residual fistula following stereotactic radiosurgery in cerebral arteriovenous malformations. **AJNR Am J Neuroradiol** **30** : 109-110, 2009
 26. Ilyas A, Ding D, Robert Hixson H, Xu Z, Starke RM, Sheehan JP : Volume-staged stereotactic radiosurgery for large intracranial arteriovenous malformations. **J Clin Neurosci** **43** : 202-207, 2017
 27. Inoue HK : Long-term results of gamma knife surgery for arteriovenous malformations: 10- to 15-year follow up in patients treated with lower doses. **J Neurosurg** **105 Suppl** : 64-68, 2006
 28. Izawa M, Hayashi M, Chernov M, Nakaya K, Ochiai T, Norikomurata, et al. : Long-term complications after gamma knife surgery for arteriovenous malformations. **J Neurosurg** **102 Suppl** : 34-37, 2005
 29. Kano H, Flickinger JC, Tonetti D, Hsu A, Yang HC, Flannery TJ, et al. : Estimating the risks of adverse radiation effects after gamma knife radiosurgery for arteriovenous malformations. **Stroke** **48** : 84-90, 2017
 30. Kano H, Kondziolka D, Flickinger JC, Park KJ, Iyer A, Yang HC, et al. : Stereotactic radiosurgery after embolization for arteriovenous malformations. **Prog Neurol Surg** **27** : 89-96, 2013
 31. Kano H, Kondziolka D, Flickinger JC, Park KJ, Iyer A, Yang HC, et al. : Stereotactic radiosurgery for arteriovenous malformations after embolization: a case-control study. **J Neurosurg** **117** : 265-275, 2012
 32. Karlsson B, Lax I, Soderman M : Risk for hemorrhage during the 2-year latency period following gamma knife radiosurgery for arteriovenous malformations. **Int J Radiat Oncol Biol Phys** **49** : 1045-1051, 2001
 33. Karlsson B, Lindqvist M, Blomgren H, Wan-Yeo G, Söderman M, Lax I, et al. : Long-term results after fractionated radiation therapy for large brain arteriovenous malformations. **Neurosurgery** **57** : 42-49; discussion 42-49, 2005
 34. Kim JW, Chung HT, Han MH, Kim DG, Paek SH : Brain edema after repeat gamma knife radiosurgery for a large arteriovenous malformation: a case report. **Exp Neurobiol** **25** : 191-196, 2016
 35. Maesawa S, Flickinger JC, Kondziolka D, Lunsford LD : Repeated radiosurgery for incompletely obliterated arteriovenous malformations. **J Neurosurg** **92** : 961-970, 2000
 36. Marks MP, Marcellus ML, Santarelli J, Dodd RL, Do HM, Chang SD, et al. : Embolization followed by radiosurgery for the treatment of brain arteriovenous malformations (AVMs). **World Neurosurg** **99** : 471-476, 2017
 37. Mohr JP, Parides MK, Stapf C, Moquete E, Moy CS, Overbey JR, et al. : Medical management with or without interventional therapy for unruptured brain arteriovenous malformations (ARUBA): a multicentre, non-blinded, randomised trial. **Lancet** **383** : 614-621, 2014
 38. Moosa S, Chen CJ, Ding D, Lee CC, Chivukula S, Starke RM, et al. : Volume-staged versus dose-staged radiosurgery outcomes for large intracranial arteriovenous malformations. **Neurosurg Focus** **3** : E18, 2014
 39. Murray AL, Dally M, Jeffreys A, Hwang P, Anderson JF : Neuropsychological outcomes of stereotactic radiotherapy for cerebral arteriovenous malformations. **J Clin Neurosci** **21** : 601-606, 2014
 40. Nagy G, Grainger A, Hodgson TJ, Rowe JG, Coley SC, Kemeny AA, et al. : Staged-volume radiosurgery of large arteriovenous malformations improves outcome by reducing the rate of adverse radiation effects. **Neurosurgery** **80** : 180-192, 2017
 41. Park HR, Lee JM, Kim JW, Han JH, Chung HT, Han MH, et al. : Time-staged gamma knife stereotactic radiosurgery for large cerebral arteriovenous malformations: a preliminary report. **PLoS One** **11** : e0165783, 2016
 42. Park JC, Ahn JS, Kwon DH, Kwun BD : growing organized hematomas following gamma knife radiosurgery for cerebral arteriovenous malformation : five cases of surgical excision. **J Korean Neurosurg Soc** **58** : 83-88, 2015
 43. Pollock BE, Kline RW, Stafford SL, Foote RL, Schomberg PJ : The rationale and technique of staged-volume arteriovenous malformation radiosurgery. **Int J Radiat Oncol Biol Phys** **48** : 817-824, 2000
 44. Pollock BE, Kondziolka D, Lunsford LD, Bissonette D, Flickinger JC : Repeat stereotactic radiosurgery of arteriovenous malformations: factors associated with incomplete obliteration. **Neurosurgery** **38** : 318-324, 1996
 45. Pollock BE, Link MJ, Stafford SL, Lanzino G, Garces YI, Foote RL : Volume-staged stereotactic radiosurgery for intracranial arteriovenous malformations: outcomes based on an 18-year experience. **Neurosurgery** **80** : 543-550, 2017
 46. Potts MB, Zumofen DW, Raz E, Nelson PK, Riina HA : Curing arteriovenous malformations using embolization. **Neurosurg Focus** **37** : E19, 2014
 47. Rao VRK, Mandalam KR, Gupta AK, Kumar S, Joseph S : Dissolution of isobutyl 2-cyanoacrylate on longterm follow-up. **AJNR Am J Neuroradiol** **10** : 135-141, 1989
 48. Reig AS, Rajaram R, Simon S, Mericle RA : Complete angiographic obliteration of intracranial AVMs with endovascular embolization: incomplete embolic nidal opacification is associated with AVM recurrence. **J Neurointerv Surg** **2** : 202-207, 2010
 49. Seymour ZA, Sneed PK, Gupta N, Lawton MT, Molinaro AM, Young W, et al. : Volume-staged radiosurgery for large arteriovenous malformations: an evolving paradigm. **J Neurosurg** **124** : 163-174, 2016
 50. Shtraus N, Schifter D, Corn BW, Maimon S, Alani S, Frolov V, et al. : Radiosurgical treatment planning of AVM following embolization with Onyx: possible dosage error in treatment planning can be averted. **J Neurooncol** **98** : 271-276, 2010
 51. Sirin S, Kondziolka D, Niranjana A, Flickinger JC, Maitz AH, Lunsford LD : Prospective staged volume radiosurgery for large arteriovenous malformations: indications and outcomes in otherwise untreatable patients. **Neurosurgery** **58** : 17-27; discussion 17-27, 2006
 52. Spetzler RF, Ponce FA : A 3-tier classification of cerebral arteriovenous malformations. Clinical article. **J Neurosurg** **114** : 842-849, 2011
 53. Stahl JM, Chi YY, Friedman WA : Repeat radiosurgery for intracranial

- arteriovenous malformations. **Neurosurgery** 70 : 150-154; discussion 154, 2012
54. Stapf C, Mast H, Sciacca RR, Choi JH, Khaw AV, Connolly ES, et al. : Predictors of hemorrhage in patients with untreated brain arteriovenous malformation. **Neurology** 66 : 1350-1355, 2006
55. van Beijnum J, van der Worp HB, Buis DR, Al-Shahi Salman R, Kappelle LJ, Rinkel GJ, et al. : Treatment of brain arteriovenous malformations: a systematic review and meta-analysis. **JAMA** 306 : 2011-2019, 2011
56. Veznedaroglu E, Andrews DW, Benitez RP, Downes MB, Werner-Wasik M, Rosenstock J, et al. : Fractionated stereotactic radiotherapy for the treatment of large arteriovenous malformations with or without previous partial embolization. **Neurosurgery** 55 : 519-531; discussion 530-531, 2004
57. Wong J, Slomovic A, Ibrahim G, Radovanovic I, Tymianski M : Microsurgery for ARUBA Trial (a randomized trial of unruptured brain arteriovenous malformation)-eligible unruptured brain arteriovenous malformations. **Stroke** 48 : 136-144, 2017
58. Xiao F, Gorgulho AA, Lin CS, Chen CH, Agazaryan N, Viñuela F, et al. : Treatment of giant cerebral arteriovenous malformation: hypofractionated stereotactic radiation as the first stage. **Neurosurgery** 67 : 1253-1259; discussion 1259, 2010
59. Yun JH, Kwon DH, Lee EJ, Lee DH, Ahn JS, Kwun BD : New nidus formation adjacent to the target site of an arteriovenous malformation treated by gamma knife surgery. **J Neurosurg** 117 Suppl : 120-125, 2012
60. Zhang Q, Jing L, Liu J, Wang K, Zhang Y, Paliwal N, et al. : Predisposing factors for recanalization of cerebral aneurysms after endovascular embolization: a multivariate study. **J Neurointerv Surg** 10 : 252-257, 2018
61. Zhong J, Press RH, Olson JJ, Oyesiku NM, Shu HG, Eaton BR : The use of hypofractionated radiosurgery for the treatment of intracranial lesions unsuitable for single-fraction radiosurgery. **Neurosurgery** 83 : 850-857, 2018