



Successful Endovascular Treatment of an Infected Aortic Aneurysm Induced by *Klebsiella pneumoniae*

*Klebsiella pneumoniae*로 인해 발생한 감염성 동맥류의 성공적인 혈관 내 치료

Hong Gwon Byun, MD¹ , Yook Kim, MD^{1*} , Jung Hwan Lee, MD¹ ,
 Jisun Lee, MD¹ , Kil Sun Park, MD²

¹Department of Radiology, Chungbuk National University Hospital, Cheongju, Korea

²Department of Radiology, Chungbuk National University College of Medicine, Cheongju, Korea

Aortic aneurysms infected by *Klebsiella pneumoniae* are rarely seen. We describe a 50-year-old man with infected aortic aneurysm that was successfully treated with endovascular aneurysm repair (EVAR). Diagnosis was confirmed using blood culture and computed tomography (CT). Intravenous antibiotics were immediately administered, with improvements in clinical findings and negative blood cultures before the procedure. Twenty-four months after the procedure, the patient was stable and serial CT revealed regression of the infected aortic aneurysm. Therefore, after controlling bacteremia and fever with targeted antibiotic therapy, EVAR can be considered as an alternative for patients who have serious comorbidities and are ineligible for conventional surgery.

Index terms Aneurysm, Infected; Endovascular Procedure; *Klebsiella* Infections; Antibiotics

INTRODUCTION

Infected aortic aneurysm is defined as the infectious destruction of the arterial wall with the formation of a saccular outpouching lesion that is connected to the arterial lumen. It is a rare, life-threatening condition, with an incidence of 0.7–3% among all aortic aneurysms. Untreated or delayed treatment of infected aortic aneurysms often leads to fulminant sepsis, spontaneous arterial rupture, and death (1, 2).

Traditional treatment option of the infected aortic aneurysm is surgical resection and debridement of the infected aorta and surrounding tissue, and in situ or extra-anatomical bypass, followed by long-term antibiotic therapy. However, surgical management is

Received June 30, 2019
 Revised September 6, 2019
 Accepted September 14, 2019

*Corresponding author

Yook Kim, MD
 Department of Radiology,
 Chungbuk National
 University Hospital,
 776 1sunhwan-ro, Seowon-gu,
 Cheongju 28644, Korea.

Tel 82-43-269-6365

Fax 82-43-269-6479

E-mail sixtwin@hanmail.net

This is an Open Access article distributed under the terms of the Creative Commons Attribution Non-Commercial License (<https://creativecommons.org/licenses/by-nc/4.0>) which permits unrestricted non-commercial use, distribution, and reproduction in any medium, provided the original work is properly cited.

ORCID iDs

Hong Gwon Byun
<https://orcid.org/0000-0002-3227-1900>
 Yook Kim
<https://orcid.org/0000-0003-2162-419X>
 Jung Hwan Lee
<https://orcid.org/0000-0002-8815-4092>
 Jisun Lee
<https://orcid.org/0000-0002-6264-7171>
 Kil Sun Park
<https://orcid.org/0000-0002-2639-3522>

associated with high risk and mortality rates (22–36%) (2, 3).

In recent decades, endovascular aortic repair (EVAR) for thoracic or abdominal aortic aneurysms has become widespread, with satisfactory results (4). Recent studies have reported that the endovascular treatments for infected aortic aneurysm are simpler than conventional treatments and may be effective for long-term prognosis (5). They may be good alternative treatments for infected aortic aneurysm; nevertheless, placement of an endovascular graft in an infected field remains a matter of controversy (2, 4).

Therefore, we present a case of a successful endovascular treatment, combined with targeted antibiotic therapy for infected aortic aneurysm induced by *Klebsiella pneumoniae* (*K. pneumoniae*), without complications on long-term follow-up.

CASE REPORT

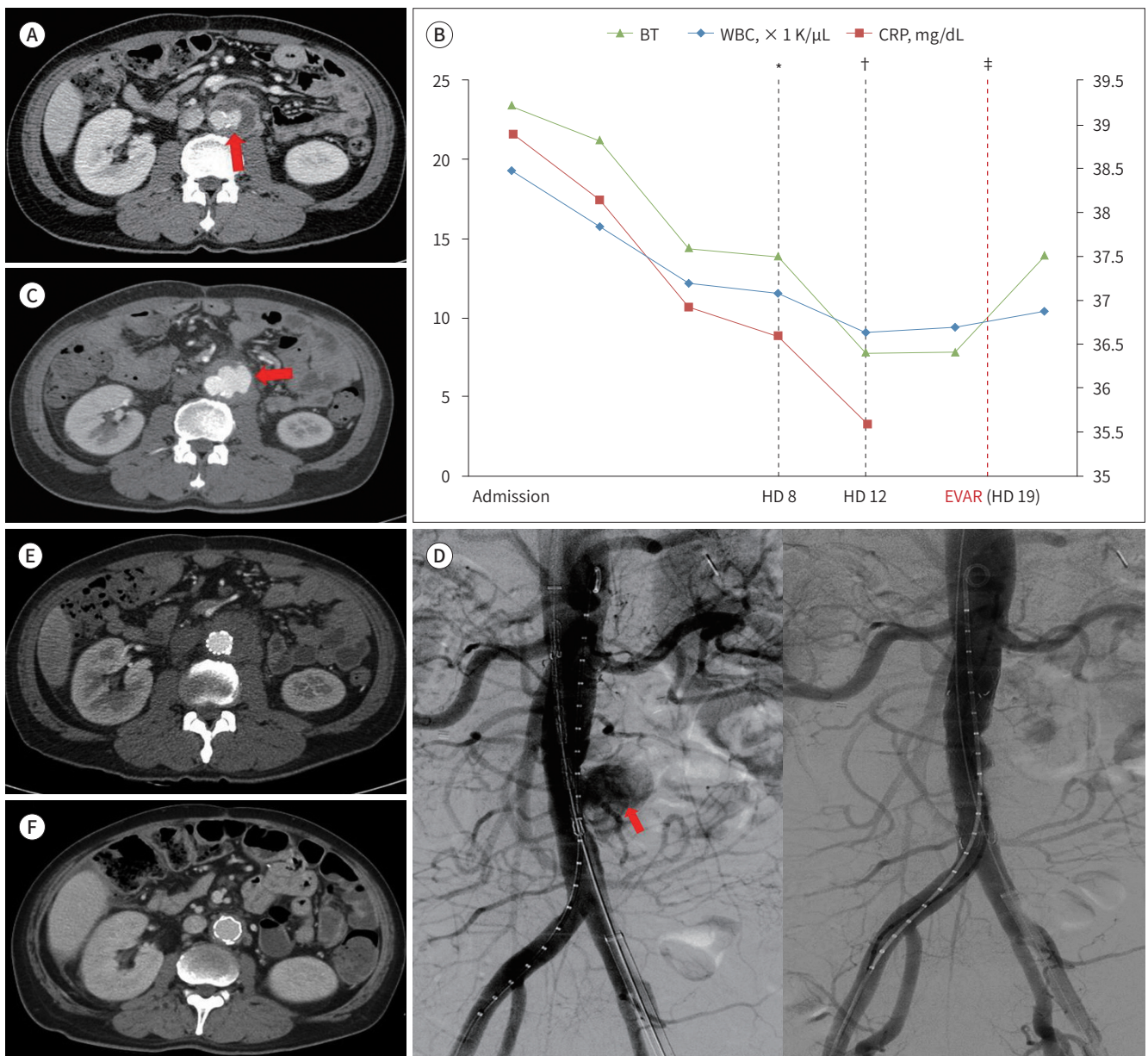
A 50-year-old man with pancreatic cancer and hepatic metastasis presented to the emergency room with high fever (39.2°C). Laboratory examinations revealed white blood cell (WBC) count and C-reactive protein (CRP) level elevated at $19.24 \times 10^3/\mu\text{L}$ (normal range $4.0\text{--}10.0 \times 10^3/\mu\text{L}$) and 21.52 mg/dL (normal concentration < 0.3 mg/dL), respectively. Abdominal contrast-enhanced computed tomography (CT) revealed a 3.9-cm diameter saccular aneurysm arising from the left lateral aspect of the infrarenal aorta with surrounding thrombus and periaortic inflammation (Fig. 1A). Based on imaging and the presence of infection, we made a diagnosis of infected aortic aneurysm. Initially, the patient was treated with empirical intravenous antibiotics (piperacillin/tazobactam) for 7 days until specific bacterial growth on blood culture.

EVAR was chosen as the treatment of choice because the patient had a high risk of perioperative death and limited life expectancy.

Before endovascular treatment, *K. pneumoniae* grew on the initial blood culture. The antibiotics were changed (ceftriaxone and ciprofloxacin) according to the sensitivity identified from the preoperative blood culture. Four days later, his body temperature was returned to normal levels, and the CRP level was markedly decreased. The WBC count normalized after 1 week. Finally, no bacterial growth was detected on numerous follow-up blood cultures during specific antibiotic treatments for 12 days (Fig. 1B).

Follow-up CT was performed 2 weeks later to evaluate the infected aortic aneurysm prior to EVAR. This study revealed that the size of the enhancing portion of the infected aortic aneurysm increased from 2.7 cm to 3.9 cm, and shape changed into a more irregular and increased outpouching enhancing lesion at left lateral aspect of infected aortic aneurysm, suggesting impending rupture (Fig. 1C). Immediate endovascular treatment was performed using a 22 mm diameter and 8 cm length stent graft (Hercules: S&G Biotech Inc. Seongnam, Korea) (Fig. 1D). The patient had an uneventful operative and postoperative course. An immediate follow-up CT revealed complete isolation of the infected aortic aneurysm with no signs of complications such as endoleak (Fig. 1E). The patient was treated with postoperative antibiotics for 2 days without any signs of infection. Twelve-month follow-up CT showed considerable decrease in aortic inflammation with near total isolation and shrinkage of the aneurysm. To date, 24 months after endovascular graft implantation, the patient was complete-

Fig. 1. A 50-year-old man with *Klebsiella pneumoniae* induced aortic aneurysm. Primary diagnosis is based on abdominal CT.
A. Initial abdominal enhanced axial CT image shows a 3.9-cm diameter saccular aneurysm (arrow) arising from the left lateral aspect of the infrarenal aorta with surrounding thrombus and periaortic inflammation, suggesting an infected aortic aneurysm.
B. Trending chart of the infection markers according to a timeline. CRP, WBC count, and BT are highly elevated on initial examination. Infection markers markedly decrease after using bacterial-specific antibiotics. Endovascular treatment is administered after normalization of infection markers and absence of bacterial growth on blood culture.
C. The pre-procedure follow-up CT angiogram 2 weeks later demonstrates an increase in the size of the saccular aneurysm and changes in the shape, suggesting impending rupture (arrow).
D. Abdominal aorta angiography demonstrates contrast pulling to the left side of the infrarenal abdominal aorta (arrow). After implantation of stent graft including the infected aortic aneurysmal site, the aneurysm is completely isolated on control angiography.
E. Immediate follow-up CT scan reveals complete isolation of the infected aortic aneurysm with no signs of complications such as endoleak.
F. The follow up CT scan after 24 months of stent graft insertion demonstrates no significant complications associated with the procedure.
 *Time when the antibiotic treatment was changed (changed on HD 8).
 †Time when the fever was subsided (normalization of BT on HD 12).
 ‡No evidence of bacterial growth on follow-up blood culture and performance of the EVAR on HD 19.
 BT = body temperature, CRP = C-reactive protein, CT = computed tomography, EVAR = endovascular aortic repair, HD = hospital days, WBC = white blood cell



ly asymptomatic with no signs of procedure-related complications such as infection, aneurysmal growth, endoleak, or graft fracture (Fig. 1F).

DISCUSSION

Several bacterial species are involved in inflammatory processes, the most common being *Staphylococcus aureus* (40%), *Salmonella* (15%), *Streptococci* (8%), *Escherichia coli* (7%), and in some cases, *Klebsiella*, *Haemophilus influenzae*, and *Mycobacterium tuberculosis*. As a result of bacteremia, atheromatous lesions inside the aneurysm may become infected, leading to necrosis of the aortic wall and subsequent aneurysmal rupture. Typical symptoms of infection include fever, elevated WBC count and CRP level, as well as severe back and abdominal pain (1, 6). As demonstrated in our case, there were two consecutive preoperative CT scans taken within the period of 3 weeks, and there was an increase in the sac size, suggesting impending rupture within a short period of time. This is a characteristic of a rapidly enlarging infected aortic aneurysm. Given that rupture is highly associated with poor prognosis after endovascular treatment, EVAR should be performed immediately without delay. Short-term repeated follow-up CT and evaluation of infection parameters (e.g., CRP) are necessary before performing EVAR (3).

Resection of the infected aorta and in situ graft replacement, together with long-term intravenous antibiotic therapy is considered the standard of care (7, 8). Nevertheless, traditional open surgery entails complex techniques and procedures. Therefore, this surgical intervention is associated with high rates of morbidity and mortality. By contrast, endovascular treatment of infected aortic aneurysm has significant advantages over open surgery in that it avoids a large incision, full heparinization, extracorporeal circulation, aortic cross-clamping, interference with respiratory function, and the need for substantial blood transfusion (3). A systemic review of outcomes after EVAR for infected aortic aneurysm showed that endovascular treatment of infected aortic aneurysm is feasible and it is a durable treatment option for most patients (2, 7). Nevertheless, the release of the endoprosthesis in the infected area is controversial and violates general surgical principles; these objections do not pertain to EVAR. If the infection persists after EVAR, it is likely to produce subsequent irremediable disaster. We suggest that EVAR can be performed in selected patients with infected aortic aneurysm. First, this type of repair should be considered in patients at high risk for major complications after surgery (e.g., due to age or multiple comorbidities). Second, it could also be performed in a patient with a ruptured aneurysm as a temporary measure to quickly achieve hemodynamic stability and as a bridge to subsequent definite surgical treatment (2, 7, 8, 9).

Based on our experience handling the present case, we can propose several explanations for the successful use of EVAR in infected aortic aneurysms. First, immediate introduction of broad spectrum antibiotics is required as soon as an infected aortic aneurysm is suspected. This is usually followed by appropriate antibiotics determined by culture and sensitivity testing, which might eradicate many bacteria. Therefore, many authors suggest that EVAR is feasible when antibiotic suppression has achieved negative blood cultures prior to surgery (2, 3, 5, 7, 8). If active infections are evident, there is a high risk of recurrence of infection after the procedure. Therefore, patients who have extensive infection are preferably excluded from

endovascular repair. In the present case, the patient had high fever and increased levels of parameters (e.g., CRP) at the time of operation, suggesting that the patient had an active infection. Therefore, the endovascular option could be performed when the infection was treated, confirmed by adjustment of fever, CRP, and absence of microbes on blood and tissue cultures after treatment with antibiotics targeted against *K. pneumoniae*. Second, prolonged postoperative antibiotic therapy is also advocated as a key component for success; however, there is no consensus regarding the optimal duration of antibiotic therapy (9). Most commonly, parenteral antibiotics are given for 2 to 8 weeks; however, whether lifelong oral antibiotics are necessary is a matter of debate (2, 3, 8). During the 24-month follow-up in our case, the patient did not report any clinical manifestations, a finding supported by CT. Antibiotics were maintained for a short period of 2 days after treatment according to the suggestion of our communicable disease specialist to avoid adverse effects; we have not seen any sign of graft infection.

Based on our experience with this patient, we propose that EVAR might be an alternative therapy in selected patients who are not candidates for surgical replacement because of underlying disease when bacteremia and fever are controlled after treatment with targeted antibiotics for 3 weeks during hospitalization. Compared to conventional surgical treatment, EVAR with appropriate antibiotic therapy is a simpler, less traumatic and more efficient procedure.

Author Contributions

Conceptualization, B.H.G., K.Y.; data curation, B.H.G., K.Y., L.J.H.; investigation, all authors; project administration, K.Y.; supervision, K.Y.; visualization, B.H.G., K.Y., L.J.H.; writing—original draft, B.H.G., K.Y.; and writing—review & editing, all authors.

Conflicts of Interest

The authors have no potential conflicts of interest to disclose.

REFERENCES

1. Lee WK, Mossop PJ, Little AF, Fitt GJ, Vrazas JI, Hoang JK, et al. Infected (mycotic) aneurysms: spectrum of imaging appearances and management. *Radiographics* 2008;28:1853-1868
2. Huang YK, Ko PJ, Chen CL, Tsai FC, Wu CH, Lin PJ, et al. Therapeutic opinion on endovascular repair for mycotic aortic aneurysm. *Ann Vasc Surg* 2014;28:579-589
3. Kan CD, Lee HL, Yang YJ. Outcome after endovascular stent graft treatment for mycotic aortic aneurysm: a systematic review. *J Vasc Surg* 2007;46:906-912
4. Lederle FA, Freischlag JA, Kyriakides TC, Matsumura JS, Padberg FT Jr, Kohler TR, et al. Long-term comparison of endovascular and open repair of abdominal aortic aneurysm. *N Engl J Med* 2012;367:1988-1997
5. Sörelius K, Mani K, Björck M, Sedivy P, Wahlgren CM, Taylor P, et al. Endovascular treatment of mycotic aortic aneurysms: a European multicenter study. *Circulation* 2014;130:2136-2142
6. Chen YJ, Chen SY, Wang JT, Hsueh PR. Mycotic aneurysm caused by gas-forming serotype K5 *Klebsiella pneumoniae*. *Int J Infect Dis* 2009;13:e47-e48
7. Silverberg D, Halak M, Yakubovitch D, Reinitz ER, Garniek A, Rimon U, et al. Endovascular management of mycotic aortic aneurysms. *Vasc Endovascular Surg* 2010;44:693-696
8. Sedivy P, Spacek M, El Samman K, Belohlavek O, Mach T, Jindrak V, et al. Endovascular treatment of infected aortic aneurysms. *Eur J Vasc Endovasc Surg* 2012;44:385-394
9. Beltran-Ordóñez IS, Yian TS, Hou A, Hai EW. Mycotic aneurysm of infrarenal aorta: a case report and review of literature. *J Biosci Med (Irvine)* 2015;3:88

*Klebsiella pneumoniae*로 인해 발생한 감염성 동맥류의 성공적인 혈관 내 치료

변홍권¹ · 김 욱^{1*} · 이정환¹ · 이지선¹ · 박길선²

*Klebsiella pneumoniae*에 의해 발생하는 감염성 대동맥류는 드문 것으로 알려져 있다. 저자들은 감염성 대동맥류가 발생한 50세 남성에게 대해 성공적으로 이루어진 혈관 내 치료를 보고하고자 한다. 진단은 혈액 배양 검사와 전산화단층촬영을 통해 이루어졌다. 시술 전 투여된 항생제로 인해 임상증상과 혈액 배양이 개선되었다. 시술 후 24개월 동안 환자는 안정된 상태였으며 감염성 대동맥류의 감소가 일련의 전산화단층촬영을 통해 확인되었다. 따라서 기저 질환으로 인해 외과적 치료를 할 수 없는 환자에서 혈관 내 치료는 선택적 항생제 사용 후 균혈증과 열이 조절되는 경우 감염성 대동맥류에 대한 치료 방법이 될 수 있다.

¹충북대학교병원 영상의학과, ²충북대학교 의과대학 영상의학교실