

An Assessment of Vertebral Left Atrial Size in Relation to the Progress of Myxomatous Mitral Valve Disease in Dogs

Sun Hwa Kim, Kyoung Won Seo and Kun Ho Song¹

College of Veterinary Medicine, Chungnam National University, Daejeon 34134, South Korea

(Received: January 18, 2020 / Accepted: February 05, 2020)

Abstract : Left atrial enlargement (LAE) is an important diagnostic factor in dogs with myxomatous mitral valve disease (MMVD). It is associated with the onset of congestive heart failure (CHF). Recently, a new radiographic left atrial measurement called vertebral left atrial size (VLAS) was introduced. This can be considered as a left atrial enlargement above 2.3. It appears to be related to the severity of MMVD. However, serial changes in VLAS in relation to disease progression and improvement in patients have yet to be studied. This study aims to assess the value of VLAS as a left atrial size monitoring indicator by examining correlations with VHS, LA/Ao ratio and LVIDDN, and comparing serial changes in dogs. A total of 126 dogs were studied with their owners' consent. The dogs were classified into four MMVD groups (Control, B1, B2, C-D) following the ACVIM Guideline by performing a physical examination, radiography and echocardiography. Besides, 24 and 17 dogs were reevaluated to compare values in relation to the progression and improvement of MMVD. VLAS showed significant increase according to the progress of the MMVD stage. This was the same in the Maltese breed group. A strong positive correlation was found between LVIDDN, VHS, LA/Ao ratio, and VLAS. The results of this study found VLAS to be significantly different according to left atrium size, and there was a correlation between disease progression and VLAS levels in each dog. Therefore, VLAS may be used to detect changes in left atrium size as an additional monitoring index of MMVD.

Key words : MMVD, VLAS, LAE, canine.

Introduction

Myxomatous mitral valve disease (MMVD) is the most common canine heart disease, and it has a higher prevalence in small breeds than in large breeds (10). It is characterized by gradually progressive degeneration of the valve and regurgitation (2,10). The clinical symptoms eventually develop due to an increase in left atrial pressure after subclinical duration (8).

Left atrial enlargement (LAE) is an important indicator and predictor of disease chronicity and severity. It is useful in determining the diagnosis of disease, detecting progression, and assessing the necessity for the intervention of medication (3,6). Therefore, evaluation of left atrial size before the onset of left-sided heart failure is an important diagnostic assessment, and echocardiography is the gold standard method for the evaluation of cardiac structure and function (8,19). Despite the merits of echocardiography, there are several limitations in that it requires a skilled examiner, the cooperation of patients for accurate examination, and it is costly in terms of time and money (1).

Radiography is also an important diagnostic screening tool for cardiac enlargement including the left atrium (2,7). Furthermore, it is a gold standard tool for detecting congestive heart failure signs such as pulmonary edema and pleural effusion (1,2,11).

The American College of Veterinary Internal Medicine (ACVIM) 2019 Consensus proposed criteria to distinguish between stage B1 and B2, recommending treatment intervention in stage B2 based on clinical trials (15). The B2 criteria for evaluating cardiac remodeling include murmur intensity $\geq 3/6$, an echocardiographic LA/Ao ratio ≥ 1.6 (13), left ventricular internal diameter in diastole, normalized for body weight (LVIDDN) ≥ 1.7 (9), and a radiographic vertebral heart score (VHS) > 10.5 (12). All of the above criteria must be satisfied before the intervention of medication. Additionally, a new indicator of left atrium size, vertebral left atrial size (VLAS), was also introduced (15,18). It was stated in this consensus that "Studies are ongoing to determine a VLAS value that accurately predicts B2 remodeling, but in the absence of echocardiography, VLAS values of ≥ 3 likely identify Stage B2 MMVD" (15,18). In the study in which VLAS was first introduced, it was shown that VLAS had a high correlation with LA/Ao ratio and could be used as an indicator of left atrium size (18). In previous research, however, serial changes in VLAS in patients were not measured. Moreover, VLAS has a limitation in that there is no breed reference.

Therefore, our overall purposes are as follows: 1) to compare VLAS among groups based on the ACVIM 2019 Consensus; 2) to make comparisons among a group of one specific breed Maltese; 3) to evaluate the relationships between VLAS and VHS, LVIDDN, and LA/Ao ratio; 4) to compare serial changes in all values in each patient as the disease progresses and improves.

¹Corresponding author.
E-mail : songkh@cnu.ac.kr

Materials and Methods

Animals

There was a total of 126 dogs in this study (Table 1). All dogs were client-owned and were examined at the veterinary medical teaching hospital of Chungnam National University between March 2016 and September 2019. Before commencement of the study, the owner's consent of all of the dogs was obtained. A diagnosis of MMVD was made based on cardiovascular symptoms, physical examinations, blood analyses, thoracic radiography, and echocardiography. Dogs with MMVD were categorized into B1, B2, and C-D groups following the ACVIM Guideline (15). The values among a total of 60 Maltese were also compared. In addition, 24 and 17 dogs were included to compare the values in relation to the progression and improvement of MMVD. Twenty-four dogs, including Stage B2 (n = 14) and C-D (n = 10), showed onset and worsening of symptoms after three months to three years. Seventeen dogs, including Stage B2 (n = 8) and C-D (n = 9), showed improvement after three months to one year of treatment intervention. All of the patients were reexamined for measurement of post values.

Thoracic radiography

Thoracic radiography was performed to obtain right lateral views, left lateral views, and dorsoventral views in all of the dogs. VHS and VLAS were measured using a digital caliper in the right lateral view as described in earlier reports (6,18). For measurement of VLAS, the length from the ventral aspect of the carina to the junction of the posterior border of the left atrium and the dorsal border of the caudal vena cava was measured. Following the VHS measurement method, this measurement was then converted to be expressed as a total unit of vertebral length (15,18,21).

Echocardiography

All echocardiographic examinations were performed using an iU22® (Phillips, Bothell, WA, USA) to diagnose MMVD based on characteristic mitral regurgitation and mitral valve

prolapse detected by color doppler imaging in the left apical 4 chamber view in conjunction with two-dimensional echocardiography. LA/Ao ratio was obtained in the right two-dimensional short axis view. Left ventricular internal diameter in diastole (LVIDd) was measured in M-mode and normalized left ventricular internal diameter (LVIDDN) was calculated using the formula $(LVIDDN = LVIDd \text{ (cm)}/\text{weight (kg)}^{0.294})$ (9).

Statistical analysis

Statistical analysis was carried out using a commercial software program (IBM SPSS Statistics 24.0.0, SPSS Inc., USA). The values in each group, including age, weight, VHS, LA/Ao ratio, LVIDDN, and VLAS were presented as median and interquartile ranges (IQR). In this study, the values among the four groups were compared using the Kruskal-Wallis test, and post hoc tests were performed using the Bonferroni correction. Besides, Pearson correlation coefficients were calculated to assess correlations between VLAS and other values (VHS, LA/Ao ratio, LVIDDN), and Paired t-tests were performed to compare the values before and after disease progression and improvement. A *P* value of < 0.05 can be interpreted as statistically significant.

Results

The study population consisted of 126 dogs, and the characteristic data for age, weight, sex, and breed of the four groups were summarized (Table 1). The dogs examined in this study were classified by breed as follows: Maltese (n = 60), Shih-Tzu (n = 31), Yorkshire Terrier (n = 12), Poodle (n = 7), Mongrel (n = 5), Schnauzer (n = 5), Cocker Spaniel (n = 3), Pomeranian (n = 2) and Beagle (n = 1). The control group consisted of 24 dogs with a median age of 9 years (6.0-12.3) and a median weight of 4.0 kg (3.28-4.96). The ACVIM B1, B2, and C-D groups comprised 36 dogs, 24 dogs, and 27 dogs, respectively. The median ages of groups B1, B2, and C-D were 12.5 years (10-15), 13 years (11-14) and 13 years (11.5-14), and the median weights were 4.0 kg

Table 1. Characteristic data for 126 dogs in this study

Variable	Control	ACVIM B1	ACVIM B2	ACVIM C-D
Total (n = 126)	24	36	27	39
Age (yr)	9.0 (6.0-12.25)	12.5 (10-15)	13 (11-14)	13 (11.5-14)
Weight (kg)	4.0 (3.28-4.96)	4.0 (3.19-5.62)	4 (3.5-4.6)	3.4 (2.95-5.5)
Sex (M/F)	M (9), F (15)	M (18), F (18)	M (13), F (14)	M (16), F (23)
Breeds				
Beagle				1
Cocker spaniel			2	1
Maltese	6	16	15	23
Mongrel	2	1		2
Poodle		4	2	1
Pomeranian	2			
Schnauzer	1	1	1	2
Shih-tzu	4	13	7	7
Yorkshire terrier	9	1		2

ACVIM, American College of Veterinary Internal Medicine; M, male; F, Female.

Table 2. Descriptive data of radiographic and echocardiographic values among four groups

Variable	Control (n = 24)	ACVIM B1 (n = 36)	ACVIM B2 (n = 27)	ACVIM C-D (n = 39)
VHS	9.90 (9.33-10.50)	10.00 (9.70-10.48)	10.70 (10.60-11.10) ^{*†‡}	11.80 (11.00-12.30) ^{*†‡}
LA/Ao ratio	1.40 (1.29-1.53)	1.59 (1.29-1.70)	2.15 (2.00-2.50) ^{*†}	2.50 (2.10-2.90) ^{*†}
LVIDDN	1.30 (1.21-1.38)	1.40 (1.32-1.65) [*]	1.86 (1.74-2.00) ^{*†}	1.91 (1.76-2.12) ^{*†}
VLAS	1.90 (1.90-2.00)	2.00 (1.97-2.00)	2.70 (2.45-2.80) ^{*†}	3.00 (2.80-3.10) ^{*†‡}

ACVIM, American College of Veterinary Internal Medicine; VHS, Vertebral heart size; LA/Ao ratio, Left atrium to aorta ratio; LVIDDN, Left ventricular internal diameter in diastole, normalized for body weight; VLAS, Vertebral left atrial size. ^{*} $P < 0.05$, difference from control group; [†] $P < 0.05$, difference from ACVIM B1; [‡] $P < 0.05$, difference from ACVIM B2.

Table 3. Descriptive data of radiographic echocardiographic values in Maltese dogs (n = 60)

Variable	Control (n = 6)	ACVIM B1 (n = 16)	ACVIM B2 (n = 14)	ACVIM C-D (n = 23)
VHS	9.35(9.22-9.70)	10.15(9.90-10.50)	10.70(10.36-11.00) ^{*†}	11.40(11.10-12.10) ^{*†‡}
LA/Ao ratio	1.43(1.26-1.49)	1.60(1.31-1.75)	2.00(2.00-2.28) ^{*†}	2.10(2.10-2.68) ^{*†}
LVIDDN	1.26(1.21-1.41)	1.40(1.28-1.53) [*]	1.85(1.74-1.91) ^{*†}	1.91(1.76-2.11) ^{*†}
VLAS	1.90(1.90-1.90)	2.05(1.97-2.10)	2.50(2.23-2.74) ^{*†}	2.90(2.80-3.05) ^{*†‡}

ACVIM, American College of Veterinary Internal Medicine; VHS, Vertebral heart size; LA/Ao ratio, Left atrium to aorta ratio; LVIDDN, Left ventricular internal diameter in diastole, normalized for body weight; VLAS, Vertebral left atrial size. ^{*} $P < 0.05$, difference from control group; [†] $P < 0.05$, difference from ACVIM B1; [‡] $P < 0.05$, difference from ACVIM B2.

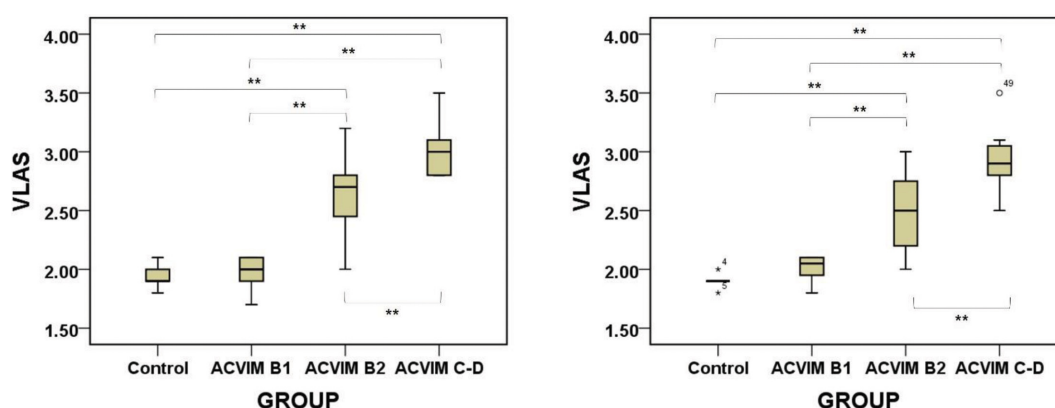


Fig 1. VLAS shows significant differences between groups except control group and B1 group in 126 dogs (A), and 60 Maltese dogs (B). Boxes represent values from the 25th to the 75th percentile, the horizontal line in each bow is the median. ACVIM, American College of Veterinary Internal Medicine; VLAS, Vertebral left atrial size. ****** $P < 0.01$.

(3.19-5.62), 4.0 kg (3.5-4.6), and 3.4 kg (2.95-5.5).

Descriptive data of the radiographic and echocardiographic values in each group were summarized (Table 2). Comparing the values among the groups, there was no significant difference between the control group and the B1 group except regarding LVIDDN. However, all of the values in the B2 and C groups were significantly larger than those in the control and B1 groups, and only VHS and VLAS showed significant differences between the B2 group and the C-D group. We also compared VLAS in only the Maltese dogs (n = 60) to overcome the limitation (Table 3). The results found that VLAS in the B2 and C groups were significantly larger than in the control and B1 groups. Also, the VLAS in the C-D group was significantly larger than in the B2 group (Fig 1).

When evaluating the correlations between VLAS and the other values (Table 4), VLAS was found to have a positive correlation with VHS ($R = 0.827$), LA/Ao ratio ($R = 0.826$) and LVIDDN ($R = 0.756$). We compared the differences in VHS, LA/Ao ratio, LVIDDN, and VLAS in each patient after

Table 4. Correlation analysis using Pearson correlation coefficient of VLAS and other values (VHS, LA/Ao ratio, LVIDDN)

	VHS	LA/Ao ratio	LVIDDN	VLAS
VHS	1			
LA/Ao ratio	0.749**	1		
LVIDDN	0.636**	0.730**	1	
VLAS	0.827**	0.826**	0.756**	1

VHS, Vertebral heart size; LA/Ao ratio, Left atrium to aorta ratio; LVIDDN, Left ventricular internal diameter in diastole, normalized for body weight; VLAS, Vertebral left atrial size.

^{*} $P < 0.05$, ^{**} $P < 0.01$.

disease progression and improvement (Table 5) (Fig 2). It was found that all of the values were significantly higher after disease progression ($P < 0.001$), and decreased after disease improvement ($P < 0.001$). Also, correlation between VHS, LA/Ao ratio, LVIDDN and VLAS variation (Table 6), VLAS variation showed positive correlation with VHS ($R = 0.860$),

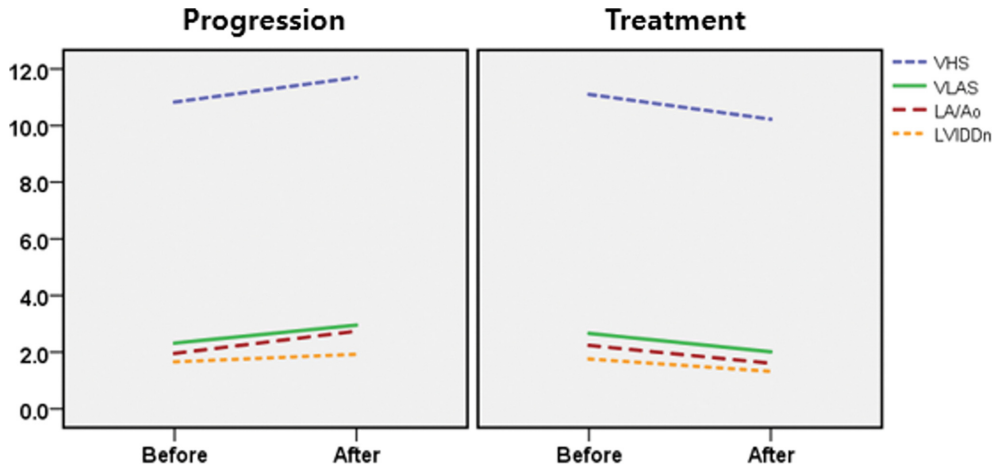


Fig 2. Figure showing changes in VHS, LA/Ao ratio, LVIDDN and VLAS before and after disease progression/ improvement. VHS, Vertebral heart size; LA/Ao ratio, Left atrium to aorta ratio; LVIDDN, Left ventricular internal diameter in diastole, normalized for body weight; VLAS, Vertebral left atrial size.

Table 5. Change of values from baseline to the progression and improvement of disease

	Progression			Improvement		
	Pre	Post	<i>P</i> value	Pre	Post	<i>P</i> value
VHS	10.83 ± 0.75	11.70 ± 0.89	< 0.001	11.10 ± 0.84	10.22 ± 0.58	< 0.001
LA/Ao	1.96 ± 0.44	2.74 ± 0.51	< 0.001	2.24 ± 0.42	1.61 ± 0.28	< 0.001
LVIDDN	1.66 ± 0.34	1.92 ± 0.29	< 0.001	1.76 ± 0.32	1.32 ± 0.28	< 0.001
VLAS	2.32 ± 0.41	2.95 ± 0.31	< 0.001	2.66 ± 0.37	2.01 ± 0.34	< 0.001

VHS, Vertebral heart size; LA/Ao ratio, Left atrium to aorta ratio; LVIDDN, Left ventricular internal diameter in diastole, normalized for body weight; VLAS, Vertebral left atrial size. *P* < 0.05.

Table 6. Correlation between VHS, LA/Ao ratio, LVIDDN and VLAS variation before and after disease progression and improvement

	diff_VHS	diff_LA/Ao ratio	diff_LVIDDN	diff_VLAS
diff_VHS				
diff_LA/Ao ratio	0.854**	1		
diff_LVIDDN	0.762**	0.751**	1	
diff_VLAS	0.860**	0.837**	0.783**	1

VHS, Vertebral heart size; LA/Ao ratio, Left atrium to aorta ratio; LVIDDN, Left ventricular internal diameter in diastole, normalized for body weight; VLAS, Vertebral left atrial size; diff, difference between pre and post. * *P* < 0.05, ** *P* < 0.01.

LA/Ao ratio (*R* = 0.837), and LVIDDN variation (*R* = 0.783).

Discussion

Currently, the ACVIM 2019 consensus is based on VHS, LVIDDN, and LA/Ao ratio for the evaluation of cardiac remodeling (15). In previous research, only the correlation between VLAS and LA/Ao ratio was examined (18). In our study, correlations with VHS and LVIDDN were also examined. The results showed that VLAS has a significant positive correlation with not only LA/Ao ratio, but also VHS and LVIDDN thereby indicating the possibility that this value reflects cardiac remodeling.

An earlier study highlighted the limitation that VLAS has no breed reference. To overcome this limitation, first we evaluated serial changes in the VLAS in each patient. Second, we compared VLAS among one specific breed group, Maltese.

The results identified that VLAS significantly changed according to the progression and improvement of MMVD, and VLAS variation tends to increase as VHS, LA/Ao, and LVIDDN variations increase. This positive correlation supports the case for considering VLAS as an additional monitoring factor given that VLAS increases with progress and decreases with improvement. In addition, the present study included patients receiving treatment in the C-D group, and the results showed that VLAS decreased after treatment in each patient. This suggests that the VLAS value in the C-D group was measured to be smaller than the actual value since VLAS decreased in the treated patients.

The significant increase in VLAS in relation to the progression of cardiac disease has already been demonstrated in a previous study (18). When comparing VLAS among dogs of the same breed a total 60 Maltese, similar results showing significant difference between all groups except Control-B1

were found in our study.

In the past, studies have measured the left atrium using radiography. In one study, left atrial size was measured using the trachea bifurcation angle (16). The results showed a significant difference between the left atrial enlargement group and the control group; however, there was no significant difference between mild, moderate, and severe LAE groups, so this was insufficient to be used as a diagnostic tool with low sensitivity.

In another study, the size of the left atrium was evaluated by measuring the length from the intersection of the short axis and long axis of the heart to the dorsal boundary of the left atrium, called the radiographic left atrial dimension (RLAD) (20). It can be concluded that RLAD tends to have difficulty in making accurate measurements due to overlap with the surrounding structure. The authors measured dorsal range of soft tissue opacity to the max, noting that this could be a potential drawback for RLAD in mild LAE.

Although the population size was small, we evaluated VLAS in Maltese breed in our study. The result revealed that VLAS showed significant increase according to the progress of the MMVD stage. Further studies focusing on various breeds are needed to establish a breed reference range for the universal clinical application of VLAS. The left atrium is a three-dimensional (3D) structure that dilates asymmetrically with variable sizes and shapes (14,22). Therefore, LA/Ao ratio reflects LAE with low accuracy, and volume based measurement in multiple planes is more precise than the LA/Ao ratio (14,17). In a study comparing volume-based method and linear methods (LA/Ao ratio), LA/Ao ratio and the LA volume showed a curvilinear relationship, which derived very different value as the volume increases (14). To achieve higher accuracy than LA/Ao ratio, further study is needed to compare the correlation between VLAS and LAV and to determine the cut-off value of VLAS through LAV.

MMVD is a disease that cannot be completely cured, and needs to be managed for life. In addition, it is known that appropriate treatment intervention can be useful for prognosis by prolonging the preclinical phase (5,6). Thus, periodic monitoring of the patient is important, and X-ray is more efficient in terms of cost and time. The results of this study have confirmed that regular monitoring of VLAS may be helpful in detecting changes in left atrium size as an additional monitoring index of MMVD.

References

- Abbott JA. Acquired valvular disease. Manual of canine and feline cardiology. Philadelphia: Elsevier Saunders. 2008: 110-138.
- Atkins C, Bonagura J, Ettinger S, Fox P, Gordon S, Haggstrom J, Hamlin R, Keene B, Luis-Fuentes V, Stepien R. Guidelines for the diagnosis and treatment of canine chronic valvular heart disease. *J Vet Intern Med* 2009; 23: 1142-1150.
- Borgarelli M, Crosara S, Lamb K, Savarino P, La Rosa G, Tarducci A, Haggstrom J. Survival characteristics and prognostic variables of dogs with preclinical chronic degenerative mitral valve disease attributable to myxomatous degeneration. *J Vet Intern Med* 2012; 26: 69-75.
- Borgarelli M, Haggstrom J. Canine degenerative myxomatous mitral valve disease: natural history, clinical presentation and therapy. *Vet Clin North Am Small Anim Pract* 2010; 40: 651-663.
- Boswood A, Haeggstroem J, Gordon SG, Wess G, Stepiens RL, Oyama MA, Keene BW, Bonagura J, MacDonald KA, Patteson M. Die Wirkung von Pimobendan bei Hunden mit präklinischer myxomatöser Mitralklappenerkrankung und Kardiomegalie: Die EPIC-Studie-Eine randomisierte klinische Studie. *Kleintierpraxis*. 2017: 64-87.
- Boswood A, Haggstrom J, Gordon SG, Wess G, Stepien RL, Oyama MA, Keene BW, Bonagura J, MacDonald KA, Patteson M, Smith S, Fox PR, Sanderson K, Woolley R, Szatmári V, Menaut P, Church WM, O'Sullivan ML, Jaudon JP, Kresken JG, Rush J, Barrett KA, Rosenthal SL, Saunders AB, Ljungvall I, Deinert M, Bomassi E, Estrada AH, Fernandez Del Palacio MJ, Moise NS, Abbott JA, Fujii Y, Spier A, Luethy MW, Santilli RA, Uechi M, Tidholm A, Watson P. Effect of Pimobendan in dogs with preclinical myxomatous mitral valve disease and cardiomegaly: The EPIC Study-A randomized clinical trial. *J Vet Intern Med* 2016; 30: 1765-1779.
- Buchanan JW, Bücheler J. Vertebral scale system to measure canine heart size in radiographs. *J Am Vet Med Assoc* 1995; 206: 194-194.
- Chetboul V, Tissier R. Echocardiographic assessment of canine degenerative mitral valve disease. *J Vet Cardiol* 2012; 14: 127-148.
- Cornell CC, Kittleson MD, Torre PD, Häggström J, Lombard CW, Pedersen HD, Vollmar A, Wey A. Allometric scaling of M-mode cardiac measurements in normal adult dogs. *J Vet Intern Med* 2004; 18: 311-321.
- Detweiler DK, Patterson DF. The prevalence and types of cardiovascular disease in dogs. *Ann N Y Acad Sci* 1965; 127: 481-516.
- Diana A, Guglielmini C, Pivetta M, Sanacore A, Di Tommaso M, Lord PF, Cipone M. Radiographic features of cardiogenic pulmonary edema in dogs with mitral regurgitation: 61 cases (1998-2007). *J Am Vet Med Assoc* 2009; 235: 1058-1063.
- Hansson K, Häggström J, Kvart C, Lord P. Interobserver variability of vertebral heart size measurements in dogs with normal and enlarged hearts. *Vet Radiol Ultrasound* 2005; 46: 122-130.
- Hansson K, Häggström J, Kvart C, Lord P. Left atrial to aortic root indices using two-dimensional and M-mode echocardiography in cavalier King Charles spaniels with and without left atrial enlargement. *Vet Radiol Ultrasound* 2002; 43: 568-575.
- Höllmer M, Willeßen J, Tolver A, Koch J. Comparison of four echocardiographic methods to determine left atrial size in dogs. *J Vet Cardiol* 2016; 18: 137-145.
- Keene BW, Atkins CE, Bonagura JD, Fox PR, Haggstrom J, Fuentes VL, Oyama MA, Rush JE, Stepien R, Uechi M. ACVIM consensus guidelines for the diagnosis and treatment of myxomatous mitral valve disease in dogs. *J Vet Intern Med* 2019; 33: 1127-1140.
- Le Roux A, Rademacher N, Saelinger C, Rodriguez D, Pariat R, Gaschen L. Value of tracheal bifurcation angle measurement as a radiographic sign of left atrial enlargement in dogs. *Vet Radiol Ultrasound* 2012; 53: 28-33.
- Lester SJ, Ryan EW, Schiller NB, Foster E. Best method in clinical practice and in research studies to determine left atrial size. *Am J Cardiol* 1999; 84: 829-832.
- Malcolm EL, Visser LC, Phillips KL, Johnson LR. Diagnostic value of vertebral left atrial size as determined from thoracic radiographs for assessment of left atrial size in dogs with myxomatous mitral valve disease. *J Am Vet Med Assoc* 2018;

- 253: 1038-1045.
19. Rishniw M, Erb HN. Evaluation of four 2-dimensional echocardiographic methods of assessing left atrial size in dogs. *J Vet Intern Med* 2000; 14: 429-435.
 20. Salguero XS, Prandi D, Llabrés-Díaz F, Manzanilla EG, Bussadori C. A radiographic measurement of left atrial size in dogs. *Ir Vet J* 2018; 71: 25.
 21. Sánchez X, Prandi D, Badiella L, Vázquez A, Llabrés-Díaz F, Bussadori C, Domènech O. A new method of computing the vertebral heart scale by means of direct standardisation. *J Small Anim Pract* 2012; 53: 641-645.
 22. Suh I-W, Song J-M, Lee E-Y, Kang S-H, Kim M-J, Kim J-J, Kang DH, Song JK. Left atrial volume measured by real-time 3-dimensional echocardiography predicts clinical outcomes in patients with severe left ventricular dysfunction and in sinus rhythm. *J Am Soc Echocardiogr* 2008; 21: 439-445.