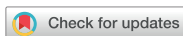

Original Article  
Medical Imaging



# Can distinction between the renal cortex and outer medulla on ultrasonography predict estimated glomerular filtration rate in canine chronic kidney diseases?

Siheon Lee , Sungkyun Hong , Seungji Kim , Dayoung Oh , Sangkyung Choen , Mincheol Choi , Junghee Yoon \*

College of Veterinary Medicine and the Research Institute for Veterinary Science, Seoul National University, Seoul 08826, Korea



Received: Jan 24, 2020  
Revised: May 25, 2020  
Accepted: May 25, 2020

\*Corresponding author:








Junghee Yoon

College of Veterinary Medicine and the Research Institute for Veterinary Science, Seoul National University, 1 Gwanak-ro, Gwanak-gu, Seoul 08826, Korea.  
E-mail: heeyoon@snu.ac.kr

© 2020 The Korean Society of Veterinary Science

This is an Open Access article distributed under the terms of the Creative Commons Attribution Non-Commercial License (<https://creativecommons.org/licenses/by-nc/4.0>) which permits unrestricted non-commercial use, distribution, and reproduction in any medium, provided the original work is properly cited.

ORCID iDs

Siheon Lee   
<https://orcid.org/0000-0002-9416-2945>  
Sungkyun Hong   
<https://orcid.org/0000-0001-7459-4639>  
Seungji Kim   
<https://orcid.org/0000-0003-2916-3084>  
Dayoung Oh   
<https://orcid.org/0000-0001-9517-1918>  
Sangkyung Choen   
<https://orcid.org/0000-0001-6009-4385>  
Mincheol Choi   
<https://orcid.org/0000-0002-3456-4790>  
Junghee Yoon   
<https://orcid.org/0000-0002-2077-763X>

## ABSTRACT

**Background:** Quantitative evaluation of renal cortical echogenicity (RCE) has been tried and developed in human and veterinary medicine.

**Objectives:** The objective of this study was to propose a method for evaluating RCE quantitatively and intuitively, and to determine associations between ultrasonographic renal structural distinction and estimated glomerular filtration rate (eGFR) in canine chronic kidney disease (CKD).

**Methods:** Data were collected on 63 dogs, including 27 with normal kidney function and 36 CKD patients. Symmetric dimethylarginine and creatinine concentrations were measured for calculating eGFR. RCE was evaluated as 3 grades on ultrasonography images according to the distinction between the renal cortex and outer medulla. The RCE grade of each kidney was measured.

**Results:** There was a significant difference in eGFR between the group normal and CKD ( $p < 0.001$ ). As mean of RCE grades (the mean values of each right and left kidney's RCE grade) increases, the proportion of group CKD among the patients in each grade increases ( $p < 0.001$ ). Also, severity of RCE (classified as "high" if any right or left kidney evaluated as RCE grade 3, "low" otherwise) and eGFR is good indicator for predicting group CKD ( $p < 0.001$ ).

**Conclusions:** The degree of distinction between the renal cortex and the outer medulla is closely related to renal function including eGFR and the RCE grade defined in this study can be used as a method of objectively evaluating RCE.

**Keywords:** Canine chronic kidney disease; renal cortical echogenicity; cortex; outer medulla; eGFR

## INTRODUCTION

Ultrasound (US) evaluation of the kidney is a routine test commonly used in veterinary medicine [1]. B-mode (brightness mode) US evaluation of canine kidneys has been used to the examination of the renal margin, renal cortical echogenicity (RCE) [2,3], and calculi [4] and lesions such as cysts and neoplastic masses [5,6].

**Conflict of Interest**

The authors declare no conflicts of interest.

**Author Contributions**

Conceptualization: Lee S, Yoon J; Data curation: Lee S; Formal analysis: Lee S; Investigation: Lee S, Hong S, Kim S, Oh D, Choen S; Methodology: Lee S, Hong S, Kim S, Oh D, Choen S; Project administration: Lee S, Yoon J; Resources: Lee S, Hong S, Kim S, Oh D, Choen S; Supervision: Lee S, Yoon J; Validation: Lee S, Yoon J; Visualization: Lee S, Yoon J; Writing - original draft: Lee S, Hong S, Kim S, Oh D, Choen S; Writing - review & editing: Lee S, Choi M, Yoon J

This study was conducted within the authors' institution except for the symmetric dimethylarginine (SDMA) concentration measurement.

The evaluation of RCE is typically performed by comparison with adjacent organs (for example, the liver and spleen). However, this method is subjective because it may differ according to the judgement of the US evaluator or as a result of abnormalities in the comparison organs. There is a recent report that the cortex of the canine kidney should be distinguished from the outer medulla [7]. This report concluded that the canine renal cortex on US is actually composed of a true cortex and either an isoechoic or a hyperechoic outer medulla. The authors perceived that RCE evaluation was not evaluated separately from the outer medulla in previous studies [1,2,8,9]. Therefore, it is assumed that the evaluation of the canine RCE can be more intuitively and objectively compared to the outer medulla than the surrounding organs such as liver or spleen.

The authors also note that quantitative evaluation of kidney using imaging modalities has been studied and developed in human [10-15]. Quantitative assessment of the kidney is helpful in diagnosing or evaluating the prognosis of chronic kidney disease (CKD) patients in humans. These quantitative data are mainly compared with estimated glomerular filtration rate (eGFR) in human studies and the results of these studies show that the imaging quantitative data of the kidney are closely related to eGFR in CKD patients.

Various methods on calculating eGFR using objective patient information including age, race, sex, weight and biochemical values have been developed in humans [16-20]. Although there are direct methods for obtaining glomerular filtration rate (GFR) such as measuring renal clearance of insulin or exogenous creatinine with the use of radiolabeled markers, the clinical application of these methods is not easy [21]. Also, GFR has been examined indirectly using computed tomography and iohexol injections [22]. However, due to the cost and anesthesia protocol, this is also difficult to apply to clinically in veterinary medicine. Recently, it has been established that eGFR using symmetric dimethylarginine (SDMA) and creatinine concentration indirectly estimates GFR in animals (M. Yerramilli, Yerramilli MVSN, inventors; IDEXX Laboratories, Inc., Proprietor. Methods for detecting renal disease. European patent EP 3041576B1. 19.06.2019.). The authors conducted this study by using the eGFR for quantifying renal function. To our knowledge, there are no detailed studies in veterinary medicine examining the relationship between eGFR and RCE that focuses only on the renal cortex, except for the outer medulla.

The authors hypothesized that the degree of distinction between renal cortex and outer medulla could be associated with renal function. Based on this hypothesis, quantitative evaluation of RCE was conducted. In this study, the RCE grade was determined according to the distinction between renal cortex and outer medulla. The aim of this study was to propose criteria for objectively evaluating RCE using only the structural features of the canine kidney via US as opposed to comparisons with other organs. In addition, we aim to investigate the relationship between eGFR and RCE, specifically in canine patients with CKD.

## MATERIALS AND METHODS

### Study design

Canine patients who visited our institution between June 2016 and August 2017 were eligible for inclusion of the study. Patients selected were those dogs that had SDMA testing (IDEXX Reference Laboratories, Inc., Korea) and creatinine concentrations determined on the same day and who had US performed. Patients were excluded if the dates of the biochemical

measurements (SDMA and creatinine) and the US evaluation were more than 1 month apart. Cases with post-renal azotemia because of urinary tract obstruction, acute kidney injury, a dialysis history, a solitary kidney (for example, congenital or renal resection history), renal neoplasia, severe cortical structure deformation caused by multiple or large sized cystic lesions of the cortex, renal asymmetry (a difference in renal length greater than 5 mm between kidneys on the US findings) were excluded. The criteria used to classify patients as acute kidney injury in this study were as follows. Patient history: intoxication, prolonged anesthesia, medication (intentional or mistake); Renomegaly: Renomegaly was differentiated based on radiographic criterion that the normal canine kidney size is 2.5 to 3.5 times the length of the second lumbar vertebra in ventrodorsal radiographic images; Clinical signs: anuria, oligouria. All patients were retrospectively classified into group normal and group CKD based on medical records. Patients in group CKD were diagnosed with CKD in our institution considering the patient's biochemical values, persistence of clinical symptoms, urinalysis results, and diagnostic imaging findings.

### Grading RCE using US

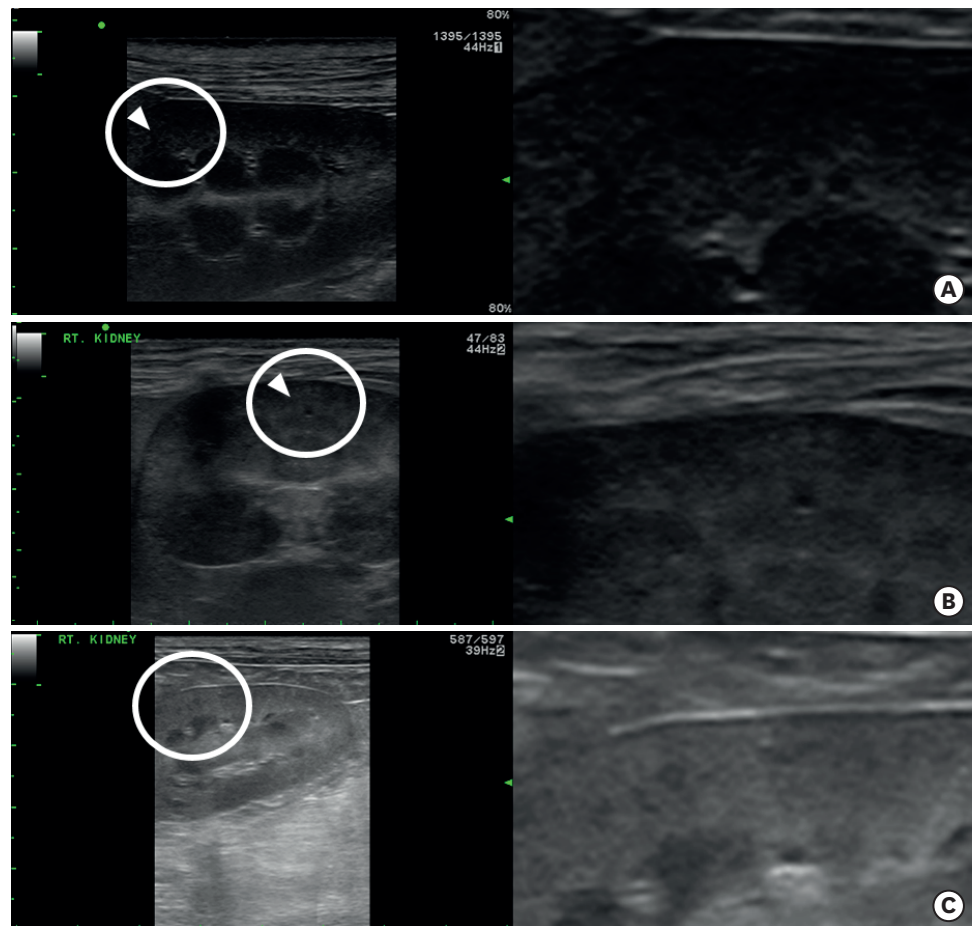
All US scans were obtained using commercial US products (Prosound alpha 7; Hitachi, Ltd., Japan), and either microconvex (4–10 MHz) or linear (4–13 MHz) probes were used. RCE was divided into 3 grades according to the degree of distinction of the renal cortex and outer medulla on DICOM images. If the border between the renal cortex and outer medulla could be clearly distinguishable, it was classified as grade 1. If the border with the outer medulla was ambiguous, it was classified as grade 2. Finally, a grade 3 classification was given if it was impossible to distinguish the border of the outer medulla. The RCE grade of each kidney was measured. In this study, mean of RCE grades (mRCE; the mean values of each right and left kidneys RCE grades of the same patient), and severity of RCE grades (sRCE; classified as "high" if any right or left kidney evaluated as RCE grade 3, "low" otherwise) were used in the statistical analyses. Examples of each RCE grade are shown in **Fig. 1**.

### Quantification of renal function using eGFR

In this study, renal function was quantified using the eGFR, which was developed by Yerramilli et al. (M. Yerramilli, Yerramilli MVSN, inventors; IDEXX Laboratories, Inc., Proprietor. Methods for detecting renal disease. European patent EP 3041576B1. 19.06.2019.) based on SDMA and creatinine concentrations in animal patients. Using 20 female CKD dogs induced by X-linked hereditary nephropathies, the eGFR formula was derived from comparison between SDMA and creatinine combination with actual GFR measures using the iohexol clearance method. The formula for eGFR presented in this patent is  $[(\text{creatinine})^p \times (\text{SDMA})^q]$ . In this formula,  $P = -5$  to  $0$ , and  $Q = -2.5$  to  $0$  (excluding  $0$ ). The equation used in this study was  $[\text{eGFR} \approx (\text{creatinine})^{-1.5} \times (\text{SDMA})^{-0.25}]$  which was presented as the most ideal and simplified format (M. Yerramilli, Yerramilli MVSN, inventors; IDEXX Laboratories, Inc., Proprietor. Methods for detecting renal disease. European patent EP 3041576B1. 19.06.2019.).

### Statistical methods

All statistical analyses were performed by R (version 3.6.0) and Rex (version 3.0.3). Difference in eGFR between the groups normal and CKD was compared using the Welch's *t*-test. The Cochran–Armitage trend test was used to confirm whether the ratio of group CKD tended to increase or decrease with increasing mRCE. The ordinal logistic regression model was fitted for the mRCE as an ordinal outcome (grade 1 to grade 3) with eGFR as a continuous covariate. Multivariate logistic regression was fitted to evaluate the effect of variables including eGFR and sRCE (low/high) on the diagnosis of group CKD.



**Fig. 1.** RCE grade classification. The right image of each figure is an enlarged image of the area indicated by the circle in the left image. (A) Grade 1 is defined as a clear distinction of the border of the cortex and outer medulla. In (B), the boundary between the cortex and outer medulla becomes ambiguous. Although unclear, if the boundary between the cortex and outer medulla can be distinguished, as in this example, the authors classified the RCE grade as 2. In (C), the boundary between the cortex and outer medulla cannot be distinguished. In this case, RCE grade was classified as grade 3. The arrow head is the boundary between the cortex and outer medulla. If a patient's left and right kidney were classified as RCE grade 1 and 2, for example, mRCE (1.5) and sRCE (low) were recorded. If a patient's left and right kidney were classified as RCE grade 2 and 3, for example, mRCE (2.5) and sRCE (high) were recorded. RCE, renal cortical echogenicity; mRCE, mean of renal cortical echogenicity grades; sRCE, severity of renal cortical echogenicity grades.

## RESULTS

During the study period, abdominal US, SDMA and creatinine concentrations were evaluated in 167 cases. Of these, 72 cases were excluded because the US evaluation and the biochemical measurements were more than 1 month interval. In addition, 32 cases were excluded due to: post-renal azotemia (n = 5), acute kidney injury (n = 8), dialysis history (n = 2), a solitary kidney (n = 2), renal neoplasia (n = 6), severe cortical structure deformations (n = 5), and renal asymmetry (n = 4).

Therefore, 63 cases satisfied the criteria for inclusion in this study. Thirty-five were male (5 intact) and 28 were female (7 intact). Small breeds were the most common breeds participating in this study. The breeds included 23 Malteses, 8 Shih-Tzus, 7 Miniature poodles, 7 mixed breeds, 6 Yorkshire terriers, 3 Pomeranians, 3 Schnauzers, 2 Cocker

spaniels, 2 Miniature pinschers, 1 Chihuahua, and 1 Welsh corgi. Of these, 27 were in group normal and 36 were in group CKD. Group normal visited authors' institution for the following reasons: dermatologic disorders (n = 1), cardiovascular system disorders (n = 9), endocrine disorders (n = 7), orthopedic disorders (n = 1), neurological disorders (n = 2), digestive system disorders (n = 1), hepatobiliary and pancreatic disorders (n = 3), hematological disorders such as anemia (n = 3), respiratory system disorders (n = 3), otitis externa (n = 1), epistaxis (n = 1), and not-specified (n = 1). Demographic data for these 63 cases are presented in **Table 1**. **Table 2** summarizes the distribution of patients according to each RCE grade, mRCE, sRCE for groups normal and CKD.

The differences in eGFR between the groups in this study were examined. There was a significant difference in eGFR between group normal and CKD ( $p < 0.001$ ). The comparison of eGFR between groups (normal, CKD) represented in box plots are shown in **Fig. 2**.

The mRCE was divided into 5 stages ranging from 1 to 3 at 0.5 intervals since it is expressed as the average value of the RCE grade of the left and right kidneys. **Fig. 3** shows the distribution of the mean RCE grade for each group. We examined whether the proportion of group CKD among patients in each grade increases with increasing grade 1, 1.5, 2, and 2.5, 3. The ratio of cases in group CKD tended to increase with increasing mRCE ( $p < 0.001$ , Cochran–Armitage trend test). This suggests that the mRCE increases with the deterioration of renal function. In other words, we found that as mRCE increases, the proportion of group CKD among the patients in each grade increases. The frequency of the mRCE in each group is shown in **Table 2**.

**Table 1.** Demographic data of the study population in the group normal (n = 27) and the group CKD (n = 36)

Variables	Group normal (n = 27)	Group CKD (n = 36)
<b>Sex</b>		
Female	3	4
Female spayed	8	13
Male	1	4
Male castrated	15	15
<b>Breeds</b>		
Maltese	9	14
Shih-Tzu	2	6
Miniature poodle	4	3
Mixed breed	6	1
Yorkshire terrier	1	5
Others*	5	7
Age (yr)	12 (1–16) 11.07 ± 3.95	13 (4–17) 11.97 ± 3.02
Body weight (kg)	4.4 (1.05–13.73) 5.23 ± 2.57	3.98 (1.93–10.14) 4.29 ± 1.87
SDMA (µg/dL)	13 (9–27) 14.11 ± 4.06	22.5 (13–57) 26.5 ± 12.38
Creatinine (mg/dL)	0.95 (0.35–1.41) 0.93 ± 0.27	1.51 (0.60–4.95) 1.73 ± 0.97
eGFR (creatinine <sup>-1.5</sup> × SDMA <sup>-0.25</sup> )	0.59 (0.32–2.41) 0.74 ± 0.51	0.26 (0.03–1.04) 0.32 ± 0.24
BUN	20.8 (9.00–49.5) 25.03 ± 14.81	44.05 (8.00–283.90) 63.23 ± 63.26
mRCE	2 (1.0–2.5) 1.94 ± 0.25	2.5 (1.0–3.0) 2.51 ± 0.53

Values are presented as mean ± standard deviation or median (interquartile range).

CKD, chronic kidney disease; SDMA, symmetric dimethylarginine; eGFR, estimated glomerular filtration rate; BUN, blood urea nitrogen; mRCE, mean of renal cortical echogenicity grades.

\*Schnauzer, Pomeranian, Miniature pinscher, Cocker spaniel, Chihuahua, Welsh corgi.

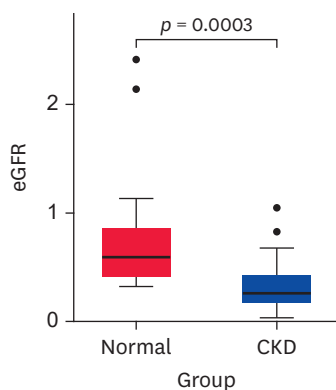
**Table 2.** Relationship between the frequency of mRCE and sRCE of the group normal and CKD

Left	RCE grade		No.	mRCE	sRCE	Group		Total
	Right					Normal	CKD	
1	1	2	1	Low	1 (3.7)	1 (2.8)	2 (3.2)	
1	2	2	1.5	Low	2 (7.4)	0 (0)	2 (3.2)	
1	3	0	2	High	0 (0)	0 (0)	0 (0)	
2	1	0	1.5	Low	0 (0)	0 (0)	0 (0)	
2	2	36	2	Low	23 (85.1)	13 (36.1)	36 (57.1)	
2	3	3	2.5	High	1 (3.7)	2 (5.6)	3 (4.8)	
3	1	0	2	High	0 (0)	0 (0)	0 (0)	
3	2	3	2.5	High	0 (0)	3 (8.3)	3 (4.8)	
3	3	17	3	High	0 (0)	17 (47.2)	17 (26.9)	
Total					27 (42.9)	36 (57.1)	63 (100)	

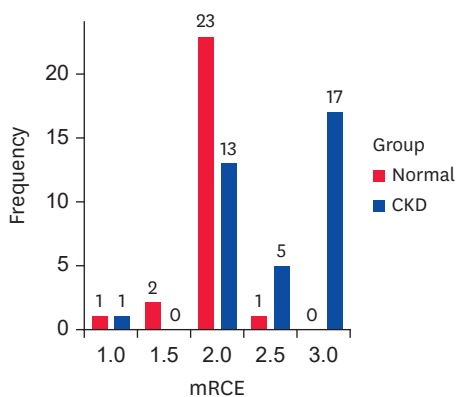
Values are presented as number (%).

The Cochran–Armitage trend test was used to examine the relationship between the ratio of all cases in group CKD and the mRCE ( $p < 0.001$ ).

mRCE, mean of renal cortical echogenicity grades; sRCE, severity of renal cortical echogenicity grades; RCE, renal cortical echogenicity; CKD, chronic kidney disease.

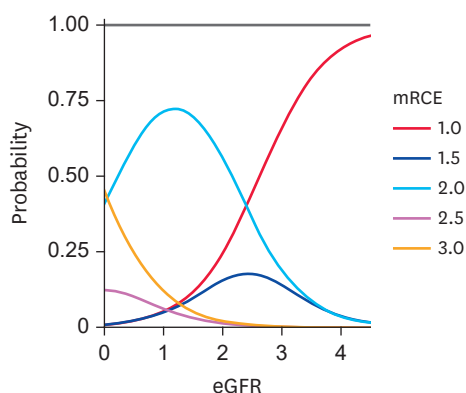


**Fig. 2.** Box plots of eGFR in group normal, CKD. The central line in the box represents the median. The horizontal lines at the top and bottom of the box are the upper and lower quartiles. The whiskers on the top and bottom of the box represent the highest and the lowest data within the 1.5 interquartile range. The dots (●) are considered outliers. The significance of the comparisons between the groups ( $p$  value) is indicated by the solid line. eGFR, estimated glomerular filtration rate; CKD, chronic kidney disease.



**Fig. 3.** The bar graph summarizes the distribution of the mRCE of group normal and CKD. mRCE, mean of renal cortical echogenicity grades; CKD, chronic kidney disease.

eGFR in ordinal logistic regression for the mRCE was a significant predictor with estimated odds ratio (OR) of 0.170 (Likelihood ratio statistic = 8.339,  $p = 0.004$ ). **Fig. 4** shows predicted curves for probability of each mRCE with various eGFR values.



**Fig. 4.** Predicted curves for probability of each mRCE with various eGFR values. The sum of the probabilities of measuring each 5 mRCE at a particular eGFR value is 1. According to this probability curves, as eGFR increases, the probability of measuring a relatively lower mRCE increases. eGFR, estimated glomerular filtration rate; mRCE, mean of renal cortical echogenicity grades.

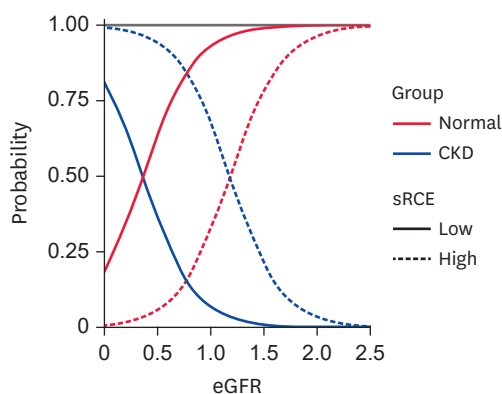
The association between sRCE, eGFR and group normal, CKD were analyzed with multivariate logistic regression. The multivariate logistic regression coefficients, ORs, and standard errors for significant factors are reported in **Table 3**. **Fig. 5** shows predicted curves for probability of each group with high and low sRCE.

**Table 3.** Results of multivariate logistic regression analysis for the factors associated with CKD (group CKD)

Variables	Coefficient (SE)	<i>p</i> value	OR (95% CI)
Intercept	1.461 (0.802)	0.069	-
sRCE*	3.332 (1.168)	0.004	28.003 (4.196–23.606)
eGFR	-4.067 (1.553)	0.009	0.017 (0.001–0.264)

CKD, chronic kidney disease; OR, odds ratio; CI, confidence interval; sRCE, severity of renal cortical echogenicity grades; eGFR, estimated glomerular filtration rate.

\*The reference level of sRCE is “low.”



**Fig. 5.** Predicted curves for probability of each group with sRCE and eGFR. As eGFR increases, the probability of predicting group normal is increasing and the probability of predicting group CKD is decreasing. At the same eGFR level, when the sRCE high, the probability of predicting group CKD is higher and the probability of predicting group normal is lower. eGFR, estimated glomerular filtration rate; sRCE, severity of renal cortical echogenicity grades; CKD, chronic kidney disease.

## DISCUSSION

In this study, there were significant differences in eGFR between groups normal and CKD. The proportion of group CKD in each mRCE tended to increase with increasing mRCE. Moreover, the OR of eGFR with a fixed mRCE was less than 1. This means that as eGFR increases, the probability of measuring lower mRCE increases. We used multivariate logistic regression to evaluate the effect of eGFR and sRCE on the diagnosis of CKD.

In this study, the RCE was graded according to the distinction of cortex and outer medulla on US images. Several studies attempted to objectively assess the degree of RCE elevation using comparisons to the liver in healthy dogs [8,9]. However, comparisons with adjacent organs are not objective RCE evaluation methods, especially in clinical patients. In this study, patients in group CKD were older than in group normal and liver echogenicity was also elevated.

In addition, most RCE-related studies did not focus only on the cortex, but on echo evaluation in the parenchymal region, including the cortex and outer medulla [2,3,8]. The renal cortex contains glomerulus, proximal and distal tubules. The outer medulla is the inner part of the cortex where the Henle loop and the collecting duct pass through. In dogs, CKD is known to be progressed by glomerulosclerosis and tubulointerstitial damage [23,24]. Therefore, it is more objective to assess the RCE focusing only on the cortex in CKD patients. It is more intuitive to evaluate the RCE in comparison with the outer medulla attached to the cortex rather than the liver or spleen. The outer medulla is a normal structure that is identifiable in the kidneys of dogs with normal renal function using US. It is known to be particularly recognizable in small breed dogs [7]. The sample used in this study consisted of mostly small breed dogs.

Inevitably, the subjectivity of the evaluator is involved in the assessment of RCE according to the distinction between the renal cortex and outer medulla. In particular, when classifying RCE grade as 2, the subjectivity of the evaluator is likely to be involved. However, the authors argue that, despite this limitation, the comparison with outer medulla which is the structure of the kidney itself will be more intuitive than any other criterion. The classification of patients with kidney evaluated grade 3 as sRCE “high” is intended to minimize the involvement of the subjectivity. The intent to apply sRCE for predictor in multivariate logistic regression is to confirm the hypothesis that differentiation between the renal cortex and the outer medulla using US would be difficult if renal function is decreased. It is very important that the multivariate logistic regression showed the probability of predicting group CKD is significantly higher in sRCE high than sRCE low. This suggests that the renal structural distinction can be used as criteria for assessing or diagnosing kidney function.

The eGFR formula was derived from the comparison between the SDMA and creatinine combination and the actual GFR using the iohexol clearance method. The equation is the  $(\text{SDMA})^p \times (\text{cr})^q$  that is most similar (statistically similar, linear regression fit) to GFR. Indeed, eGFR is not considered as a routine method for evaluating kidney function in veterinary medicine. The eGFR used in this study has a distinct limitation, which is not a specific formula considering patients' age or weight, species, and breed. As described above, eGFR has been widely studied and developed more sophisticatedly in human medicine, but it is yet understood incomplete protocol in veterinary medicine. Despite these limitations, we thought that this study has some significant meaning in that we made a new attempt. Although the authors should be satisfied that the values measured on US images has some



relationship with eGFR, we believe that this study could contribute to make eGFR a more precise and specific in veterinary practice in the future.

There are some limitations of this study. Firstly, relatively few case studies were included. If there were more cases, the relevance of mRCE or sRCE to the eGFR could be determined more precisely. Secondly, in this retrospective study, the RCE grade was evaluated on the US DICOM images. It is possible that evaluator bias influenced the classification of the RCE grade. Thirdly, renal function assessment was performed using eGFR rather than the measured GFR. The eGFR used in this study was based on the biochemical value of SDMA and creatinine. Because these can be influenced by the hydration state of the patient on the measuring day, eGFR may not be able to fully represent the patient's renal function. Moreover, the study was based on only one eGFR formula that can be generally applied to small animals, such as dogs and cats. It is not a specific formula for use in dogs or cats. Various formulas for calculating eGFR have been established in humans, but not in veterinary medicine. It could be suggested that if variable formulae for eGFR could be developed in the future that were specific to species or breeds for veterinary patients, the study could be conducted in a more diverse and precise way. Lastly, the biochemical values were not measured on the same day as the US evaluations. If the study was conducted using only cases where the US evaluation and the biochemical measurements were conducted on the same day, more reasonable results of the relationship between renal function and RCE using US could be obtained. Furthermore, if histopathological studies could also be performed, the relationship with RCE and eGFR would be more specified.

In conclusion, the degree of distinction between the renal cortex and the outer medulla is closely related to renal function including eGFR and the RCE grade defined in this study can be used as a method of objectively evaluating RCE. Therefore, structural distinction of the kidney derived using US images in canine CKD patients are good indicators of renal function.

## ACKNOWLEDGMENTS

The authors gratefully acknowledge Jaehoon An, DVM, MPH. PhD; graduate student in Biostatistics, Graduate School of Public Health, Seoul National University for assistance with the statistical analyses.

## REFERENCES

1. Nyland TG, Widmer WR, Mattoon JS. Urinary tract. In: Mattoon JS, Nyland TG, editors. *Small Animal Diagnostic Ultrasound*. 3rd ed. Saint Louis: Elsevier Saunders; 2015, 557-607.
2. Zotti A, Banzato T, Gelain ME, Centellegho C, Vaccaro C, Aresu L. Correlation of renal histopathology with renal echogenicity in dogs and cats: an ex-vivo quantitative study. *BMC Vet Res*. 2015;11(1):99.  
[PUBMED](#) | [CROSSREF](#)
3. Banzato T, Bonsembiante F, Aresu L, Zotti A. Relationship of diagnostic accuracy of renal cortical echogenicity with renal histopathology in dogs and cats, a quantitative study. *BMC Vet Res*. 2017;13(1):24.  
[PUBMED](#) | [CROSSREF](#)
4. Heng HG, Rohleder JJ, Pressler BM. Comparative sonographic appearance of nephroliths and associated acoustic shadowing artifacts in conventional vs. spatial compound imaging. *Vet Radiol Ultrasound*. 2012;53(2):217-220.  
[PUBMED](#) | [CROSSREF](#)

5. McAloney CA, Sharkey LC, Feeney DA, Seelig DM, Avery AC, Jessen CR. Evaluation of the diagnostic utility of cytologic examination of renal fine-needle aspirates from dogs and the use of ultrasonographic features to inform cytologic diagnosis. *J Am Vet Med Assoc.* 2018;252(10):1247-1256.  
[PUBMED](#) | [CROSSREF](#)
6. Taylor AJ, Lara-García A, Benigni L. Ultrasonographic characteristics of canine renal lymphoma. *Vet Radiol Ultrasound.* 2014;55(4):441-446.  
[PUBMED](#) | [CROSSREF](#)
7. Hart DV, Winter MD, Conway J, Berry CR. Ultrasound appearance of the outer medulla in dogs without renal dysfunction. *Vet Radiol Ultrasound.* 2013;54(6):652-658.  
[PUBMED](#) | [CROSSREF](#)
8. Mattei C, Pelander L, Hansson K, Uhlhorn M, Olsson U, Häggström J, et al. Renal ultrasonographic abnormalities are associated with low glomerular filtration rate calculated by scintigraphy in dogs. *Vet Radiol Ultrasound.* 2019;60(4):432-446.  
[PUBMED](#) | [CROSSREF](#)
9. Ivancić M, Mai W. Qualitative and quantitative comparison of renal vs. hepatic ultrasonographic intensity in healthy dogs. *Vet Radiol Ultrasound.* 2008;49(4):368-373.  
[PUBMED](#) | [CROSSREF](#)
10. Gao J, Perlman A, Kalache S, Berman N, Seshan S, Salvatore S, et al. Multiparametric quantitative ultrasound imaging in assessment of chronic kidney disease. *J Ultrasound Med.* 2017;36(11):2245-2256.  
[PUBMED](#) | [CROSSREF](#)
11. Shivashankara VU, Shivalli S, Pai BH, Acharya KD, Gopalakrishnan R, Srikanth V, et al. A comparative study of sonographic grading of renal parenchymal changes and estimated glomerular filtration rate (eGFR) using modified diet in renal disease formula. *J Clin Diagn Res.* 2016;10(2):TC09-TC11.  
[PUBMED](#) | [CROSSREF](#)
12. Lin HY, Lee YL, Lin KD, Chiu YW, Shin SJ, Hwang SJ, et al. Association of renal elasticity and renal function progression in patients with chronic kidney disease evaluated by real-time ultrasound elastography. *Sci Rep.* 2017;7(1):43303.  
[PUBMED](#) | [CROSSREF](#)
13. Beland MD, Walle NL, Machan JT, Cronan JJ. Renal cortical thickness measured at ultrasound: is it better than renal length as an indicator of renal function in chronic kidney disease? *AJR Am J Roentgenol.* 2010;195(2):W146-W149.  
[PUBMED](#) | [CROSSREF](#)
14. Yamashita SR, von Atzingen AC, Iared W, Bezerra ASA, Ammirati AL, Canziani MEF, et al. Value of renal cortical thickness as a predictor of renal function impairment in chronic renal disease patients. *Radiol Bras.* 2015;48(1):12-16.  
[PUBMED](#) | [CROSSREF](#)
15. Zhao J, Wang ZJ, Liu M, Zhu J, Zhang X, Zhang T, et al. Assessment of renal fibrosis in chronic kidney disease using diffusion-weighted MRI. *Clin Radiol.* 2014;69(11):1117-1122.  
[PUBMED](#) | [CROSSREF](#)
16. Levey AS, Coresh J, Greene T, Stevens LA, Zhang YL, Hendriksen S, et al. Using standardized serum creatinine values in the modification of diet in renal disease study equation for estimating glomerular filtration rate. *Ann Intern Med.* 2006;145(4):247-254.  
[PUBMED](#) | [CROSSREF](#)
17. Matsuo S, Imai E, Horio M, Yasuda Y, Tomita K, Nitta K, et al. Revised equations for estimated GFR from serum creatinine in Japan. *Am J Kidney Dis.* 2009;53(6):982-992.  
[PUBMED](#) | [CROSSREF](#)
18. Schwartz GJ, Muñoz A, Schneider MF, Mak RH, Kaskel F, Warady BA, et al. New equations to estimate GFR in children with CKD. *J Am Soc Nephrol.* 2009;20(3):629-637.  
[PUBMED](#) | [CROSSREF](#)
19. Teo BW, Xu H, Wang D, Li J, Sinha AK, Shuter B, et al. GFR estimating equations in a multiethnic Asian population. *Am J Kidney Dis.* 2011;58(1):56-63.  
[PUBMED](#) | [CROSSREF](#)
20. Zuo L, Ma YC, Zhou YH, Wang M, Xu GB, Wang HY. Application of GFR-estimating equations in Chinese patients with chronic kidney disease. *Am J Kidney Dis.* 2005;45(3):463-472.  
[PUBMED](#) | [CROSSREF](#)
21. Von Henty-Willson VE, Pressler BM. An overview of glomerular filtration rate testing in dogs and cats. *Vet J.* 2011;188(2):156-165.  
[PUBMED](#) | [CROSSREF](#)

22. Chang J, Kim S, Jung J, Lee H, Choi H, Chang D, et al. Assessment of glomerular filtration rate with dynamic computed tomography in normal Beagle dogs. *J Vet Sci.* 2011;12(4):393-399.  
[PUBMED](#) | [CROSSREF](#)
23. Breshears MA, Confer AW. Pathology of organ systems, the urinary system. In: Zachary JF, editor. *Pathology Basis of Veterinary Disease.* 6th ed. Saint Louis: Elsevier Saunders; 2017, 617-681.
24. Brown SA. Oxidative stress and chronic kidney disease. *Vet Clin North Am Small Anim Pract.* 2008;38(1):157-166.  
[PUBMED](#) | [CROSSREF](#)